



HOW TO...

Ophthalmic practice



Sue Stevens

Ophthalmic Resource Coordinator/Nurse Advisor, International Centre for Eye Health, London School of Hygiene and Tropical Medicine, Keppel Street, London WC1E 7HT, UK.

Remember – wash your hands before and after performing all procedures!

How to irrigate the eye

Indications

- To wash the eye thoroughly following alkali or acid burns
- To prevent corneal and conjunctival scarring
- To remove multiple foreign bodies from the eye.

This is an emergency situation – prompt and thorough action is vital.

*Do **not** delay to check visual acuity – proceed to irrigation immediately.*

Alkali and acid solutions in the eye may cause serious damage to vision.

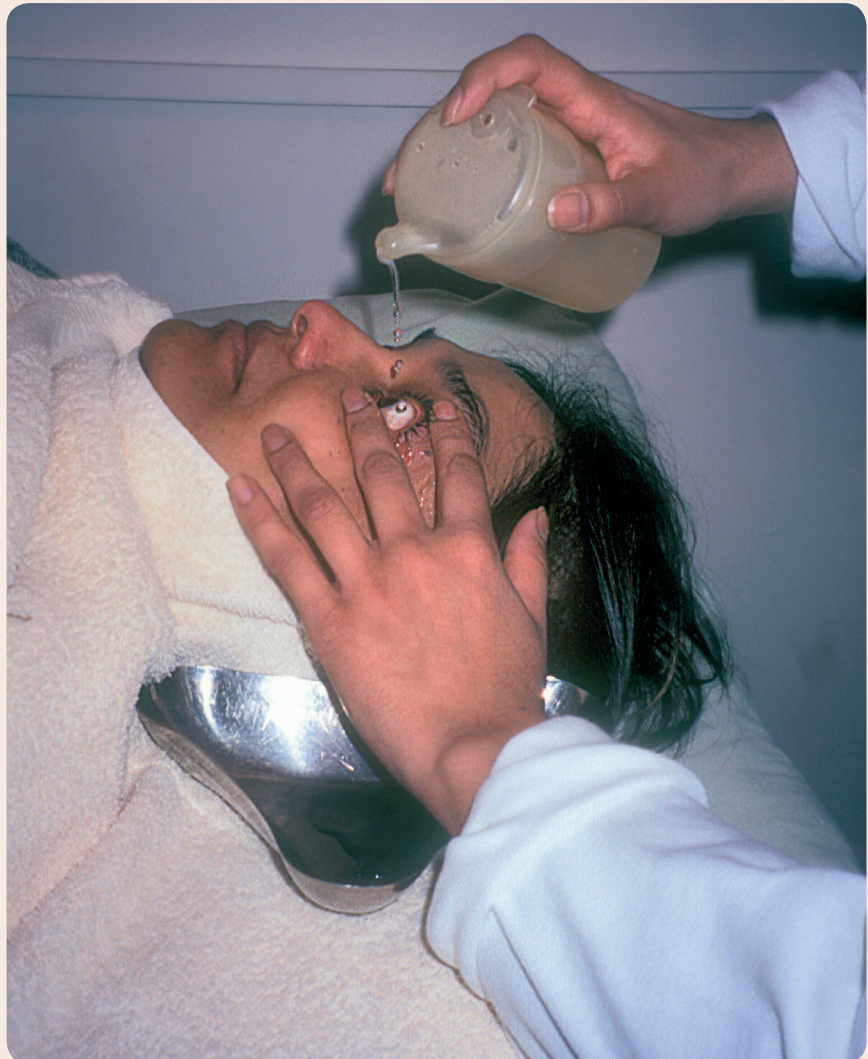You will need

- pH indicator strips or litmus paper, if available
- Local anaesthetic eye drops
- Towel
- Waterproof sheet
- Cotton buds
- Lid retractors
- Kidney dish
- Gauze swabs
- Small forceps
- Undine or any small receptacle with pouring spout, e.g., feeding cup
- Irrigating fluid – Universal Buffer Solution, if available. Otherwise, clean water at room temperature should be used.

Preparation

- If available, use pH indicator strips or litmus paper to assess the acidity / alkalinity of the tears caused by the injury
- Take two small strips and, with these, gently touch the inside of each lower eyelid
- Compare the colour result with the scale on the container or note the colour change of the litmus paper and record in the patient's documentation.

This is repeated after the procedure and will determine if sufficient irrigation has been done



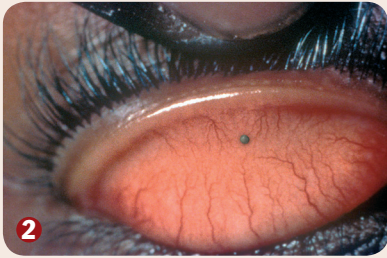
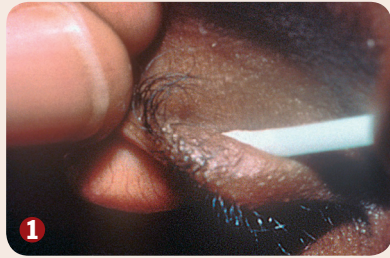Sue Stevens

Method

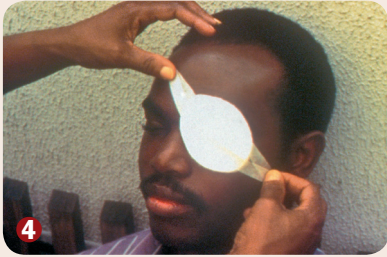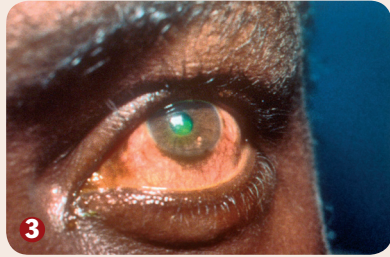
- Instil local anaesthetic eye drops
- With the patient sitting or lying down, protect the neck and shoulders with the waterproof sheet and towel
- Place the kidney dish against the cheek, on the affected side, with the head tilted sideways towards it
- Fill the undine or feeding cup with the irrigating fluid and test it for temperature by pouring a small amount against the patient's cheek
- Ask the patient to fix his/her gaze ahead
- Spread open the eyelids, if necessary **gently** using eyelid retractors
- Pour the fluid slowly and steadily, from a distance of no more than 5 centimetres, onto the front surface of the eye, and importantly, inside the lower eyelid and under the upper eyelid
- Evert the upper eyelid to access all of the upper conjunctival fornix
- Ask the patient to move the eye continuously in all directions while the irrigation is maintained for **at least** 15 minutes, 30 minutes is better
- Remove any residual foreign bodies with moist cotton buds or forceps
- Check the pH again and, if this is unchanged or not yet normal, continue the irrigation
- Check and record the visual acuity when the procedure is finished.

Refer the patient for urgent medical assessment

Murray McGavin



Murray McGavin



How to evert the upper eyelid and remove a sub-tarsal foreign body

Indications

- To examine the upper tarsal conjunctiva
- To remove a foreign body (FB) and so relieve pain
- To prevent a corneal abrasion and limit further damage.

Never evert the upper eye lid if a penetrating injury or corneal thinning (e.g., due to ulceration) is suspected.

You will need

- Cotton buds, paper clip or small blunt object, e.g., pen top
- Magnification
- Sterile needle
- Local anaesthetic drops
- Fluorescein strips
- Saline or cooled boiled water
- Prescribed antibiotic eye drops or ointment
- Tape, two eye pads and bandage.

Preparation

- Explain the procedure, advising the patient that he/she may experience a brief increase in discomfort but that it is important to relax and keep still
- Reassure and encourage him/her by stressing that relief should be felt immediately after the FB is removed.

Method

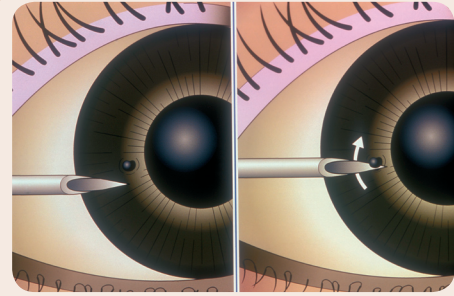
- Instil a drop of local anaesthetic and fluorescein dye
- Ask the patient to **look down**
- With one hand, hold the eyelashes of the upper eyelid between thumb and index finger
- With the other hand, place a cotton bud (or paper clip or other small blunt object) midway from the eyelid margin
- Turn the eyelid against steady and gentle pressure on the upper eyelid (picture 1)
- The eyelid will evert to reveal the upper tarsal conjunctiva. The FB may be large enough to be seen easily (picture 2)
- With a gentle upward movement, remove the FB using a moistened cotton bud. It may be necessary to use a needle if it has embedded
- If the FB cannot be seen, examine the eye again using a torch and magnification to ensure it is not missed
- On completion of the sub-tarsal examination and removal of FB, ask the patient to look up and the eyelid will return to its normal position
- Examine the rest of the eye for further particles
- If a corneal abrasion has resulted, instil antibiotic eye drops or ointment and apply a firm eye dressing, using two pads (a bandage may be added), for 24 hours (pictures 3 and 4).

Review the eye after 24 hours or earlier if pain persists.

Finally

- Wipe needle with a swab to confirm removal of FB and show it to the patient – this will reassure him/her it has been removed
- Dispose of needle carefully in an appropriate container.

Murray McGavin



Pak Sang Lee

How to remove a corneal foreign body

Indication

- To remove superficial material from the surface of the cornea, e.g., metal fragment.

You will need

- Slit lamp or magnification and torch
- Fluorescein strips
- Local anaesthetic drops
- Sterile No.21 gauge needle
- Sterile cotton buds
- Prescribed antibiotic eye drops or ointment
- Tape, two eye pads and bandage.

Preparation

- Position the patient comfortably with head supported – at the slit lamp, sitting in a chair or lying down

Method

- Instil local anaesthetic drops and fluorescein dye
- Ask the patient to look straight ahead, fix gaze and keep perfectly still
- With one hand, **gently** control the patient's eyelids
- With the other hand, support the sterile needle with two fingers and the thumb
- Approach the cornea slowly with the bevel of the needle uppermost and horizontally 'flat on' to the cornea
- Gently lift off the foreign body (FB) from the corneal surface. *Sometimes this is possible simply using a moist cotton bud and is safer practice in less skilled hands*
- Check the patient's eye, carefully everting the upper eyelid to ensure no FB's remain – a corneal abrasion may be seen
- Instil antibiotic ointment and apply a firm eye dressing, using two pads and a bandage, for 24 hours.

If there is any resistance and the FB does not come off easily do not persist! The FB may be deeply embedded and this situation should be referred for further medical attention.

Finally

- Wipe needle with a swab to confirm removal of FB and show it to the patient – this will reassure him/her it has been removed
- Dispose of needle carefully in an appropriate container.

Cactus design and illustration Ltd.