


**STUDIES ON THE INFECTIVITY AND PATHOGENICITY OF
LEISHMANIA SPECIES FROM LEISHMANIASIS DIFFUSA,
AND ON THE IMMUNE RESPONSE OF THE HOST,
IN LABORATORY ANIMALS**

**A thesis submitted for the degree of Doctor of
Philosophy (Faculty of Science) of the
University of London**

by

**ZUHAIR GHALIB HAYATEE, B.Sc. (LONDON),
D.A.P. & B. (LONDON)**



**The Department of Medical Protozoology,
London School of Hygiene and Tropical Medicine.**

February, 1971

ABSTRACT

1. The infectivity of three strains of Leishmania braziliensis pifanoi, strain V₁ and V₂ from Venezuela and L 15 from Brazil was studied in albino, hairless, "shaven" and "shaven" x albino mice; in hamsters, rats and guinea pigs.

Rats and guinea-pigs were not susceptible. Hamsters were more susceptible to infection than mice.

Hairless and "shaven" mice were more readily infected than albino or "shaven" x albino.

On intradermal inoculation, amastigotes were more effective than promastigotes in establishing infection.

The size of the lesion and the extent of metastasis were directly proportional to the dose of inoculum: the incubation period was inversely proportional to the dose of inoculum.

Primary and secondary lesions were restricted to hairless parts of the body.

The appearance of the primary lesion and metastasis to other parts of the body was followed in mice and hamsters:-

Intraperitoneal inoculation led to the involvement of the scrotum in 2 out of 6 hamsters and 11 out of 32 mice.

Intracardiac inoculation resulted in diffuse infection in 4 out of 4 "shaven" mice, and in none of the hairy mice (albino or hybrid).

Intradermal, intraperitoneal and intrasplenic inoculation with the parasite did not lead to visceral involvement.

Age and sex were not found to play an important role in influencing the course of infection.

2. The effect of the environmental temperature on the course of infection in mice was studied.

In mice adapted to live at -15°C , no lesion developed, but when these mice were transferred to 4°C lesions developed as in the control kept at room temperature.

Mice and hamsters inoculated with the parasite and kept at 4°C showed a normal course of infection.

When mice with active lesions were kept at 36.5°C , the parasites disappeared from the infected histiocytes within 26 - 39 hours and the lesions healed within 27 - 35 days.

3. The histiopathological picture of the disease was studied in mice and hamsters.

The lesions consisted mainly of a histiocytic granuloma in the dermis extending into the subdermis and sometimes into the epidermis in the form of a micro abscess. In the secondary lesions the subpapillary zone of the epidermis, which normally is clearly demarcated from the dermis, may become invaded with parasites.

The mucous membranes and cartilage of the ears usually remain free from infection, but the regional lymph nodes were found to become involved.

4. Attempts were made to attenuate the parasite by exposure to gamma-irradiation in order to use it as a vaccine. However, parasites exposed to from 6.5 to 17.5 Kilo rads retained their normal infectivity in mice.

ACKNOWLEDGEMENTS

During the last two years my work was supervised by Professor W.H.R. Lumsden; to whom I am deeply indebted for his unfailing interest, helpful suggestions and encouragement. I also wish to express my gratitude to Professor P.C.C. Garnham for suggesting the topic of the present work and for his kind guidance during the first part of this work, until his retirement in 1968.

Special thanks are due to Dr. A. Bryceson, Dr. R. Bray and Dr. J.R. Baker for valuable advice and suggestions, and to Dr. W.E. Ormerod, Dr. J.R. Baker and Dr. G. Targett for reading and correcting the manuscript.

I would like to thank Dr. J. Convit and Dr. R. Medina from the Department of Dermatology, Caracas University, Venezuela, for supplying me with the two strains of Leishmania braziliensis pifanoi, on which most of the present work was carried out. Dr. D. Walliker, Institute of Genetics, Edinburgh supplied me with hairless and "shaven" strains of mice, for which I thank him.

The author is grateful to Mr. G.S. Innes of the Department of Radiotherapy, St. Bartholemew's hospital for helping him in the irradiation of parasites and animals. I also wish to thank Dr. K.J. Collens,

Mr. G.W. Crockford, Medical Research Council, Environmental Physiology Research Unit at the London School of Hygiene and Tropical Medicine for making available the equipment used in measuring the body temperature of experimental animals.

I am very grateful to Dr. W.A. Tadros for her assistance in translating the French literature, constructive criticism, and valuable discussions.

I would like to thank Professor J.V. Scorza for the translation of some of the Spanish and Portuguese papers, and for helping me to correspond with workers in the same field in Venezuela.

While carrying out the present work at the London School of Hygiene and Tropical Medicine, I received valuable assistance from technical staff of the Department of Medical Protozoology, the staff of the library, the staff of the Visual Aid Department and the animal house, for which I wish to express my gratitude.

Thanks are due to Miss J. Crompton for typing the final manuscript of this thesis, and to Mrs. E. Manson for typing part of the draft.

Finally, the author wishes to acknowledge with thanks the financial support given him by the University of Mosul and the Calouste Gulbenkian Foundation.

TABLE OF CONTENTS

	Page
ABSTRACT	2
ACKNOWLEDGEMENTS	5
LIST OF TABLES	11
LIST OF FIGURES	12
GENERAL INTRODUCTION	21
Classification of <u>Leishmania</u> parasites	23
Diffuse cutaneous leishmaniasis	26
Aims of the present work	27
PART I - GENERAL MATERIALS AND METHODS	32
Parasites	32
Preparation of culture media	35
Experimental animals	37
Anaesthetics	38
Preparation of parasites for inoculation	40
i) Amastigotes	40
ii) Promastigotes	42
Routes of inoculation	43
Smear preparation and staining techniques	46
Collection, fixation and staining of tissues	48
Measurement of body temperature of mice	51
PART II - <u>THE INFECTIVITY OF LEISHMANIA BRAZILIENSIS</u> <u>PIFANOI TO LABORATORY ANIMALS</u>	59
Review of relevant literature	59
(a) Experimental leishmaniasis of mice	59
(b) Experimental leishmaniasis of hamsters	65
(c) Experimental leishmaniasis of other rodents	67

Part II (cont'd)	Page
Present work	68
(a) Diffuse cutaneous leishmaniasis in hamsters	68
(b) Diffuse cutaneous leishmaniasis in mice	86
(c) Attempts to infect albino rats	109
(d) Attempts to infect guinea pigs	110
Discussion	113
 PART III - THE EFFECTS OF ENVIRONMENTAL TEMPERATURE ON THE COURSE OF CUTANEOUS LEISHMANIASIS IN MICE AND HAMSTERS	 134
Review of relevant literature	134
Present work	139
(a) The effect of environmental temperature of -15°C on the course of cutaneous leishmaniasis in mice	 139
(b) The effect of environmental temperature of 4°C on the course of cutaneous leishmaniasis in mice and hamsters	 144
(c) The effect of environmental temperature of $35 - 36.5^{\circ}\text{C}$ on the course of cutaneous leishmaniasis in mice	 146
Discussion	162
 PART IV - EXPERIMENTAL PATHOLOGY OF AMERICAN DIFFUSE CUTANEOUS LEISHMANIASIS IN EXPERIMENTAL ANIMALS	 170
Review of relevant past work	170
Visceral leishmaniasis	170
Cutaneous leishmaniasis	174
a) Old World cutaneous leishmaniasis	174
b) New World cutaneous leishmaniasis	178

Part IV (cont'd)	Page
Diffuse cutaneous leishmaniasis	186
Caused by <u>L. donovani</u>	187
Caused by <u>L. tropica</u>	191
Caused by <u>L. brasiliensis</u>	195
Present work	200
Gross pathology of diffuse cutaneous leishmaniasis in hamsters and mice	200
Development of lesions in hamsters	201
Development of lesions in mice	207
Histopathology of diffuse cutaneous leishmaniasis in mice and hamsters	220
Histology of the normal skin of albino mice	220
Histopathology of the cutaneous lesions of hamsters	225
Histopathology of the cutaneous lesions of mice	237
The normal anatomy and histology of lymph nodes	257
Histopathology of lymph nodes	258
Discussion	263
 PART V - THE EFFECTS OF IRRADIATION ON THE INFECTIVITY OF <u>L. B. PIFANOI</u> AND THE POSSIBILITY OF USING SUCH MATERIAL AS VACCINE	 270
Review of past work	270

	Page
Present work	276
Exposure of amastigotes	276
Results	278
Morphological observations	278
Growth in culture	278
Infectivity to mice	278
Exposure of promastigotes	282
Results	282
Morphological observations	282
Growth in culture	283
Infectivity to mice	283
Subinoculation of irradiated amastigotes in mice	287
Challenge of mice which did not develop infection	289
Discussion	290
DISCUSSION ON THE IDENTITY OF THE CAUSATIVE ORGANISM OF AMERICAN DIFFUSE CUTANEOUS LEISHMANIASIS	296
BIBLIOGRAPHY	304

LIST OF TABLES

	<u>Page</u>
1. Course of <u>L.b.pifanoi</u> Strain V1 (Amastigotes) in hamsters.	70
2. Course of <u>L.b. pifanoi</u> Strain V1 (Promastigotes) in hamsters.	74
3. Summary of experimental infection of hamsters with Strain L 15.	79
4. Results of experimental infection of Albino mice with different doses of <u>L.b. pifanoi</u> Strain V1.	90
5. Summary of the infectivity of <u>L.b. pifanoi</u> Strain V1 in mice.	109
6. Results of attempts to infect Albino rats with <u>L.b. pifanoi</u> Strain V1.	110
7. Results of attempts to infect guinea pigs with <u>L.b. pifanoi</u> Strains V1 and V2.	112
8. The relation of environmental temperature to temperature of the body of mice.	149
9. The effect of irradiation on the infectivity of <u>L.b. pifanoi</u> Strain V1.	279
10. The effect of irradiation on the infectivity of <u>L.b. pifanoi</u> Strains V1 and V2.	288

LIST OF FIGURES

	Page	
Fig.1	Photograph of the patient from whom <u>L.b. pifanoi</u> Strain VI was isolated by Dr. J. Convit showing small diffused cutaneous lesions on the ear and face.	33
Figs.2 & 3	The same patient in Fig.1 showing nodular lesions on both legs.	34
Fig.4	Digrams of two types of thermocouple: (a) for measuring deep temperature, and (b) for measuring surface temperature.	54
Fig.5	Thermocouple and thermocouple potentiometer set up for measuring the rectal and skin temperature.	55.
Fig.6	Calibration graph for Constantin Copper thermocouple.	57
Fig.7	Hamster inoculated with <u>Leishmania braziliensis pifanoi</u> VI in the left hind foot, showing metastasis of the infection to the other hind foot and fore limbs.	72
Fig.8	Secondary lesions on the snout and foot pads of the same hamster.	72
Fig.9	Primary lesion of <u>L.b. pifanoi</u> VI on the snout of a hamster inoculated three months previously with a heavy dose of amastigotes.	75
Fig.10	Six months old primary lesion of the snout of a hamster inoculated with a medium dose of <u>L.b. pifanoi</u> .	75
Fig.11	Hamster inoculated with heavy dose of Strain L 15 showing ulceration and encrustation of the primary lesion.	78
Fig.12	Smear from the lesion on the snout of an infected hamster, showing a large number of amastigotes.	81
Fig.13	Stages in the development of lesions of <u>L.b. pifanoi</u> on the snouts of albino mice, showing from right to left: a papule, nodule, ulceration and proliferation with encrustation.	88

		Page
Fig.14	Advanced stage in the development of the primary snout lesion and metastasis to the left hind foot, 14 months after inoculation with a heavy dose of <u>L.b. pifanoi</u> strain V1.	88
Fig.15	Course of infection of <u>L.b. pifanoi</u> V1 in hairles, "shaven" and albino mice.	92
Fig.16	"Shaven" mouse showing satellite lesions around the initial primary lesion on the back.	93
Fig.17	A hairless mouse showing ulceration of the primary lesion on the base of the tail and metastasis of the parasite to all the limbs, snout and eyelids.	94
Fig.18	A "shaven" mouse with an ulcerating primary lesion at the base of the tail and secondary lesions on the tail, feet, ears and snout. Some of the lymph glands are enlarged probably due to secondary bacterial infection of the primary lesion.	94
Fig.19	"Shaven" mouse inoculated intraperitoneally with <u>L.b. pifanoi</u> strain V1, showing ulcerating lesions on the scrotum and nodular lesions on the hind limbs and tail.	99
Fig.20	The same mouse in Fig.19 with diffused nodular lesions on both ears and nose.	99
Fig.21	A hybrid mouse inoculated intraperitoneally with <u>L.b. pifanoi</u> showing lesions on the scrotum, penis and hind feet and tail.	100
Fig.22	A "shaven" mouse inoculated intracardially with <u>L.b. pifanoi</u> showing lesions on the hind feet, skin of the back and base of tail.	103
Fig.23	Frost bite of the tail of albino mice maintained for six months at -15°C .	142
Fig.24	A hybrid mouse (A) showing modular lesion of <u>L.b. pifanoi</u> on the snout. A hybrid mouse (B) inoculated with the same inoculum as A but maintained at 35°C soon after inoculation, showing absence of lesions.	148

- Fig.25 Mice inoculated with similar doses of L.b. pifanoi. Mice 1, 2 and 3 showing small healing lesions following maintenance at 35°-36°C for 3 weeks. Mice 4, 5, 6 and 7 control mice showing well developed lesions following maintenance at room temperature. 152
- Fig.26 Higher magnification of the lesions on the snouts of mice 2, 3, and 6 on the previous photograph. 152
- Fig.27 A hybrid mouse showing diffuse cutaneous leishmaniasis on the tail and hind limbs. 153
- Fig.28 A hybrid mouse with diffuse cutaneous leishmaniasis on the tail and hind limbs after exposure to 35°C for 3 weeks. Marked shrivelling and healing of the lesions is observed. 153
- Fig.29 Effect of environmental temperature on the growth of six month old lesion of cutaneous leishmaniasis in mice. 154
- Fig.30 Mouse (A) showing a decrease in the size and loss of the shiny appearance of the lesion on the snout following exposure to 35°C for 48 hours, compared to mouse (B) untreated control. 155
- Fig.31 Two albino mice inoculated with the same dose of L.b. pifanoi at the same time. Mouse (A) was maintained at room temperature for 3 months, while mouse (B) was exposed to 35°C for 3 weeks and then maintained at room temperature. Mouse B shows smaller healing lesions and signs of hair regeneration on the affected skin. 155
- Fig.32 Smear from a lesion of L.b. pifanoi from a mouse prepared 3 hours after exposing the animal to 36.5°C. Histiocyte is packed with amastigotes. 156
- Fig.33 Smear from the same lesion prepared 12 hours later, showing fewer parasites, some of which appear degenerate. 156
- Fig.34 Smear from the same lesion after 18 hours showing remarkably few parasites. 157
- Fig.35 Smears from the same lesion after 39 hours showing the dramatic disappearance of parasites from the histiocytes. 157

		Page
Fig.36	Section from a lesion of a mouse killed 3 days after exposure to 35°C showing disintegrating parasites in the histiocytes.	159
Fig.37	Higher magnification of the same photograph showing histiocytes.	159
Fig.38	Skin section of a mouse infected with <u>L.b. pifanoi</u> maintained at 35°C for 3 weeks, showing fibroblasts and granular tissue formation with sloughing of the epidermis.	160
Fig.39	The same section under higher magnification showing fibroblasts and granular tissue.	160
Fig.40	Case of post-kala-azar dermal leishmaniasis (after Morgan <u>et al.</u> , 1962).	190
Fig.41	Ethiopian case of diffuse cutaneous leishmaniasis (after Bryceson, 1969).	193
Fig.42	Nodular lesions on the face, caused by <u>L.b. pifanoi</u> (after Convit, 1958).	197
Fig.43	Different stages in the development of lesions of <u>L.b. pifanoi</u> in hamsters.	203
Fig.44	Hamster showing primary lesion on the right hind foot pad and the metastasis of the parasite to both left limbs.	206
Fig.45	Early stage of nodular lesion on snout of mouse.	208
Fig.46	Large nodular lesion on the snout of ("shaven" x albino) mouse six months after inoculation.	208
Fig.47	Nodular lesion of <u>L.b. pifanoi</u> (strain V2) on the snout of ("shaven" x albino) mouse, four months after inoculation.	209
Fig.48	("Shaven" x albino) mouse showing ulcerating primary lesion.	209
Fig.49	Ulceration of the primary lesion at the base of the tail of a "shaven" mouse, six months after inoculation with <u>L.b. pifanoi</u> . The skin of the basal part of the tail has sloughed off.	211

		Page
Fig.50	Ulceration of the primary lesion at the base of the tail of an albino mouse, ten months after inoculation with <u>L.b. pifanoi</u> resulting, in the loss of the tail.	211
Fig.51	Ulcerating "crater" lesion on the snout of an albino mouse inoculated with heavy dose of amastigotes. Compare to mouse on the right inoculated with very low dose.	212
Fig.52	Stages in the ulceration of the primary lesion on the snouts of two albino mice.	212
Fig.53	Warty type of lesion at the base of the tail of a ("shaven" x albino) mouse.	214
Fig.54	Lesion at the base of tail of "shaven" x albino mouse. Note the flat form of the lesion, and the depigmentation of the affected skin.	215
Fig.55	"Shaven" x albino mouse showing metastasis of <u>L.b. pifanoi</u> (strain V1) to all hairless parts of the body, 18 months after infection.	217
Fig.56	"Shaven" x albino mouse showing metastasis of the parasite from the site of inoculation at the base of the tail to the rest of the tail and the hind limbs, 12 months later.	219
Fig.57	"Bead-like" nodular lesions on tails and metastasized lesions on hind limbs of hybrid mice.	219
Fig.58	Secondary lesions on snout and ears of "shaven" mouse inoculated at base of tail.	221
Fig.59	Same mouse as in Fig.58 showing enlarged lymph glands due to secondary bacterial infection.	221
Fig.60	Section of normal skin of albino mouse.	222
Fig.61	An infected macrophage from a smear of a primary lesion of a hamster. Note the clustering of the parasite at the nuclear end of the tail.	228

- Fig.62 Smear from a nodular lesion of a hamster, showing histiocytes packed with amastigotes. Few akinetoplastic free amastigotes may also be seen. 228
- Fig.63 Section of hamster skin showing hyperkeratosis, and slight thickening of the epidermis, destruction of the papillary layer with some breakdown in the clear zone of the sub-papillary region. Note the loose arrangement of the infected histiocytes. 229
- Fig.64 Section of the dermis of hamster showing many very heavily infected histiocytes. 229
- Fig.65 A section of skin of infected hamster showing histiocytic granuloma in the deep dermis, extending upward to the sub-papillary zone and invading the epidermis. Note the formation of the microabscess within the Malpighian layer of the epidermis. 231
- Fig.66 The same section as in Fig.65 with higher magnification showing heavily parasitized histiocytes in the papillary zone, Malpighian layer and in the microabscess. 231
- Fig.67 Parasitized histiocytes amongst the muscle fibres of the deep subdermis of a hamster. 232
- Fig.68 Section through secondary lesion on the ear of a hamster showing histiocytic granuloma in the dermis, and parasite clear cartilage. 235
- Fig.69 Section through the secondary lesion on the foot of a hamster. 236
- Fig.70 Two magnifications of a section through the snout of an infected mouse, showing mononuclear cell infiltration into the deep dermal layer. 238
- Fig.71 Section of infected mouse skin showing histiocytic granuloma in the deep dermis, clear sub-epidermal zone, destruction of the papillary layer and thickening in the Malpighian layer with hyperkeratosis. 239
- Fig.72 A section of skin of a mouse showing the clear subpapillary zone. 241
- Fig.73 The same section showing parasites in the dermal layer of the skin. 241

		Page
Fig.74	Section of skin of snout of a mouse showing intense histiocytic proliferation in the dermis. The blood vessel is surrounded by a clear area.	242
Fig.75	Section through the subdermal muscular layer of a hairless mouse showing massive cellular infiltration and degeneration of the muscle fibres.	243
Fig.76	Higher magnification of Fig.75 showing a large number of amastigotes amongst disintegrating muscle fibres.	243
Fig.77	A section of the epidermis of a "shaven" mouse showing infiltration with a large number of infected histiocytes.	244
Fig.78	Higher magnification of same section.	244
Fig.79	A section through the lesion of the snout of ("shaven" x albino) mouse. Note the acanthosis and moderate hyperkeratosis of the Malpighian layer.	245
Fig.80	Section of skin of the snout showing a dense infiltration of infected histiocytes in the dermis involving the follicles of the sensory bristle, and slight acanthosis of the epidermis.	246
Fig.81	Higher magnification of the basal part of the follicle of the snout bristle in Fig.80 showing many infected histiocytes and some lymphocytes and plasma cells.	246
Fig.82	Section of the dermis of an infected mouse showing parasites in the sebaceous glands.	248
Fig.83	Section of ulcerated lesion of a mouse, showing secondary bacterial infection near the surface of the lesion, isolated from the deeper <u>Leishmania</u> infected zone by an infiltrate of polymorphonuclear cells.	249
Fig.84	Section through a secondary lesion on the foot of a hairless mouse, showing the extension of the parasitized histiocytes between the collagen fibres of the deep dermis.	251
Fig.85	Section through a secondary lesion on the snout of a hairless mouse. Note the vacuolated appearance of the infected histiocytes and their loose arrangement.	251

		Page
Fig.86.	A section through the ear of an albino mouse showing thickening of the epidermis on the infected side of the ear compared to that of the healthy part.	252
Fig.87	The same section at a higher magnification showing the involvement of the clear zone.	252
Fig.88	Section of a secondary lesion on the ear of a hairless mouse showing thickening in the epidermis, histiocytic granuloma in the dermis extending through a break in the ear cartilage to the dermis of the inner surface of the ear.	253
Fig.89	Higher magnification of the break in the cartilage seen in Fig.88 showing infected histiocytes in direct contact with the cartilage matrix; however, neither the cartilage cells nor the neighbouring blood vessel are invaded.	253
Fig.90	Section through the scrotum of an albino mouse showing cellular infiltration into the epididymis. Note the thickening of the scrotum and ulceration along the left margin of the section.	254
Fig.91	Section through the head of the epididymis in Fig.90 showing infiltration with lymphocytes, plasma cells and infected histiocytes.	254
Fig.92	Section through the body of the epididymis in Fig.90 showing cellular infiltration into the interstitial spaces.	255
Fig.93	Section through the skin of the scrotum in Fig.90 showing massive histiocytic infiltration in the dermis.	255
Fig.94	Smear of bone marrow of a mouse showing parasites within a histiocyte.	256
Fig.95	Schematic diagram of a dissected mouse showing the location of the lymph nodes.	259
Fig.96	Section through the lymph node of an infected hybrid mouse showing a few intact germinal follicles and masses of histiocytes in the sinusoidal spaces.	260

		Page
Fig.97	Section through the sciatic lymph node of a hairless mouse, inoculated with <u>L.b. pifanoi</u> at the base of the tail, showing massive destruction of the lymph follicles and their overlapping cellular infiltration.	260
Fig.98	A section of a lymph node from an infected ("shaven" x albino) mouse showing the sinusoidal spaces packed with histiocytes and plasma cells.	261
Fig.99	Section of lymph node at a late stage of infection showing parasitized histiocytes and plasma cells.	261
Fig.100	Stages in the development of irradiated amastigotes in 4N media a) after 4 hours, b) after 8 hours, c) after 24 hours, d) after 7 days.	280
Fig.101	Comparison of the growth of irradiated and non irradiated amastigotes of <u>L.b. pifanoi</u> in 4N media.	281
Fig.102	Different forms of promastigotes of irradiated culture of <u>L.b. pifanoi</u> .	284
Fig.103	Comparison of the growth of irradiated and non irradiated promastigotes of <u>L.b. pifanoi</u> in 4N solution.	285
Fig.104	Smears of promastigotes prepared (a) before, and (b) after irradiation.	286
Map of the World with geographical distribution of Leishmaniasis		179

GENERAL INTRODUCTION

Oriental sore was described as early as 1756 when Russell found the disease endemic in Aleppo, in Syria, and gave an account of it under the name "Aleppo boil". Cunningham (1885) was first to describe the observation of "peculiar parasitic organisms" in sections of Delhi boil fixed in alcohol and stained with gentian violet. He thought macrophages infected with parasites were amoebic and that the organisms within them were spores. Firth (1891) confirmed the observations of Cunningham on the parasite and considered it a sporozoon, he proposed the name "Sporozoa furunculosa, to indicate the peculiar pathological influence of the parasite".

Borovsky (1898) gave an accurate description of the causative agent of oriental sore ("Sart sore"), including the nucleus and rod-shaped kinetoplast. He recognised the parasites as protozoa and differentiated them from the elements of the tissues of the host.

In 1900 Leishman found small oval bodies in the spleen of a soldier who had died of an obscure Indian disease called dum dum fever, but did not publish his observations until 1903. He related these organisms to trypanosomes entitling his paper "The possibility of occurrence of Trypanosomiasis in India". Donovan in the same year independently described the parasite from spleen punctures of patients suffering from dum dum fever. Laveran and Mesnil (1903a, 1904) considered these organisms piroplasms, and suggested the

name Piroplasma donovani. Ross, (1903 a and b) concluded that the organisms were sporozoan and proposed the name Leishmania, so the name of the kala-azar parasite is known as Leishmania donovani (Laveran & Mesnil, 1903) emended Ross, 1903.

Wright (1903) described similar parasites from a case of oriental sore in a child who had been infected in Armenia. He related the organism to microsporidia and suggested the name Helcosoma tropicum. Luhe (1906) adopted the modern name Leishmania tropica (Wright, 1903) for the parasite of the oriental sore.

In South and Central America the disease was described by many authors. Lindenberg (1909) described Leishmania parasites from "ulcera de bauru". In 1911, Splendore found the parasite in one type of "buba brasiliiana" with lesions in the mouth and nose. Vianna (1911) proposed the name Leishmania braziliensis for the parasite of American cutaneous leishmaniasis.

The genus Leishmania consist of flagellates characterised by the possession of two forms:

1. Amastigotes (round, non-flagellate) which are also known as Leishman-Donovan bodies are found in the reticulo endothelial system of the mammalian host where they develop intracellularly, and entirely as amastigote forms.
2. Promastigotes (flagellate forms) found in the mid and anterior parts of the alimentary canal of insect host (sand flies), where they multiply

extracellularly.

The parasites are transmitted by sandflies (Phlebotomus spp.). When infected macrophages in the blood or skin are ingested by a susceptible species of Phlebotomus, the parasite emerges from the macrophage and undergoes further development in the mid-gut of the insect where it develops into promastigote forms by elongating, developing a flagellum, and multiplying by binary fission. In many instances the flagellates extend forward to the pharynx, buccal cavity, and mouth parts of the sandfly; the flagellates eventually block the cavity of the proventriculus, pharynx and proboscis. These flies, when they attempt to ingest blood, dislodge the flagellates which are injected into the vertebrate host. The promastigotes are phagocytosed by macrophages and change to the amastigote forms, which multiply. Infection of other macrophages takes place in this way, the entire reticulo-endothelial system becomes progressively infected.

Classification of Leishmania Parasites

Leishmania parasites of man belong to three species:

1. Leishmania donovani (Laveran and Mesnil, 1903), Ross, 1903, which causes visceral leishmaniasis in India, China, Africa (Central and East Africa) and South America.

Leishmania infantum Nicolle, 1908, the species identified as the causative organism of infantile kala-azar in the Mediterranean

basin and in the Middle East, is a synonym of L. donovani.

2. Leishmania tropica Wright, 1903, causing oriental sore along Mediterranean shores, Middle East, Central Asia, drier parts of Central and Western India and also in many places of Central and North Africa.

The Russian authors specify the causative organism of the oriental sore into two species (Yakimoff 1915).

L. tropica minor, which causes the classical form of oriental sore (urban) and producing "dry" type lesions.

L. tropica major, the causative organism of zoonotic form of oriental sore with much limited distribution (rural) and producing "wet" type lesions.

3. Leishmania braziliensis Vianna, 1911, which produces all types of cutaneous and muco-cutaneous infections in the New World.

Because of the difference in the clinical picture of the disease in South and Central America, as well as the histopathological variations, Pessoa (1961) classified the Latin American species of Leishmania braziliensis into the following subspecies, corresponding to the various types of cutaneous and muco-cutaneous lesions.

- i) Leishmania brasiliensis brasiliensis Vianna, 1911,
(= L. tropica brasiliensis Biagi, 1953), which causes a malignant form of disease (Espundia) with extensive lesions; in over 80 % of cases metastatic invasion of the oronasopharyngeal mucosa occurs.

- ii) Leishmania brasiliensis guyanensis Floch, 1954,
(= L. tropica guyanensis Floch, 1954) causing benign cutaneous lesions; only 5% of cases show metastatic invasion and this is of the nasal mucosa only.
- iii) Leishmania brasiliensis mexicana Biagi, 1953,
(= Leishmania tropica mexicana Biagi, 1953, causing Chiclero's ulcer with ecthymatous lesions on the ears.
- iv) Leishmania brasiliensis peruviana (= L. peruviana Velez, 1913) causing a benign infection (Uta) with dry, papular, rarely eczematous ulceration.
- v) Leishmania brasiliensis pifanoi Medina and Romero, 1959, causing a malignant form with extensive lesions of the tuberculoid type (leishmaniasis lepromatosa brasiliensis diffusa).

In 1962 the taxonomic rank of L. t. mexicana was raised from a subspecies where it was placed by Biagi in 1953 to a species (L. mexicana Biagi, 1953; emend. Garnham, 1962).

Medina & Romero (1962) in the light of further observations and studies on L. b. pifanoi, proposed raising the taxonomic rank of L. b. pifanoi from subspecies to species (L. pifanoi, Medina & Romero, 1962). This has not been accepted by many authors, however.

Diffuse cutaneous leishmaniasis

In 1948 Barrientos reported an unusual form of cutaneous leishmaniasis in Bolivia. This was a leproid or diffuse tegumentary type. In the same year Convit and Lapenta reported similar forms in Venezuela. Several cases were reported subsequently from many parts of South and Central America: Ortiz and Pardo (1949), Medina and Romero (1957, 1959, 1962), Convit (1958), Convit et al. (1957, 1959, 1962), Convit and Kerdel-Vegas (1960, 1965), Deane et al. (1966), Pons et al. (1967), from Venezuela; Malamos (1949), Guimaraes (1954), Portugal and Marques (1960) and Bandieri and Cavalcanti (1965) from Brazil; Shanbrom et al. (1955) from Panama; León (1957) from Ecuador; Martinez et al. (1968) from Mexico; Simpson et al. (1968) from Texas and Padilla and Lainez (1968) from Honduras. The characteristic features of the disease, which resembles lepromatous leprosy, have been studied in great detail by Convit and co-workers (Convit 1958, 1969; Convit et al. 1957, 1959, 1962) and Medina and Romero (1957, 1959, 1962). They described the disease in 16 cases, many of which were followed up for several years. The distinguishing characteristics of diffuse cutaneous leishmaniasis may be summarized as follows:

The clinical picture begins with a localized lesion, which very frequently is a nodule. This spreads locally by the formation of satellite lesions from which the disease disseminates to other parts of the body. As the

disease progresses, it attacks practically the entire skin with the exception of the scalp and inguino-crural region. The satellite lesions may remain discrete or may fuse with the central lesion. The secondary lesions do not ulcerate except perhaps when they occur over a bony protruberance when they become verrucose; they may then occasionally ulcerate following trauma.

The lesions have a distribution on the body similar to that of lepromatous leprosy, spreading to the face, ears, extensor surfaces of limbs, buttocks and occasionally to the trunk and scalp. The lesions extend up to, but only rarely cross, the mucocutaneous junction. Lesions of the nasal mucous membrane remain discrete and, because of light infiltration, never lead to the mutilating destruction of the oropharynx typical of espundia.

The disease is characteristically slow developing, often taking years for any change to be observed. Occasionally, however, it spreads rapidly. The lesions do not heal spontaneously. The viscera and bone marrow never become infected.

Histopathologically the lesions show a thinned epidermis and the dermis is transformed into a histiocytic granulomata packed with amastigotes. There are some plasma cells but few lymphocytes.

In its immunological aspects this condition shows a negative Montenegro reaction. (This is an intradermal test of delayed hypersensitivity to dead promastigotes grown in culture, and it is read 24, 48 and 72 hours after inoculation (Pessoa and Barretto, 1944).) The responses to tuberculin and

lepromin tests are unimpaired.

The absence of demonstrable immune reaction in patients infected with diffuse cutaneous leishmaniasis indicates an anergic response of the host to this particular pathogen. This is shown by the inability of the host to localize the parasite at the site of the primary infection. The fact that the response of these patients to some other antigens, e.g. tuberculin and lepromin, is unimpaired strengthens the evidence for the existence of specific anergy. Circulating antibody has not been detected. The parasite initiates a strong erythematous reaction, similar to the Montenegro reaction, in patients with mucocutaneous lesions (espundia) (Convit and Kerdel-Vegas, 1965).

An unfortunate feature of the disease in Latin America is its failure to respond to leishmanicidal drugs in current use. Administration of antimonial drugs achieves only a temporary improvement which is followed by relapse.

Aims of the Present Work

Leishmania brasiliensis pifanoi causes a serious disfiguring, mutilating disease which produces great physical as well as psychological suffering to patients. Although human cases have been studied for many years there are still many gaps in our understanding of the nature of the parasite and its behaviour. The use of human volunteers for studies on the course of the disease is unjustifiable. The few human beings accidentally or deliberately inoculated with L. b. pifanoi were promptly treated before the disease ran its full normal course (Convit, 1958; Convit and Kerdel-Vegas, 1965).

The study of the course of the disease in experimental animals provides an invaluable tool in furthering our understanding of the parasite and therefore our ability to cope with human infection.

In the present investigation attempts were made to gain some information on the infectivity and pathogenicity of L. b. pifanoi to laboratory animals, and to examine some of the factors influencing the immune response of the host to the parasite.

The thesis falls into the following parts:

Part I

This deals with the more routine techniques adopted throughout the work, such as the preparation of media, maintenance of strains of parasites, histological techniques, etc.

Part II

This is devoted to studies on the infectivity of L.b. pifanoi to laboratory animals. The experiments were designed to show:

- a) The susceptibility of different laboratory animals to diffuse cutaneous leishmaniasis.
- b) The effect of the dose and the source of inoculated parasites on the course of experimental infection.
- c) The influence of the route and site of inoculation on the course of the disease.

Part III

This deals with the effect of the environmental temperature on the course of experimental cutaneous leishmaniasis. This part of the work was carried out because Leishmania brasiliensis pifanoi infection does not visceralize; behaviour similar to that of L. enriettii in guinea pigs which was explained by Pereira^{et al.} (1958) as being due to the higher temperature of the viscera; also, because of the known preference of dermal species of Leishmania for cooler parts of the body of the host.

The problem was tackled by:-

- a) Maintaining newly inoculated mice at different environmental temperatures.
- b) Exposing animals with established lesions to different temperatures to observe the effect on the course of the disease.

Part IV

This part is devoted to studies on the gross and histopathological aspects of diffuse leishmaniasis in laboratory animals.

Part V

This describes attempts to immunize laboratory animals against diffuse leishmaniasis by inoculation with L. b. pifanoi which had been exposed to different doses of gamma-irradiation.

PART I - GENERAL MATERIALS AND METHOD

Parasites

The following materials were studied:

Strain VI*

This strain was isolated in 1963 by Dr. J. Convit from a typical case of diffuse cutaneous leishmaniasis (Figs. 1, 2, & 3) in Venezuela. The organism had been passaged nine times in hamsters when it was received by the author in August, 1967. It was subsequently maintained in hamsters and mice. Cultures were kept in the dark at room temperature (22-25°C). The parasites were subcultured in 4N medium once every 2-3 weeks.

Strain V2*

This strain was isolated in 1965 by Dr. R. Medina from a Venezuelan case of diffuse cutaneous leishmaniasis.

The parasite had been maintained in culture and in hamsters until the author received a culture in July, 1968. Since then, it has been passaged in hamsters and mice.

Strain L 15

This strain was originally isolated by Dr. R.S. Bray in August 1963 from a Brazilian patient who had suffered from leishmaniasis tegumentaria

* Strains V1 and V2 were so named by the present author.

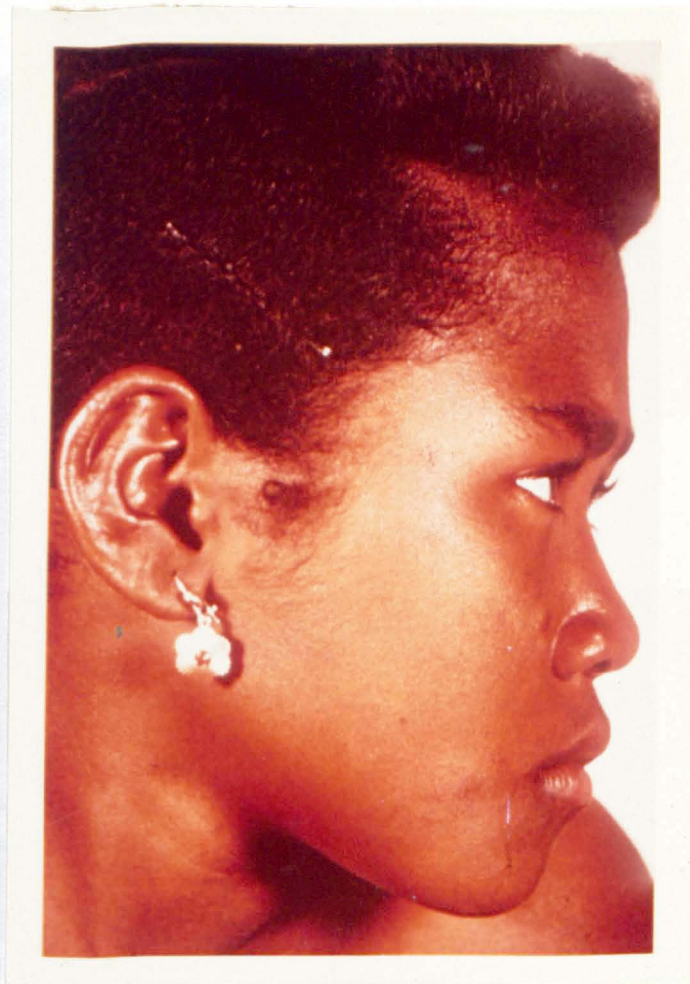

Fig.1 Photograph of the patient from whom L. b. pifanoi Strain V1 was isolated by Dr. J. Convit showing small diffused cutaneous lesions on the ear and face.

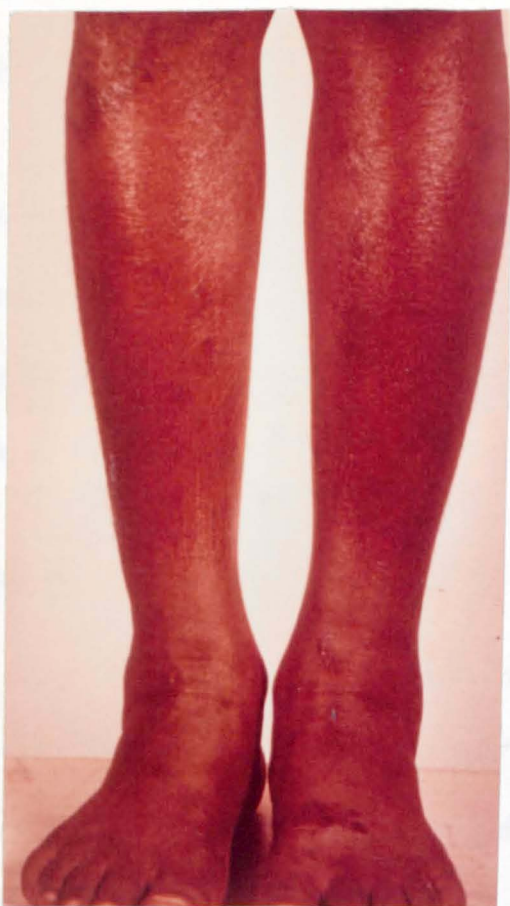

Fig.2

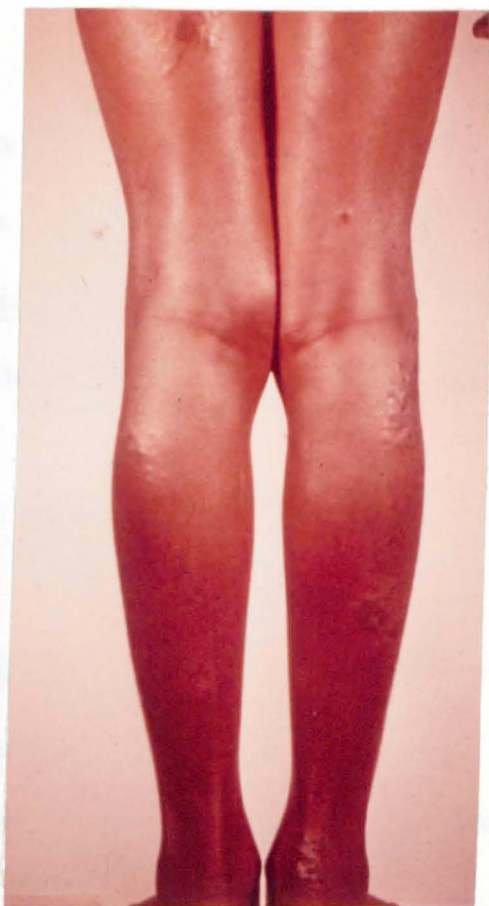

Fig.3

Figs. 2 & 3. The same patient in Fig. 1 showing nodular lesions on both legs.

diffusa for 24 years. The strain was maintained in hamsters, in 4N culture medium and by storage at -196°C .

Mexicana

Strain L 11

This strain was recovered from Mrs. A.P. Lainson in London in May 1962 following an infection with a strain originally isolated by R. Lainson in 1962 from a wild rodent (Nyctomus gumichrasti). The strain is sometimes referred to as "Lainson strain". It was maintained in hamsters, mice and 4N culture medium or stored at -196°C .

Preparation of Culture Medium

4N nutrient agar blood medium (Baker, 1966), which is a modification of a medium first described by Novy and McNeil (1904), was used throughout the work, to check visceral infections and for preparations of inocula. Aseptic procedures were followed.

The medium was prepared as follows:

Solid phase

10 gm. of Oxoid No.2 nutrient agar.

250 ml. distilled water.

The above ingredients were put into 500 ml. conical flask which was stoppered with cotton wool and left on the bench for 15 minutes. It was then autoclaved for 20 minutes at 121°C . 20 ml. of rabbit blood, obtained by

means of cardiac puncture, were transferred to a flask containing a few glass beads and defibrinated by agitating for about 5 minutes until the beads no longer rolled around freely. The blood was then added to the flask containing nutrient agar at 50°C and then the mixture was distributed in 2 ml. quantities into 5 ml. screw cap Bijou bottles or in 5 ml. quantities in 20 ml. screw cap Macartney bottles. The bottles were "sloped" so that the molten blood agar spread to a depth of 2 cm. up one side of each bottle and left undisturbed until the agar set.

Liquid phase

Hanks's solution was used as overlay. It was obtained from Oxoid and it was prepared according to the manufacturers' instructions, autoclaved for 15 minutes and left to cool. Using a pH meter the pH was adjusted to 7.2 by addition of 2.5 ml of ^{4%} sodium bicarbonate to 100 ml. of the stock solution. Penicillin G and Streptomycin sulphate were added, each to a concentration of 200 units/ml.

An overlay of 1 ml. for small bottles and 2 ml. for the larger ones was used. The completed bottles were incubated at 37°C for 24 hours to check their sterility. Any contaminated bottles were discarded while the sterile bottles were stored at 4°C until required.

Inoculated cultures were incubated at room temperature and were examined after 7, 14, and 21 days for the presence of promastigotes. The cultures were considered negative when they failed to reveal parasites after

3 successive weeks.

Experimental Animals

Mice

Five strains of mice were used.

Hairless mice (hr hr)

"Shaven" mice (sha sha)

These two strains were obtained from Dr. D. Walliker, Institute of Genetics, Edinburgh, and the "shaven" mice were successfully bred in the animal house. They were fostered by lactating female albino mice as their own mothers were not successful in suckling them.

Albino mice (TO Swiss)

Hybrid (Albino x "shaven") This was bred in the animal house.

The offspring are usually hairy with dark fur.

Mice - Strain C57. Black mice.

The animals were fed on standard mouse cubes and the "shaven" and hairless were also given sunflower seeds.

For most experiments, the mice weighed 15 - 25 gms. (3 - 4 weeks old), but baby mice, 1 - 3 days old, were also used.

Hamsters

Golden hamsters 4 - 6 weeks old weighing 40 - 50 gms. were usually used. They were kept in separate cages or in groups of four.

Albino rats (Wistar)

6 - 8 weeks old rats were used. Baby rats, 1 - 3 days old, were also used.

The adult rats were obtained from Tuck & Son; the baby rats were bred in the animal house.

Guinea pigs (Duncan & Hartler)

Animals aged 6 - 8 weeks and also 1 - 7 days were used.

Rabbits

Rabbits were used for obtaining blood for media preparation. The animals were kept in separate cages. They were bled once a month, taking 20 - 30 ml. of blood.

Anaesthetics

The choice of anaesthetic was governed by the duration of anaesthesia required. For operations of a few minutes inhalation of ether was used. For longer periods of anaesthesia intraperitoneal inoculation with the anaesthetic was preferred.

Inhalation method

For anaesthetizing small animals a piece of cotton wool was soaked in ether and put in the bottom of a glass jar and covered. The animal was put in this jar and watched until it was narcotized and laid flat with hurried

respiration. The animal was then removed, held on the dissecting board and kept in its deep anaesthesia using a mask consisting of a small piece of cotton wool and soaked in ether in a small bottle.

Injection method

- (i) Pentobarbiturate (Nembutal) was used for anaesthetizing mice for spleen biopsy and splenectomy as well as for heart puncturing. An intraperitoneal dose of 60 mg./kg. body weight was used and this produced surgical anaesthesia of 20 - 30 minutes' duration.
- (ii) Avertin with Amylene Hydrate Bayer $C_2H_3Br_3O$ (Tribromoethanol).

It was used in mice in the following solution:

0.5 ml. Avertin with Amylene Hydrate

2.0 ml. absolute alcohol

25 ml. Sterile normal saline solution

The reagents were mixed thoroughly in 50 ml. screw cap bottles, and 0.01 ml. of the mixture per gm. of body weight was given intraperitoneally. Atropine Sulphate 0.1 ml. of 0.25% solution per 3 week old mouse intraperitoneally was used to cut down the secretions and to reduce convulsion. This gave surgical anaesthesia for 30 - 40 minutes without a mortality risk.

Preparation of Parasites for Inoculation

The inocula used were prepared in two ways:

Amastigotes

These were obtained from infected hamsters or mice. Metastatic nodules on a foot, which were clean and had not ulcerated, were usually chosen because of their freedom from secondary bacterial infection. The lesion was removed by amputating the infected foot after anaesthetizing the animals with ether or Avertin (Bayer). The stump was cauterized with a hot scalpel.

The removed, infected foot was ground in a sterile tissue grinder with 5 - 10 ml. of Hanks's solution.

The suspension was transferred to centrifuge tubes and centrifuged for one minute at 50 g. Coarse tissue particles were sedimented. The supernatant, which contained a large number of amastigotes, was then transferred to a sterile Bijou bottle and kept at 4°C ready for inoculation after serial dilution.

The parasite density in the inoculum was estimated by taking 0.01 ml. of the suspension and spreading it over an area of one square centimeter, on a microscope slide. 100 microscopic fields were counted to give an estimate of the intensity of the parasites in the inoculum. A X100 oil immersion objective and X10 eye pieces were used. The counts were scored as follows:

1. Inocula with more than 100 parasites per microscopic field was classed as "very heavy".

2. Inocula with 25 - 100 parasites was considered "heavy".
3. Inocula with 15 - 25 parasites per microscopic field was classed as "medium".
4. Inocula with 5 - 15 parasites per microscopic field were classed as "low".
5. Inocula with 1 - 5 parasites per five microscopic fields was referred to as "very low".

Some inocula were diluted further for quantitative comparative studies.

The estimates of actual numbers of parasites/ml. made by using a haemocytometer and staining the parasites with vital stains, were unsatisfactory. It was very difficult to differentiate between the actual parasite and other cell debris by phase contrast microscopy.

Stauber's (1955) method for estimating the number of the amastigotes in a homogenized suspension of infected tissue was also tried. 0.005 ml. of 0.01 ml. was taken up in a micropipette and expressed on a slide as evenly as possible over an approximately square area of 12 - 15 mm. (about 80 oil immersion microscopic field). These slides were thoroughly air dried, fixed in absolute methyl alcohol and stained with Geimsa. Three horizontal and three vertical bands, one field wide, across the stained homogenate were examined and both the number of microscopic field and the number of parasites were counted. From these counts, estimates of the total number can be related.

The number of amastigotes estimated per microscopic field area by this method again does not give the actual number of the parasites inoculated.

Promastigotes

Promastigotes were used for infecting animals with known numbers of parasites. The promastigotes were harvested from the second subculture of material from lesions, in 4N medium, incubated at room temperature for 7-10 days. They were counted in a haemocytometer chamber as follows:

The supernatant of the culture was removed and was diluted 1 in 10 with sterile buffered saline (pH 7.2), and centrifuged for 10 minutes at 2500 g. The supernatant was removed and Hanks's solution was added to the sediment. This was mixed thoroughly by shaking with glass beads for about 5 minutes to resuspend the promastigotes.

Samples from the suspension were taken and diluted with phosphate buffered saline containing either 0.002% neutral red dye (1 mg/50 cc.) (Lemma and Schiller, 1964) or 0.001% gentian violet in order to stain the promastigotes and inhibit their activity.

The dilution was made in a white blood cell pipette which was shaken thoroughly for two to three minutes. An Improved Neubauer counting chamber was then flooded in the standard manner used for making blood counts. The white blood counting area was used for counting the organisms, using a light microscope X 40 objective lens and X 6 ocular lense. When the population of

the parasites in the culture was low, they were counted without dilution. This was done by spreading a drop of the stain on a clean slide and allowing it to dry in the air. A few drops of promastigote suspension were mixed on the slide for a few minutes and the number of parasites was then counted as mentioned before.

Routes of Inoculation

The animals were inoculated with either promastigotes or amastigotes by the following routes:

Intradermal inoculation

A small volume of inoculum was injected into the skin by using a fine needle (10.4 x 0.47 mm.). The preferred sites for this type of inoculation were the base of the tail and the snout. The animals were put under general anaesthesia, and the site of injection was shaved and then swabbed with methyl alcohol. The skin was stretched and the needle was pushed into it gently, parallel to the skin surface for 0.5 - 1 mm. 0.01 - 0.05 ml. was injected. A small button-shaped swelling at the site of inoculation was formed. This disappeared after 10 - 20 minutes.

Subcutaneous inoculation

This was done without anaesthetizing the animal. The animals were inoculated in the snout, at the base of the tail, and into the tail and foot pad,

using 16.8 x 0.52 mm. needles. A bulge formed when the volume of inoculum was large. When mice were inoculated subcutaneously at the base of the tail a vein was sometimes ruptured and the parasites were then inoculated intravenously as well as subcutaneously.

Intravenous inoculation

This was made through the tail vein of mice by restraining the animal in a small wire basket and pulling its tail through the mesh of the basket. The tail was held at its base and was rinsed in water at 45 - 50°C for ½ to 1 minute. The vein became swollen and was easily punctured with a needle, 10.4 x 0.47mm. The inoculations were made slowly to avoid the death of the animals through shock. The flow of the inoculum could be seen in the vein by releasing the thumb pressure from the tail base. Rupture of the vein occasionally led to subcutaneous inoculation.

Intracardiac inoculation

Animals were inoculated intracardially under general anaesthesia, using either ether or Avertin (Bayer). The animal was held on its back on a dissecting board by adhesive plaster. The hair of the left side of the chest was shaved and cleaned with methyl alcohol. The heart was palpated between the third and fourth ribs. A needle (16.8 x 0.52 mm.) attached to a syringe was introduced through the chest wall and into the heart. The heart beat was felt when the needle was in the heart. Some blood was drawn into the syringe

to confirm the position of the needle in the heart. The inoculum was then given very slowly, avoiding the introduction of air. Cardiac puncture was performed in the same way when collecting blood for media making and for serum.

Intrasplenic inoculation

Intrasplenic inoculations were made by laparotomy. The animals were anaesthetized either with ether (hamsters) or Avertin (mice) and were fixed on the dissecting board with adhesive plaster. The left side of the abdomen was shaved and then swabbed with methyl alcohol. Using sterile scissors, a longitudinal incision was made on the left side 1 cm. below the lower costal margin. All the abdominal wall layers were cut and the peritoneal cavity was opened. The stomach was pushed aside and, on its left side, the spleen could be seen. The spleen was held gently with flat, blunt forceps and was pulled slightly out of the abdomen. An injection of not more than 0.05 ml. was made on one side of the spleen using a 10.4 x 0.47 mm. needle. The spleen was then returned to the abdomen and the peritoneum, muscle layers and skin were stitched together by continuous stitches. The wound healed within one week in the absence of infection.

Intraperitoneal inoculation

Animals were inoculated intraperitoneally without anaesthesia. The animals were held in the left hand with the head downward. The inoculation

was made with 16.8 x 0.52 mm. needle in the lower part of the abdomen.

Intratesticular inoculation

This was usually done under anaesthesia. The animal was held supine on the bench and the testicles were firmly grasped after stretching the scrotum. A 16.8 x 0.52 mm. needle was used after swabbing the site of injection with methyl alcohol.

Intrauterine inoculation

Mice which were 18 days pregnant were anaesthetized with Avertin and the lower part of the abdomen was shaved. The method used in inoculating embryos with material through the uterine wall of the mother was that described by Pautrizel et al. (1960).

The uterus was exposed by laparotomy of the anaesthetized mother; the embryos, which were visible through the transparent uterine wall, were then inoculated with 0.05 ml. of suspension using 16.8 x 0.52 mm. needle. The wound was then closed and the animal was injected with 10,000 I.U. of antibiotic (Penicillin) intramuscularly.

Smear Preparations and Staining Technique

Smears from the lesions of infected animals were prepared by aspiration of the nodule margin using a sterile dry micro-Pasteur pipette. The aspirated fluid (which is usually creamy in colour) was smeared thinly on a

clean slide. The smears were dried by waving the slide in the air and were then fixed with methyl alcohol for $\frac{1}{2}$ - 1 minute.

Impression smears were prepared from tissues of dead animals by removing a nodule or lesion and touching its cut surface gently to a clean slide. Smears from the lymph nodes were made in a similar way. To prepare impression smears from liver, spleen, kidney, lung and heart, the cut surface of the organ was pressed gently onto clean filter paper to remove any exuding blood and then the dried surface was pressed against clean slides.

Smears were either dry-fixed with methyl alcohol or wet-fixed with Bouin's for 20 minutes and washed with 70% alcohol containing a few drops of saturated aqueous lithium carbonate until the yellow coloration was removed. They were rinsed quickly in tap water and stained in Giemsa's stain. Osmium tetroxide vapour was also used for wet fixation. The smears were exposed to the vapour for 10 seconds, rinsed in methyl alcohol and washed in tap water to remove any remaining acid. For routine examinations, smears were fixed in methanol and stained with Giemsa's stain for 35 minutes. One ml. of stain in 15 ml. of buffered distilled water, at pH 7.2 (prepared by adding 3.0 g. anhydrous Na_2HPO_4 and 0.6 g. anhydrous KH_2PO_4 to each litre of distilled water) was used. Smears were rinsed quickly in tap water and allowed to dry in upright position.

Collection, fixation and staining of tissues

Infected tissues were collected by biopsy from anaesthetized animals or from sacrificed animals during routine autopsy.

Small lesions were removed whole, by biopsy. Large lesions were studied histologically after killing the animal. Small pieces of lesions comprising both layers of the skin and occasionally deeper parts of the subdermal muscles were fixed for a histological study of the pattern of distribution of the parasite in the dermis as well as the infiltration into underlying tissues.

The removal of early lesions from sparsely furred areas, e.g. snout, was preceded by the shaving of the skin to facilitate sectioning.

Diffuse lesions on the foot-pads and the tail were studied by the amputation of the infected part from live or dead animals. Live animals were deeply anaesthetized with Avertin (Bayer) or ether. The healthy skin of the infected limb, just above the lesion, was stretched away from the distal end of the leg, and the limb ligatured with surgical thread at that point. A sharp, sterile scalpel was used to cut off the affected part of the limb. The uneven cut surface of the stump was trimmed and the wound cauterized with a very hot spatula. The ligature was then removed, the loose skin pulled over the stump and sutured. Recovery from this surgical operation was uneventful.

The amputated foot was fixed, and the bone removed before processing for histological sectioning.

Smears of bone marrow were prepared from the larger bones, mainly from the femur. The bone was dissected out and held at one end with a pair of forceps while the other end was sawn off. A dissecting needle was used to split the bone open and to scrape out the small amount of bone marrow which was smeared on slides, dried in air, fixed in methanol alcohol and stained with Giemsa's stain.

The following histological procedures were used routinely for the preparation of sections:

Fixation

Small pieces of infected tissue were fixed in one of the following solutions:

1. 10% formal-saline:

The tissues were fixed in this fixative for one to two days and then transferred to 70% alcohol.

2. Bouin's fluid:

The tissues were fixed for 24 hours and transferred to 2 - 3 changes of 70% alcohol until the yellow picric acid had disappeared, before processing for embedding.

3. Carnoy's fluid:

glacial acetic acid	10 ml.
absolute ethyl alcohol	60 ml.
chloroform	30 ml.

The tissues were fixed for 3 to 4 hours and washed in two changes of absolute alcohol, followed by two changes of 90% alcohol (45 minutes each) before storing in 70% alcohol.

Processing

A Histo-kinette machine was used for the processing of the large amount of material in a short time. The tissues were placed in the cassettes and mechanically transferred to 90% alcohol for two hours, absolute alcohol for two hours, clove oil for 12 hours, xylene for two hours, then infiltrated with molten paraffin wax for 3 hours and embedded in fresh paraffin wax.

Preparing sections

The blocks were trimmed and the embedded skin was orientated so that vertical sections, showing all the layers of the skin, could be cut. Sections were cut at 3 to 5 μ . and mounted on slides in 1 : 1 egg-albumin and glycerine solution diluted forty times in water.

Considerable difficulty was encountered in cutting sections of the skin, with frequent cooling of the block and sharpening of the microtome knife, thus making the procedure very time-consuming.

Staining methods

One of the following staining methods was used to stain the sections:

1. Haematoxylin and eosin

2. Heidenhain's iron haematoxylin
3. Giemsa-colophonium (after Bray and Garnham, 1962)
4. Feulgen reagent
5. Picro-Ponceau with haematoxylin (after Gurr, 1956) for the detection and staining of collagen fibres
6. Pyronin-methyl green for the staining of nucleic acids (after Kurnik, 1955)
7. Sudan III for the detection of lipids. Frozen sections (10 - 15 $\mu\text{m}.$) were cut for this staining method.

Measurement of the temperature of different parts of the body of mice

Measurement of the rectal temperature

a) Using a mercury thermometer:

A thermometer with a long, fine bulb was used to measure the rectal temperature of mice. The type of thermometer used differed from the medical mercury thermometer in that the thread of mercury did not become detached from the contents of the bulb while recording the maximum temperature attained, but remained free to fluctuate throughout the time taken to record the temperature. It was thus possible to observe the slight rise as well as fall of temperature during this period. The thermometer was designed to read temperatures between 32° and 45°C.

To record the rectal temperature of a mouse, the animal was held gently but firmly on its back in the left hand, while the bulb of the thermometer, coated with petroleum jelly, was inserted into the rectum, and after half to one minute the temperature was read.

The use of a mercury thermometer had the following disadvantages:

- (i) Most of the animals reacted to the insertion of the thermometer into the rectum by struggling to get free. Apart from making it difficult to take the reading accurately, this extra activity due to stress, caused the temperature of the mouse to rise above the normal body temperature.
- (ii) Since glass is a poor conductor of heat, the thermometer had to be left for at least half a minute to reach the temperature of its surroundings, and record it accurately, by which time the temperature had risen due to the violent struggling of the mouse.

b) Using a thermocouple:

When two dissimilar metals are joined together to form a closed loop, and the two junctions are held at different temperatures, an electric current flows through the loop. This can be detected by using an ammeter. This phenomenon, which was first observed by Seebeck in 1825, is used for measuring temperatures by measuring the voltage between the junctions of two metals, the thermoelectrical properties of which are known.

The thermocouple was prepared and used in the following way:

1) Preparing the thermocouple:

The external ends of twin thermocouple flex, consisting of insulated copper and constantin wires, were exposed and soldered at T, as shown in Fig.4. A short length of the flex behind the exposed tip was enclosed within a plastic tube, PT. This facilitated the handling of the thermocouple. The rim of this tube (R), about one centimetre from the exposed end of the wires, also served to control to keep constant the depth to which the needle could be inserted into the recta of the animals examined.

The free ends of the flex were soldered separately to the naked tips of two short lengths of copper flex (CF). The junctions were dipped in nail varnish and wrapped in water-proof insulating tape. These ends of the flex were fixed with adhesive tape around an aluminium rod A. This lent a stiffness to the flex. The free ends of the copper flex B and C were connected to a potentiometer (see Figs. 4 and 5).

2) Calibration of the thermocouple:

The ends of the flex, soldered to the copper wire, were stood in crushed ice in a thermos flask to maintain them at a temperature of 0°C . The thermocouple was fixed with adhesive tape to the bulb of a standardized thermometer. The thermometer with the attached thermocouple was immersed in a water bath, and the temperature of the water recorded. At the same time the reading

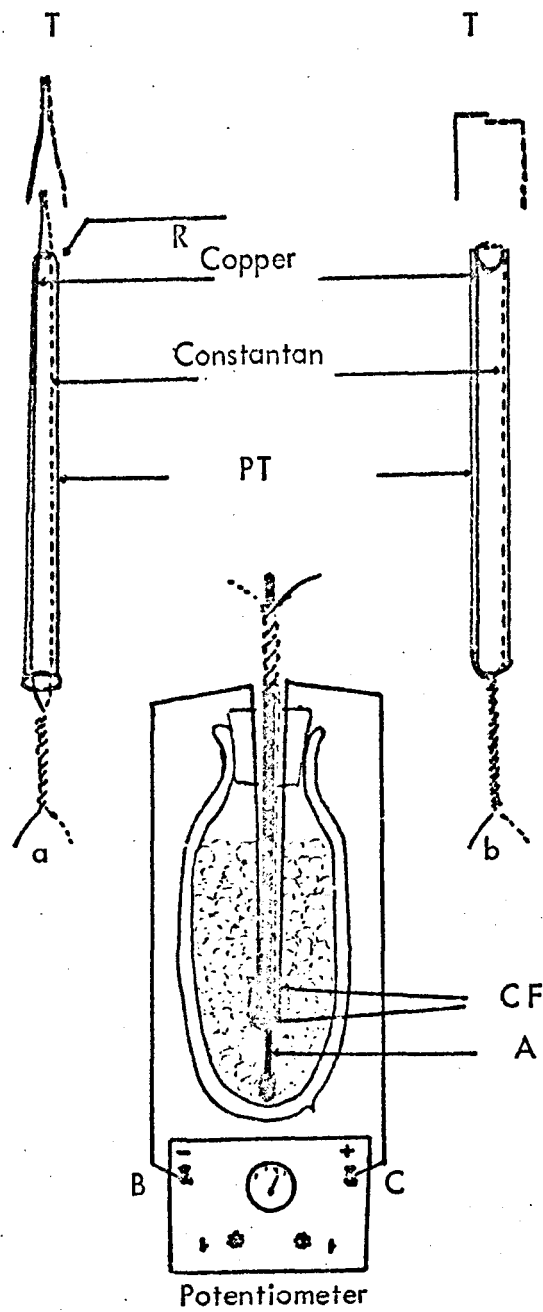


Fig.4 Diagrams of two types of thermocouple
 (a) For measuring deep temperature, and
 (b) For measuring surface temperature



Fig.5 Thermocouple and thermocouple potentiometer set up for measuring the rectal and skin temperature.

of the potentiometer was also registered. Next, the temperature of the water in the bath was altered by adding cold water and stirring for a minute. The new temperature and reading of the potentiometer was again recorded. The process was repeated several times. From these readings a graph of the changes in temperature in $^{\circ}\text{C}$ and the corresponding changes in voltage measured in milli volts (m.v.) was plotted (see Fig.6).

3) Use of the thermocouple:

The needle was inserted 1 cm. into the rectum, spleen, peritoneal cavity (or any other part, the temperature of which was to be measured), while the other was kept in ice. Readings were taken within seconds, which ensured an accurate measurement of the temperature without distress to the animals.

For the measurement of the temperature of different parts of the skin of mice, another thermocouple was used (Fig.4b). This was made by soldering the overlapping ends of the flex. The rest of the procedure and the calibration was the same as described above.

For measurement of the surface temperature of the skin, the thermocouple was touched gently to the skin. Pressure was not applied to avoid interfering with the free circulation of blood supply to the skin.

Before measurement of internal body temperature, the mice were killed either by a blow on the head or by dislocation of the neck. To dislocate

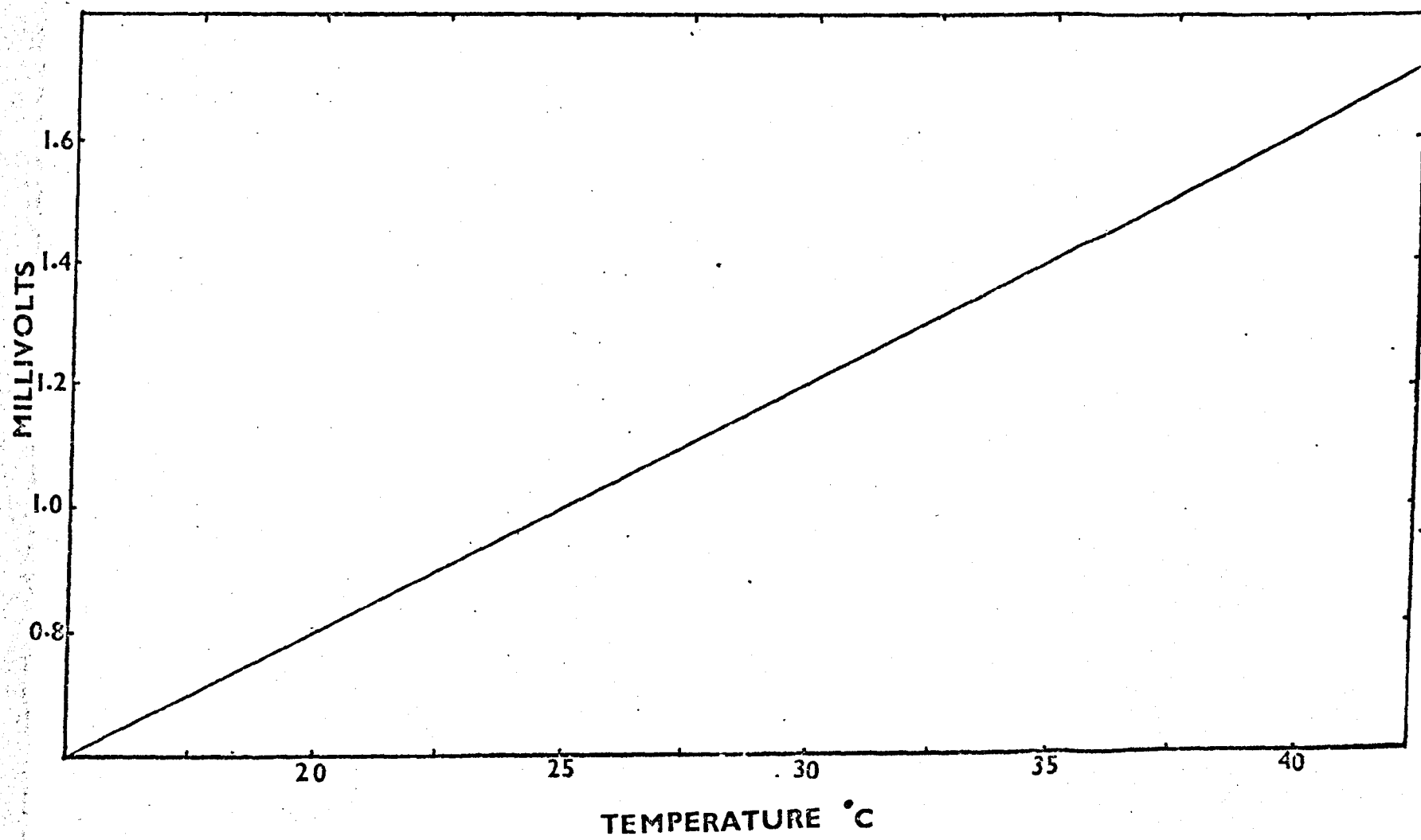


Fig.6 Calibration graph for Constantan-Copper thermocouple.

the neck forceps were placed across the back of the neck and the body of the animal was pulled by the tail up and away from the neck. This was the method preferred, as death was instantaneous.

PART II - THE INFECTIVITY OF LEISHMANIA BRAZILIENSIS PIFANOI

TO LABORATORY ANIMALS

Review of the relevant literature

a) Experimental leishmaniasis of mice:

L. tropica

Nicolle and his co-workers (Nicolle, 1908^{b,c}; Nicolle and Comte, 1909; Nicolle and Manceaux, 1910) were first to study experimental leishmanial infections in animals. They showed that oriental sore or kala-azar could be produced in man, monkeys and dogs by the intradermal inoculation of parasites from infected tissues or from young cultures.

Laveran (1912, 1914, 1915, 1917) infected mice with Leishmania tropica by inoculating them with promastigotes from old cultures via the subcutaneous, the intraperitoneal and the intravenous routes. Intraperitoneal and intravenous inoculation resulted in generalized infection without the appearance of local lesions. Four months after intraperitoneal inoculation the testes of the experimentally infected animals became greatly enlarged. Smears from these organs revealed large numbers of amastigotes. The spleen, liver and bone marrow of these animals were free of parasites. Amastigotes were, however, found in these tissues six months after inoculation.

Row, in 1912, 1914^a, found that intraperitoneal inoculation of mice

with cultures of L. tropica resulted in the appearance of parasites in the liver, spleen and bone marrow after nine months. The same author in 1924 found that mice are also susceptible to intraperitoneal inoculation with L. donovani. Mice infected by this route always developed generalized infection, while those inoculated subcutaneously developed localized or generalized infections.

In 1913 Gonder carried out a series of experiments on the infection of mice by intraperitoneal and intravenous inoculation with L. tropica and L. infantum from cultures. Generalized infections were produced in the liver and spleen one month after inoculation. In all infected mice, parasites occurred only in the liver and spleen and were always absent from the bone-marrow. Mice showing enlarged livers and spleens appeared otherwise healthy and unaffected by the infection. Two mice inoculated intraperitoneally with L. tropica became ill and died four months after inoculation. Numerous parasites were found in the greatly enlarged livers and spleens. Parasites were found in smears of spleens and livers of infected mice which had not shown splenomegaly or hepatomegaly. Four months after intraperitoneal inoculation, four of the mice developed oedematous swellings of the feet. Puncture of these produced a clear serous fluid, which was practically a pure culture of L. tropica. Similar lesions later developed on the ears, tail and lower jaws. Two of these mice had a large number of parasites in the liver and spleen, until the peripheral lesions appeared, whereupon the parasites in the liver and spleen became very

scanty. Another mouse has extensive ulcerations of the paws, tail and ears, and revealed parasites in the liver. The fourth mouse, also with extensive peripheral lesions, showed enlarged liver and spleen which contained numerous parasites.

Sergent (1915) and Pavoni (1915) also produced generalized infections in mice by intravenous and intraperitoneal inoculation with L. tropica. Parrot and Donatien (1927) infected albino mice with L. tropica culture forms. This resulted in the appearance of nodular and ulcerated lesions on the skin of the tail.

Adler and Theodor (1930) found that strains of L. tropica varied in their ability to infect white mice. Some human and canine strains, intraperitoneal inoculations produced generalized infection. In 1930 Das Gupta noticed differences in the course of infection of L. donovani from post kala-azar dermal leishmanoid and L. tropica when they were inoculated intraperitoneally into mice. Although both produced visceral infections, L. tropica gave rise in addition to nodular lesions in the skin.

Kojevenkov (1941) experimentally infected 500 mice with L. tropica from dry and wet types of sores by intradermal inoculation at the base of the tail or the ears. They found that mice rarely became infected when inoculated with the dry type while 100% infection resulted from inoculation with the moist type.

L. mexicana

Garnham and Lewis (1959) inoculated albino mice with promastigotes of L. mexicana at the base of the tail. One month later the skin showed roughening without ulceration, and fairly numerous parasites were found in scrapings of the area. Subinoculation of amastigotes in normal saline, into further mice, gave similar results. When the suspension was inoculated subcutaneously or intrasplenically, infection resulted; however, intraperitoneal inoculation was not successful. Strangways-Dixon and Lainson (1962) succeeded in infecting mice with L. mexicana by intradermal inoculation.

Coelho and Coutinho-Abath (1965) studied the course of infection with L. mexicana in albino mice. They observed local lesions, with a very large number of parasites in mice inoculated subcutaneously. The typical lesion following subcutaneous inoculation was of the nodular tumoural type not involving the epidermis. For the first three months the disease was restricted to the site of inoculation. In the following months metastatic foci appeared at the extremities. Visceralization was only rarely observed in mice.

Mata et al. (1968) found 93% of albino mice subcutaneously inoculated with L. mexicana developed infection, while 94% of mice inoculated intraperitoneally with the same parasite became infected. 85% of the animals infected by either route eventually showed visceral infection. All infected animals showed extensive and heavily infected skin lesions regardless of the route of inoculation.

L. enriettii

This species of Leishmania is usually specific to guinea pigs, adult mice not being susceptible. Adler and Halff (1955) produced a transient infection in suckling mice by inoculation subcutaneously with promastigotes and amastigotes. They were able to detect the parasite by culture in the mice up to the 25th day after inoculation.

L. braziliensis

In 1913 Wenyon isolated a strain of Leishmania, probably L. b. braziliensis, from a patient who had become infected with the parasite in South America. Intraperitoneal inoculation of mice with amastigotes from the sore or promastigotes from a rich culture did not result in infection.

Da Fonesca (1929) inoculated 46 mice into the vagino-peritoneal recess with promastigotes obtained within eleven days of the first subculture of a strain of L. b. braziliensis. Only one animal became infected and this animal died 70 days later with parasites detected in smears from the liver.

Guimaraes (1951c) studied the course of infection of 5 strains of L. b. braziliensis in mice. He was successful in infecting mice with amastigotes of four of the five strains. All resulted in visceral infection. Mice inoculated with culture forms of the parasite failed to develop infection. He also (Guimaraes 1951e) inoculated subcutaneously into mice a strain of L. b. braziliensis from a case of cutaneous leishmaniasis from Amazonia; lesions were produced at the site of inoculation, with parasitic invasion of the testes, vagina, lymph nodes,

and with a few parasites in the liver and spleen. Intraperitoneal inoculation of the mice with the same strain gave similar infection.

L. b. pifanoi

Limited studies on the course of experimental diffuse cutaneous leishmaniasis in laboratory animals were carried out in South America. Mayer et al. (1949) infected mice with parasites from a nodule isolated from a human case of diffuse cutaneous leishmaniasis. Nodules developed in 2 to 3 months without ulceration, and abundant parasites were seen in smears prepared from the nodules. Subinoculation of animals with material from these nodules produced similar results.

Convit (1958) inoculated albino mice with a suspension of amastigotes of L. braziliensis pifanoi prepared by grinding tissue from a nodule from a human case of diffuse leishmaniasis. Local nodules appeared at the site of inoculation 3 weeks to 3 months later. Smears prepared from these lesions were very rich in parasites.

Medina and Romero (1959) infected albino mice with a strain of L. b. pifanoi by intradermal inoculation only. They obtained 100% infection in mice, with an incubation period of 2 to 4 months.

In 1961, Ercoli infected 60 mice with a suspension of amastigotes obtained from a donor mouse inoculated with L. b. pifanoi. The rate of

infection varied from 51 to 100% in different experiments. The infection developed one month to one year after inoculation. Visceral infection in mice has not been observed by him or by any other worker (Ercali + Fink, 1966).

b) Experimental leishmaniasis of hamsters.

L. tropica:

Adler (1947) concluded that the different Leishmania species can be distinguished by animal inoculation. L. tropica in Syrian hamsters uniformly produces a visceral infection and a uniform skin infection (without ulceration) as intense or even more intense than that produced by L. donovani or L. infantum, but in the case of L. tropica the parasites in the hamster are much larger than L. infantum or L. donovani, and there is thus no difficulty in distinguishing spleen smears of the two types of infection.

L. mexicana

Garnham and Lewis (1959) studied the course of infection of L. mexicana from British Honduras in hamsters. Garnham (1962) described the infection in young and in adult hamsters inoculated intradermally with either amastigotes or promastigotes of L. mexicana as follows:

"In less than a month, an indurated swelling appears at the site of inoculation; the tumour enlarges and may adhere to the skin, which loses its hair. Slow growth occurs during the next six months, the tumour may regress or remain stationary for a year or longer. The

swelling is conspicuous and rather soft in consistency; sometimes two or three lumps may be present, close to each other. No ulceration takes place but the infection spreads metastatically, and within three months the organism may be present in small numbers in the spleen, by six months, the invasion of the internal organs is more intense, parasites are numerous and the liver and bone marrow may be invaded. Metastatic spread is however inconsistent."

Coelho and Coutinho-Abath (1965) described the course of infection in hamsters inoculated with L. mexicana. This was very similar to that described by the same author in mice. In contrast to mice, visceralization was common in hamsters. Mata et al. (1968) found 75% of hamsters inoculated subcutaneously showed visceral infection. 100% visceral infection occurred by intraperitoneal inoculation.

L.b. braziliensis

Fuller and Geiman (1942) infected Syrian hamsters with three strains of L.b. braziliensis in culture. Of fourteen animals inoculated, only three developed skin lesions. Those three hamsters had been inoculated with organisms which had been passaged through chick embryos. The lesions consisted of indurated nodules, which were first noticed at the site of inoculation, fifty-five, seventy-four and ninety days after inoculation. The nodules increased in size to a diameter of 5 to 7 mm. *Intra peritoneal*

inoculation, did not develop the infection.

L. b. pifanoi

Inoculation of hamsters with L. b. pifanoi resulted in a high percentage of infection, sometimes reaching 100%. The incubation period was from 3 weeks to 3 months. 40% of the hamsters showed metastasis of the infection to various parts of the hairless skin. The initial lesions, as well as metastatic ones, were full of parasites but there was no visceral involvement. Intraperitoneal inoculation did not produce infection (Convit, 1958; Medina and Romero, 1959).

c) Experimental leishmaniasis of other rodents:

Rats and guinea pigs have been repeatedly proved unsuitable or poor hosts of human species of Leishmania. Neither rats nor guinea pigs are susceptible to L. b. pifanoi (Convit 1958; Medina and Romero, 1959). Ercoli and Coelho (1957) succeeded in infecting guinea pigs by intradermal inoculation. This is the only record of its kind in the literature.

Strangways-Dixon and Lainson (1962) obtained very poor infections in rats, guinea pigs and gerbils inoculated intradermally with L. mexicana.

Present Work

During the present studies the course of infection due to three different strains of L. braziliensis pifanoi was followed in hamsters, albino mice, hairless mice, "shaven" mice, hybrid mice ("shaven" x albino), rats and guinea pigs.

Animals were infected by intradermal, intraperitoneal, intracardiac, intravenous, intratesticular or intrauterine inoculation.

(a) Diffuse cutaneous leishmaniasis in hamsters

1. Intradermal inoculation of L. b. pifanoi

Experiment 1: amastigotes of strain VI

Ten young hamsters were each inoculated intradermally with 0.05 ml. of a suspension of amastigotes in balanced Hanks's solution, obtained from an infected hamster, as follows:

- 4 hamsters were inoculated in the snout with "medium" dose
- 2 hamsters were inoculated in the snout with "heavy" dose
- 2 hamsters were inoculated at the base of the tail with "medium" dose
- 2 hamsters were inoculated in the foot pad with "medium" dose.

The animals were checked once a week by aspirating material from the site of inoculation and making smears, also by inoculating 4N cultures, to determine the presence or absence of parasites.

The animals were killed 2, 4, 6, 8, 12 or 18 months after inoculation. Smears made from their liver and spleen were fixed in methanol and stained with Giemsa. Heart blood, small pieces of spleen, liver and in some cases lymph glands were put into culture medium. Smears were also prepared from metastasized nodular lesions from different parts of the body. Pieces of tissue from liver, spleen, lung, infected skin and regional lymph glands were fixed in 10% formal saline or Carnoy's fixative, for histological studies.

Results:

The result of this experiment is shown in Table 1. In the two hamsters inoculated with a "heavy" dose of parasites in the snout, lesions appeared as slight bulges or swellings at the sites of inoculation as early as 10 - 14 days after inoculation. In all other hamsters inoculated with a "medium" dose, the incubation period varied from 6 - 24 weeks.

The lesions grew slowly, reaching 1 - 1.5 cm. in diameter in two hamsters with heavy infections within two months of inoculation. The small indurated swellings of the lesion was accompanied by loss of hair from the affected area of skin. The lesion assumed a shiny, firm, reddish appearance. Ulceration of the initial nodule was not uncommon, occurring especially in animals inoculated in the snout. Five out of eight hamsters inoculated with the medium dose showed ulceration of the primary lesion.

Smears prepared from the lesions showed abundant amastigotes. In the majority of cases these amastigotes were of the usual rounded or oval form.

Table 1

Course of *L. b. pifanoi* Strain VI (Amastigotes) in Hamsters

Hamster Serial No.	Type and dose of inocula	Site and mode of inoculation	Incubation Period	Type of Lesions		1st metas-tasis after:	Smears from skin lesions	Spleen		Liver		Heart blood		Lymph Glands					Fate of Animal
				N	U			Sm	Cl	Sm	Cl	Sm	Cl	Max	Axi	Ing	Cudal	Lumbar	
H12	Am. "heavy"	I.D. Snout	10 days	N	U	20 weeks	+++	-	-	-	-	-	-	+	--	+-	-	--	Killed after 6 months
H13	Am. "heavy"	I.D. Snout	14 days	N	U	24 weeks	+++	-	-*	-	-	-	-	+	+-	+-	-	--	Killed after 8 months
H14	Am. "medium"	I.D. Snout	6 weeks	N	U	-	++	-	-	-	-	-	-	-	--	--	--	--	Killed after 2 months
H15	Am. "medium"	I.D. Snout	8 weeks	N	U	-	++	-	-*	-*	-	-	-	few	--	--	--	--	Killed after 4 months
H16	Am. "medium"	I.D. Snout	6 weeks	N	U	-	+++	-	-	-	-	-	-	+	--	-+	-	--	Killed after 8 months
H17	Am. "medium"	I.D. Snout	7 weeks	N	U	35 weeks	+++	-	-	-	-	-	-	+	+-	-+	-	--	Killed after 10 months
H18	Am. "medium"	I.D. B.T.	14 weeks	N	U	38 weeks	+++	-	-	-	-*	-	-	-	--	-+	+	-	Killed after 10 months
H19	Am. "medium"	I.D. B.T.	8 weeks	N	-	-	++	-	-	-	-	-	-	-	-	-	-	-	Died after 5 m
H20	Am. "medium"	I.D. F.P.	24 weeks	N	-	56 weeks	+++	-	-	-	-	-	-	+	+-	++	+	-	Killed after 18 months
H21	Am. "medium"	I.D. F.P.	14 weeks	N	-	45 weeks	+++	-	-	-	-	-	-	+	-	+	+	--	Killed after 12 months

Key

Am. = Amastigotes
I.D. = Intradermally
B.T. = Base of the tail

F.P. = Foot Pad
N = Nodule
U = Ulcer

Sm = Smear
Cl = Culture
Max = Maxillary

Axi = Axillary
Ing = Inguinal
+ = Positive

- = Negative
* = Contaminated culture

Occasionally elongate forms were interspersed among the rounded forms. The amastigotes varied in size from 2×3 to $5 \times 5 \mu\text{m}$. The nucleus was slightly elongate and closely applied to the cell wall. The kinetoplast was located at the opposite pole of the cell. A large vacuole was often seen in the cytoplasm between the nucleus and the kinetoplast.

In animals inoculated with heavy doses, metastasis of the parasite started 5–6 months after inoculation. The metastasis was limited to hairless parts of the body. The first secondary lesion appeared on the feet, tail or ears. Secondary lesions did not ulcerate.

On the feet, diffuse nodules appeared on the pad or on one of the digits as a small lesion which gradually enlarged and extended to involve the other digits, and eventually the foot lost its distinct shape and became transformed into one large nodular growth (Figs.7 and 8).

The course of the disease in animals inoculated with a medium dose of parasites was similar to that in animals receiving heavy doses, except for the longer incubation period, being 6–24 weeks. The growth of the lesions was slower and metastasis of the lesions was delayed up to ten months in some animals.

Smears of liver and spleen, as well as cultures from these organs, were free of parasites. The inoculation of cultures with heart blood from animals with metastatic lesions did not result in the growth of parasites.

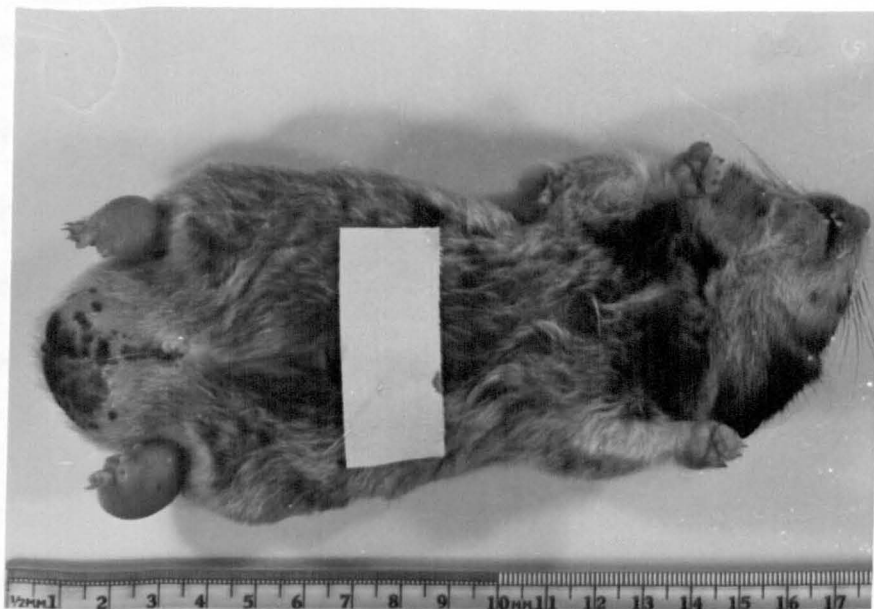


Fig.7 Hamster inoculated with Leishmania braziliensis pifanoi V1 in the left hind foot, showing metastasis of the infection to the other hind foot and fore limbs.

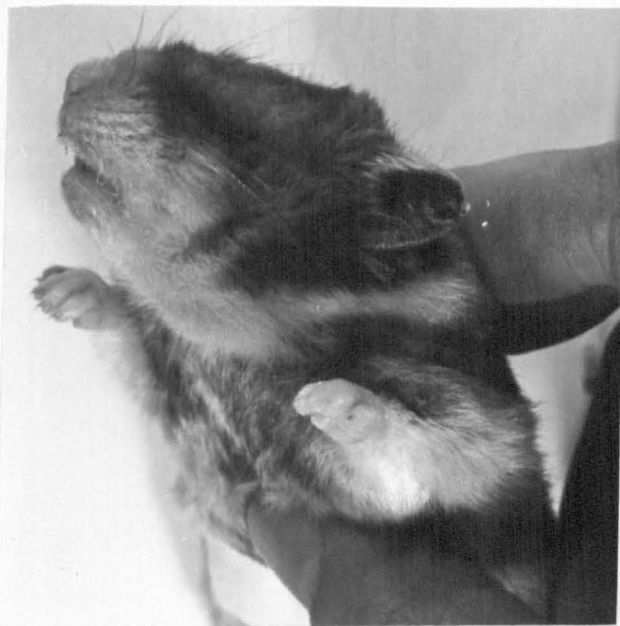

Fig.8 Secondary lesions on the snout and foot pads of the same hamster.

Experiment 2: promastigotes of strain VI

Promastigotes of strain VI, isolated from an infected hamster, were cultivated for 1 to 2 weeks in 4N media. The parasites were harvested and the number of promastigotes was adjusted to 40×10^6 /ml. 0.1 ml. of this suspension was inoculated intradermally or subcutaneously as follows:

4 hamsters were inoculated in the snout

4 hamsters were inoculated at the base of the tail

2 hamsters were inoculated in the foot pad.

The animals were checked for the development of lesions as in Experiment 1.

Results:

The result of this experiment is shown in Table 2. Lesions appeared on the snout and at the base of the tail as small, hardly palpable nodules 4 - 6 months after inoculation. The growth of the lesions was accompanied by loss of hair from the affected part. The lesions attained a size of 0.4 - 0.5 cms. in diameter 8 months after inoculation. Ulceration occurred in three out of four animals inoculated in the snout and in two out of four of those inoculated in the base of the tail; none of the foot pad lesions ulcerated.

Table 2

Course of *L. b. pifanoi* Strain VI (Promastigotes) in Hamsters

Hamster Serial No.	Type and dose of inocula	Site and mode of inoculation	Incubation Period	Type of Lesions		1st metas-tasis after:	Smears from skin lesions	Spleen		Liver		Heart blood		Lymph Glands					Fate of Animal
								Sm	Cl	Sm	Cl	Sm	Cl	Max	Axi	Ing	Cudal	Lumbar	
H ₂	Pro. 4 x 10 ⁶	I.D. Snout	12 weeks	N		-	++	-	-	-	-	-	-	+	+	+-	-	-	Killed after 6 months
H ₃	Pro. 4 x 10 ⁶	I.D. Snout	15 weeks	N	U	30 weeks	++	-	-	-	-	-	-	+	-	--	-	-	Killed after 9 months
H ₄	Pro. 4 x 10 ⁶	I.D. Snout	14 weeks	N	U	40 weeks	+++	-	-	-	-	-	-	+	-	+-	+	--	Killed after 14 months
H ₅	Pro. 4 x 10 ⁶	I.D. Snout	20 weeks	N	U	45 weeks	+++	-	-	-	-	-	-	+-	+-	++	-	--	Killed after 18 months
H ₆	Pro. 4 x 10 ⁶	S.C. Tail	18 weeks	N		-	+++	-	-	-	-	-	-	-	-	-	+	-	Killed after 10 months
H ₇	Pro. 4 x 10 ⁶	S.C. Tail	14 weeks	N	U	36 weeks	+++	-	-	-	-	-	-	+	+	+	+	-	Killed after 16 months
H ₈	Pro. 4 x 10 ⁶	S.C. Tail	15 weeks	N		42 weeks	+++	-	-	-	-	-	-	+	+		+	-	Killed after
H ₉	Pro. 4 x 10 ⁶	S.C. Tail	12 weeks	N	U	-	+++	NOT EXAMINED										Died after 7 months	
H ₁₀	Pro. 4 x 10 ⁶	S.C. Foot Pad	9 weeks	N		-	+++	-	-	-	-	-	-	-	+-	-	-	-	Killed after 7 months
H ₁₁	Pro. 4 x 10 ⁶	S.C. Foot Pad	24 weeks	N		44 weeks	+++	-	-	-	-	-	-	-	++	++	-	-	Metastasis occurred after amputation of the infected foot

Key:

Pro. = Promastigotes
 I.D. = Intradermally
 S.C. = Subcutaneously

F.P. = Foot Pad
 N = Nodule
 U = Ulcer

Sm = Smear
 Cl = Culture
 Max = Maxillary

Axi = Axillary
 Ing = Inguinal
 + = Positive

- = Negative



Fig.9 Primary lesion of L. b. pifanoi V1 on the snout of a hamster inoculated three months previously with a heavy dose of amastigotes.

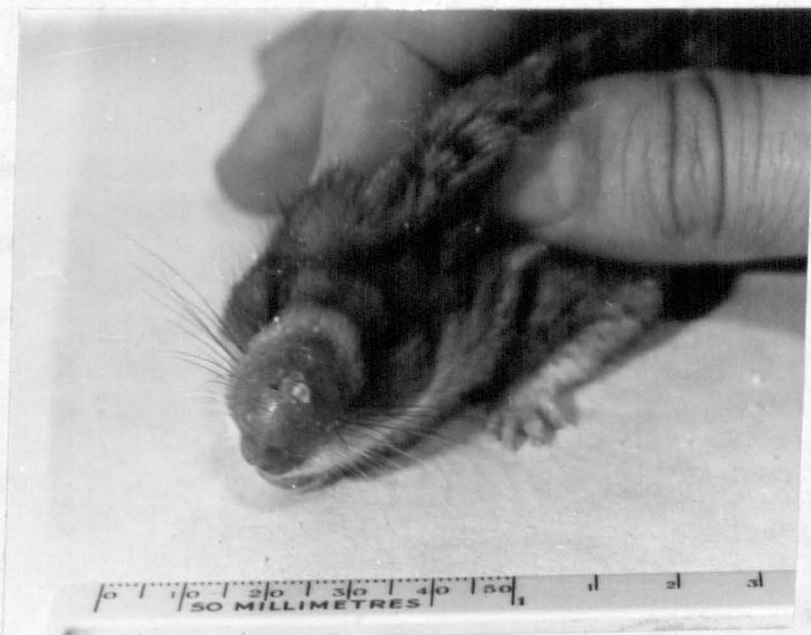

Fig.10 Six months old primary lesion on the snout of a hamster inoculated with a medium dose of L. b. pifanoi.

Each lesion of the foot pad started as a general swelling of the foot. In 8 - 10 months the foot became a shiny, erythematous, round mass. Metastasis to the left hind foot and to the base of the tail was noticed in two of the hamsters inoculated in the snout, in one of those inoculated in the foot pad (following amputation of the affected foot) and in two of the animals inoculated at the base of the tail.

Smears as well as cultures of the liver and spleen did not reveal parasites. Lymph glands, mainly the regional ones, showed abundant parasites.

Experiment 3: promastigotes of strain V2

Six young hamsters were inoculated intradermally in the snout with promastigotes from a young culture; 2 hamsters received 100×10^6 parasites and 4 received 4×10^6 . The animals were checked for the development of the lesions and investigated for the occurrence of metastasis in the usual way. The viscera were checked for the presence of the parasites by smears and culture.

Results:

The two hamsters inoculated with 100×10^6 promastigotes developed lesions 10 - 14 days after inoculation. Ulceration started four weeks later. The ulceration was accompanied by secondary bacterial infection. Metastasis

was noticed after four months in one animal and after five and a half in the other; the secondary lesions occurred on the skin of the hairless parts of the body.

In the other four hamsters the lesions developed 2 - 3 months later with ulceration in one of them. The lesions grew slowly and reached 0.5 - 1 cm. in diameter within 6 - 8 months. Metastasis was not noticed up to 8 months after inoculation.

Viscera and heart blood remained uninfected.

Experiment 4: amastigotes of strain L 15

Six young hamsters were inoculated in the snout with amastigotes from infected hamsters; four received 0.1 ml. of a "heavy" dose and two received 0.05 ml. of a "low" dose.

Results:

The result of this experiment is shown in Table 3. Each animal inoculated with the heavier dose of parasites developed a lesion at the site of inoculation within one month. The lesion extended to the rest of the snout in the form of a slightly raised flat area of thickened skin, which became free of hair and shiny. Ulceration of the lesion took place in all animals. In some cases the ulcer was covered with a dry crust. Metastasis was noticed in only one animal 30 weeks after inoculation (Fig.11). The other animals

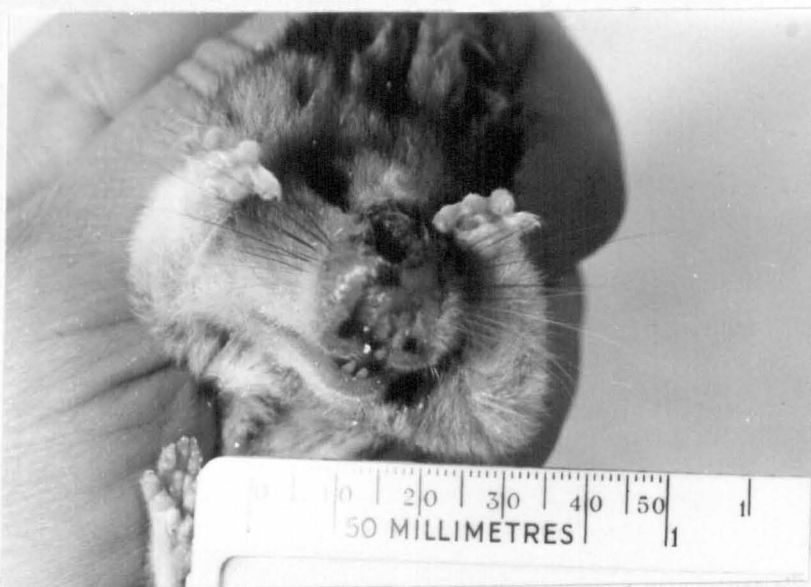

Fig.11 Hamster inoculated with heavy dose of Strain L 15 showing ulceration and encrustation of the primary lesion.

were killed or died within 41 weeks of inoculation without showing metastasis.

In the two hamsters inoculated with lower doses of parasites the lesions developed 14 - 18 weeks after inoculation as small nodules. Ulceration was noted in one animal. No metastasis was seen in either of them.

Smears from the lesions showed large numbers of parasites (Fig.12) but the viscera were not invaded.

2. Intraperitoneal inoculation

Experiment 5: amastigotes and promastigotes of Strain V1

Six young hamsters were inoculated intraperitoneally with 0.2 ml. "heavy" dose of amastigotes of L. b. pifanoi V1. Two animals were inoculated with 30×100^6 promastigotes. The animals were checked for the presence of the parasite by preparing smears and cultures of peritoneal fluid aspirated after intraperitoneal inoculation of 1.0 ml. of sterile balanced Hanks's solution.

Biopsy of the spleen of two hamsters was carried out four weeks after inoculation, and of another two after 8 weeks. Impression smears were prepared, stained with Giemsa's stain, and examined for parasites.

Four of the animals were kept under observation for 18 months and

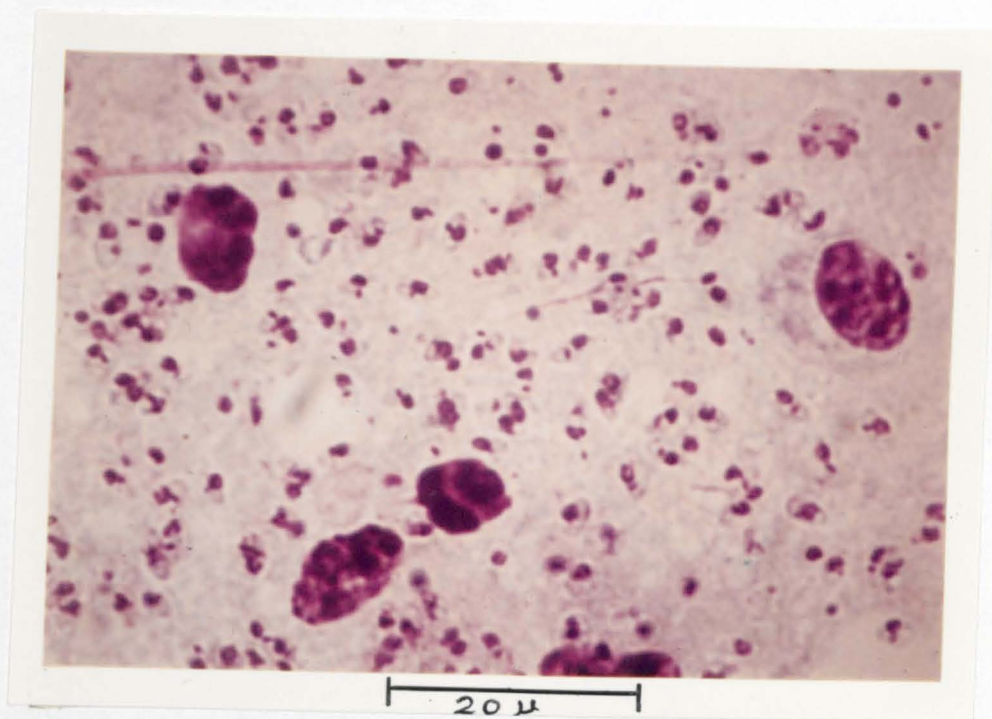


Fig.12 Smear from the lesion on the snout of an infected hamster, showing a large number of amastigotes. Smear stained with Giemsa's stain.

the course of the disease followed.

Two animals were killed 6 months after inoculation and thoroughly examined for the parasites in different organs (lungs, spleen, kidney, liver) by means of smears and cultures.

Results:

Aspiration of the peritoneal fluid from two of the animals one week after inoculation with amastigotes did not reveal any parasites. Material obtained by splenic biopsy 4 and 8 weeks after inoculation showed no signs of infection. The spleens of all the animals were normal in size and colour.

The two animals killed six months after inoculation also showed no sign of visceral infection. However, two of the animals inoculated with amastigotes showed a primary lesion in the scrotum 10 and 13 months after inoculation. This was followed by metastasis on the base of the tail and the hind foot pad. Smears prepared from the scrotum were rich in parasites.

The two animals inoculated with promastigotes remained uninfected and they were killed 18 months after inoculation.

Experiment 6: amastigotes of strain V2

Two hamsters were inoculated intraperitoneally with 0.2 ml. of heavy doses of amastigotes from ground-up infected lesions from mice.

0.5 ml. of sterile Hanks's solution was inoculated intraperitoneally and peritoneal fluid aspirated 3, 7, and 14 days after inoculation of the parasites. The aspirated fluid was examined by smears and cultures.

Results:

Culture of peritoneal fluid obtained 3 and 7 days after inoculation of the parasite revealed a few promastigotes but fluid aspirated 14 days after inoculation was free of parasites.

One hamster was killed 5½ months after inoculation. Smears of its liver and spleen did not show any parasites.

The other hamster was killed one year later and was also uninfected. No lesion was seen on its skin or elsewhere.

3. Intracardiac inoculation

Experiment 7: a mastigotes of strain VI

12 young hamsters were inoculated intracardially with strain VI. Two hamsters were inoculated with 0.1 ml. of a young culture containing approximately 10^7 promastigotes. One of the animals died five months after inoculation and the other was killed ten months after inoculation.

10 hamsters were also inoculated intracardially with a rich suspension of amastigotes. One of the animals inoculated with amastigotes died one hour later and parasites were detected in smears of its liver. The

other nine hamsters were kept under observation to determine the course of the infection. One animal was killed two months, another three months and a third four months after inoculation. Pieces of their spleens and livers and heart blood were cultivated in 4N medium.

Four animals were kept under observation more than two years after their inoculation.

Results:

The hamsters which died five months after inoculation with culture forms, and the hamster sacrificed after 10 months, had not become infected.

All hamsters killed two, three and four months after inoculation with amastigotes were also uninfected.

The four animals which were kept under observation for more than two years did not show any symptom of the disease.

4. Intrasplenic inoculation

Experiment 8: promastigotes and amastigotes of strain VI

10 young hamsters were inoculated intrasplenically by laparotomy under general anaesthesia.

2 hamsters received 5×10^6 promastigotes

4 hamsters received a "heavy" dose of amastigotes

4 hamsters received amastigotes prepared by grinding infected regional lymph glands from hamster

In addition, 2 hamsters were inoculated intradermally to check the viability of the parasites from the lymph glands.

The animals were examined by splenic biopsy, 4, 8 and 16 weeks after inoculation. Impression smears were prepared, stained with Giemsa's stain, and examined for the presence of parasites.

Results:

The two animals inoculated with cultures of L. b. pifanoi did not show any infection in the spleen or in any viscera or in the skin. One hamster was sacrificed 8 months after inoculation and another after a year. Both were uninfected.

Spleen biopsies taken after 4 - 8 weeks from animals inoculated with amastigotes did not show parasites in smears. These animals were killed one year later without having shown any sign of disease.

Animals inoculated with infected lymph glands showed a similar picture to those mentioned above: one of the animals died after 6 months from unknown causes; no parasites were detected in its internal organs. Another animal showed a small nodule on the right hind foot 8½ months after inoculation. The lesion grew larger and another lesion appeared on the snout 3 months after the appearance of the first one. The animal was killed

6 months later but no parasites were detected in its internal organs, either from smears or after culture. The other two animals remained uninfected and they were sacrificed 14 and 18 months after inoculation.

(b) Diffuse cutaneous leishmaniasis in mice

1. i) Intradermal inoculation (albino mice) into snout with different doses of parasites

Experiment 9: promastigotes and amastigotes of strain VI

Promastigote inocula were prepared as in previous experiments.

Young albino mice in groups of six were inoculated in the snout with doses of 10^8 , 10^7 , 10^6 , 10^3 and 10^2 promastigotes per mouse.

Six more groups of 6 mice each were injected in the snout with 0.1 ml. suspension of amastigotes. The inoculum was estimated as very heavy, heavy, medium, low, or very low. The same procedures as outlined in the previous experiment were used for detecting parasites in lesions and in other parts of the body.

Results:

The results of this experiment are shown in Table 4. In animals inoculated with 10^8 promastigotes, lesions appeared 2 - 4 weeks after inoculation. Ulceration with secondary bacterial infection was noticed 4 - 6 weeks later. The lesions enlarged slowly and reached 1 - 1.5 cm.

in diameter in four months. The lesions extended to the eye-lids of some animals (Fig.13) and, in one case, to the upper lips. In 3 mice metastasis occurred 7 - 9 months after infection, but no visceral involvement was seen.

In animals inoculated with 10^7 promastigotes, the lesions developed 4- 8 weeks after inoculation and reached 0.8 - 1.2 cm. in diameter in 6 - 7 months. Metastasis occurred in one animal after 14 months (Fig.14). No visceral involvement was detected in any of the animals.

In mice inoculated with 10^6 promastigotes no lesions appeared until 5 months after inoculation, but parasites were detected in smears at the site of inoculation 2-3 months before a nodule was visible. The lesion attained a size of 6 - 8 mm. in 10 - 12 months. No metastasis occurred in this group, even in animals kept under observation for 18 months.

Of the mice inoculated with 10^3 promastigotes only one developed a lesion after an incubation period of nine months; the other 5 mice remained negative.

Mice inoculated with 10^2 promastigotes also remained uninfected.

The development of lesions in mice inoculated with amastigotes was faster and the lesions more uniform in shape than in those inoculated with promastigotes. The lesions developed after 10 - 21 days in mice inoculated with "very heavy" dose of parasites. Ulceration occurred in 12 out of the 24 mice. The lesions reached a size of 1.2 - 1.8 cm. in

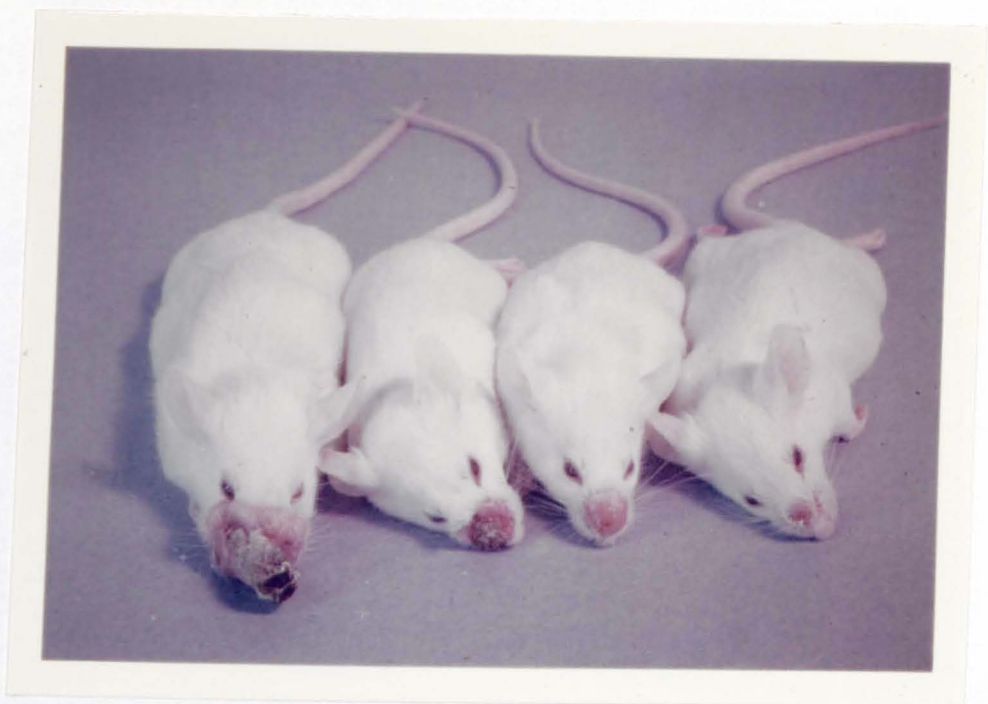

Fig.13 Stages in the development of lesions of L. b. pifanoi on the snouts of albino mice, showing from right to left: a papule, nodule, ulceration and proliferation with encrustation.

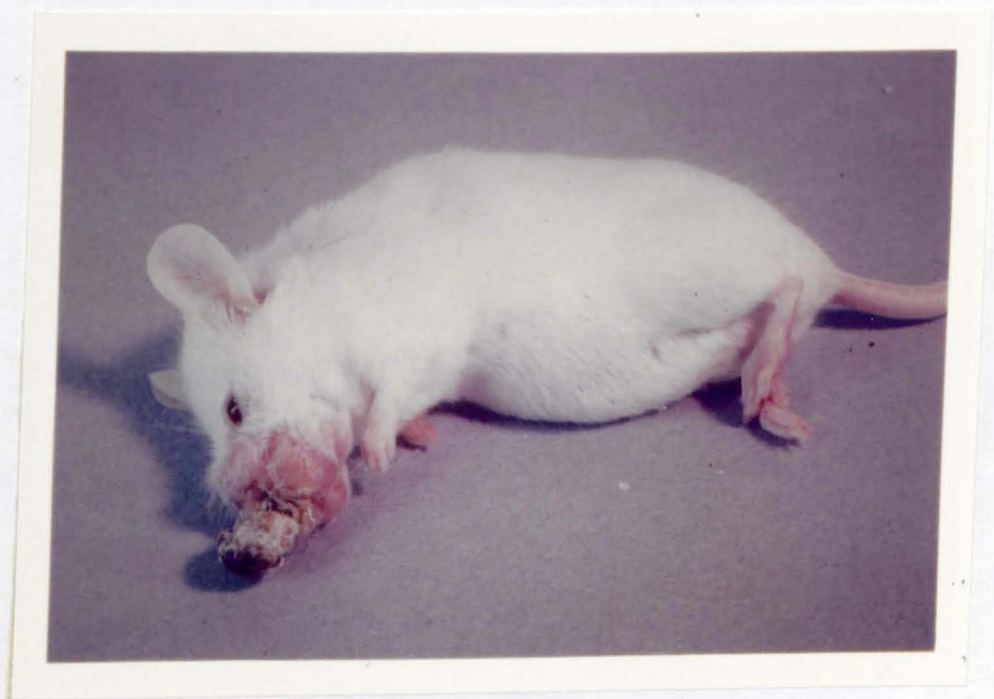

Fig.14 Advanced stage in the development of the primary snout lesion and metastasis to the left hind foot, 14 months after inoculation with a heavy dose of L. b. pifanoi strain V1.

diameter in 3 - 5 months. Metastasis was noticed in one mouse only seven months after inoculation.

In animals inoculated with a "heavy" dose, the lesions developed 4 - 12 weeks after inoculation and reached 1 - 1.4 cm. in diameter in 10 months.

Metastasis was noticed in two animals but only after 10 - 12 months.

In mice inoculated with a "medium" dose, the lesion developed 8 - 16 weeks after injection. Ulceration followed in only two animals. The lesions attained a size of 0.4 - 0.8 cm. in diameter in 6 months. No metastasis occurred in this group of animals.

In mice inoculated with a "low" dose, only two developed lesions which were 0.2 - 0.3 cm. in diameter after nine months, without any sign of metastasis or ulceration.

None of the animals inoculated with "very low" doses developed a lesion and are therefore excluded from Table 4.

Table 4. Results of experimental infection of albino mice with
different doses of L.b. *trypomastigoti*

No. of albino mice	Type of inocula	Dose	Incubation Period weeks	Type of lesions		Size of lesions cm.	No. of mice with metastasis	Time of metastasis months
				N	U			
6	Promastigotes	10^8	2 - 4	1	5	1.0-1.5	3	7 - 9
6	"	10^7	4 - 8	-	6	0.8-1.2	1	14
6	"	10^6	20 - 24	2	2	0.6-0.8	-	-
6	"	10^3	36	1	-	0.2	-	-
6	"	10^2	-	-	-	-	-	-
6	Amastigotes	very heavy 0.05 ml.	2 - 3	-	6	1.2-1.8	2	7
6	"	heavy 0.05 ml.	4 - 12	2	4	1.0-1.4	2	10-12
6	"	medium 0.05 ml.	8 - 16	4	2	0.4-0.8	-	-
6	"	low 0.01 ml.	30	2	-	0.3	-	-

Key:

N = Nodular

U = Ulcer

- ii) Intradermal inoculation (hairless, "shaven" and albino mice)
into base of tail

Experiment 10: amastigotes of strain V2

Six hairless, six "shaven", and six albino mice were inoculated at the base of the tail with 0.05 ml. of a suspension of amastigotes in Hanks's solution, containing 50 parasites per microscopic field.

Results: A comparison of the course of infection is shown in Fig.15. The first sign of development of the lesions was noticed 2 - 3 weeks after inoculation in hairless and "shaven" mice, while in albino mice nodular lesions were detected 8 - 12 weeks after inoculation in 5 animals only. Most of the lesions were flat with a tendency to ulcerate.

The lesions grew fastest in the hairless mice, reaching 0.7 - 1.2 cm. in diameter in 4 - 5 months. Ulceration was noticed in all mice.

In hairless mice metastasis appeared 2 - 5 months after inoculation in the form of tiny satellite lesions around the original lesion (Fig.16). Other lesions then appeared along the tail. One of these mice died after 5 months due to the severity of the infection producing obstruction of the rectum (Fig.17). In all these mice, parasites were detected in the regional lymph glands, deep skin (subdermal layer) and epidermis. All the animals died (2) or were killed within 8 months of inoculation. No visceral infection was found. Smears from liver, spleen, kidney and lung, and cultures of heart blood, liver and

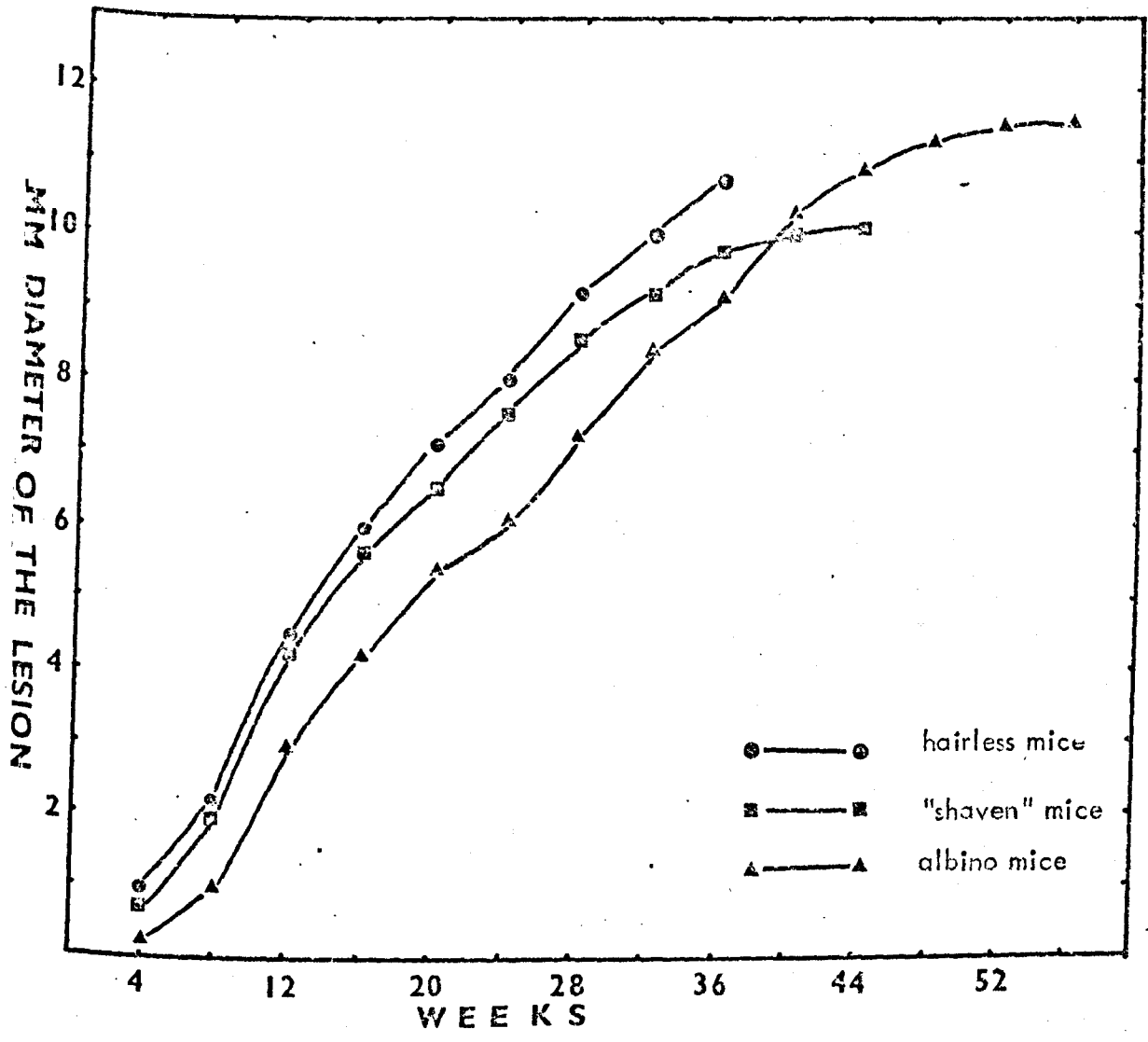


Fig. 15 Course of infection of *L.b. pifanoi* VI in hairless, "shaven" and albino mice after intradermal inoculation at the base of the tail.

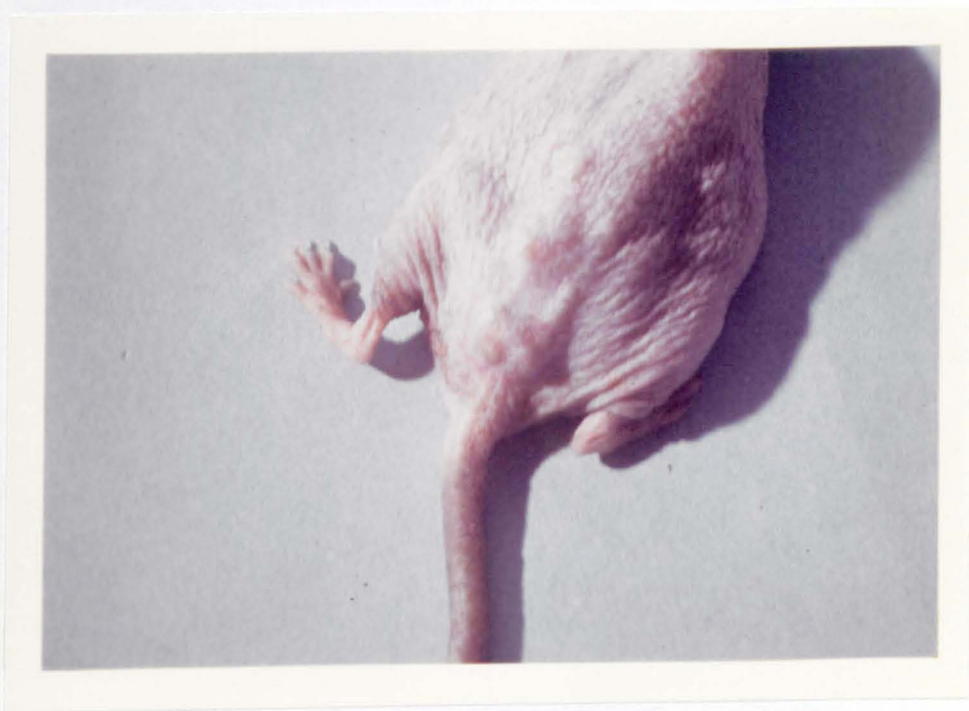

Fig.16 Shaven mouse showing satellite lesions around the initial primary lesion on the back.

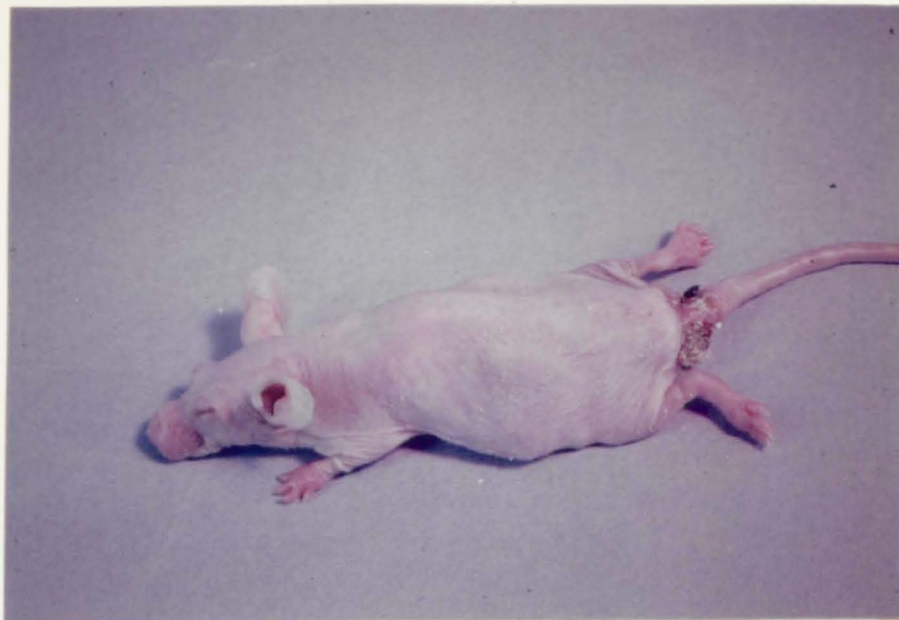


Fig.17 A hairless mouse showing ulceration of the primary lesion on the base of the tail and metastasis of the parasite to all the limbs, snout and eyelids.

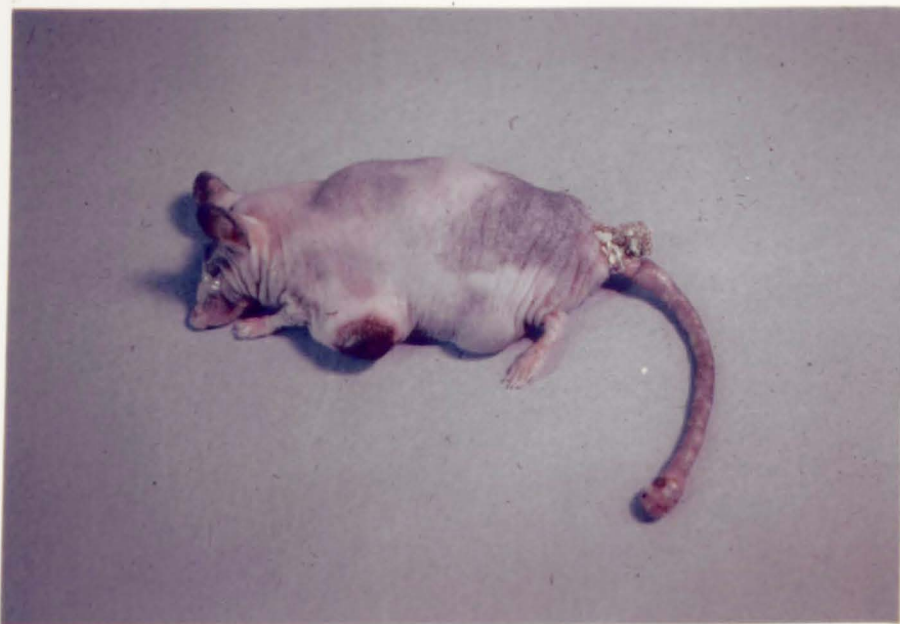

Fig.18 A shaven mouse with an ulcerating primary lesion at the base of the tail and secondary lesions on the tail, feet, ears and snout. Some of the lymph glands are enlarged probably due to secondary bacterial infection of the primary lesion.

spleen did not reveal parasites.

The course of infection in the shaven mice was similar to that in the hairless mice but the growth of the lesion was slower. Metastasis of the parasite to different parts of the body was observed 3 - 5 months after inoculation. Some of the animals survived over a year (Fig.18).

In the albino mice only 4 animals developed lesions after 3 - 6 months. One animal showed metastasis after 14 months. The lesions measured 0.8 - 1.1 cm. in diameter 9 months after inoculation.

iii) Intradermal inoculation (albino and "shaven" mice) into different parts of the body

Experiment 11: amastigotes of strain VI

Six groups, each consisting of 6 young albino mice, 2 "shaven" mice, were inoculated intradermally with 0.05 ml. of a "medium" dose of a suspension of amastigotes.

The sites of inoculation for each group were: 1) the snout; 2) the back; 3) the inner thigh; 4) the base of the tail; 5) the tail, and 6) the foot pads. The 2 shaven mice were inoculated in the back.

The hair of the back of 2 additional albino mice inoculated in their back was clipped from the area of inoculation for 3 successive weeks.

The lesions were checked in the usual way.

Results:

Mice of group 1 (inoculated in the snout) and of group 4 (inoculated at the base of the tail) developed lesions 3 - 8 weeks later. Ulceration took place 2 - 4 months after the development of the lesions. No metastasis was noticed although the animals were kept under observation for more than a year.

Four mice from group 6 (inoculated in the foot pad) showed lesions 8 - 12 weeks after inoculation. The growth of the lesions was very slow. No ulceration or metastasis was noticed and the infection remained static for as long as 2 years in the form of small local lesions.

One animal from group 3 (inoculated in the skin of the inner thigh) developed a lesion 8 months later, not at the site of inoculation but on the ventral surface of the base of the tail.

In animals of group 5 (inoculated in the tail) the infection developed 8 - 12 weeks after inoculation with flat lesions extending along the tail. Two mice from this group developed lesions within 10 weeks of inoculation. Metastasis occurred in one animal along the tail and on the left hind foot after 12 months. The infection remained static for as long as 18 months.

Shaven mice inoculated on their backs developed lesions within 5 - 8 weeks of inoculation. The 2 clipped albino mice showed few parasites in smears prepared 3 weeks after inoculation, but the albino mice which

were left unclipped (group 2) failed to develop lesions.

2. Intraperitoneal inoculation (albino, hybrid and "shaven" mice)

Experiment 12: promastigotes and amastigotes of strain V1

24 young albino mice, 8 hybrid ("shaven" x albino) and 2 "shaven" mice were inoculated intraperitoneally with a suspension of amastigotes or promastigotes.

Eight albino mice received 5×10^6 promastigotes and the rest of the mice received 0.1 ml. of "heavy" dose of amastigotes. The animals were checked for the presence of the parasites by peritoneal fluid aspiration as in hamsters. The aspiration was carried out 4, 8 and 12 weeks after inoculation with promastigotes and 3 days, 1, 2 and 4 weeks after inoculation with amastigotes. Smears and culture from internal organs were made in the usual way.

Results:

None of the animals inoculated with promastigotes showed parasites in the peritoneal fluid, neither cultures nor smears revealed any parasites. No lesions developed on any of the animals, even though some of them were kept under observation for more than one year.

In mice inoculated with amastigotes, the parasites were detected in the peritoneal fluid of 4 albino mice 3 days after inoculation. The

peritoneal fluid, spleen and liver did not reveal any parasites when examined 1 week or 2 weeks after injection.

Two albino mice showed the first sign of development of a lesion in the scrotum after 8 - 11 months. Another albino mouse showed a similar lesion 2½ months later. The lesion started as a thickening in the scrotal skin, followed by hair loss; ulceration of the scrotum occurred in 2 mice.

The rest of the albino mice remained uninfected.

From the hybrid mice group, 3 animals became infected 8 - 11 months after inoculation. The lesion was on the scrotum in male mice and the vulva of the female mouse. No ulceration occurred. The viscera and peritoneal fluid remained negative. The inguinal lymph glands were enlarged, and smears from the scrotum and lymph glands showed the presence of large numbers of parasites. Metastasis occurred in all infected animals to the penis, foot pads, ears and snout (Fig.21). The parasites were detected in all of these lesions as well as in regional lymph nodes such as the perianal, caudal, inguinal, axillary and sub-maxillary nodes.

The rest of the group remained uninfected.

In the "shaven" mice the lesions were developed in the scrotum 7 - 8 months after inoculation. Ulceration followed in one of them 3 weeks later. The other showed thickening of the skin and flattened lesion. Smears revealed the presence of the parasites. Metastasis to other parts of the body occurred

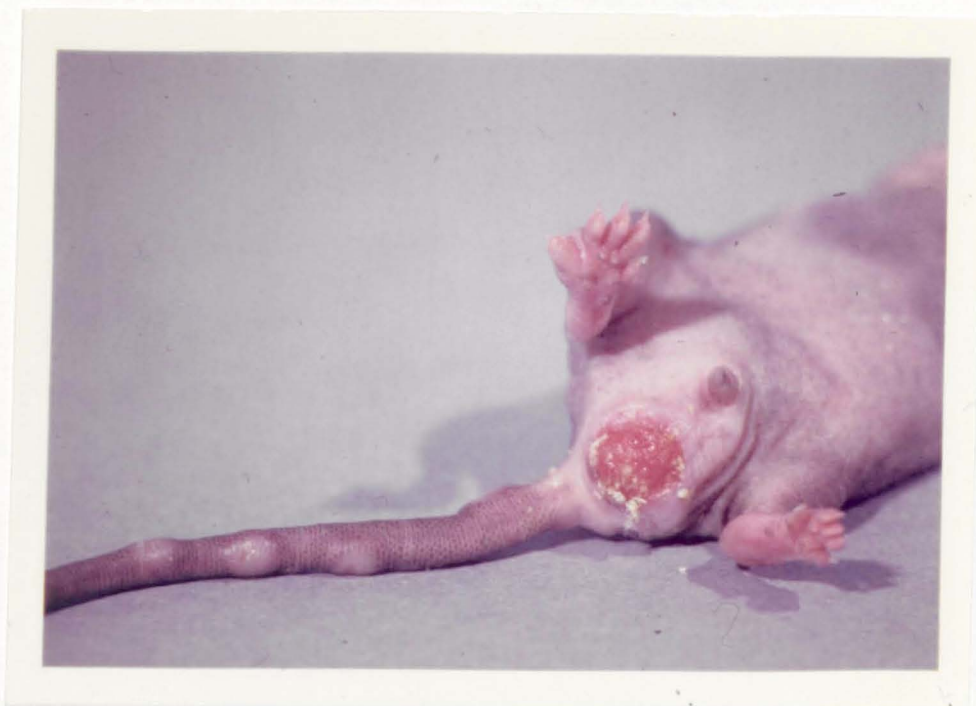

Fig.19 Shaven mouse inoculated intraperitoneally with L.b. pifanoi Strain V1; showing ulcerating lesions on the scrotum and nodular lesions on the hind limbs and tail.



Fig.20 The same mouse in Fig.19 with diffused nodular lesions on both ears and nose.

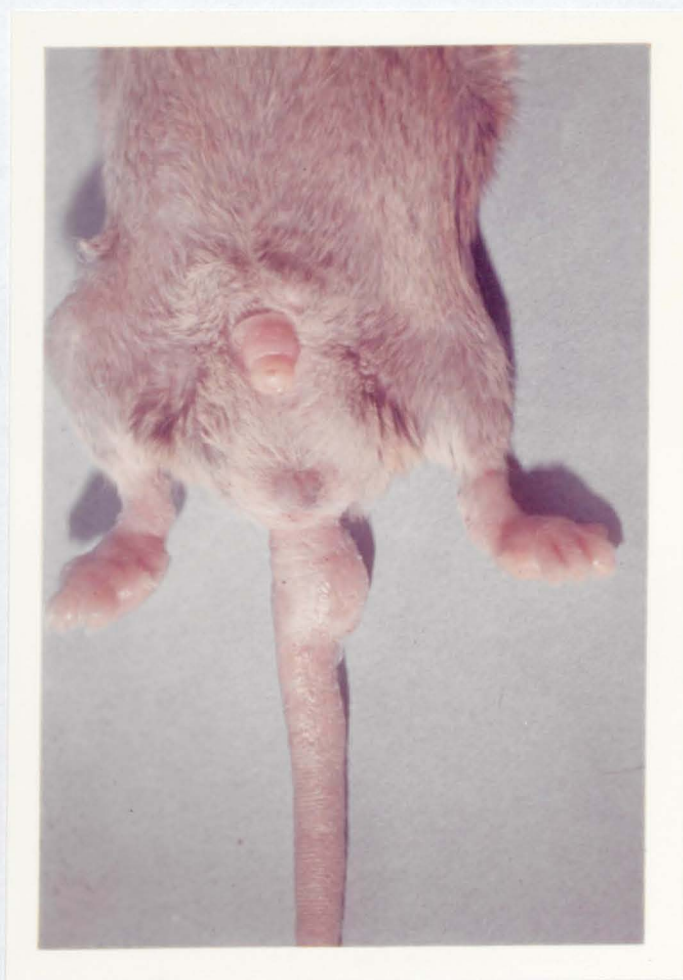

Fig.21 A hybrid mouse inoculated intraperitoneally with L. b. pifanoi showing lesions on the scrotum, penis and hind feet and tail.

2 - 3 months later with lesions spreading to the tail, foot pads, and snout (Fig.20).

Spleen, liver and peritoneal fluid were uninfected.

3. Intracardiac inoculation ("shaven", albino and hybrid mice)

Experiment 13: promastigotes and amastigotes of strain V1

Four shaven, 6 albino and 6 hybrid mice were each inoculated intracardially with 0.1 ml. of a "heavy" dose of amastigotes. Four other albino mice were inoculated with 10^8 promastigotes. The animals were kept under observation for more than one year. Tail blood from 3 of the albino mice inoculated with amastigotes was cultured at 2-monthly intervals.

Smears of spleen, liver, and bone marrow were examined when the animals were sacrificed 8, 12 and 14 months after inoculation.

Results:

Cultures of blood taken from the 3 albino mice 2, 4 or 5 months after inoculation did not reveal parasites.

None of the hairy mice (albino or hybrid) developed any lesions.

Two of the shaven mice showed the first signs of infection 11 weeks after inoculation. The other 2 shaven mice became infected 16 and 20 weeks after inoculation, respectively. The lesions appeared on different parts of

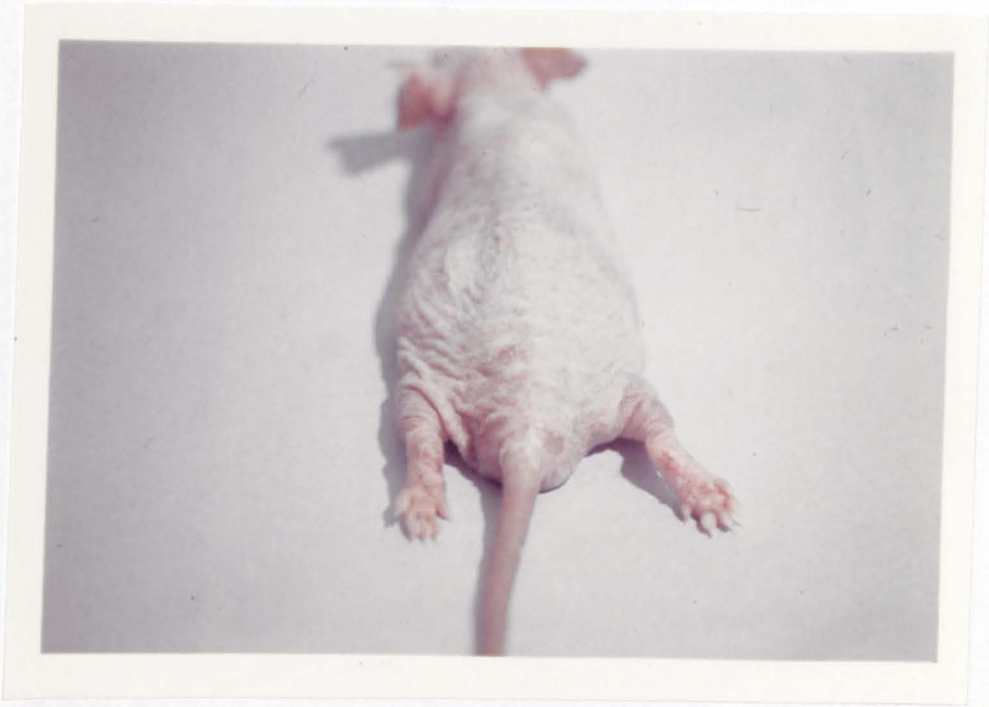

Fig.22 A shaven mouse inoculated intracardially with L.b. pifanoi showing lesions on the hind feet, skin of the back and base of tail .

the body at the same time; foot pads, snout and back were most commonly involved (Fig.22). Groups of 4 - 6 lesions developed simultaneously and grew uniformly, but did not ulcerate.

Smears from the lesions showed abundant parasites, but the spleen and livers remained uninfected.

4. Intravenous inoculation ("shaven", albino and hybrid mice)

Experiment 14: amastigotes of strain VI

Two shaven, 6 albino and 6 hybrid mice were inoculated with 0.1 ml. of a "very heavy" dose of amastigotes. During the inoculation in 2 of the hybrid mice some of the inoculum escaped into the subdermal space. The animals were checked weekly in the usual way.

Results:

None of the albino mice became infected; neither visceral nor dermal lesions were found. Both shaven mice became infected and 3 - 4 months after inoculation lesions developed along the tail and on the foot pads, snout and ears. Visceral involvement did not occur.

In the 2 hybrid mice, in which the inoculum diffused subcutaneously, lesions appeared after 4 - 6 weeks. These were followed by the appearance of other lesions on the hairless parts of the body, 2 - 3 months later.

One hybrid mouse became infected without showing a lesion at the

site of inoculation; $4\frac{1}{2}$ months after inoculation it exhibited diffused nodules all over the hairless parts. None of the infected mice showed visceral infection.

5. Intratesticular inoculation (albino mice)

Experiment 15: amastigotes of strain VI

Eight albino mice were inoculated with amastigotes, each receiving 0.1 ml. (a "medium" dose) deeply into the testis. The animals were kept under observation for 8 months.

Two mice inoculated with the same material intradermally at the base of the tail served as controls.

Results:

Three mice showed infection within 4 months of inoculation and 2 mice developed lesions 5 months after inoculation. The lesions appeared in the lower part of the scrotum, which became hard and leathery. At this stage large numbers of parasites were detected in smears of the affected area. In one animal the scrotum became ulcerated. No metastasis was observed in any of these mice during 8 months of observation. Sections of infected scrotum revealed the parasites in the tunica vaginalis, but the infection did not spread to the rest of the sexual organs or to other parts of the body.

6. Intrauterine inoculation of the foetus (pregnant hybrid mice)

Experiment 16: amastigotes of strain VI.

Two pregnant hybrid mice (3 days pre-parturition) were anaesthetized with Avertin (Bayer). Their uteri were exposed and 8 and 7 foetuses were inoculated through the uterine wall with 0.01 ml. suspension of amastigotes ("medium" dose) - see general Materials and Methods. The two mothers also received 0.1 ml. of the same inoculum at the bases of their tails.

The animals gave birth naturally to 8 and 7 young respectively.

Two of the newly-born mice were killed soon after birth and their spleens and livers were examined by the preparation of smears and cultures.

Eight mice were killed and examined 2, 6, 8 and 16 weeks later. The rest of the groups were kept under observation for more than one year.

Results:

None of the mice inoculated while in the uterus developed infection, but the two mother mice inoculated at the base of the tail developed infections at the site of inoculation, $2\frac{1}{2}$ and 4 months after inoculation, respectively.

7. Course of infection in suckling mice (hybrid mice)

Experiment 17: amastigotes of strain VI

1 - 3 day-old hybrid baby mice were inoculated subcutaneously (20 mice) and intraperitoneally (17 mice) with 0.01 ml. each of a suspension of amastigotes obtained by macerating a nodule of L. b. pifanoi from the snout of an infected hamster in Hanks's solution.

The mice were examined 1, 2, 4, 8, 20 and 42 weeks after inoculation by a palpation and by preparation of smears from the site of inoculation or from peritoneal fluid. Following the death of the animals, smears were prepared from spleen, liver and kidney.

14 hybrid mice (controls), 3 - 4 weeks old, were inoculated subcutaneously (8 mice) or intraperitoneally (6 mice) with similar doses of the same material to compare the course of infection in the adult mice with that of suckling mice.

Results:

Experimental mice

15 (75%) of the 1 - 3 day-old mice inoculated subcutaneously and 3 (17.6%) of those inoculated intraperitoneally developed lesions.

The mice inoculated subcutaneously showed signs of infection within 8 - 32 weeks, while those which became infected following intraperitoneal

inoculation did not reveal visible lesions until much later (9 - 11 months).

The lesions at the base of the tail in the first group of mice inoculated subcutaneously were comparable to those in the controls.

The lesions in the 3 mice which were inoculated intraperitoneally appeared on the scrotum. Infection of the scrotum started with palpable thickening of the skin followed by loss of hair. Smears from the leathery, affected part of the scrotum revealed a number of amastigotes. The lesions remained flat and did not become nodular in any of the infected scrotums. Ulceration was not observed.

In 1 of the 3 mice, which developed scrotal infection, the disease metastasized to both hind feet after eleven months and later on to other parts (ears, snout and the tail).

Smears from the viscera of the mice which had been inoculated intraperitoneally and which did not develop lesions, were free of parasites.

Control mice

None of the adult control mice inoculated intraperitoneally developed infection; 5 mice (62.5%) of the control mice inoculated subcutaneously developed infections within 8 - 38 weeks.

C. Investigating the possibility of droplet infection through the eye (hybrid mice)

During one of the experiments in the present work, a small amount of suspension of L. b. pifanoi in Hanks's solution accidentally spurted out from a syringe into my face. The face was immediately washed in water and soap and rubbed with a piece of cotton wool soaked in spirit. The possibility remained, however, that a few droplets of the suspension may have found their way into the eyes. It is known that infection with L. donavani may take place by droplet infection (Shortt, 1928) and the following experiment was carried out to test whether L. b. pifanoi could become established through the conjunctiva of the eye.

Experiment 18: amastigotes of strain V1

Six hybrid mice ("shaven" x albino) were anaesthetized. A large drop of a rich suspension in Hanks's solution was introduced into one of the eyes of each mouse. Smears were prepared from the affected eyes 24 hours later. The animals were put under observation for one year.

Results:

None of the mice developed lesions, and the smears did not reveal any parasites, nor did I show any subsequent sign of infection.

Table 5.

Summary of the infectivity of *L.b. pifanoi* Strain V1 in mice

No. of mice used	Strain of mice	Type of inocula	Route and site of inoculation	Incubation period weeks	No. of mice becoming infected	No. of mice showing metastasis
30	Albino TO	Promastigotes	I.D. Snout	2 - 36	17	4
30	" "	Amastigotes	" "	2 - 30	17	3
6	Hairless	"	I.D. Base of tail	2 - 3	6	6
6	"Shaven"	"	" " " "	2 - 3	6	6
6	Albino TO	"	" " " "	12 - 24	4	1
36	" "	"	I.D. Different sites	3 - 12	29	1
2	"Shaven"	"	I.D. Back	5 - 8	2	2
8	Albino TO	Promastigotes	I.P.	-	-	-
16	" "	Amastigotes	I.P.	32 - 53	3	-
8	Hybrid	"	I.P.	32 - 44	3	3
2	"Shaven"	"	I.P.	28 - 32	2	2
6	Albino TO	"	I.C.	-	-	-
4	"Shaven"	"	I.C.	11 - 20	4	4
6	Hybrid	"	I.C.	-	-	-
6	Albino TO	"	I.V.	-	-	-
6	Hybrid	"	I.V.	12 - 18	3	3
2	"Shaven"	"	I.V.	12 - 16	2	2
8	Albino TO	"	I.T.	16 - 22	5	-
2	Hybrid	"	I.U. & I.D.	10 - 16	-	-
20	(Pregnant) (15 embryos)	"	?	-	-	-
20	Suckling Hybrid	"	S.C.	8 - 32	15	-
17	" "	"	I.P.	36 - 44	3	1
8	" "	"	S.C.	8 - 38	5	-
6	" "	"	I.P.	-	-	-
6	" "	"	Eye conjunctiva	-	-	-

Key: I.D. = Intradermal. I.P. = Intraperitoneal. I.C. = Intracardiac. I.V. = Intravenous. I.T. = Intratesticular.
I.U. = Intrauterine. S.C. = Subcutaneous

(c) Attempts to infect albino rats

Experiment 19: amastigotes and promastigotes of strain VI

12 albino rats, 4 - 6 weeks old, and 8 baby rats, 2 - 3 days old, were inoculated with amastigotes or promastigotes. The animals were inoculated intradermally, intraperitoneally or intracardially. They were checked for the development of the infection regularly. Table 5 summarizes this experiment.

Table 6 Results of attempts to infect albino rats with L.b. pifanoi

Type & No. of Rats	Type of inoculation	Site and mode of inoculation	Strain VI						General Remarks	
			Weeks after inoculation							
			1	2	4	8	12	16	32	
a) Adults										
4	4×10^6 pro.	Snout I.D.	-	-	-	-	-	-	-	No infection
4	4×10^6 pro.	Foot pad I.D.	-	-	-	c-	-	-	-	No infection
2	4×10^6 pro.	I.C.	-	c-	-	-	-	-	-	one animal remained (-)
2	4×10^6 pro.	I.P.		c-		c-			c-	
b) Baby										
8	0.01 ml. am.	Base of the tail I.D.								2 rats kept for 2 years remained (-)

pro. = promastigote

I.C. = Intracardiac inoculation

am. = amastigote

I.P. = Intraperitoneal inoculation

I.D. = Intradermal inoculation

c = culture test

- = negative

(d) Attempts to infect guinea pigs

Experiment 20: promastigotes and amastigotes of strains V1 and V2

16 guinea pigs, 6 - 8 weeks old, and 12 young guinea pigs, 1 - 7 days old, were inoculated intradermally, intraperitoneally or intracardially with L. b. pifanoi strain V1 or with L. b. pifanoi strain V2.

The animals were checked for the development of the infection 1, 2, 4, 8, 12, 16 and 32 weeks after inoculation. Some animals were kept for more than one year. Table 6 summarizes this experiment.

7/

Table 7 Results of attempts to infect guinea pigs with *L. b. pifanoi*
Strains V1 and V2

Type & No. of Guinea pigs	Type of inoculation	Site and mode of inoculation	Smears examined Weeks after inoculation							General Remarks
			1	2	4	8	12	16	32	
a) Adult										
4	4 x 10 ⁶ pro. V1	Snout	-	-	-	-	-	-	-	after 1 year (-)
4	0.05 ml. am. V1	Snout	-	-	-	-	-	-	-	after 1 year (-)
4	0.05 ml. am. V1	I.P.	-	-	-	-	-	-	-	-
4	0.05 ml. am. V2	I.C.	-	-	-	-	-	-	-	after 10 months (-)
b) Young Animals										
6	0.05 ml. am. V2	Snout I.D.	-	-	-	-	-	-	-	after 10 months (-)
4	0.05 ml. am. V2	Snout S.C.	-	-	-	-	-	-	-	-
2	0.05 ml. am. V2	Foot pad	-	-	-	-	-	-	-	after one year (-)

pro. = promastigote

am. = amastigote

V1 = *L. b. pifanoi* strain V1

V2 = *L. b. pifanoi* strain V2

I.D. = Intradermal inoculation

I.P. = Intraperitoneal inoculation

S.C. = Subcutaneous inoculation

I.C. = Intracardiac inoculation

Discussion

The results of the inoculation experiments revealed differences in the susceptibility of laboratory animals to intradermal inoculation of L. b. pifanoi.

Golden hamsters were the most susceptible with a 100% rate of infection, followed by mice with 68% infection rate. Guinea pigs and rats were completely insusceptible. Similar observations on the high susceptibility of hamsters to L. b. brasiliensis were made by Guimaraes (1951b) who obtained 95% positive results by inoculation intradermally. Convit (1958), Medina and Romero (1959) and Zeledon et al. (1969) obtained up to 100% infections in hamsters.

The high susceptibility of hamsters to Leishmania other than L. b. brasiliensis is well known and has been shown by Stauber (1955), Young et al. (1927) with L. donovani, Garnham (1962), Lainson and Strangways-Dixon (1964) and Coelho and Coutinho-Abath (1965) with L. mexicana, and Mayer (1929), Adler and Zuckerman (1948), and Mohiuddin (1952) with L. tropica.

The incubation period of the disease varied in the present study between two weeks and four months with a moderate inoculum. With very few ^{parasites} doses, the incubation period was as long as one year or more in some cases. This agrees with the observations of other authors (Zeledon, 1969). Individual

variation in the incubation period in the same group of animals was not uncommon, even when they were inoculated with the similar inocula and kept under the same conditions.

Different results were obtained using mice of different strains. The hairless and "shaven" mice showed very high susceptibility (100% infection while only 68.5% of the albino mice became infected. Mayer et al. (1949) successfully passaged strains of L. b. pifanoi in albino mice for several years, and Medina and Romero (1959) reported a 90% infection rate. Ercoli (1961), using mice inoculated with a diffuse strain, obtained 51 - 100% infections.

The susceptibility of mice to leishmanial infection obviously varies with the species or strain. Using L. tropica, Wenyon (1913, 1926) and Da Fonseca (1929) failed to infect mice while Leveran (1912), Row (1912, 1924), Gonder (1913), Adler and Theodor (1930), Kojevenkov (1941) and Mohiuddin (1952) all succeeded in infecting mice. Stauber (1962) considered mice as moderately susceptible to L. donovani, while rats were insusceptible.

Rats and guinea pigs failed to become infected with L. b. pifanoi, even after repeated reinoculations with culture as well as tissue forms. This was true when newly born animals as well as adults were used. The insusceptibility of rats agrees with the observations of Convit (1958) and Medina and Romero (1959); Strangways-Dixon and Lainsou (1962) did obtain infections in rats and guinea pigs using L. mexicana but described the infections as poor.

The successful infection of guinea pigs with L. donovani and L. tropica has been recorded by Dasgupta (1930) and with L. tropica and L. b. pifanoi by Ercoli and Coelho (1967).

The failure of guinea pigs to become infected with L. b. pifanoi has also been confirmed by Bray (personal communication), Convit (1958), Convit et al. (1962), and Medina and Romero (1959). The only record of experimental infection of guinea-pigs with L. b. pifanoi is that of Ercoli and Coelho (1967). These authors reported "the lesions which we have obtained with the leproid form of L. brasiliensis in mice and guinea-pigs are similar to those described after the inoculation of benign L. mexicana."

In view of the negative results obtained by all other authors including myself, and as Ercoli's paper included reports of experiments with L. enriettii, which runs a similar course in guinea-pigs to diffuse leishmaniasis, I suspected a printing error in Ercoli's paper. However, Ercoli (personal communication) confirmed that the guinea-pigs had been inoculated with L. b. pifanoi and added that intradermal inoculation on the snout resulted in infections with an incubation period of 4 - 6 weeks and metastasis after 6 - 8 months.

I therefore repeated the experiment and kept the guinea-pigs under observation for 18 months. None of them became infected.

Ercoli's unique positive results may have been due to the strain of

parasite that he used.

It is noticeable that, in studying the susceptibility of laboratory animals to Leishmania and following the course of infection, the observations of all investigators are usually based on the inoculation of these animals with massive doses of parasites without taking into consideration the size of the animal and its immunological capacity. This tends to give a uniform picture of infection of the different species and strains of Leishmania.

In the present investigation the course of the disease in susceptible animals was found to be influenced by several factors. These included the routes of inoculation, the size of the inocula, the site of inoculation and the source of the inoculum.

The highest rate of infection in both hamsters and mice was achieved by the dermal route of inoculation. This was to be expected as Leishmania is primarily a dermatropic parasite transmitted by the bite of Phlebotomus flies.

The first sign of a lesion was noticed at the site of inoculation as a small papule which gradually increased in size forming a nodule. Growth of the lesion was accompanied by loss of hair from the affected parts of the skin. The combined effects of growth of the lesion and hair loss gave the infected skin a firm, shiny, reddish appearance. Ulceration of the primary lesion was not uncommon and was observed in both hamsters and mice. Ulceration of the lesion was initially believed to be due to trauma, animals

with large nodular lesions on the snout possibly damaging the skin overlying the lesion by forcing their infected snout against the bars of the feeding basket. Further observations showed, however, that when the lesions were not subjected to traumatic damage, they still became ulcerated. Also, secondary lesions which developed on the snout, where they were exposed to the same pressure against the feeding basket as the primary ones, failed to become ulcerated. This indicated that ulceration is characteristic of the initial lesion. The tendency of the lesion to ulcerate is one of the basic characteristics of the classical type of cutaneous leishmaniasis. The phenomenon of ulceration of the initial lesion has also been noticed by Bryceson (personal communication) in guinea-pigs inoculated with L. enriettii.

In the classical type of L. tropica infection, the ulceration is believed to be due to cellular infiltration (mainly lymphocytes) around the infected area, and leading to its rejection. Pressure on the blood vessels of the involved area results in necrosis and leads to rupture and sloughing of the thin skin. This explanation of ulceration in L. tropica infection as a result of immunological response and host reaction in rejecting the infection is not applicable to diffuse leishmaniasis. Sections from the infected initial lesions of L. b. pifanoi showed little infiltration with lymphocytic cells, but there were aggregations of histiocytes full of parasites

forming "histiocytic granuloma".

A possible alternative explanation for the ulceration was the introduction of pyogenic bacteria from ulcerated lesions during the process of inoculation. This was investigated by the administration of antibiotics with the inoculum (400 I.U./1 ml. of penicillin and streptomycin). Ulceration of the primary lesion still occurred, which cast doubt on bacterial infection being responsible for the ulceration. This doubt was confirmed by the inoculation of suspensions of parasites deliberately contaminated with bacteria. Ulceration occurred at the site of inoculation within a few (2 - 3) days, but the ulcers healed within a few (2 - 3) weeks. The parasite established itself and the normal course of infection followed, resulting in further ulceration at about the same stage of development of the lesion as occurred in bacteria-free lesions (3 - 4 months).

It was noticed that the tendency of the lesions to ulcerate increased with increase in the dose of inocula. No ulceration was seen in animals inoculated with low doses of parasites.

The ulceration of the initial lesion was usually complicated by secondary bacterial infection. The lesion slowly discharged a small amount of pus and exudate containing dead cells. As it dried, this formed a crust which, on falling or being scratched off, uncovered a deep ulcer. The margin of the ulcerated lesion remained firm and reddish and was packed with histiocytes full of parasites.

Metastasis

This is the dissemination of the parasite from the initial primary lesion to other parts of the body. One or more lesions appear usually on the hairless parts of the body, e.g. foot pads, snout, eyelids, ears, penis or vulva, and base of the tail. The lesions appear as heavy palpable nodules and grow slowly into nodular lesions which may only rarely ulcerate. The size of the lesion depends on the part of the body on which it appears. It reaches maximum size when it is formed on the nose. When on the foot pads it involves all the digits which lose their distinct appearance and become stump-like. The metastasized lesion is very similar to the initial one before it ulcerates.

Metastasis was more common in hamsters than in mice. Amongst the mice, metastasis was most common in hairless and "shaven" mice. In fact, 100% showed it, whereas only 18.9% of albino mice showed metastasis.

Satellite lesions which are small lesions around the primary lesion
 → Kerdal-Vegas,
 (Convit/1965) appeared in two "shaven" mice but not in hamsters or albino mice. There is strong evidence to suggest that the extent of metastasis is influenced by the available hair-free skin area of the infected animal. This was confirmed by the success of Bray (personal communication) in initiating L. enriettii infection in guinea-pigs inoculated intradermally on their backs by shaving the hair from the site of inoculation for three consecutive weeks.

^{et al.} Pereira (1958) noticed the failure of the parasite to cause infection when inoculated on the back or belly of the guinea-pigs. Zeledon ^{et al.} (1967) also failed to infect hamsters inoculated on the back or belly with L. b. brasiliensis.

Shaven mice inoculated on their backs with L. b. pifanoi developed lesions within 5 - 8 weeks after inoculation while albino mice inoculated failed to do so. When the hair was clipped from the area of inoculation for three successive weeks after inoculation, the parasites were seen in smears prepared from the site of inoculation, but when the animals were left unclipped until later on, none of them developed lesions.

The variations in the response of "shaven" mice and albino mice and between normal albino mice and clipped mice possibly shows the effect of the hair on the course of infection and on survival of the inoculated parasites. This is most probably mediated by the temperature, the higher temperature of the hairy parts of the body appearing to inhibit the growth of the parasite (Zeledon ^{et al.} 1965 and 1969; Hayatee, 1970).

Occasionally the secondary lesions coalesce, forming a single large nodule. The metastasis progresses until it involves all the hairless parts of the body. With most animals, this limits the development of lesions to the snout, ears, foot pads, base of the tail, the tail, eye-lids, etc., while in "shaven" and hairless mice, most of the skin is involved,

resulting in severe disfigurement of the animal. However, the general health of the infected animal and its appetite do not appear to be affected.

The mucocutaneous membrane of the oronasopharynx, the genital organs and anal region never become involved, which differentiates the diffuse type of infection with L. b. pifanoi from the classical type of human South American mucocutaneous leishmaniasis (Espundia) caused by L. b. brasiliensis which sometimes gives rise to mucocutaneous involvement in experimental animals (Guimaraes, 1951b). However, involvement of the mucocutaneous membranes alone cannot be considered as a reliable factor in differentiating the causative species of South American leishmaniasis since this may not be a stable strain characteristic. For instance, a similar picture of the spread of the disease to the mucocutaneous membranes has been noticed by different authors in cases of visceral or dermal leishmaniasis in the Old World (Kirk, 1945; Manson Bahr, 1964) which constitutes a rare deviation from the normal pattern.

The internal organs and blood remained clear of the parasites. Some South American workers use this criterion to differentiate L. b. pifanoi from the classical form of L. b. brasiliensis. Zeledon ^{et al.} (1969) found 69.7% visceralization in L. b. brasiliensis (O.CR strain from Costa Rica) in hamsters, while in mice the infection ran a more benign course, with a longer incubation period. Involvement of the viscera (mainly spleen), which

contained scattered parasites, was noticed in some mice.

In the present work the parasite was not isolated from the internal organs (even from animals with lesions almost covering the whole surface), except in mice inoculated with irradiated parasites. This topic will be discussed in Part V of this thesis.

Previous workers who have studied diffuse cutaneous leishmaniasis in hamsters or mice have failed to find the parasite in any internal organs by smears or culture (Mayer et al., 1949; Convit, 1958; Convit et al., 1965; Medina and Romero, 1959; Hayatee, 1969.)

The failure of the parasite to invade the viscera is probably due to the high temperature of the internal organs compared to that of the skin. This hypothesis is the main subject of Part III of this thesis.

Site of intradermal inoculation

The critical factor determining the success of the inoculation was whether the site of inoculation was covered with hair or not. All animals inoculated on the back or inner side of the thigh did not become infected. The only exception was a mouse which was inoculated on the inner thigh and developed a lesion on the base of the tail. This was probably due to some parasites finding their way into the blood which then carried them to the base of the tail where they became established because of the lower

temperature there. This agrees with the observations of Adler and Theodor (1930), who reported secondary infection far from the site of inoculation of the parasite in hairy parts of the body, and also with the observation of Pereira ^{et al.} (1958); de Castro and Pinto (1960) and Zeledon ^{et al.} (1965, 1969).

Inoculation into different hairless parts of the body was equally successful. The maximum size was attained by lesions on the snout, followed by those on the base of the tail and the foot pad. The large size attained by lesions on the snout and the base of the tail interfered with the processes of respiration and defaecation respectively.

Intraperitoneal inoculation

Intraperitoneal inoculation of hamsters and mice with promastigotes of L. b. pifanoi did not result in infection. This is probably due to the sudden change in the biological, physiological and biochemical conditions in the environment of the parasites, resulting from such inoculation. The promastigotes, cultivated at room temperature (20 - 25°C) in an artificial medium, when introduced into the peritoneum, meet with a sudden rise in temperature to 36 - 38°C. The biochemical make-up of the peritoneal fluid may not provide the parasites with the optimum conditions for establishing themselves and growing.

Stauber (1962) estimated that only one out of every 3,000 amastigotes of L. donovani introduced intraperitoneally survived to initiate infection in hamsters.

Intraperitoneal inoculation of amastigotes gave 28.5% infection in the scrotum of mice and 33.3% in hamsters after an incubation period of 10-13 months. None of the animals showed visceral infection. These results, supported by the observations of Guimarães (1951d, 1951e) and Zeledon^{et al} (1969), contrast with those of Convit (1958) and Medina and Romero (1959), who failed to infect the animals by the intraperitoneal route.

None of the animals in the present studies showed initial lesions on the snout, which contradicts the findings of Zeledon^{et al} (1969).

The high percentage of peritesticular involvement was probably due to contamination of the scrotum sac through the inguinal canal which in rodents remains open after the testicles have descended. The lower temperature, compared to that in the peritoneal cavity, allowed the parasite to establish itself and develop a lesion. This was followed by the development of secondary lesions on other hairless parts of the skin.

The first sign of infection of the scrotum was thickening of the skin, which became leathery (similar to elephantiasis). The parasite was found in the deep layer of the skin and involved the tunica vaginalis.

The survival of the parasite within the scrotum was probably due to the lower temperature of that organ. The temperature of the scrotum was found to be 32.2 - 33.8°C.

It is known that if the testicle does not descend, the sperm become non-viable because of the raised temperature of their surroundings (Crew, 1922; Bloom and Fawcett, 1962). It would be of interest to inoculate mice, in which the testicles are surgically prevented from descending, with L. b. pifanoi to test whether the parasite would develop in the testicles at a higher temperature.

Involvement of the scrotum with L. tropica had been reported previously by Laveran (1915), Row (1924) and with L. donovani by Hindle and Thomson (1928), Young and Hertig (1927).

The infection of the scrotum by L. tropica, L. b. brasiliensis and L. donovani is probably the result of systemic dissemination of the parasite, as amastigotes are found in the liver, spleen, and circulating in the blood. It may be argued that intraperitoneally inoculated L. b. pifanoi may likewise invade the blood and fail to settle in the internal organs because of their unfavourable high temperature, but succeed in becoming established in the cooler skin of the scrotum. This appears unlikely for two main reasons:

1. Parasitized wandering macrophages in the blood stream would be carried to the reticuloendothelial system of the liver, spleen, and mesenteric lymph nodes where they would become trapped. In the case of L. b. pifanoi the amastigotes in these regions would become destroyed and filtered out of the blood and therefore would be unlikely to reach the scrotum.

2. Had the infected macrophages survived this filtration process and remained in circulation, it is difficult to explain why they always found their way to the scrotum, the only place where such lesions were observed. It is interesting to note that when massive numbers of parasites were injected intracardially the lesions were randomly distributed in parts of the skin like the snout, foot pads, ears and tail, where the lower skin temperature allowed the parasite to become established.

Zeledon^{et al} (1969) inoculated mice and hamsters intraperitoneally with L. b. brasiliensis and found the first lesion on the snout. Successful intraperitoneal inoculation was achieved by:

1. Using a large amount of virulent inoculum, or
2. Repeated reinoculation. This was first demonstrated by Adler and Halff (1955) when infecting guinea-pigs by the intraperitoneal route.

Intrasplenic inoculation

In the present work all of the animals inoculated intrasplenically with amastigotes or promastigotes of L. b. pifanoi failed to become infected. The inability of the parasite to establish itself in the spleen even after being introduced directly into the organ supports the fact that infection could not be obtained by intraperitoneal inoculation either.

The failure of both forms of the parasite to infect the spleen is probably due to the effect on the parasite of the relatively high temperature of the spleen, which ranges between 37.2 - 38.2°C (the skin temperature of the nose ranges between 27.2 - 29°C at room temperature of 20°C). Another contributory factor may be the intense immunologic activity of the spleen in getting rid of parasites.

It is more likely that the parasite in the spleen is destroyed by a combination of the effects of both factors.

The high temperature of the spleen can inhibit the growth and rate of multiplication of the parasite. This is known from experiments on the thermal effect on L. b. brasiliensis and L. enriettii in culture (Zeledon, et al., 1965; de Castro and Pinto, 1960).

Thermal reduction of the rate of division and viability of the parasites renders them more vulnerable to the antagonistic action of the splenic tissue. The number of parasites that can initially be inoculated

into the spleen is limited by the small size of the organ, and the expulsion of part of the inoculum by bleeding.

It was thought that parasites isolated from the regional lymph nodes might have been naturally selected for certain characters enabling them to survive in the reticuloendothelial system. This hypothesis was tested by inoculating such parasites into the spleen. The failure of these to become established in that organ did not support the idea. Only one animal of this group became infected, a lesion appearing in the foot pad. This was considered to be a result of contamination of the circulating blood.

Intracardiac and intravenous inoculation

The positive results obtained by intracardiac inoculation of the "shaven" mice and intravenous inoculation of the hybrid mice indicate the active role of the blood in carrying the parasites from the initial lesion to other parts of the body. The Leishmania parasites are probably carried to other suitable sites on the body surface by wandering macrophages. Although all attempts to isolate the parasite from the heart blood of heavily infected animals failed, successful infection by intravenous or intracardiac inoculation proves that the vascular system can play a part in spreading the parasite all over the body. The failure of other workers (Convit, 1958; Convit et al., 1962; Convit and Kerdel-Vegas, 1965; Modina and Romero 1959) to infect animals

by these routes may be due to the following factors:

1. The low dose of parasites used by them.

For the infection to become established the inoculated parasites must be sufficiently numerous for some to survive long enough to reach hairless parts of the body suitable for the development of a lesion.

2. The choice of experimental animals

All previous workers used hamsters and albino mice. The choice of shaven mice and hybrid mice in the present work in addition to hamsters and albino mice showed that the two former strains were susceptible to infection by intracardiac or intravenous inoculation, whilst albino mice and hamsters were insusceptible. The shaven mice had a double advantage in the present work, as they offered the parasites an enormous area of naked skin, which made the chance of the parasites reaching a suitable cool, hairless part of the body very much greater than it would have been in furred rodents.

Shaven and hybrid mice proved to be particularly susceptible to infection with L. b. pifanoi.

The successful infection with L. tropica obtained by intravenous inoculation in mice (Gonder, 1913; Sergent, 1915) may be explained by less strict tissue specificity of this species compared to L. b. pifanoi; L. tropica and L. mexicana become established in the liver and spleen which

then serve as a source for further invasion of other parts of the body.

Intrauterine inoculation

The failure of infection to develop in the foetus after inoculation in utero may have two explanations:

1. The inoculation was performed through the wall of the uterus and the site of inoculation could not therefore be pin-pointed. It is likely that the inoculum was introduced into the visceral organs and not into the skin, the ideal site for the development of the parasite.

2. The parasites which may have found their way into suitable sites, e.g. skin or peritoneal cavity, were probably discouraged from establishing an infection by the high environmental temperature of the foetus inside the uterus.

It is thought that mothers infected with L. tropica do not confer immunity on their unborn young. As Garnham and Humphrey (1969) pointed out, if passive immunity could be transferred from mother to offspring, none of the children in the Middle East would be susceptible to L. tropica infection.

In the present work, the mother was inoculated only 3 days before the birth of the young, which is too short a period for her to have formed any effective antibody, so that the possibility of passive transfer of immunity can be discounted.

The source and age of the inoculum

The source and age of the inoculum were important features in influencing the infectivity of the parasite in experimental animals. Promastigotes maintained in culture for several months (8 months) lost their ability to infect mice or hamsters.

Similar observations were made by Fuller and Geiman (1942) on the infectivity of L. b. brasiliensis in hamsters. A strain maintained in NNN medium for 3 years failed to infect hamsters. The same strain passaged into chick embryos regained its infectivity.

The variation in the ability of the parasite to infect experimental animals is the result of prolonged cultivation under artificial, though adequate, conditions.

The maintenance of parasites in abnormal hosts or cultures or by repeated syringe passage often leads to abnormalities in the infectivity and behaviour of the parasite in the normal host or vector. Thus Trypanosoma rhodesiense loses its infectivity to Glossina after repeated blood passage in experimental animals (Willet & Fairbairn, 1959; Duke, 1934); Plasmodium chabaudi loses its ability to undergo gametogony and sporogony in the mosquitoes after prolonged syringe passage from mouse to mouse (Wéry, 1967).

Amastigotes were invariably more virulent than promastigotes. Thus more animals became infected in a shorter period of time and larger

lesions were produced when the inoculum contained amastigotes rather than promastigotes.

The amastigotes are transferred directly from one animal to another and, unlike the promastigotes they do not have to adjust to great changes in the biochemistry of their environment. The promastigotes, on the other hand, have to withstand severe physiological changes. Being adapted to living in a cell-free medium at room temperature, they suddenly have to adjust themselves to live and reproduce at a higher temperature inside living cells - the macrophages - the primary function of which is to clear up foreign bodies. Faced with these drastic changes in the temperature and the biochemical environment and with the immune response of the host, it is not surprising that the majority of the promastigotes fail to survive (Zuckerman, 1953; Re y, 1943).

The mortality rate of the promastigotes is probably very much reduced when they are introduced into the mammalian host by the bite of the sandflies. The number of promastigotes injected by a fly is hardly more than a few hundreds. The efficiency of these few parasites in establishing an infection is remarkable and may be due to three main reasons:

1. The promastigotes in the sandfly are maintained inside a natural biological vector, with a long evolutionary association between parasite and fly. The medium in the insect probably favours the maintenance of vigour of the strain.

2. Transference of the promastigotes from fly to mammal is probably a less drastic change than that following syringe passage from a cell-free media.

3. The majority of the promastigotes during natural transmission of the parasite are injected by the fly into the most suitable region of the body - namely the dermis of hairless parts of the skin.

PART III - THE EFFECT OF ENVIRONMENTAL TEMPERATURE
ON THE COURSE OF CUTANEOUS LEISHMANIASIS

Review of relevant literature

The effect of environmental temperature on the course of infection with micro-organisms was studied as early as 1878. Pasteur et al. (1878) succeeded in infecting birds with Anthrax bacilli to which they were not normally susceptible by cooling the birds in cold water for a few days. The chickens died within a short period from severe infection. Gibier (1882) found that frogs did not become infected with Anthrax bacilli inoculated into the dorsal lymph sac when kept at room temperature or in the refrigerator, but they died from severe bacteremia when kept at 37°C. In 1894 Diendonno isolated a strain of Anthrax which grew well at 12°C. This strain killed frogs when they were inoculated and kept at low environmental temperatures.

Wolf (1935) was able to abort poliomyelitis infections in monkeys by hyperpyrexia induced soon after inoculation and maintained, at high temperature for a long time. Lillie et al. (1937) showed that raised environmental temperature increased the intensity of the brain reaction in mice infected with the virus of St. Louis encephalitis.

Sarracino and Soule (1941) concluded that the human influenza (A) virus was not affected by heat, cold, fatigue or alcohol. Sulkin (1945), on the other hand, found a slight effect of environmental temperature on the mortality of Swiss mice infected with this virus. Animals kept at a high environmental temperature (35°C) showed significantly less pulmonary involvement than those kept at a lower temperature (4°C).

Thompson and Parker (1941) have shown that, at high external temperatures, infection of rabbits with Myxoma virus was checked, while at low temperature the course of the infection was not influenced.

Ross and Williams (1910) associated the high incidence of parasitic infection in the tropics with the high environmental temperature prevalent in such areas. In other words they stated that parasites are accustomed to living in hosts which themselves live under conditions favourable to the parasites. They observed that cases of malaria were treated more effectively in the cooler seasons than in the very hot season. They noticed too that human trypanosomiasis occurred in persons in very hot climates and suggested that the disease might possibly be retarded if such persons were removed to cold areas. They also showed experimentally that guinea pigs inoculated with Trypanosoma gambiense showed delayed development of the disease under cooler conditions. Ross and Thomson (1910) prolonged the life of experimental animals inoculated with Trypanosoma rhodesiense

by treating them with atoxyl and keeping them in a cold room. The same authors tried to treat a case of human trypanosomiasis by keeping the patient at 4°C but the experiment had to be stopped because of other complications.

Kalbuchov and Levinson (1936), working on the effect of cooling on Trypanosoma equiperdum in bats, found that cooling bats Nyctalus and Pip-strellus nathusii, 3 - 5 days after their inoculation with T. equiperdum resulted in the disappearance of trypanosomes from the blood. Bats cooled immediately after inoculation did not become infected; rewarming the animals 2 - 4 days after the parasite had disappeared did not induce relapses. Resistance to reinfection was not observed.

Kolodny (1940), working with Trypanosoma cruzi infection in rats, found that low environmental temperatures (4.5 - 7.2°C) generally resulted in parasitaemias several times more intense than those usually seen in animals of the same age maintained at ordinary room temperatures (21 - 24°C). High environmental temperatures (32 - 35°C) resulted in a slight increase in the resistance of young rats to infection, with very few parasites detectable in their blood.

Stauber (1939) showed that exposure of canaries infected with Plasmodium cathemerium to higher environmental temperatures disturbed the parasites' synchronicity or caused a shift in the time of segmentation. The

influence was greatest on the young trophozoites.

Boyd (1929) prolonged the asexual cycle of Plasmodium cathemerium in a canary to 28 hours by imposing an artificial 28-hours day. He disrupted the synchrony of the parasite by continuous illumination. Stauber (1953) interpreted Boyd's observations as a result of temperature variation associated with the degree of host activity when exposed to light or darkness. This was supported by striking differences in the body temperature of canaries during day and night (Huff, 1939).

Rodhain (1951) found that hibernating marmots maintained toxoplasma parasites for 3 months but died with severe parasitaemia 18 days after waking up; on the other hand the control marmots which were kept in the active stage died within 22 days after inoculation.

Vignat (1914) successfully treated a case of oriental sore of six years' standing by single exposure to hot air (750°C) applied after local anaesthesia had been introduced.

Stauber (1953) obtained variable results in hamsters infected with Leishmania donovani and kept at high environmental temperature ($34 - 35^{\circ}\text{C}$), with apparent cures in two out of five groups of the animals. Baker and Gutierrez (1958) succeeded in curing dermal infection of Leishmania enriettii in guinea-pigs by using moist heat. The treatment resulted in cicatrization of the ulcers: they also obtained similar results in human cases

infected with L. b. brasiliensis on the ear.

Pereira et al. (1958) studied the effect of environmental temperature on the course of Leishmania enriettii infection in guinea-pigs in the light of their previous observation on the metastasis of the parasite to the cooler parts of the body only. None of the animals inoculated with the parasite and kept at high temperature (35 - 36.5°C) showed any lesions and, when animals with established lesions were kept at a higher temperature the lesions healed. Garnham and Lewis (1959) found that 27 out of 33 cases (82%) of cutaneous leishmaniasis in British Honduras had lesions on the ear, and Lainson and Strangways-Dixon (1963) explained the high incidence of ear infection with L. mexicana on the basis of the lower temperature of the ear compared to the rest of the body.

The growth of cutaneous species of Leishmania in tissue culture is limited by the temperature; growth occurs only between 32° and 35°C (Wallace and Hamilton, 1946; de Castro and Pinto, 1960; Zeledon et al., 1965).

The tolerance of high temperature by L. donovani, L. tropica and L. b. brasiliensis is very limited. Senekji (1941) found that 40°C for 30 minutes destroyed all the parasites. Bryceson (1970) noticed a remarkable improvement in the skin infection of 3 patients suffering from Ethiopian diffuse cutaneous leishmaniasis when they became infected with measles.

"By the third day of the fever, the leishmanial nodules were shrinking and within a few more days most of them had melted away, leaving the overlying skin intact, wrinkled, darkened and disquamating. Parasites could not be found in these lesions and the histology showed collapse of the previous structure and many dead cell nuclei. Not all the lesions disappeared completely, however, and these residual foci soon began to spread."

The present work was an investigation of the effects of the environmental temperature on the course of the infection in mice with diffuse cutaneous leishmaniasis with reference to:

1. Metastasis of the parasite.
2. Visceral invasion by several species of Leishmania.

Present work

- (a) The effect of environmental temperatures of -15°C on the course of cutaneous leishmaniasis in mice

Experiment 1: amastigotes of strain V1

18 hybrid mice ("shaven" x albino) and 12 albino mice were used in this experiment. The hybrid mice were each inoculated with 0.05 ml. of a medium dose of amastigotes (10 in the snout and 8 in the base of the tail).

The albino mice were inoculated in the snout with 5×10^6 organisms.

The animals were left at room temperature for 24 - 48 hours to give the parasite sufficient time to establish itself in the host.

The animals were gradually adapted to the low temperature

(Ogle and Mills, 1933) as follows:

1. They were exposed to 4°C in the refrigerator for progressively increasing periods (2, 4, 8 and 16 hours per day), then kept there continuously for 6 days.
2. The animals were caged separately to prevent them huddling together and thus increasing their body temperature.
3. Animals were supplied with sufficient food (rich in carbohydrate and fat) and water.
4. Animals acclimatized to 4°C were further adapted to temperatures below 0°C by transferring them into a cabinet with a temperature regulatory system. (Teddington Type QR -5°C to -30°C).

The animals were adapted to -5°C by keeping them at this temperature for 4, 8, 12 and 20 hours daily for 4 days, then for 23 hours per day for 6 months, during which period the cabinet temperature was gradually lowered to -15°C . The animals were very active during the first few hours of exposure, playing with their exercise wheel and consuming a lot of sunflower seeds. The problem of drinking water was solved by keeping ice

cubes in each cage. This was more practical than giving them water every few hours.

The animals were removed to room temperature for 10 - 30 minutes each day during which time they were examined for the development of lesions by the preparation of smears. Animals which survived for 6 months or more were then returned to room temperature.

Smears were also prepared from dead frozen animals from the site of inoculation. 4N cultures were inoculated with material from the site of inoculation.

The body temperature of mice was measured by means of a thermocouple and potentiometer (see General Materials and Methods).

Results:

The rectal temperature of animals kept at -15°C dropped to $35.0 - 36.5^{\circ}\text{C}$; in one mouse it fell to 18°C . The skin temperature of the hairless parts of the nose fell to $2.1 - 3.6^{\circ}\text{C}$. Table 7 shows the temperature of different parts of the body.

Frostbite was very common on the tails and ears of these mice, and was often followed by necrosis (Fig.23).

Lesions did not appear on animals kept continuously at -15°C . (There was a very high mortality rate because of severe effects of the cold on unadapted animals.) When the mice were removed to 4°C or to room



Fig.23 Frost bite of the tail of albino mice maintained for six months at -15°C .

temperature, lesions appeared 2 - 3 weeks after their removal. Development of the lesions was similar to the course of development in mice kept at room temperature. The nodules reached 10 mm. in diameter in 6 months. They were reddish in colour and congested, and smears taken from the nodules showed the presence of a large amount of blood. Ulceration was noticed in 6 animals (2 albino and 4 hybrid). Metastasis did not occur in any of the animals during their incubation at -15°C , but in animals kept for 2 months at -15°C , metastasis was noted 6 months after removing them to room temperature. The tails became swollen and necrosis occurred because of traumatic pressure of the nodule on the tail blood vessels. Metastatic lesions developed all over the body - foot pads, snout, ears, eyelids, scrotum and penis.

The mortality rate was very high when animals were transferred directly to -15°C . Six hybrid mice were frozen when they were left over night. No parasites were detected at the site of inoculation, either by examining smears or by culturing material in 4N medium.

Smears from infected animals showed large numbers of parasites, some of which had large vacuoles.

(b) The effect of environmental temperature of 4°C on the course of cutaneous leishmaniasis in mice and hamsters

Experiment 2: amastigotes and promastigotes of strain V1

Animals were adapted to 4°C in the same way as in the previous experiment. 3 to 4 animals were kept together in one cage.

Six hybrid mice ("shaven" x albino) were each inoculated with 0.05 ml. of a "medium" dose of amastigotes in the base of the tail.

Six albino mice were inoculated with 5×10^6 promastigotes at the base of the tail and 6 other albino mice received a similar dose in the snout.

Four hamsters were inoculated intradermally at the base of the tail with 0.05 ml. of a "medium" dose of amastigotes and 2 hamsters received 0.1 ml. of a "heavy" dose of amastigotes intraperitoneally.

Results:

The animals survived well and the mice even bred at this temperature. They remained in good condition and withstood living under these conditions for 6 months. They gained some weight and their fur looked denser and longer. Their activity was increased as well as their consumption of food and water.

$^{\circ}\text{C}$ /
The temperature of hairless parts of the body dropped to 23.7 - 26.2 although the rectal temperature was only 1 - 2 $^{\circ}\text{C}$ below normal temperature. Table 7 shows the temperature of different parts of the body at 4 $^{\circ}\text{C}$.

The first sign of a lesion appeared two weeks after intradermal inoculation and after 3 - 4 weeks in the others. The lesions ulcerated in one mouse - smears taken from this lesion showed secondary bacterial infection but no amastigotes were seen. The growth of the lesion followed the same pattern as that at room temperature. Metastasis did not occur during the period of maintenance at 4 $^{\circ}\text{C}$. The nodules were firm and congested - smears showed large numbers of amastigotes.

None of the hamsters inoculated intraperitoneally developed lesions during their period of maintenance at 4 $^{\circ}\text{C}$. Peritoneal aspirates did not reveal parasites either in smears or in culture. Three months later the hamsters were reinoculated intraperitoneally with a heavy dose of amastigotes and examined for the presence of parasites in the spleen by biopsy 2 months later. No parasites were detected. Four months after their removal to room temperature the hamsters developed lesions in the scrotum and these then metastasized to the hind foot pad and to other hairless parts of the body. When the hamsters were killed, smears and cultures from their heart blood, spleen and liver were examined for the presence of the parasites, but none were seen.

(c) The effect of environmental temperature of 35 - 36.5°C on the course of cutaneous leishmaniasis in mice

Experiment 3: amastigotes of strain V1 and L. mexicana

Eight hybrid mice were inoculated intradermally in the snout with 0.05 ml. of a "medium" dose of amastigotes of strain V1.

Six albino mice were inoculated in the snout with 5×10^6 promastigotes of strain V1.

Four albino mice were inoculated with 0.1 ml. of a heavy dose of L. mexicana, strain L11.

The animals were easily adapted to 30°C. They were transferred from room temperature to 30°C directly and continuously and were then transferred to 35 - 36°C, and were kept at this temperature for progressively increasing periods of 4, 8, 12, 16 and 20 hours per day. They were then kept for 3 - 5 weeks under these conditions.

Two of the hybrid mice were killed in the first week and 1 albino mouse inoculated with L. mexicana was killed after three days. Smears and cultures were prepared from the site of inoculation.

The animals were supplied daily with food and water and examined weekly for the development of lesions.

The cured animals were kept under observation for more than six months after they were removed to room temperature of 22 - 25°C. They were tested for the presence of the infection at regular intervals in the usual way by smears and cultures.

Results:

The adapted animals became sluggish and their food consumption was reduced. The animals looked thinner and lost some weight. The rectal temperatures of the mice rose, reaching 40°C in some cases. Table 7 shows the body temperature of different parts of the body of animals kept at 35 - 36°C.

The 2 animals killed within the first week did not show any parasites in culture or smears, while the animal from the group inoculated with L. mexicana which was killed after 3 days showed amastigotes in smears.

The animals inoculated with L. b. pifanoi all remained uninfected after they were removed to room temperature.

The animals inoculated with L. mexicana showed lesions during the first week but these subsided. One animal was killed after 2 weeks and parasites were seen in smears from the site of inoculation.



Fig.24 Three hybrid mice (on the right) showing nodular lesion of L. b.pifanoi on the snout. Three hybrid mice (on the left) inoculated with the same inoculum as those on the right but maintained at 36.5°C soon after inoculation, showing absence of lesions.

Table 8. The relation of environmental temperature to the temperature of different parts of the body

Part of the body	Environmental temperature			
	-15°C	4°C	22-25°C	35-36.5°C
	Temperature °C			
Rectum	33-36.5	35-37°C	35.9-37.2	38.8-40
Base of the tail	5-6.8	27-28.2	30.6-31	35.6-35.9
Foot pad	3.2-4	17-23.7	26.2-27	33.5-35.9
Snout	4.2-6	19-26.2	24.5-26	32.6-33
Back	29-30.5	32-32.6	35.6-36.5	37-37.5
Liver	Not measured		37.2-38	Not measured
Spleen	"	"	37.2-38.2	" "
External genitalia	"	"	31.7-32.8	" "

All the animals infected with L. b. pifanoi were negative and none developed lesions when kept for 4 weeks at 35° - 36.5°C; they remained negative even after they were transferred to room temperature.

The 10 control mice which were kept at room temperature developed lesions within 2-- 3 weeks and these reached 7 - 9 mm. in diameter 4 months after inoculation.

Experiment 4: amastigotes of strain VI

The following groups of animals were used:

1. Six hybrid mice ("shaven" x albino) with single nodular lesions and 3 with single ulcerated lesions which had been inoculated with 0.05 ml. of a "medium" dose of L. b. pifanoi 6 months earlier.
2. Five hybrid mice with 2 - 6 diffused nodular lesions.
3. Three albino mice with single lesions, all of the ulcerated type.
4. Three "shaven" mice, 2 with a single nodular lesion and 1 with 2 diffused lesions.

These infected animals were adapted to high temperatures in the same way as in the previous experiment.

They were kept at 30°C for 7 to 10 days and then were exposed to 35 - 36°C continuously for 24 hours for 17 - 35 days. Smears were taken from their lesions every six hours, fixed and stained with Giemsa's stain. Tissues from killed animals were fixed on Carnoy's fixative or 10% formol saline. 4 µm thick sections were cut and stained with haematoxylin and eosin for histopathological studies and by the Giemsa-collophonium method (Bray and Garnham, 1962) for parasitological examination.

The size of the lesions was measured once a week with a fine scale ruler.

Results:

The infected animals, before exposure to high temperature, had firm active lesions, reddish in colour, shiny and tender. Smears showed very large numbers of amastigotes in the histiocytes. No changes were noticed in the mice kept at 30°C for 7 - 10 days. Clinically the lesions at 30°C did not show any differences from the control ones, but when the animals were kept at 35 - 36.5°C for 18 hours the colour of the lesion became yellowish and softening started in the centre of the nodules (Figs. 25, 26, 27, 28, 29, 30 and 31). The nodules were full of unparasitized histiocytes and some contained disintegrated parasites (Figs. 33, 35 and 36).

The density of the parasites in the histiocytes diminished gradually. The organisms disappeared completely within 26 - 39 hours leaving behind

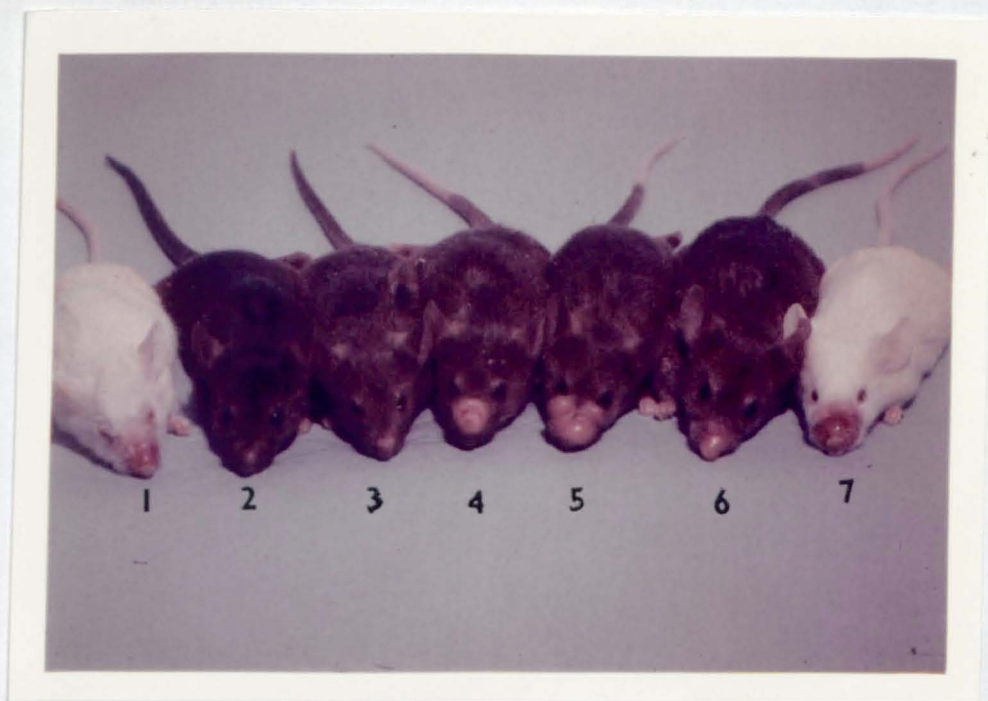

Fig.25 Mice inoculated with similar doses of *L. b. pifanoi*. Mice 1, 2 and 3 showing small healing lesions following maintenance at 35°C-36.5°C for 3 weeks. Mice 4, 5, 6 and 7 control mice showing well developed lesions following maintenance at room temperature.

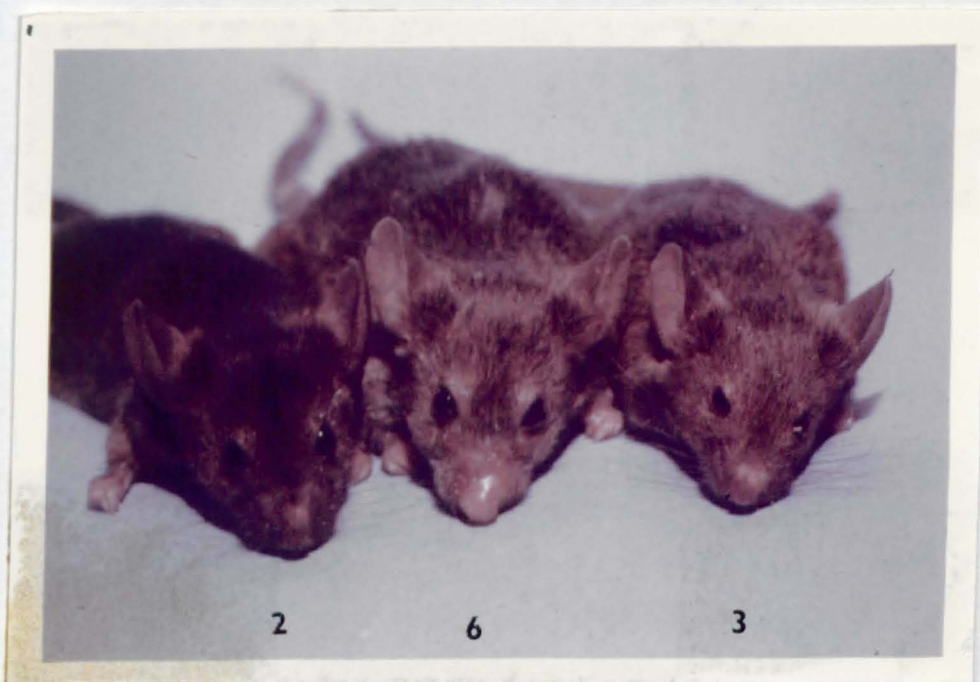


Fig.26 Higher magnification of the lesions on the snouts of mice 2, 3 and 6 on the previous photograph.

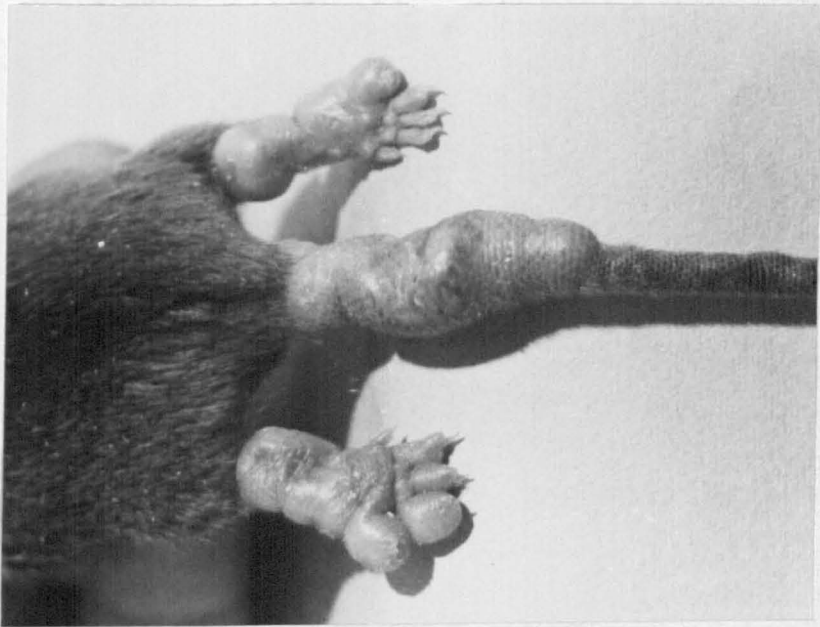


Fig.27 A hybrid mouse showing diffuse cutaneous leishmaniasis on the tail and hind limbs.

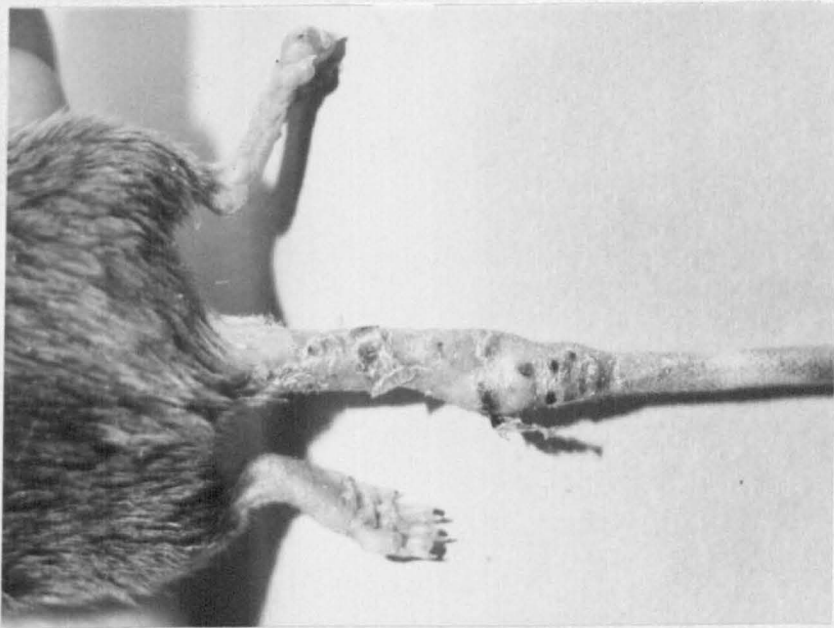


Fig.28 A hybrid mouse with diffuse cutaneous leishmaniasis on the tail and hind limbs after exposure to 35°C for 3 weeks. Marked shrivelling and healing of the lesions is observed.

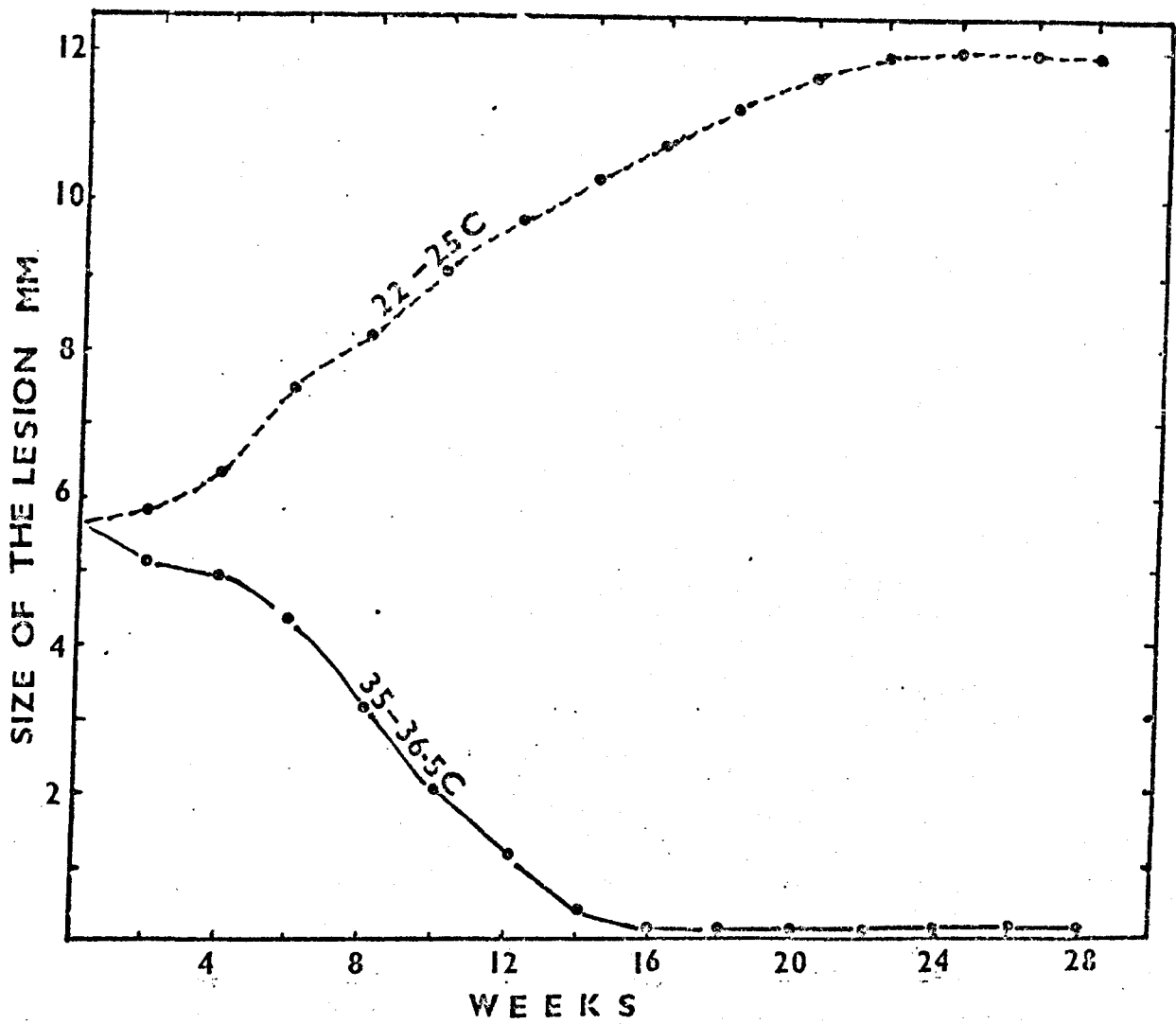


Fig.29. Effect of environmental temperature on the growth of six month old lesions of cutaneous leishmaniasis in mice.

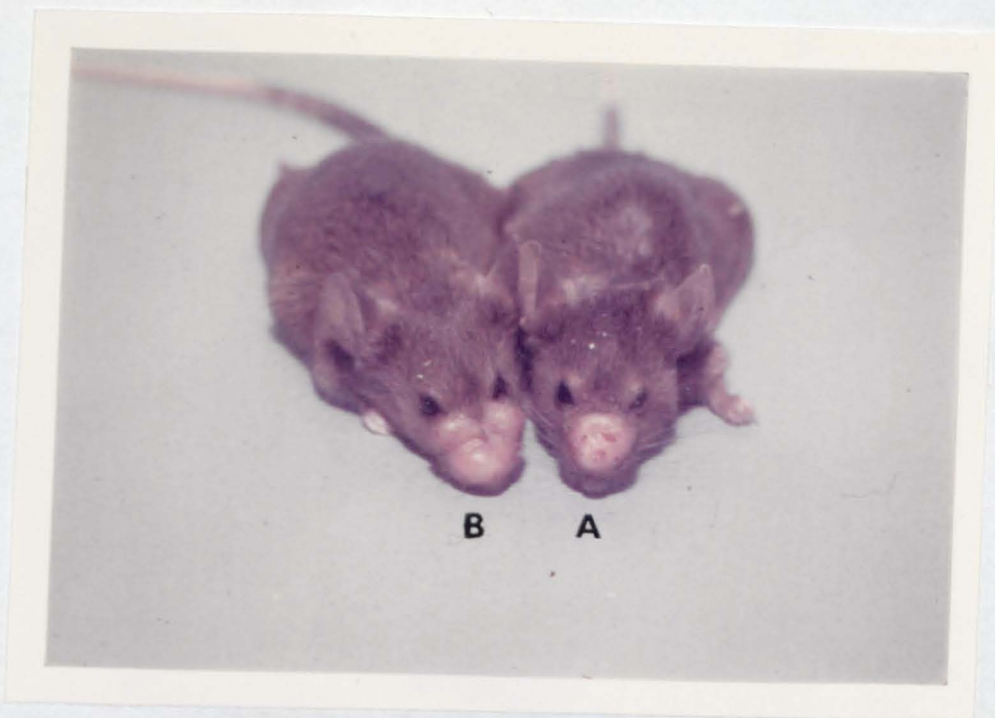


Fig.30 Mouse (A) showing a decrease in the size and loss of the shiny appearance of the lesion on the snout following exposure to 35°C for 48 hours, compared to mouse (B) untreated control.

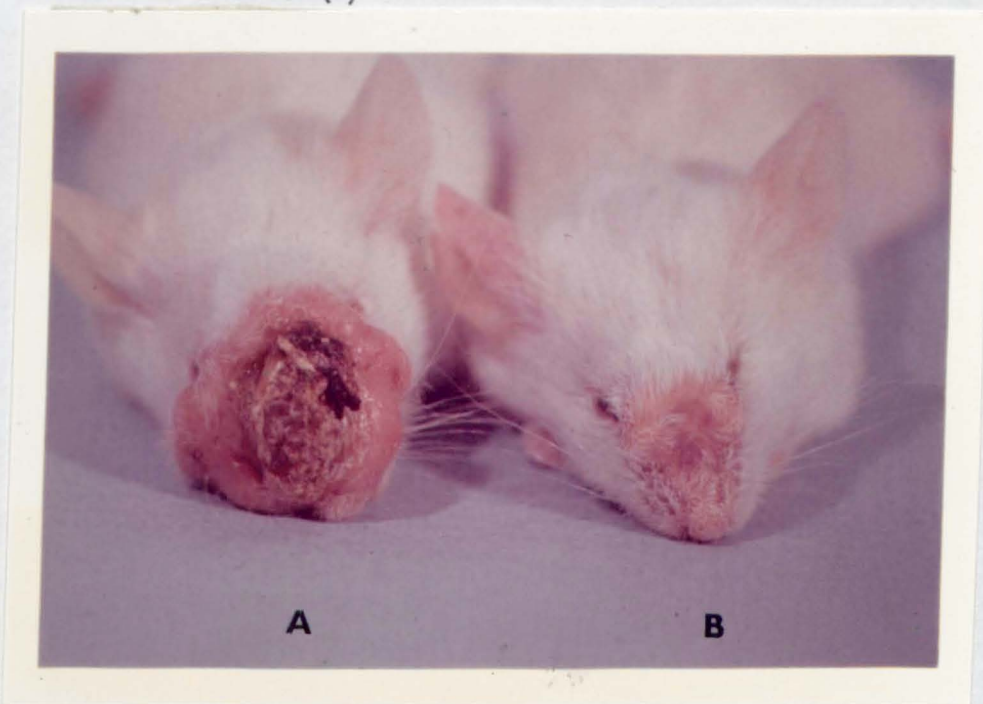


Fig.31 Two albino mice inoculated with the same dose of *L.b. pifanoi* at the same time. Mouse (A) was maintained at room temperature for 3 months, while mouse (B) was exposed to 35°C for 3 weeks and then maintained at room temperature. Mouse B shows smaller healing lesions and signs of hair regeneration on the affected skin.

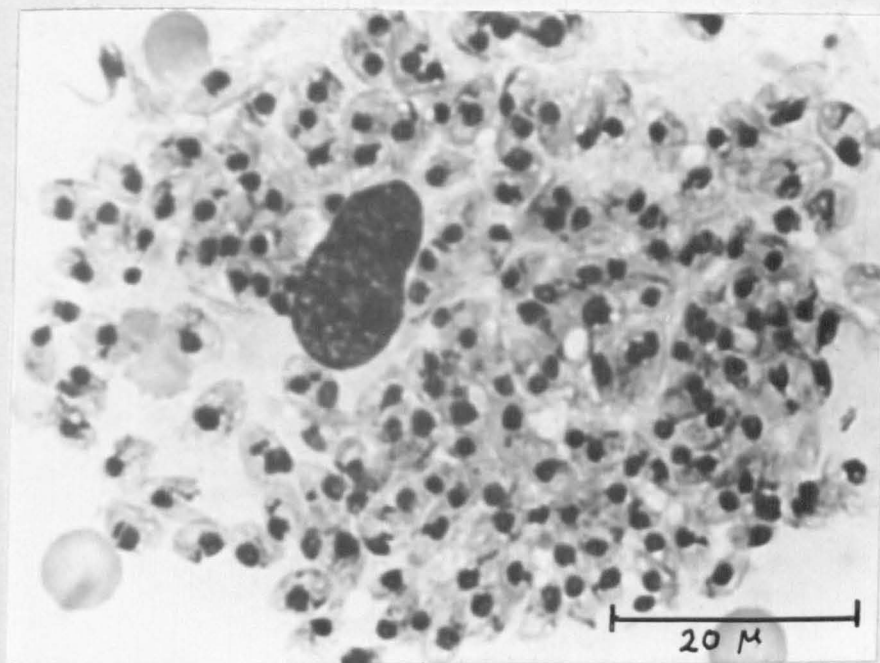


Fig. 32 Smear from a lesion of *L. b. pifanoi* from a mouse prepared 3 hours after exposing the animal to 36.5°C. Histiocyte is packed with amastigotes.

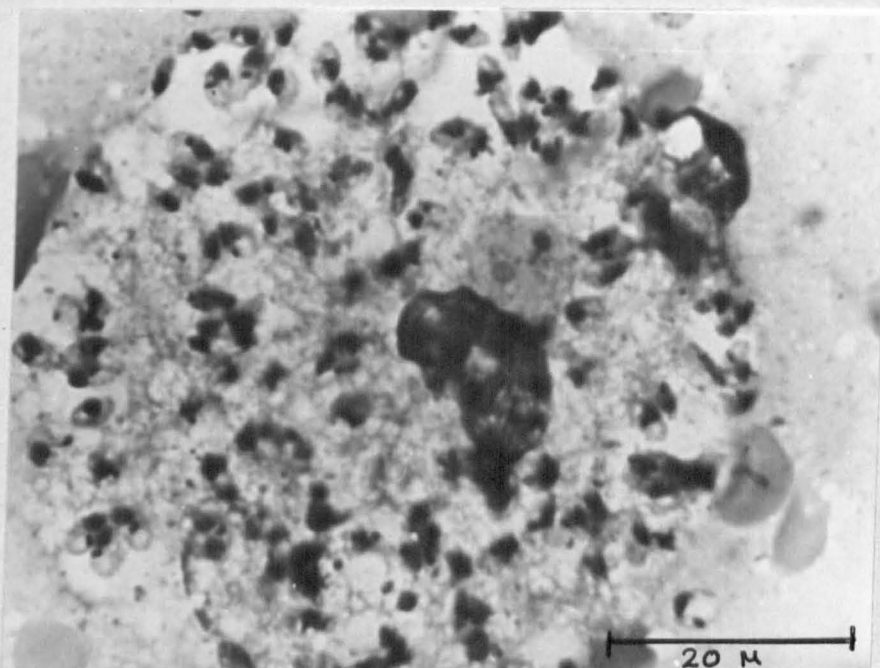


Fig. 33 Smear from the same lesion prepared 12 hours later, showing fewer parasites, some of which appear degenerate.

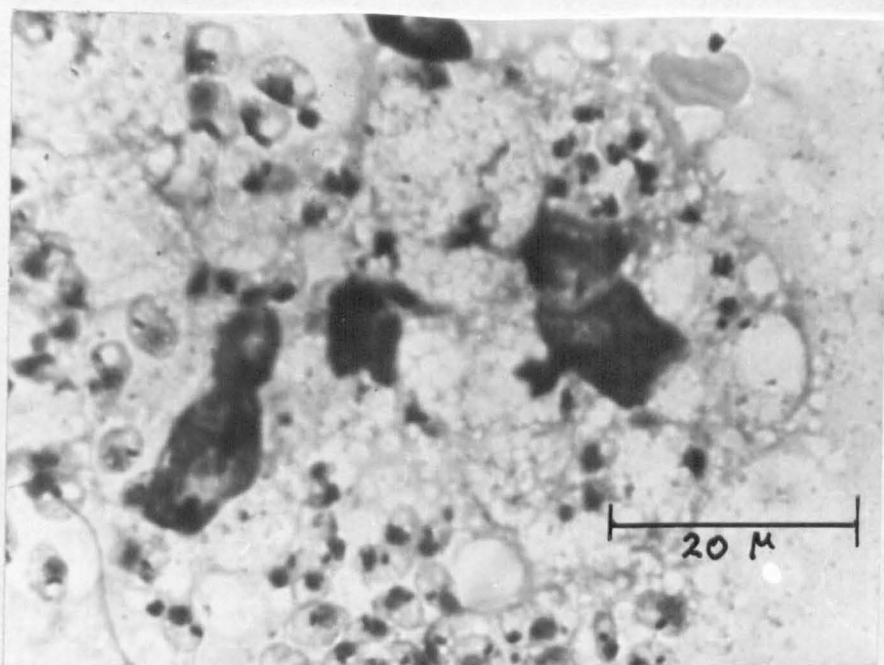


Fig.34 Smear from the same lesion after 18 hours showing remarkably few parasites.

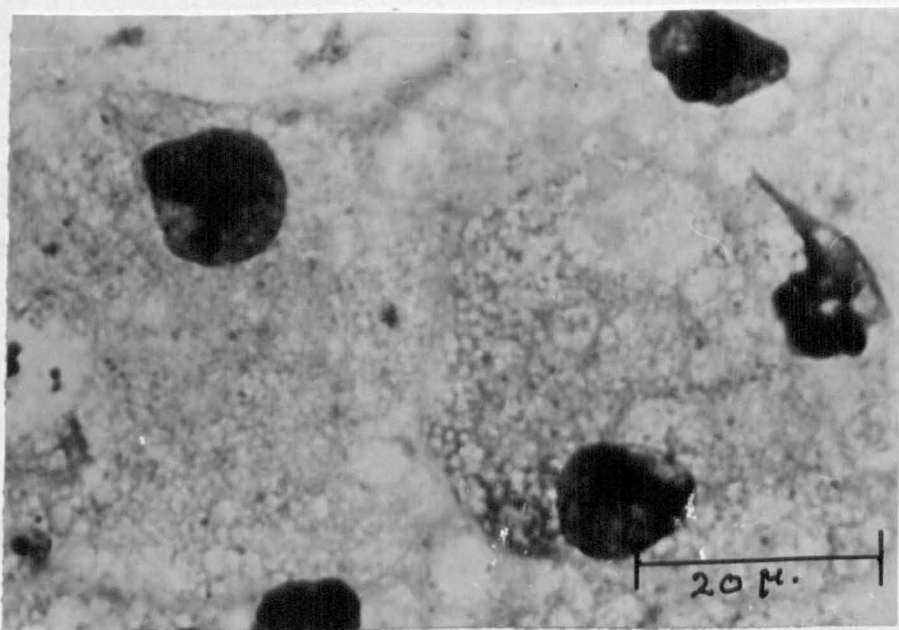


Fig.35 Smears from the same lesion after 39 hours showing the dramatic disappearance of parasites from the histiocytes.

only debris (Fig. 37). The destruction of the parasites and their disappearance from the lesion was not accompanied by any great differences in cellular reaction compared to that occurring during the normal process of healing in cutaneous leishmaniasis.

In section, the lesion treated by exposure to high temperature shows a thinned epidermis. In the dermis and subcutaneous tissue, there was marked oedema, a focus of necrosis, hyperaemia and an inflammatory infiltrate composed of lymphocytes, monocytes, groups of neutrophils and a very few plasma cells. Many histiocytes are devoid of parasites. (Figs. 36, 37, 38 and 39).

Experiment 5: Challenging cured mice by intradermal reinoculation with amastigotes of strain VI.

Four hybrid and 2 "shaven" mice from the thermally cured group (Experiment 4) were kept at room temperature for 4 weeks. They were then inoculated with .05 ml. of a suspension of amastigotes strain VI; to check whether their susceptibility to infection had been changed after being cured from active lesions. Two stock hybrid mice were inoculated at the same time as control.

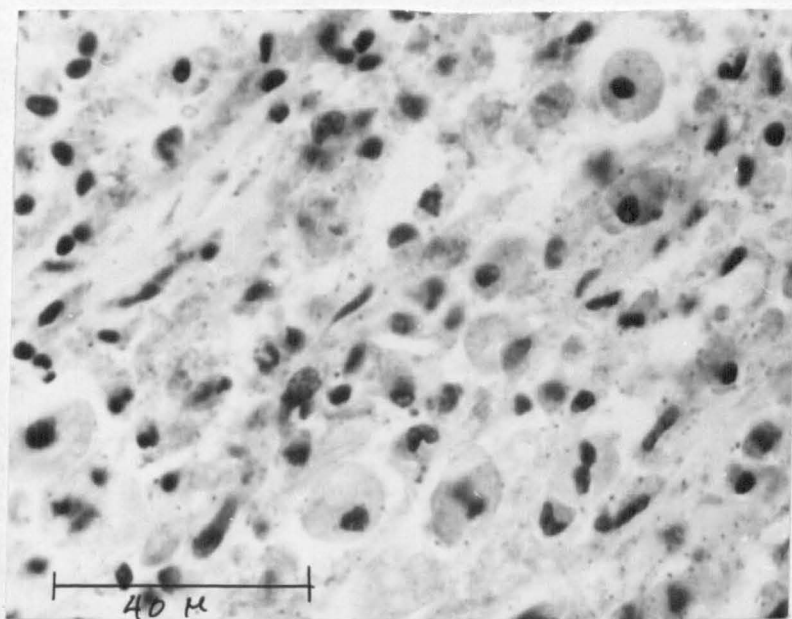


Fig.36 Section from a lesion of a mouse killed 3 days after exposure to 35°C showing disintegrating parasites in the histiocytes.

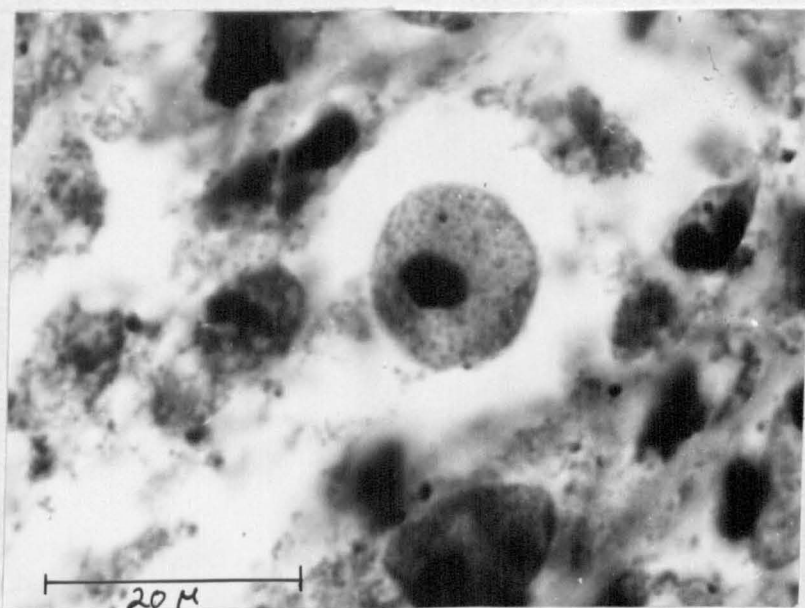


Fig.37 Higher magnification of the same photograph showing histiocytes.

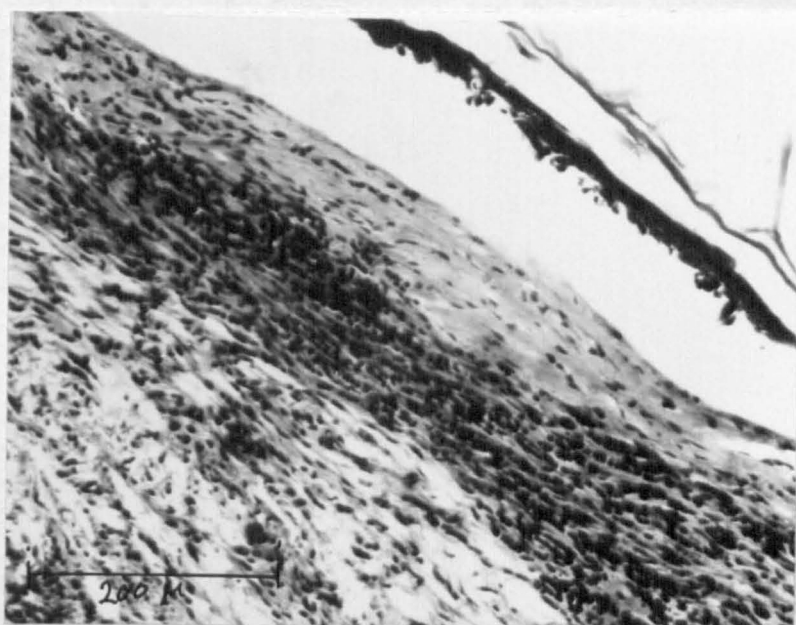

Fig.38 Skin section of a mouse infected with *L.b. pifanoi* maintained at 35°C for 3 weeks, showing fibroblasts and granular tissue formation with sloughing of the epidermis.

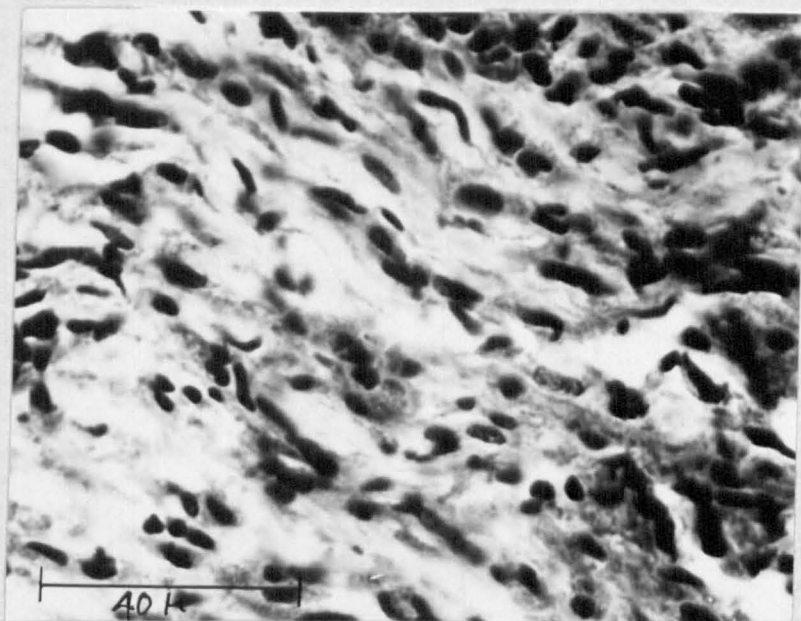


Fig.39 The same section under higher magnification showing fibroblasts and granular tissue. Stained with Haematoxylin and Eosin.

Results:

None of the challenged mice developed any lesions during 6 months of observation, while both control mice became infected.

Discussion

WLS / The investigation into the effect of the environment on the course of infection with Leishmania brasiliensis pifanoi were inspired by the observation that the parasite produced lesions only on hairless parts of the body and failed to metastasize to the viscera. Pereira ^{et al} (1958) was the first to correlate the restriction of the lesions to the ear, nostril, tail and foot pad with the lower temperature of these regions of the skin. The effect of the environmental temperature on the viability of parasites has been subject to some controversy. Hyperpyrexia was, however, first used many years ago to treat parasitic, viral and bacterial infections. The present study was undertaken to gain some understanding of the limitation of the lesions of L. b. pifanoi to hairless parts of the body, the failure of the parasite to invade the viscera and, in particular, to investigate the possibility of curing human cases of leishmaniasis diffusa by exposing the patients to high temperature.

Many homiotherms are capable of maintaining a steady body temperature even when exposed to a wide range of environmental temperatures. This ability is not the same in all mammals. Rodents on the whole have fairly poor thermoregulatory systems, probably because of the large

surface area/body volume ratio of small animals (Bernstein, 1967). The body temperature of the rodents has been shown to reach 38 - 41°C when they were kept at 35 - 37°C and drop to 29 - 35°C in mice kept at 4°C (Congdon, 1912; Hutchison, 1914; Benedict and Lee, 1936; Larson *et al.*, 1940; Sulkin, 1945; Weir, 1947). The rectal temperature of the rodents used in the present experiments was influenced considerably by the environmental temperature. The body temperature of animals rose to 39 - 40°C when they were kept at 35 - 36°C and fell to 18 - 36.5°C when they were kept at -15°C. The skin temperature of hairless parts of all animals was strikingly affected by the exposure of the animals to different temperatures. Pereira^{*et al*} (1958), Zeledon^{*et al*} (1965) and Eliseev and Serelkova (1966) compared the skin temperature of experimental animals maintained in different environmental temperatures. They found that the temperature of the skin varied from 11.1 to 34.5°C when the environmental temperature was changed from 5 to 35°C. Similar results were obtained in the present work. In general the skin temperature of hairless parts was 7 - 9°C below that of the rectum at room temperature (22 - 25°C), while the temperature of the skin at 4°C was never lower than 17°C.

Animals experienced a high mortality rate when exposed suddenly to very high or very low temperatures. When they were gradually adapted to these extremes they survived quite well.

The exposure of animals to low temperature caused them to consume more food and they showed greater activity, whereas animals kept at 35 - 36°C ate less food, lost weight and became sluggish. This is probably because of the increased metabolic activities of the animals at lower temperature (Holtman, 1946).

The incubation period of the parasite in animals kept at 4°C was shorter than in those at room temperature but the development of the lesion followed the same pattern as in animals kept at room temperature. Several protozoal, bacterial and viral diseases are more severe under conditions of low temperature.

Most parasitic organisms can withstand lower temperatures better than higher ones, if they are given the minimum requirements of survival. At low temperatures there is a drop in the biochemical and physiological activities to a minimum, which rises again when the parasite is warmed up again to normal temperature. This is the basis of deep freezing for the preservation of bacterial, protozoal and other living organisms.

Kolodny (1940) suggested that the differences in the course of infection with Trypanosoma cruzi at different temperatures were due to modifications of the physiological processes of the host as changes in sugar concentration of the blood, cellular changes and endocrine activities and not because of the direct effect of the low temperature on the parasite. This explanation

is not applicable to diffuse leishmaniasis. The parasite appeared to be favoured by maintaining the infected animal at 4°C; lesions developed in the normal way but with a slightly shorter incubation period. A temperature of -15°C, however, prevented the appearance of the lesion as long as the animal was maintained at that temperature, which inhibited the rate of multiplication of the amastigotes but did not destroy them. The parasites survived and gave rise to the usual infection in animals when they were removed to room temperature. The exposure of animals with developed lesions to low temperature did not affect the clinical picture or metastasis.

The parasite failed to become established in the viscera of animals maintained at 4°C. This does not contradict the effect of temperature on the distribution of the parasite in the body as the temperature of the viscera of the mice and hamster - was probably unaffected by the low ambient temperature. The increased activity of the animals possibly even raised their internal temperature. This point could be determined by inducing hibernation in infected hamsters. When the activity was reduced the internal temperature of the animal would fall to a few degrees above the environment and this might allow the parasite to invade the viscera until the animal's body temperature rose to normal.

Vassieadis and Jadin (1930) inoculated doormice (Myoxus miteb) with Trypanosoma rhodesiense and kept the animals in an ice box. The

animals remained aparasitaemic until removed to room temperature, when the parasite flourished and killed the animal in 12 days. A long period of hibernation eliminated the parasite. Rodhain (1951) inoculated hibernating marmots with Toxoplasma. The animals did not show any sign of infection but died, with the typical pathological picture, 18 days after waking up.

Leishmania, being originally a parasite of insects, might be expected to grow abundantly at temperatures between 25 - 28°C, a favourable temperature range for the insect vector.

The effect of high temperature on the course of diffuse leishmaniasis was the most interesting result of the study on thermal effects on the parasites.

Inoculated animals kept at 35 - 36.5°C did not develop lesions during the three weeks of maintenance at this temperature or subsequently during the six months at room temperature. This showed that the parasite failed to establish itself under those thermal conditions. Total elimination of the parasite at 36°C could be due to either or both of the following factors:

1. A direct effect of high temperature on the parasite. Senekji (1941) showed that L. donovani, L. tropica and L.b. brasiliensis tolerated a temperature of 40°C for only 15 - 30 minutes, whereas the body temperature

of the mice used in the present experiments was higher than 39°C.

In tissue cultures of cutaneous species of Leishmania, the favoured temperature for the growth of the amastigotes is 32 - 35°C. (Lelijveld and Atanasiu, 1966; de Castro and Pinto, 1960; Wallace and Hamilton, 1946). Similar results were obtained by Lemma and Schiller (1964) with L. tropica, L. donovani and L.b. brasiliensis adapted to grow at high temperature in cell-free culture. Bray and Lainson (1964) found that diffuse strains of L.b. brasiliensis from Brazil grew well at 37°C, while other strains of L.b. brasiliensis did not grow at temperatures higher than 35.5°C.

^{*et al.*}
Zeledon (1965) correlated these variations in the growth of the parasite in culture at different temperatures with the temperature of the favoured sites of lesions in the body of infected animals. Direct evidence for the degeneration of the parasite at high environmental temperatures was obtained by de Castro and Pinto (1960). They proved that a strain of L. enriettii, maintained in tissue culture at 37°C, underwent degeneration, while populations maintained at 32 - 34°C survived well, undergoing active division.

Further evidence for a direct effect of high temperature on the parasite is provided by destruction of the parasites and their disintegration in infected animals with well developed lesions when exposed for a short period (26 - 48 hours) to high temperature. Smears from the lesions after

this period showed histiocytes containing disintegrated parasites.

The reaction of Leishmania parasites to different temperatures bears a direct relationship to the metabolic rate of the parasite at these temperatures. It has been shown that, with the cutaneous species of Leishmania, the metabolic rate rises with a rise in temperature up to 35.5°C, but drops if the temperature is raised further. With the visceral species, the metabolic rate rises until a temperature of 37°C is reached, then drops at higher temperatures (Zeledon ^{et al.} 1965; Greenblatt and Glaser, 1965; Janovy and Poorman, 1969).

2. Effect of the environmental temperature on the host.

It is possible that raised temperature can stimulate an increase of antibody production (Cushing, 1942). It is known that antibody production is lowered in hibernating animals and in fishes kept at low temperature (Janssen and Wealer, 1967). On the other hand the process of antibody production as well as phagocytosis is speeded up by exposure to high temperatures (Ipsen, 1952; Kopeloff and Stanton, 1942; Ledingham, 1908).

It is likely that the effect of high temperature on Leishmania is the result of a combination of a direct effect on the parasite as well as an indirect effect due to an increase in the immune response of the infected animals.

The results of these experiments on the effects of high temperature on the diffuse leishmaniasis in experimental animals encourages one to hope that the application of hot compresses to the site of the lesions on human beings might result in a cure. The problem deserves further studies in animals as well as with human volunteers.

The failure to re-infect mice which had been cured from active lesions by exposure to high temperature, suggests the development of some sort of immunity similar to that in cured cases of L. tropica. The experiment needs to be repeated using a larger number of animals and a longer period of observation.

PART IV - EXPERIMENTAL PATHOLOGY OF AMERICAN
DIFFUSE CUTANEOUS LEISHMANIASIS IN
LABORATORY ANIMALS

The three species of Leishmania which infect man, namely L. donovani, L. tropica and L. brasiliensis are morphologically identical but give rise to relatively distinct clinical and pathological pictures. As, however, there is a considerable degree of overlap in the gross and histopathological manifestations of the three forms, particularly in experimental animals, it is relevant here to give a brief account of the disease caused by each of the three species in humans and animals before dealing in greater detail with diffuse cutaneous leishmaniasis, caused by L. b. pifanoi, with which this part of the thesis is primarily concerned.

Visceral leishmaniasis

Visceral leishmaniasis, also known as kala-azar, is a common disease in the Mediterranean basin, Africa, the Middle East and parts of the Far East and Latin America, (see map. page 179) where a suitable sandfly vector is favoured by the local climatic and other ecological conditions.

The disease in man

When the parasite is injected into the skin of man by the bite of an infected sandfly, the promastigotes are engulfed by histiocytes and change into amastigotes. Eventually some of the infected histiocytes escape into the blood stream and are carried to the visceral organs, where the parasites multiply rapidly and most of the amastigotes so formed are picked up by fixed histiocytes of the reticulo-endothelial system. Eventually the parasite invades the bone marrow and interferes with the production of the erythrocytes leading to anaemia and netropoenia. In the later stages of the disease, the parasite is found in the liver, which becomes enlarged and undergoes fatty degeneration of the parenchymal cells and shows an enormous increase in the size and number of the Kupffer's cells; in the spleen, which also becomes enlarged, congested and dark in colour; there is little change in the heart, lungs, kidneys and lymph nodes become infested only in certain areas. These visceral manifestations of kala-azar are strikingly distinct from those of dermal leishmaniasis. The clinical and pathological picture of kala-azar has been studied thoroughly and described in detail by Meleny (1925); Hu (1933); Adler (1940); Chatterchjee (1952); Sen Gupta et al. (1956); Sen Gupta and Bhattacharyya (1951); Manson-Bahr (1966); Bell et al., (1958); Chung (1942, 1944).

u/

The primary skin lesion at the site of sandfly bite usually passes

unnoticed, but may appear as a minute pink or reddish papule several weeks to several months before the onset of systemic symptoms of the disease (Mirzoian, 1941; Kirk, 1942; Kirk and Sati, 1940).

The disease in experimental animals

The course of infection with L. donovani in experimental rodents varies slightly depending on the route of inoculation. According to Hindle and Thompson (1928), when the parasite is inoculated intradermally into hamsters, nodular lesions appear at the site of inoculation. These lesions are indistinguishable from those resulting from inoculation with L. tropica, L. mexicana or L. b. brasiliensis.

When inoculated intraperitoneally L. donovani invades the visceral organs within a few days. Thus 9 days after inoculation a few scattered infected histiocytes may be detected in the spleen. As in man, when the infection advances histiocytic proliferation tends to dominate the whole picture. The pulp of the spleen is gradually replaced by a histiocytic granuloma. The blood capillaries and sinuses of the organ become somewhat compressed by the surrounding cells; however in the later advanced stages the sinuses are widely dilated and contain parasitized histiocytes (Meleney, 1925). Hu (1933) found a marked increase in plasma cells, which he suggested may be partly responsible for the enlargement of the spleen

and other infected visceral organs, a state of affairs which has not been described in man.

Six days after inoculation the parasite is found in the liver when amastigotes may be detected in a few Kupffer cells. This is followed by the appearance of small groups of proliferating Kupffer cells extending into the lumen of the capillaries. As in man, the Kupffer cells may be distended to the size of the parenchymal cells. The portal spaces, bile ducts, and arteries may be infiltrated with lymphocytes and plasma cells to the point where the whole architecture of the lobe may be destroyed.

(Meleney, 1925; Hu, 1933; Sen Gupta and Bhattacharyya, 1951.)

In the lymph glands, infected histiocytes may proliferate in the mesial wall of the peripheral sinus and extend to involve the lymph follicles. The parasitized histiocytes increase in number until they completely overlap the follicular architecture of the lymph nodes. The histiocytic infiltration extends inwards from the peripheral sinus to involve the medullary portion of the node (Meleney, 1925). Following intraperitoneal inoculation, Hu (1933) noticed an increase in the plasma cells, especially in the mesenteric lymph nodes. He also described the enlargement of the abdominal and retroperitoneal lymph nodes. The proliferation of the plasma cells leads to the thickening of the medullary cord, which has not been described as a marked feature of infected lymph glands in man.

In the bone marrow, parasites are found within histiocytes 24 days after inoculation. In the advanced stages of the infection (after one year) the infected histiocytes may form about half the cells of the bone marrow. Small compact groups of haemopoietic cells are found between the masses of histiocytes with great reduction in the erythropoiesis (Meleney, 1925).

Cutaneous Leishmaniasis

a) Old-world cutaneous leishmaniasis

Known in different parts of the world as oriental sore, Aleppo button, Jericho boil, Baghdad boil, Delhi boil, Bouton de Biskra, it is caused by L. tropica. It is endemic in the Middle East, Mediterranean basin, parts of the U.S.S.R., India, Pakistan, North, East, Equatorial and West Africa (see map page 179).

The disease in man

The parasite is introduced into the skin of man by the bite of an infected sandfly. The promastigotes are taken up by the regional white blood corpuscles. Parasites engulfed by neutrophil leukocytes are destroyed, while those taken up by histiocytes survive and multiply. Eventually the engorged histiocyte ruptures and the released amastigotes are picked up by other local histiocytes.

The infection of the skin is usually accompanied by histological changes at the site of infection. These changes may be summarized under the following headings:

Epidermal changes: Changes in the epidermis may be noticed six days after experimental infection of man.

Thus, Dostrovsky (1935) described hyperkeratosis and acanthosis of this layer of skin. Kurban et al. (1966) failed to relate the changes in the epidermis with the duration of the infection. He found the most common changes in the epidermis to be hyperkeratosis, parakeratosis, atrophy and/or acanthosis. He also described follicular plugging, liquification and degeneration of the basal cell layer. In three of the cases studied, Kurban et al. (1966) described the formation of microabscesses in the hyperplastic epidermis with neutrophil and lymphocyte infiltration.

Dermal changes: Distinctive changes take place in the dermis due mainly to histiocytic proliferation.

Adler (1947) studied these cellular changes in experimentally infected patients. He found a primary proliferation of the histiocytes, heavily infected with parasites, followed by a secondary infiltration of lymphocytes marked by a reduction in the number of parasites. Kurban et al. (1966) found that the dermal changes were distinctive and related to the duration of the

lesion. The same authors found that in the early stages of infection (up to one year) there is marked diffuse infiltration of the dermis with histiocytes, mononuclear leucocytes, and more rarely with eosinophils and neutrophils. Plasma cells may occasionally be present but giant cells are very infrequent.

In the later stages (more than one year) the dermis may exhibit tubercles consisting of epithelioid cells and containing giant cells of Langhan's type. These tubercles are surrounded by slight infiltration of histiocytes and mononuclear leukocytes with only a few parasites. Necrosis is very rare and the blood vessels are unaltered.

Ulceration: The ulceration of the lesion may take place with or without secondary bacterial infection.

Ulceration is probably due to necrosis of the overlying epidermis as a result of pressure and interference with the blood supply by the mass of proliferating histiocytes and secondary infiltration of lymphocytes (Adler, 1962).

In uncomplicated cases, the ulcer heals within three to eighteen months, leaving the patient with a depressed scar and life-long immunity against reinfection with L. tropica (Katzenellenbogen, 1944; Adler, 1964).

The disease in experimental animals

L. tropica has been experimentally studied in dogs, monkeys, white mice and hamsters. In dogs and monkeys it produces purely local lesions which bear a close resemblance to the disease in man. On the other hand, in rodents (mice or hamsters) the intravenous or intraperitoneal inoculation of the parasite gives rise to a generalized infection without the formation of a local lesion. In fact, L. tropica results in visceral leishmaniasis of hamsters more frequently and with greater intensity than L. donovani (Adler, 1947).

The histopathological picture of the disease in mice and hamsters has been studied by Adler and Theodor (1930); Adler, (1947); Levinson and Skadovskaja, (1946); Zuckerman, (1953); Coutinho-Abath and Coelho, (1965). As in human cases, the infection with the parasite leads to an inflammatory reaction with enormous infiltration of neutrophilic leukocytes, followed by histiocytic proliferation from the surrounding connective tissue.

Levinson and Skadovskaja (1946) injected mice intradermally with L. tropica and found the parasites increased in number even before being taken up by the host cells. This is followed by the usual inflammatory reaction. The same authors reported the presence of the parasite in cells other than histiocytes, namely in neutrophils, lymphocytes, in epithelial as well as muscle and cartilage cells. Zuckerman (1953) found the parasite in the fibroblasts of the

loose subcutaneous tissues. Zuckerman interpreted the presence of the parasite in the fibroblasts as the result of the intense stimulation of these cells by the parasite resulting in their assuming a phagocytic role.

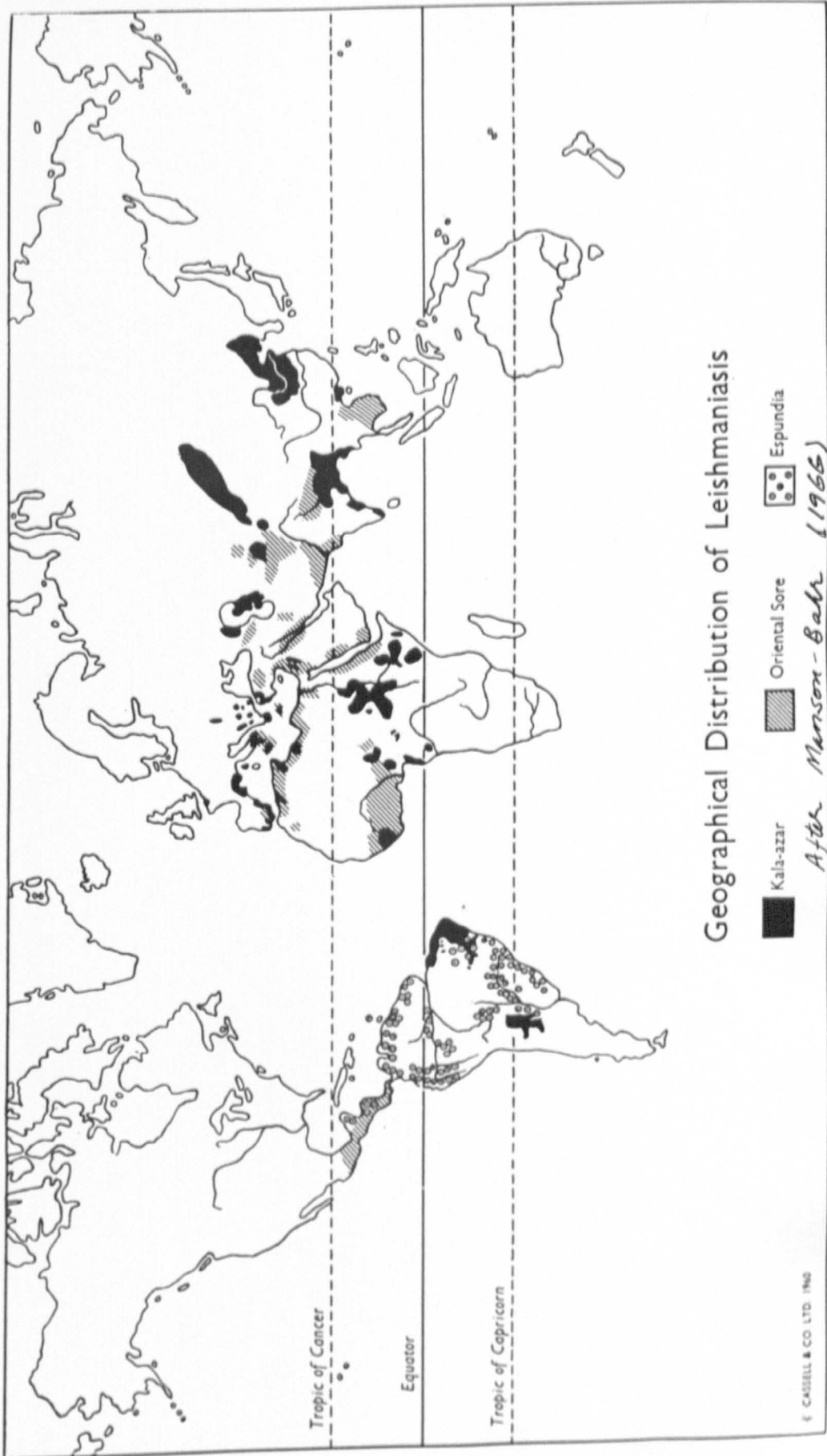
b) New-world cutaneous and mucocutaneous leishmaniasis - exists throughout South and Central America (see map page 179) The disease is most common in tropical regions with virgin forests or luxuriant vegetation, especially during the rainy season (Pifano, 1966).

The disease in man

American cutaneous leishmaniasis may be classified according to the localization of the lesion into: i) Benign cutaneous leishmaniasis, in which the lesion does not metastasise to other parts of the body; ii) Mucocutaneous leishmaniasis or malignant type, in which the parasite spreads to other parts of the body, especially the mucosa of the oronasopharyngeal membranes.

i) Benign cutaneous leishmaniasis

This may be caused by L. mexicana or L.b. peruviana. The lesions caused by these two parasites show similar clinical pictures. The lesion starts as a small papule, changes into a nodule and ulcerates before healing. The lesions are usually found in uncovered parts of the body; the ulcers are usually round or oval with a well-defined, slightly raised edge and narrow



indurated rim.

The histopathological picture of the disease is very similar to that of L. tropica in the old world.

Epidermal changes: The epidermis shows extensive acanthosis.

Between the projections of the acanthosed epidermis there are usually large numbers of infected histiocytes.

Dermal changes: In the dermis there is a great proliferation of histiocytes at the site of infection forming a histiocytic granuloma or 'histiocytoma' (Martinez-Baez and Aleman, 1960). The parasites inside the histiocytes have a characteristic 'garland' arrangement (Garnham and Lewis, 1959; Garnham, 1962; Lainson and Strangways-Dixon, 1963).

The disease in experimental animals

Subcutaneous inoculation of the parasite into experimental rodents leads to the formation of nodular, tumoural lesions. The lesions in hamsters and mice are very similar; however, in hamsters there is a greater tendency to visceralization. Metastasis of the parasite to the limbs is not uncommon (Coelho and Coutinho-Abath, 1965).

The pathological picture of the lesions in experimentally infected mice and hamsters is very similar to that in naturally infected wild rodents (Lainson and Strangways-Dixon, 1964).

The epidermis covering the primary lesion shows hardening of the squamous

epithelium, which becomes atrophic or acanthotic.

In the dermis, the normal tissue is replaced by a mass of vacuolated histiocytes which are heavily parasitized and form a histiocytic granuloma. As in human cases, the parasites within the histiocytes are arranged along the periphery in the 'garland' pattern (Garnham and Lewis, 1959; Garnham, 1962). In addition to the histiocytic proliferation there is infiltration of lymphocytes, plasma cells and a few polymorphnuclear cells, mainly around the blood vessles and nerves.

Sections of ulcerating lesions reveal separate areas of intense secondary cellular response along the edges of the ulcer with heavy infiltration of lymphocytes and plasma cells but only scanty parasites (Lainson and Strangways-Dixon, 1964).

Visceralization: has been noticed in experimental rodents by Garnham and Lewis (1959); Garnham, (1962); Lainson and Strangways-Dixon (1963, 1964); Coelho and Coutinho-Abath (1965); and Coutinho-Abath and Coelho (1965).

In the spleen, histiocytic infiltration is accompanied by atrophy of the lymphatic follicles, although sometimes diffuse lymphatic hyperplasia of the red pulp occurs with marked blurring of the lymphatic follicles. Amyloid deposits appear on the walls of the splenic sinuses around the lymphatic follicles.

In the liver, Kupffer cells are seen to contain parasites. Portal infiltration with lymphocytes, plasma cells and polymorphonuclear cells occurs in addition to extensive deposition of amyloid substance on the walls of the sinusoids. Small foci of necrosis may be found in the liver parenchyma (Coutinho-Abath and Coelho, 1965).

In heavily infected animals, the parasites are also found in the bone marrow freely or inside histiocytes.

ii) Mucocutaneous leishmaniasis (or Espundia).

This is caused by L.b. brasiliensis or L.b. guyanensis.

The disease in man

The disease is characterized by the appearance of primary cutaneous lesions similar to those of benign cutaneous leishmaniasis or oriental sore, followed by the invasion of the oral and nasal mucous membranes. The primary lesion heals after a few months to two years, but is followed by secondary ulcerative granulomatous lesions which appear on the skin and especially of the mucous membranes of the nose, mouth and pharynx.

The primary lesion may develop on different parts of the body, especially face, arms and legs (Snow, et al., 1948; Fox, 1931). The site of the infected sandfly bite becomes red, itchy and may vesiculate to form a papule or nodule (Goldman, 1947).

The histopathological picture of the primary lesion has been studied by Thornburgh et al. (1952); Snow et al. (1948); Fox, (1931).

Epidermal changes: The epidermis shows parakeratosis with slight atrophy of the rete pegs. Intracellular oedema, necrosis and ulceration may follow.

Dermal changes: The lesion is characterized by an inflammatory reaction in the dermis with cellular infiltration of lymphocytes and histiocytes containing amastigotes. As the infection progresses a greater area becomes involved. Plasma cells in large numbers, few eosinophils and some giant cells may appear, but no tuberculoid lesions are formed (Snow, et al., 1948).

Eventually necrosis and ulceration take place. The ulcers are round or oval with undermined border a clear-cut ulcer surrounded with a narrow rim of induration. The ulcer may be covered with a brownish crust. Trauma or slight injury may cause free bleeding of the ulcer.

In the ulcerating stage, the lesion extends to the mid-dermis with granular tissue at its base and intense chronic inflammation surrounding the ulcer crater; plasma cells, lymphocytes and giant cells of Langhan's type are found in some cases with older lesions.

Acanthosis of rete pegs extending to the upper dermis and necrosis of the dermal papillae about the ulcer crater have been noticed (Thornburgh et al., 1952).

In the healing stage, which may start several weeks after ulceration with granulations in the central portion of the ulcer and its proliferation to fill all the ulcer, plasma cells are replaced by greater numbers of lymphocytes and monocytes. The epithelioid cells proliferates to replace the inflammatory foci followed by epithelization and fibrosis of the granular tissue which complete the healing processes.

The secondary lesions of the auronasopharyngeal mucous membranes occurs as a metastasis of the parasite from the primary lesion of the skin before or after it heals. The first signs of this are usually the thickening of the mucosa of the nasal septum, followed by the development of nodules which later undergo necrosis and ulcerate. The ulceration may involve the buccal cavity and extend to the pharynx or even larynx, causing serious deformity.

The pathological picture of the secondary lesions has been studied by Klotz and Lindenberg, (1923); Fox, (1930); Sanchez-Corisa and Guerra (cited from Jaffe, 1944), Snow et al., (1948); and Azuley, (1960). The pathology of the infected mucous membrane is very similar to that of the primary skin lesion, except that spontaneous healing of the mucous membrane takes place only rarely.

The disease in experimental animals

Guimaraes(1951b, c) studied the course of infection of four strains of L. b. brasiliensis in hamsters and mice.

Hamsters and mice inoculated intradermally or subcutaneously with the parasite developed nodular lesions similar to those caused by L. tropica and L. mexicana, with a similar tendency to visceralize.

Changes in the epidermis: The epidermis looked normal and remained intact during the early stages, but was destroyed and became ulcerated later on. The histiocytes may infiltrate to the basal layer of the epidermis.

Changes in the dermis: The pathological changes in the dermis are similar to those caused by other species of Leishmania in experimental rodents.

Ulceration: In the later stages of infection, the ulcer becomes covered with a crust, fibrin and pus. Moderate acanthosis may be noted along the margin of the ulcer.

Visceralization: The parasite has a greater tendency to visceralize in hamsters than in mice, as is the case with L. mexicana.

The spleen shows scattered necrotic foci because of extensive histiocytic proliferation along the periphery of the capsule of the organ. Histiocytes, heavily parasitized with amastigotes form a histiocytic nodule in the spleen.

In the liver, the parasites are found in the Kupffer cells. Infiltration of the area with lymphocytes and plasma cells is not uncommon.

In the later stages of infection the parasite has also been recorded in the bone marrow, lymph nodes, testicles, intestine, lungs, striated muscles, and brain.

Diffuse cutaneous leishmaniasis

The term "diffuse cutaneous leishmaniasis" is usually used to refer to the dissemination of the parasite from the site of initial inoculation in the skin, or secondarily from the visceral infection, to various parts of the body surface, which may be far removed from the original part of entry of the parasites. Diffuse cutaneous leishmaniasis may be caused by each of the known human species of Leishmania. The factors which bring about the dissemination of each of the three species of the parasite in satellite lesions, metastases or direct spread, are not fully understood. The degree of implication of strain differences, antigenic variation on the one hand and the host immune response and environmental factors on the other, are still subjects of controversy.

- i. Diffuse cutaneous leishmaniasis caused by Leishmania donovani or post kala-azar dermal leishmaniasis.

In 1922, Brahamachari recorded a new form of cutaneous leishmaniasis - dermal leishmanoid - in an Indian patient, who had suffered from kala-azar. Acton and Napier (1927) named the disease post kala-azar dermal leishmaniasis. Napier and Das Gupta (1934) examined 209 cases during 1931-1934 in Calcutta, Assam and Madras. Since the explosive epidemics of kala-azar in Bengal in 1925, and later on in 1940, it has been considered that 10% of kala-azar infections are followed by post kala-azar dermal leishmaniasis within 1 to 2 years of the end of treatment (Sen Gupta, 1956).

The disease is found in three forms, which follow one another in this order (Sen Gupta and Bhattacharyee, 1953).

1. The macular-hypopigmented type

This appears as depigmented areas of skin on the lateral parts of the trunk and on the face. The flat lesions may coalesce and affect the whole body.

The epidermis shows very little variation except for slight decrease of pigment in the basal layer. In long-standing cases atrophy of rete pegs with less pigmentation may be seen.

In the dermis, in the subpapillary plexus infiltration of histiocytes

and lymphocytes with proliferated blood vessels are the main early changes noticed. In more advanced cases, cellular infiltration extends to the reticular layer of the dermis around sebaceous glands, hair follicles and sweat ducts and very rarely around the sweat glands. Foci of cellular infiltration, mainly histiocytes, lymphocytes and, to a lesser extent, plasma cells, are found beneath the infected area. No alteration with blood vessels was noticed in the early stages. However, in chronic stages some degree of vascular thickening may be found. The papillary layer of the dermis shows oedema in few cases.

Few Leishmania parasites are found inside the histiocytes either in the superficial or deeper islands of cell infiltration.

2. The erythematous type

Lesions are most commonly seen on the face but may occasionally affect other parts of the body. The lesions may be found as butterfly - i.e. symmetrical - erythema.

The histological structure of the epidermis shows thinning of rete pegs over the infected areas. Distinct reduction in the pigment content of the basal layer is noticed. In the dermis more intense infiltration of histiocytes, lymphocytes and plasma cells around the proliferated subpapillary plexus extends to the superficial part of the papillary layer, along the papillary capillaries. Infiltrations are also found around the mid-dermal blood vessels, around the

sebaceous glands, hair follicles, sweat ducts and the infiltration may be found extending as deep as the sweat glands. The granuloma are formed of histiocytes, lymphocytes and plasma cells. Plasma cells are numerous in erythematous type, Leishmania parasites are more numerous than in the first or the hypopigmented type.

3. The nodular type (Fig.40)

Nodular lesions are most commonly found on the face, occasionally on the extremities, trunk, genitalia, rarely on the mucous membrane of the buccal cavity. The nodules are granulomatous, soft, relatively rich in parasites and never ulcerate.

The epidermis becomes thin and reduced to few layers. The rete pegs disappear and the pigment granules in the basal layer show marked reduction. The dermis contains vascular granulomata consisting of histiocytes, lymphocytes, plasma cells and newly formed blood vessels. A clear sub-papillary zone is seen in most cases but in others the granuloma extends up to the basal layer of the epidermis. The whole dermal layer shows invasion with infected histiocytes, especially around the newly formed blood vessels.

The lesions are confined to the skin. The blood count does not show differences and the general body condition is excellent; there is no fever or any other general symptom.

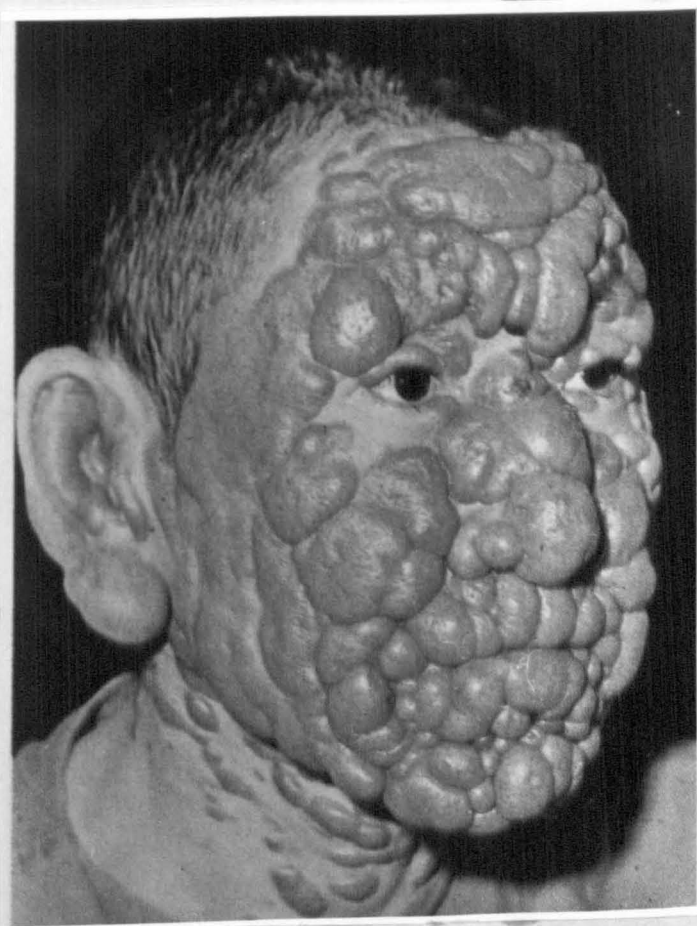


Fig.40 Case of post-kala-azar dermal leishmaniasis
(after Morgan et al., 1962).

ii. Diffuse cutaneous leishmaniasis caused by Leishmania tropica

The disease is found in one of two forms:

1. Leishmaniasis recidiva.

This has been described from the Middle East by Owen (1927), Dostrovsky (1936); Dostrovsky and Sagher (1945); Evan-Paz and Sagher (1961) and Dobrzhanskaya (¹⁹⁶⁴1965) described the same cases from Russia.

Clinically the primary lesions develop and ulcerate normally. In some cases they may heal completely but months or years later new small discrete nodules appear around the scar and ulcerate. In other cases, healing takes place in the centre and small nodules appear on the periphery, and in others, the initial lesion does not heal but continues as a chronic, indolent ulcer, with partial healing and spreading continuing for years.

The histopathological picture of the disease is distinctly different from the classical type of cutaneous leishmaniasis (oriental sore) in that the lesion is usually of the tuberculoid type with very scantily infected histiocytes, a few scattered lymphocytes, as well as a number of epithelioid cells of Langhan's type developing into giant cells (Kurban et al., 1966).

The leishmanin test is more strongly positive in patients with leishmaniasis recidiva than in those with leishmaniasis nodosa (the classical

oriental sore). Positive results were still obtained in patients with recidiva of antigen no longer capable of producing reactions in patients with leishmaniasis nodosa (Sagher, 1946, 1947).

Super-infection can be established by inoculation of viable flagellates of L. tropica. into patients with leishmaniasis recidiva. The developed lesion closely resemble recidiva type. This reaction is called isophasic reaction (Dostrovsky, et al., 1952, 1953).

2. Nodular type of diffuse cutaneous leishmaniasis caused by L. tropica (Fig.41)

This disease is found mainly in Africa where forty-four cases have been described. Forty three were from Ethiopia (Balzer et al., 1960; Poirier, 1964; Schaller and Sérié, 1963; Destombes et al., 1965; Price and Fitzherbert, 1965; Sérié et al., 1966; Bryceson, 1969; Bryceson and Leithead, 1966). One case was reported from Tanzania by Anderson (1964).

The first Ethiopian case was described by Balzer et al. (1960) from a leprosarium. The patient had been treated for three years as a case of leprosy before Leishmania was seen in a biopsy of a skin lesion. Price and Fitzherbert (1965) described cases of lymphatic blockages in the lower limbs and indolent swelling of the feet; due to enlargement of the lymphatic glands this sometimes extended above the ankle into the lower leg, causing a form of elephantiasis.

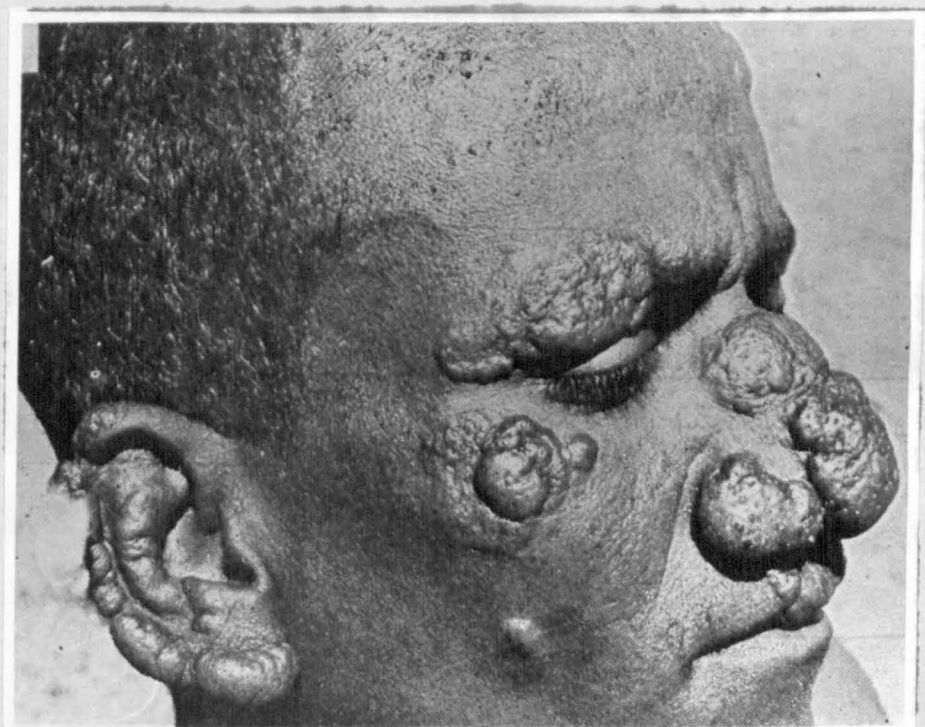


Fig.41 Ethiopian case of diffuse cutaneous leishmaniasis (after Bryceson, 1969).

A few cases reported in the literature as being caused by L. tropica show a clinical picture similar to that of diffuse cutaneous leishmaniasis, although skin leishmanin test was not undertaken in these cases (Ferguson and Richards, 1910; Thompson and Balfour, 1910; Balfour and Thompson, 1911). Bryceson (1969, 1970) carried out extensive studies on the clinical histopathological and immunological aspects of diffuse cutaneous leishmaniasis in Ethiopia. He described thirty-three cases and found that twenty-two out of thirty-one patients with diffuse cutaneous leishmaniasis showed no response whatsoever to the leishmanin or montenegro test, six developed a hardly-palpable nodule while three were positive. Eleven patients showed a positive skin reaction after treatment. Bryceson considered that the Ethiopian cases of diffuse leishmaniasis were not due to post kala-azar dermal leishmaniasis, pointing out the absence of visceral leishmaniasis from the area. He believed that the appearance, as well as the histological picture, of the lesions of the cases of diffuse cutaneous leishmaniasis studied by him were governed by the immune response of the host, while the distribution of the lesions was a feature of the parasite.

The histopathological picture of diffuse cutaneous leishmaniasis caused by L. tropica has been studied in detail by Bryceson (1969). The main microscopic features of this disease's characteristics were:

Epidermal changes: The epidermis is intact but thin and flat with loss of rete pegs. The epidermal cells do not show ulceration. There is no hyperkeratosis except in lesions over the bony promontories. Under the epidermis there is a thin clear zone usually but not always seen.

Dermal changes: The dermis shows massive infiltration of histiocytes with large open nuclei and the cytoplasm packed with amastigotes. Amastigotes have been observed lying free. In some cases the main cellular infiltration consists of histiocytes, monocytes, plasma cells, but lymphocytes are few and frequently absent.

iii. Diffuse cutaneous leishmaniasis caused by *L. b. pifanoi*

The disease in man

Convit and Lapenta (1948) in Venezuela described the first case of a bizarre form of cutaneous leishmaniasis, which involved almost the whole body surface. Since then various authors have reported a similar disease in 40 patients from Central and South America.

These cases are distributed sporadically within the endemic areas of American cutaneous leishmaniasis. The disease affects adults and children of both sexes.

The first sign of infection is the appearance of a small localized lesion, which may take the form of a nodule, macule, plug or ulcer. This is followed

at widely variable intervals by the appearance of satellite lesions. These secondary lesions may remain discrete or may fuse with each other and with the primary lesion. At a later stage of the disease lesions appear on parts of the body far removed from the original site of infection. Eventually the whole skin surface with the exception of the scalp and the arm pits may be involved. At this stage it resembles lepromatous leprosy closely (Fig.42). The oropharynx and the nasal mucosa remain unaffected, although slight infiltration of the lower nasal septum may occur in a few cases.

Histopathologically the epidermis shows atrophy of the Malpighian layer with moderate hyperkeratosis (Convit et al., 1957). Convit et al. (1962), examining skin sections from patients with diffuse cutaneous leishmaniasis, found that the epidermis was normal.

The dermis showed histiocytic granuloma packed with amastigotes. The histiocytes had vacuolated protoplasm. No fats were demonstrated in these vacuoles by staining with Sudan IV.

The granuloma may also contain some giant cells and groups of epithelioid cells.

In the macule, during its eruptive stage, the intact epithelium covers the congested skin, which becomes infiltrated with polymorphonuclear cells overlaying vacuolated histiocytes which are in parasite.

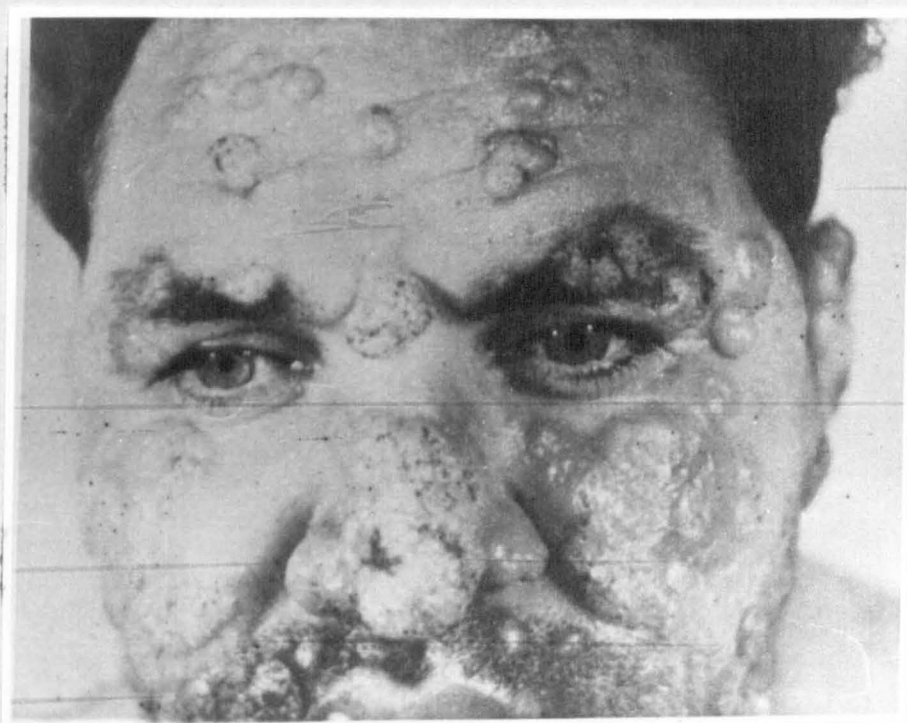


Fig.42 Nodular lesions on the face, caused by L. b. pifanoi (after Convit, 1958).

The lymphatic glands are found to be congested and heavily infected with *Leishmania* in two cases of diffuse cutaneous leishmaniasis described by Convit and Lapenta (1948). Montenegro skin test was negative.

Disease in experimental animals

L.b. pifanoi was studied in experimental rodents by Mayer et al., (1949), Convit (1958), Convit et al., (1965), Medina and Romero (1959, 1962).

The infection in hamsters and mice revealed nodular lesions but no visceralization of the parasite was noticed. Metastasis to other parts of the skin, like those of L. mexicana are found on different parts of the skin.

The dermis revealed infiltration with lymphocytes, plasma cells and numerous histiocytes with vacuolated cytoplasm containing amastigotes, as well as oedematous foci of polymorphonuclear cell infiltration and intense vascularization.

Guimaraes (1951 d and e) studied the course of a strain of L.b. brasiliensis which was isolated from a diffuse cutaneous leishmaniasis in Amazonia in which the patient showed positive Montenegro reaction after 48 hours.

Intraperitoneal inoculation of hamsters did not give visceral infection but periorchitis without skin lesions being noticed. The parasites were found with proliferated histiocytes in the epidermis. There was also some lymphocyte infiltration.

In animals inoculated subcutaneously with the same strain, local nodules developed, followed by metastasis of the parasite to other parts of the body, but not to the viscera. Although he has been able to find very few parasites in the liver and spleen, no pathological changes have been noticed in any of these organs.

Most of the authors who studied L. b. pifanoi in experimental animals reported the similarity of the lesions to those in human cases without giving detailed descriptions.

Present Work

During the present work, the author investigated the gross and histopathological picture of Leishmania brasiliensis pifanoi in hamsters and mice. The information included in this part of the present work embodies data collected during the investigation of the various aspects of the parasite over the preceding three years (see Part II).

The description of the gross pathology of the disease was followed by recorded observations on the incubation period after inoculation by the dermal or intraperitoneal routes, the size and rate of growth of the primary lesion, the appearance of secondary lesions and the eventual generalized dissemination of the parasite over the body. These macroscopic observations were confirmed by the preparation of Giemsa stained smears from the affected skin. Smears were also routinely prepared from the peritoneal fluid and visceral organs.

The histopathology of the disease was studied in paraffin sections of the infected skin and lymph glands. Sections were also prepared from liver, spleen, lungs, kidneys and heart to investigate the possibility of visceralization of L.b. pifanoi.

The Gross Pathology of Diffuse Cutaneous Leishmaniasis in Hamsters and Mice :

The three strains V1, V2 and L 15, used during the present investigations, gave primary lesions which were indistinguishable from one another.

In the later stages of the disease, however, the Venezuelan strains, V1 and V2, showed a strong tendency to spread to other hairless parts of the body, while the Brazilian strain, L 15, failed to spread and remained restricted to the site of the primary lesion.

Development of the lesion in hamsters:

The incubation period following intradermal inoculation with amastigotes or promastigotes, varied from two weeks to three months depending on the density of parasites in the inoculum (see Part II).

The first sign of infection is a small, hardly palpable, papule at the site of inoculation. This early stage is visually detectable as a tiny, pinkish area of skin, which may be hard and shiny looking or covered with whitish, scaling stratum corneum. The hair in the affected area is usually thinner than on the surrounding skin, giving the appearance of a small, balding patch. The lesion after intradermal inoculation is small and raised above the surface of the skin; whereas after subcutaneous inoculation it is almost flat and covers a larger area of the skin. The latter type of lesion takes longer to become visible and is more difficult to detect by palpation.

The lesions develop very slowly, into nodules attaining a diameter of about 1.8 cm. in 8 to 12 months. The growth of the lesion is accompanied by a gradual loss of hair from the affected skin which becomes strikingly smooth and shiny (Fig.43). The colour of the nodule varies from

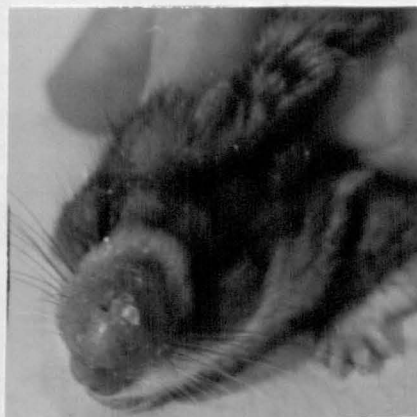pink to light purple. The lesion is firm to the touch.

The degree of interference with the health and the general activities of the infected animal depends on the site of inoculation. Even large primary lesions on the foot pad, involving most of the paw, do not seem to hamper the movement of the hamster. The animal steps with the affected foot without appreciable sign of pain. The lesion on the base of the tail only rarely interferes with defaecation. This is because of the short length of the tails of hamsters and the subsequent growth of the lesion towards the coxal part of the back. The most deleterious type of lesion is the large, bulbous nodule which forms on the snout following intradermal inoculation of the parasite into that organ (Fig.43 a, b). In the later stages, this lesion involves the whole snout as well as the upper lips (Fig.43 c). This leads to the partial blocking of the nares and consequent difficulty in breathing. The affected hamster is observed to labour for breath, and the wheezy respiration may become audible. The hamsters may resort to breathing through the mouth, the mouth being opened and gulps of air breathed in.

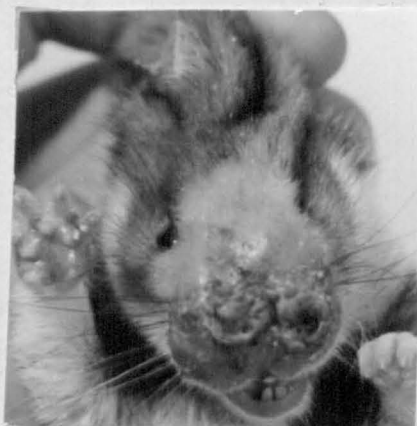The large lesions on the snout also interfere with the feeding of the animal. The size and position of the nodule prevents the teeth from reaching the standard diet cubes in the feeding basket of the cage. Repeated attempts by the animal to reach the cubes may lead to traumatic injury (Fig.43d). At this stage it is usually advisable to supply the hamsters with food at the bottom of the cage.



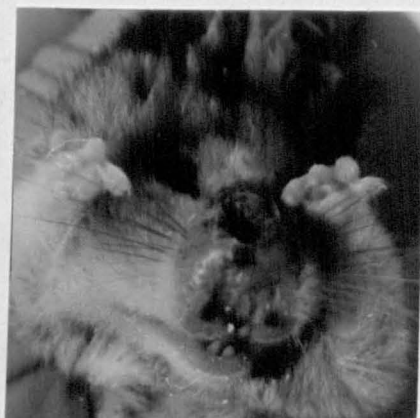a



b



c



d

Fig.49

Different stages in the development of lesions of
L. b. pifanoi in hamsters. a + b nodular lesions,
 c + d ulcerated lesions.

The enormous size which the snout may attain, may interfere with the grooming activities of the infected hamster. These animals look less clean and their fur less sleek and shiny than uninfected hamsters. The effects are apparently due to loss of function of the part and not to effects of the disease process.

The advanced primary lesion may remain as a nodule or it may ulcerate. Ulceration starts at the centre of the lesion with the collapse of the middle part of the lesion. The epidermal layer sloughs off revealing the infected dermis. The wound oozes out a small amount of yellowish exudate. At this stage the lesion has the appearance of a crater (Fig.43d). The exudate, together with the dead cells of the affected skin, dry up to form a thin, hard, brittle crust over the open wound. The margin of the ulcer is indurated and hyperaemic. The bottom of the ulcer is granular and reddish in colour. In most cases these ulcerating lesions become secondarily infected with bacteria; mainly of the staphylococcal group resulting in the production of a purulent discharge which is thick, white and evil smelling. When the surface of the ulcer dries, it becomes encrusted with a thick, rough, dark crust which can easily be peeled off, exposing a shallow pus stained crater surrounded by red and swollen skin.

Secondary bacterial infection may interfere with the general health of the hamster as the bacterial infection may progress to involve all the snout,

extending to the lips and eyes, or larger areas surrounding other sites of inoculation.

Secondary lesions:

Metastasis to other parts of the body may occur following the formation of the nodular as well as the ulcerated type of lesions. Metastasis results in the formation of new secondary lesions on other hairless parts of the body, which may be at some distance from the site of inoculation of the parasite. The time of metastasis and the number of animals showing this vary with the size of the inoculum. Secondary lesions appear 5 to 14 months following the initial inoculation of the parasite.

The secondary lesions appear gradually, but do not follow any regular pattern. The first secondary lesion usually appears at some distance from the primary one. Thus if the primary lesion is on the snout, the secondary one may appear on the hindfoot or base of the tail (Fig.44).

The secondary lesion starts as a small papule and follows a similar pattern of growth and development to that of the primary lesion. Unlike the initial primary lesion, however, the secondary lesions do not ulcerate but remain in the nodular stage.

The secondary lesions may appear on one or more of the digits of the foot or on the foot pad, but may grow to involve the whole foot by coalescence of lesions on neighbouring digits to form a large nodule which

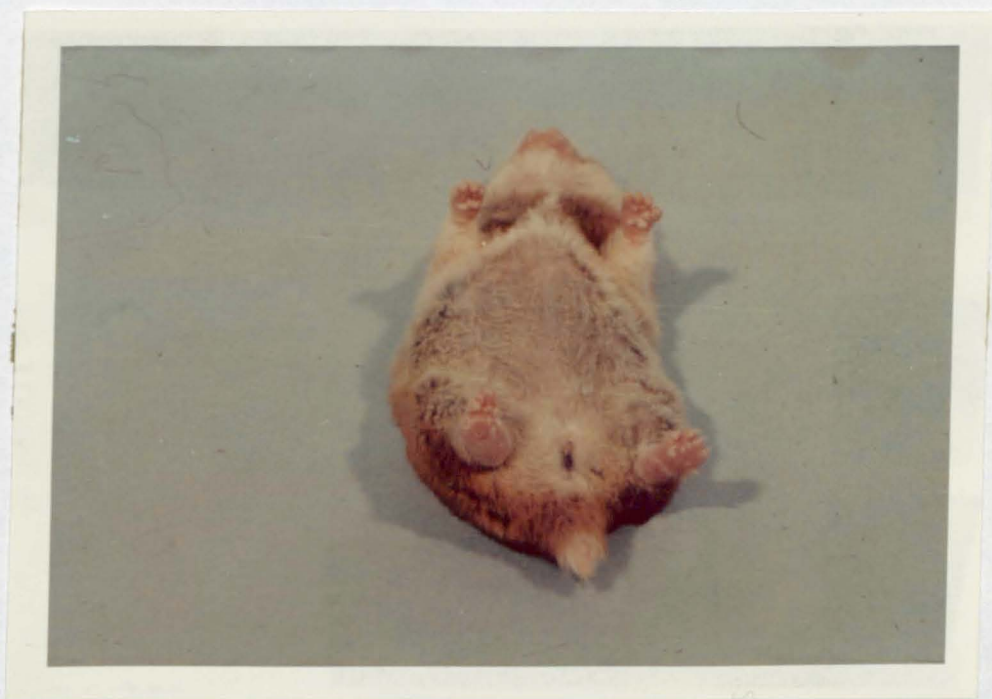


Fig.44 Hamster showing primary lesion on the right hind foot pad and the metastasis of the parasite to both left limbs .

results in the loss of distinct shape of the individual digits and deformity of the foot. Accompanying the involvement of the feet is the swelling of the regional, inguinal or axillary lymph nodes; the enlarged inguinal lymph nodes may grow to such a size that they can be palpated.

Secondary lesions form singly or in pairs on the upper surface of the external ears. One or both ears may become involved. Eventually the lesions on the ear coalesce, so that the ears resemble inflated sacs, which tend to droop on account of their weight. The enormous swelling of the ears must interfere with the hearing of the animal, by blocking the auditory meatus and by preventing movement of the pinna to catch sounds.

The secondary lesion forming on the snout develops into a large nodule in the same way as the primary lesion.

Occasionally the eyelids may become involved. One or more secondary lesions may form on each eyelid. These lesions usually remain small and do not grow large enough to obstruct vision.

Development of the lesion in mice

The primary lesion, as in hamsters, appears as a small papule which develops slowly into one of the following types of lesion:

i) Nodular lesion:

This is similar to the corresponding lesion in hamsters (Figs.45, 46 and




Fig.45 Early stage of nodular lesion on snout of mouse.

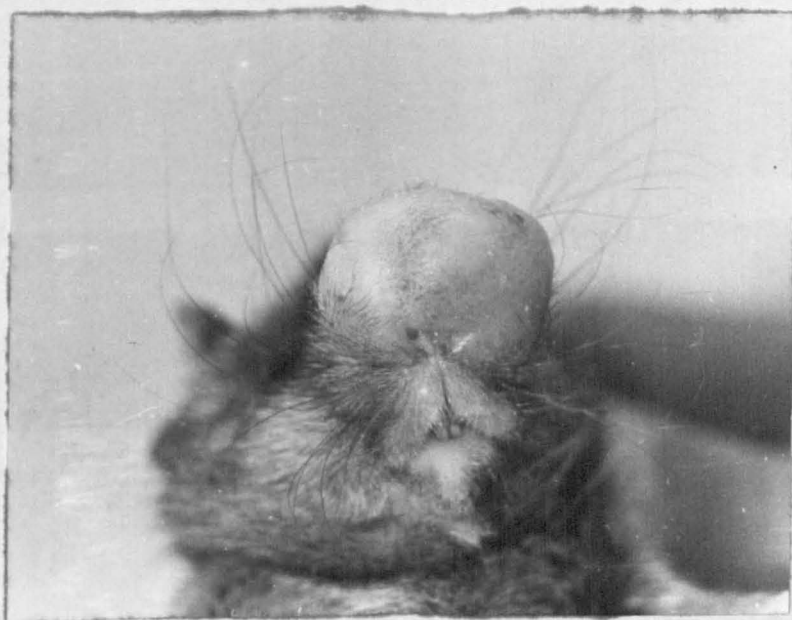

Fig.46 A large nodular lesion on the snout of (shaven x albino) mouse, six months after inoculation.

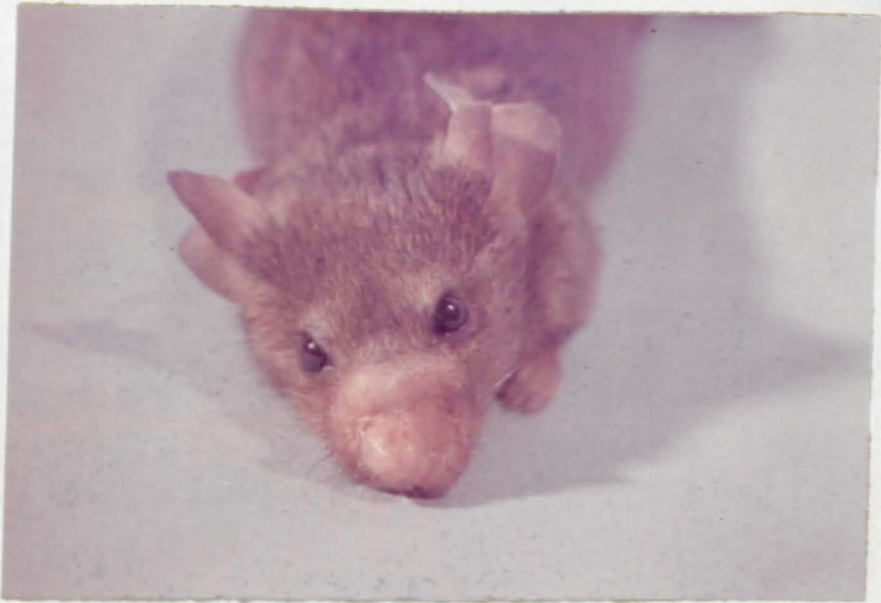

Fig.47 Nodular lesion of *L. b. pifanoi* (strain V2) on the snout of (shaven x albino) mouse, four months after inoculation.



Fig.48 (Shaven x albino) mouse showing ulcerating primary lesion.

ii) Ulcerating lesions:

Nodular lesions may ulcerate in the later stages of the development of the primary lesion^(Fig.48). The process is similar to that described for hamsters. The ulceration of the primary lesion in mice inoculated at the base of the tail often led to the exposure of the surface of the vertebrae (Fig.49) leading sometimes to the loss of the tail. Secondary infection of such lesions with bacteria increases the erosion of the base of the tail. The heavy, stiff crust which forms at the base of the tail may deform the normal shape of the tail and cause it to be held at an abnormal angle. The stiffness of the crust on the dorsal surface of the tail at the site of inoculation prevents the animal from lifting its tail. In severe cases the tail may be held beneath the body, which interferes seriously with the movement of the mouse. The animal walks with its hind legs spread apart and its back hunched. Defaecation becomes difficult and this interferes with bowel movements, appetite and the grooming of the animal. This leads to a drop in the general health of the mouse, which becomes thin and distressed. The condition often results in death. When the tail is lost the general health of the mouse improves.

The ulceration of the lesion on the snout may be deep enough to expose the bone (Fig.51 and 52).

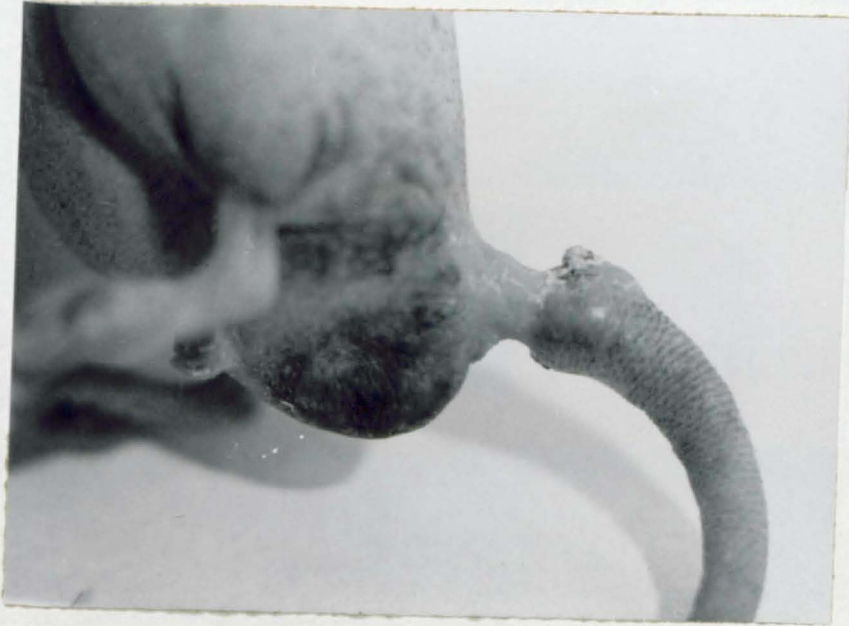

Fig.49 Ulceration of the primary lesion at the base of the tail of a shaven mouse, six months after inoculation with L.b. pifanoi. The skin of the basal part of the tail has sloughed off.

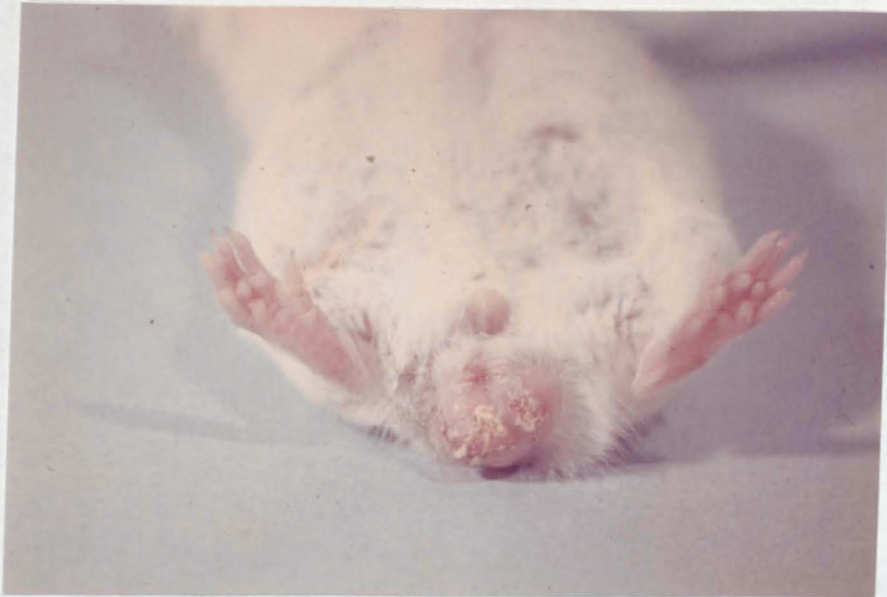

Fig.50 Ulceration of the primary lesion at the base of the tail of an albino mouse, ten months after inoculation with L.b. pifanoi, resulting in the loss of the tail.

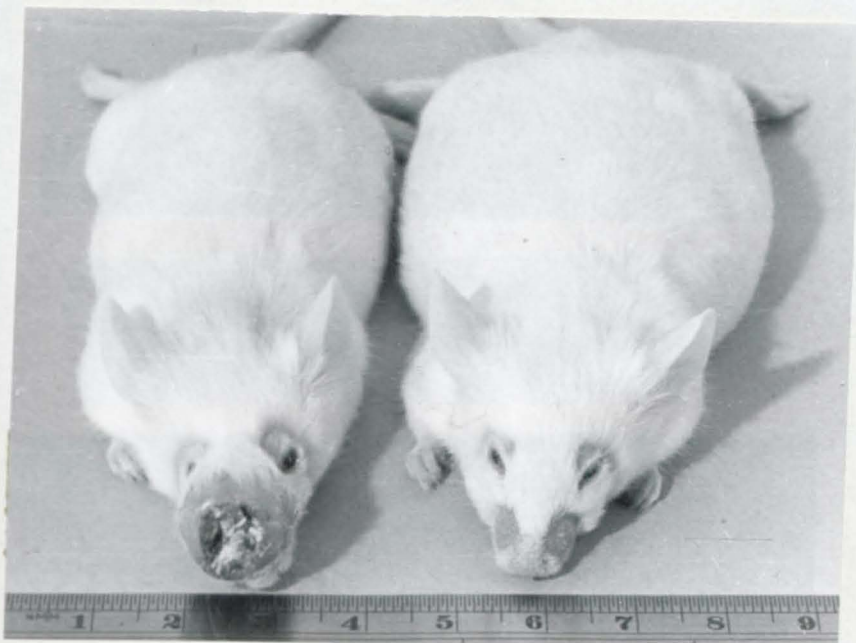

Fig.51 Ulcerating "crater" lesion on the snout of an albino mouse inoculated with heavy dose of amastigotes. Compare to mouse on the right inoculated with very low dose.

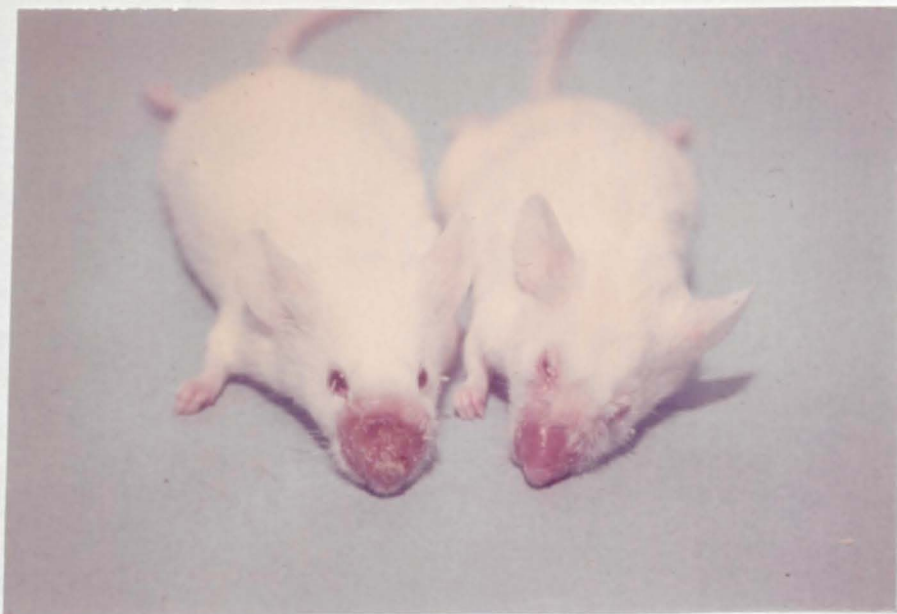


Fig.52 Stages in the ulceration of the primary lesion on the snouts of two albino mice.

iii) Warty lesions

These start as nodules which ulcerate. The ulcers become wart-like. The affected skin forms a thick, hard growth which may extend over the whole lesion. The surface of this growth is irregular and has a cauliflower-like appearance (Fig.53). The lesions bleed readily. This type of lesion was noticed only in two (albino x "shaven") mice and in both cases the lesions were at the base of the tail.

iv) Macular lesions

This form of lesion is most commonly found at the base of tail of mice. The lesion grows very slowly, without revealing any swelling above the surface of the skin. The surface of the lesion may cover up to 3 cm. of skin at the site of inoculation. The affected skin is shiny and pinkish in colour. Sometimes depigmentation of the area may be noted. This form of lesion does not ulcerate (Fig.54).

Secondary lesions:

The highest rate of metastasis is noted amongst hairless and "shaven" mice, followed by hybrids. Only a few albino mice show the dissemination of the parasite.

In the albino and hybrid mice the secondary lesions are restricted to the snout, foot pads, ears, tails, eyelids and scrota, i.e. the hairless parts of the body.

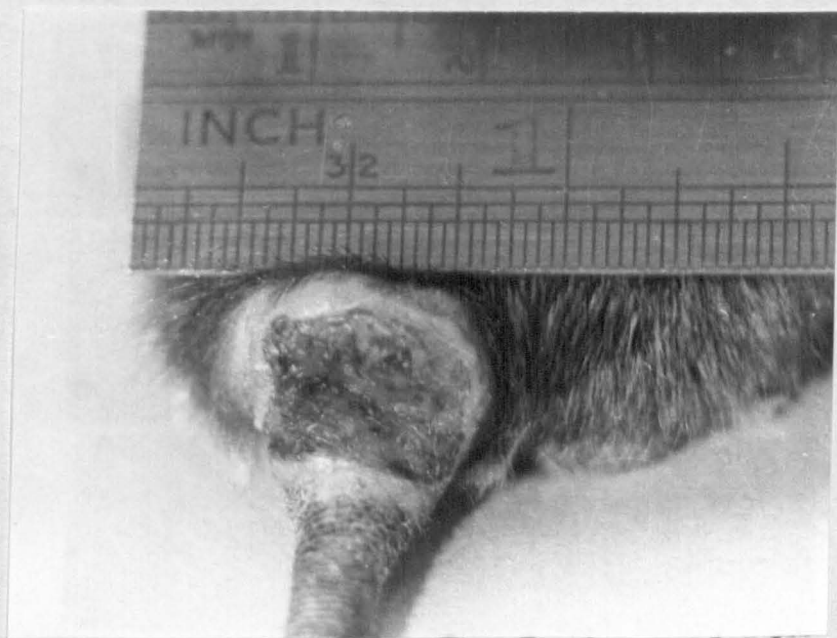

Fig.53 Warty type of lesion at the base of the tail of a (shaven x albino) mouse.

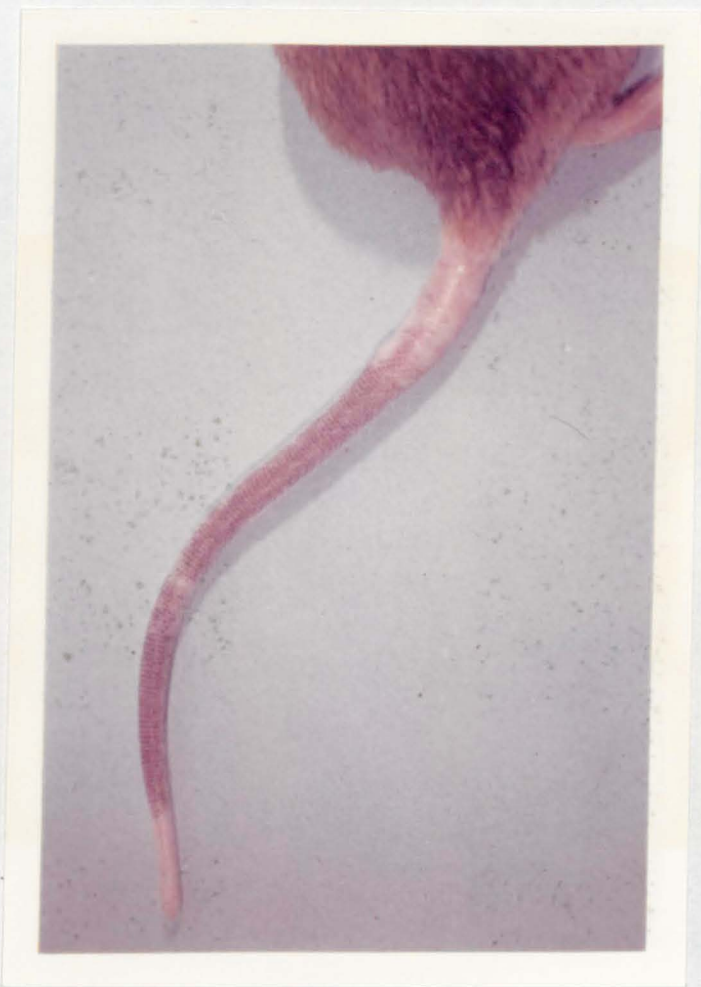

Fig.54 Lesion at the base of tail of shaven x albino mouse. Note the flat form of the lesion, and the depigmentation of the affected skin.

In albino and hybrid mice the pattern of dissemination of the lesions does not follow any given order. The secondary lesions may appear on any of the hairless parts of the body. The distribution of these lesions is not determined by the position of the primary lesion. The progress of the disease and the effect on the animal is very similar to that in hamsters. In the later stages of the disease all the hairless parts of the body may become affected (Figs.55, 56). The snout becomes bulbous and nodular, the ears may change into huge inflated bags of infected macrophages, the digits of the feet become swollen and lose their shape, the foot pads are also affected. Secondary lesions form at intervals down the length of the tail giving it a beaded appearance (Fig.57). In the later stages these lesions may coalesce to change the tail from its slender cylindrical form to a thick, irregular, nodular appendage.

In some cases the parasite extends to the scrotum which loses its hair and becomes leathery. When the penis is involved it becomes swollen and the glans penis remains permanently outside its sheath (Fig.55).

The course of the disease in hairless and "shaven" mice is similar. Secondary lesions tend to develop close to primary lesions. In "shaven" mice several satellite lesions appear simultaneously around the initial lesion (Fig.16). These often coalesce with one another and with the primary lesion to form one large nodule. In hairless mice the secondary lesions develop in the same



Fig.55 Shaven x albino mouse showing metastasis of L.b. pifanoi (strain V1) to all hairless parts of the body, 18 months after infection.

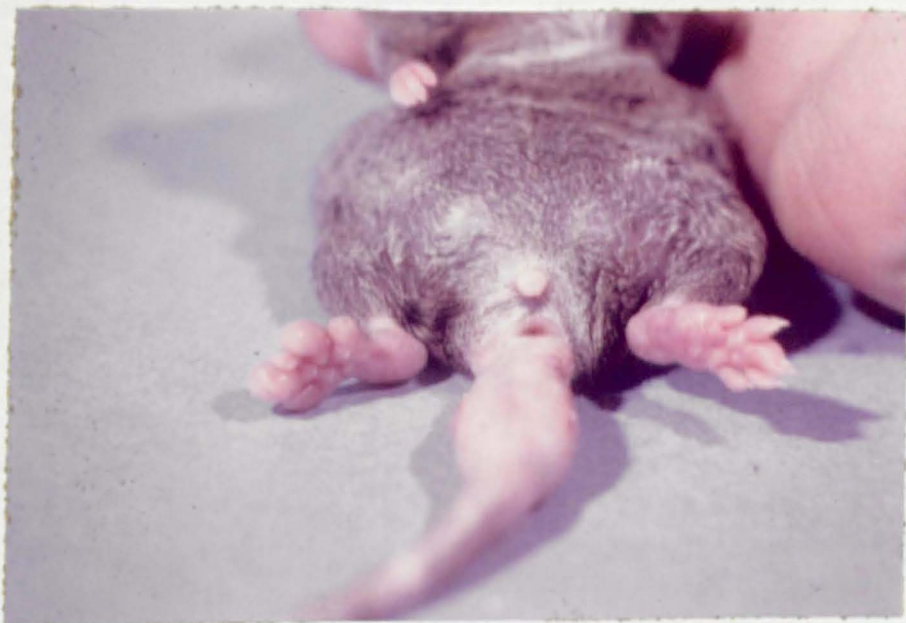

Fig.56 Shaven x albino mouse showing metastasis of the parasite from the site of inoculation at the base of the tail to the rest of the tail and the hind limbs, 12 months later.



Fig.57 "Bead-like" nodular lesions on tails and metastasized lesions on hind limbs of hybrid mice.
mouse

part of the body as the initial lesion. No satellite lesions are, however, formed around the primary lesions.

This stage is followed by the development of more secondary lesions on the paws, snout, or ears (Fig.58). Later, scattered lesions may appear on the back, the scrotum or penis. In "shaven" and hairless mice the regional lymph glands may become enlarged and palpable. This generalized infection may interfere with the health, feeding and defaecation of the animals. Hairless mice are more severely affected. They lose weight, their skin becomes wrinkled and they usually die within 7 to 8 months.

All the secondary lesions of mice remain nodular and do not ulcerate.

Histopathy of Diffuse Cutaneous Leishmaniasis in Hamsters and Mice

Before describing the histopathological changes in the skin following infection with Leishmania brasiliensis pifanoi it is essential to give an account of the normal skin histology of rodents. The albino mouse is chosen as an example.

1. The histology of the normal skin of albino mice (Fig.60)

Except in certain regions or in mice of certain genotypes (hairless and "shaven" strains), the skin bears hair over its greater part. Hairless skin surrounds and extends for a variable distance around all external openings (nipples, nostrils, mouth, urethra, vagina and anus). The skin consists of

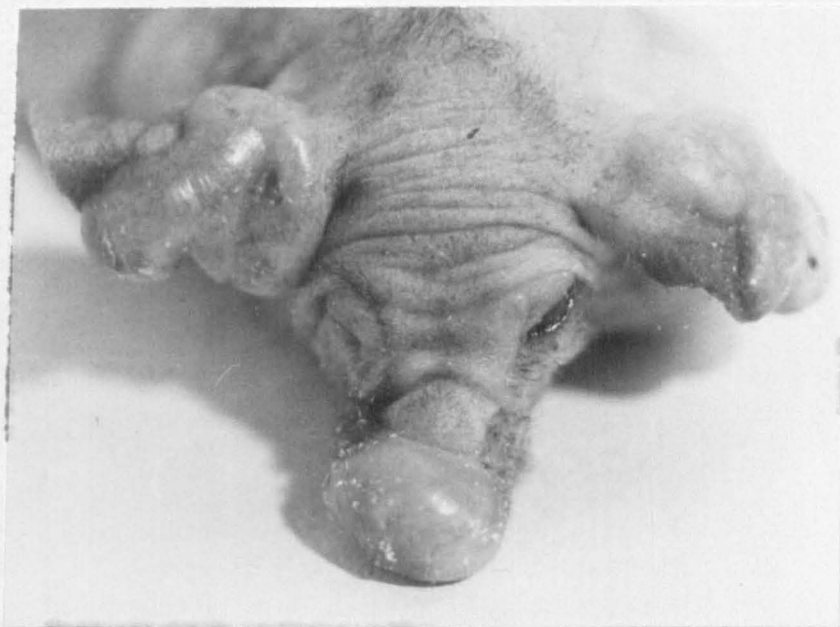

Fig.58 Secondary lesions on snout and ears of "shaven" mouse inoculated at base of tail.




Fig.59 Same mouse as in Fig.58 showing enlarged lymph glands due to secondary bacterial infection.

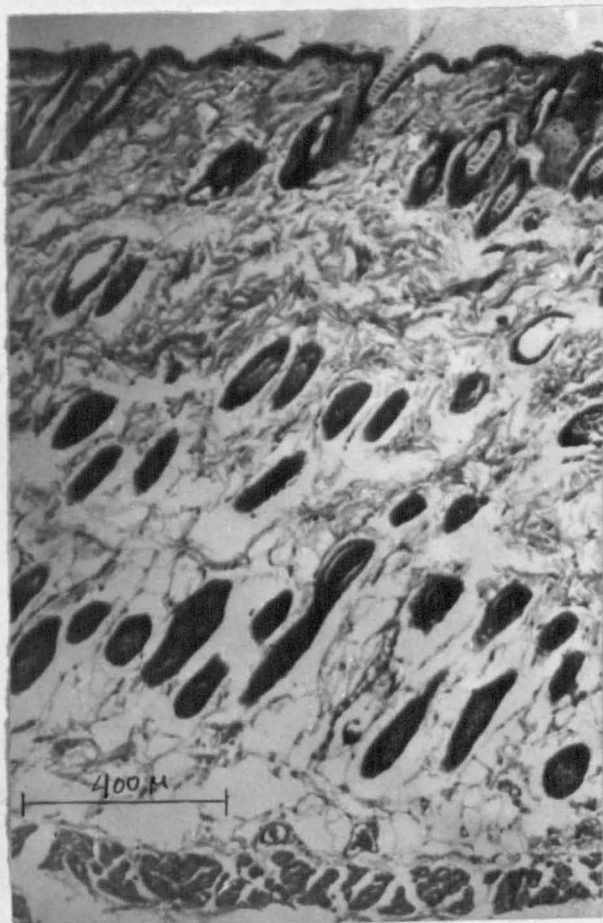


Fig.60 Section of normal skin of albino mouse,
Giemsa stain X 40.

of two parts - an outer epidermis of stratified squamous epithelium and an inner dermis or corium of dense connective tissue, continuous with adipose and loose connective tissue of the subcutaneous areas.

The epidermis:

This is thin in hairy areas, and considerably thickened on the hairless or relatively hairless parts, e.g. feet, tail, snout, nipples, genital and anal areas. In these thick areas there are three or more strata, each of several cell layers. The basal layer, the stratum germinatum, rests on a basement membrane and consists of vertically compressed cells with indistinct cell outlines and clear oval nuclei, plus several layers of polyhedral cells connected across intercellular spaces by fibrils. The next four or five layers of cells, which are compressed horizontally and may contain coarse keratohyalin granules, make up the stratum granulosum. The outermost stratum corneum is composed of several layers of dead cornified cells that are shed at the surface and replaced from deeper layers.

In hairy areas the epidermis rarely exceeds 6 cell layers and the strata are hard to define. The basal cells of the stratum Malpighum are cuboidal, the stratum granulosum is represented by a few scattered cells, and there are only one or two layers of cells in the stratum corneum.

The epidermis is well developed at birth, becomes thicker during the first four to five days after birth and then increases as the hair follicles

develop. There are no blood vessels or nerves in the epidermis and although melanocytes, potentially capable of producing pigment, are scattered amongst the basal cells, pigment is usually not detectable in epidermal cells.

The dermis:

The connective tissue of the dermis contains collagenous and elastic fibres, blood vessels, nerves, fat cells and strands of smooth muscles (the erector pili muscles). In the head, neck and trunk regions thin sheets of striated muscle (the *panculus carnosus*) insert on the fibres of the dermis at its boundary with the subcutaneous tissue.

Branched melanocytes containing pigment are cellular components of the dermis in pigmented areas, e.g. muzzles, ears, soles of feet, tail, external genitalia and scrota; but they are not demonstrable in the dermis of hairy areas. Where the epidermis is thick, the epidermal boundary is uneven, because the dermis with its blood vessels and nerves is extended into the epidermis in tall elevations or papillae. In hairy areas dermal papillae are inconspicuous and the boundary between the dermis and epidermis is only slightly uneven.

The loose connective tissue on which the dermis rests becomes transformed soon after birth into an adipose layer of packed fat cells.

Hair and sebaceous glands:

Hair follicles are invaginations of the epidermis into the dermis giving rise to hair, both pelage and tactile, and to sebaceous glands.

Below the skin surface the hair shaft is enclosed in a double sheath or follicle at the base of which the hair matrix is formed by proliferation of epidermal cells.

Sebaceous glands are associated with hair follicles. Each gland is a pear-shaped structure surrounded by a basement membrane and dermal connective tissue. There are two layers of cells, an outer basal layer of thin flat cells, and an inner layer of large round secretory cells. These latter accumulate secretion, die, disintegrate and are replaced from the basal layer.

The skin of hamsters is very similar to that described for mice. Unlike human skin, the skin of rodents does not contain sweat glands.

2. Histopathology of the cutaneous lesions of hamsters

i) Primary lesions:

Smears prepared from the site of inoculation, 36 to 48 hours after intradermal inoculation of the parasite, reveal an acute inflammatory tissue reaction in the area. This consists of polymorphonuclear leukocytes and

plasma cell infiltration. The polymorphonuclear leukocytes engulf the amastigotes by phagocytosis, each cell taking up several to many parasites. The phagocytosed amastigotes are destroyed within these inflammatory cells. The local histiocytes of the skin also engulf some parasites. Far from destroying the amastigotes these histiocytes act as an ideal medium for the protection of the parasites from other destructive inflammatory cells and for the multiplication of the Leishmania cells. Eventually the engorged histiocyte bursts or it may divide into two infected cells and the released amastigotes are picked up by other histiocytes or by other inflammatory cells.

Smears taken a week later reveal histiocytes and a few plasma cells, but most of the neutrophils and other leukocytes have disappeared from the area.

Histological sections of lesions at the stage when they first become visible, 3 to 12 weeks after inoculation, reveal masses of histiocytes packed with parasites, lying within the lymphocytic spaces of the dermis. The histiocytes have a vacuolated appearance. The parasites appear to be lodged within the cytoplasm. Stages of the multiplication of the parasite within the histiocytes may be observed in smears. Some histiocytes contain one or two parasites, usually just within the cell margin, others show clusters of 4 to 8 amastigotes, which remain close together and appear to be the result of

multiplication of the engulfed parasites, while other histiocytes are packed full of parasites (Figs.61, 62).

Histological sections of the lesions during the following 3 to 4 months reveal a slow growth of the lesion by the infection of more histiocytes and the gradual expansion of the focus of infection towards the epidermis. No striking changes in the epidermis are observed. The epidermis is usually separated from the infected dermis by a clear zone which is free of parasites. In sections this zone appears to consist of collagenous fibres which stain pale pink with Giemsa's stain. The dermis becomes thickened and its cellular structure destroyed by the invasion and multiplication of very large numbers of infected histiocytes (Figs.63, 64).

The dermal lesion may consist of a compact granuloma of heavily parasitized histiocytes, or of loose aggregates of these cells surrounded by oedematous exudate.

At a later stage in the development of the primary lesion, 6 to 8 months after inoculation, the subpapillar clear zone may become invaded by infected histiocytes. This invasion may be so marked that the spaces become obliterated, and masses of Leishmania-engorged histiocytes come to lie in contact with the Malpighian layer of the epidermis. In such cases it is not unusual to find infected histiocytes within the Malpighian layer. These infected histiocytes may be individually scattered through the Malpighian

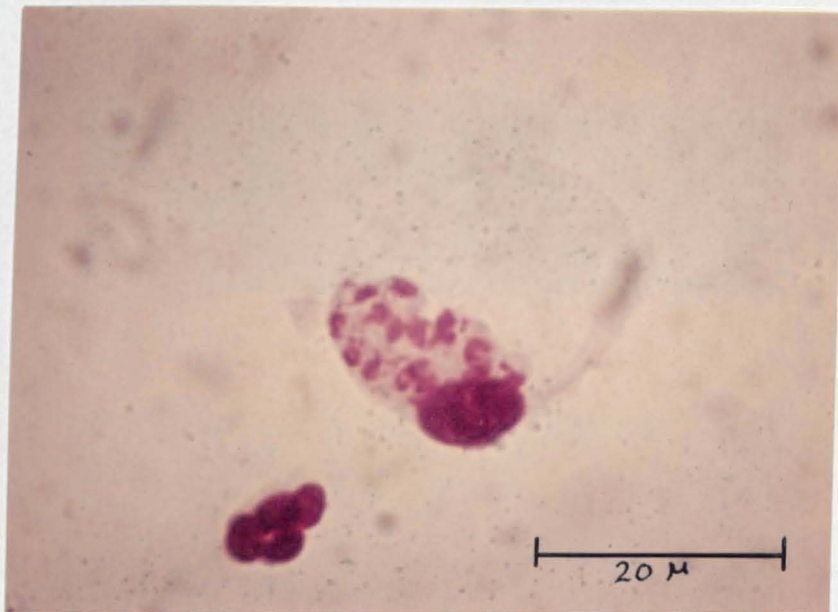


Fig.61

An infected macrophage from a smear of a primary lesion of a hamster. Note the clustering of the parasite at the nuclear end of the cell. Giemsa-stained smear (X 1000).

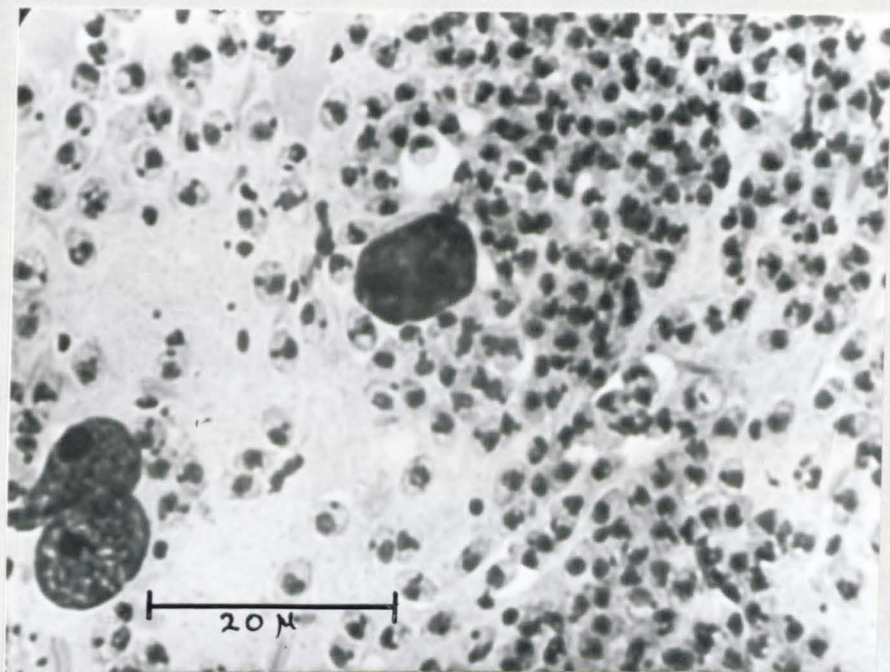


Fig.62

Smear from a nodular lesion of a hamster, showing histiocytes packed with amastigotes. Few akinetoplasmic free amastigotes may also be seen. Giemsa's stain.

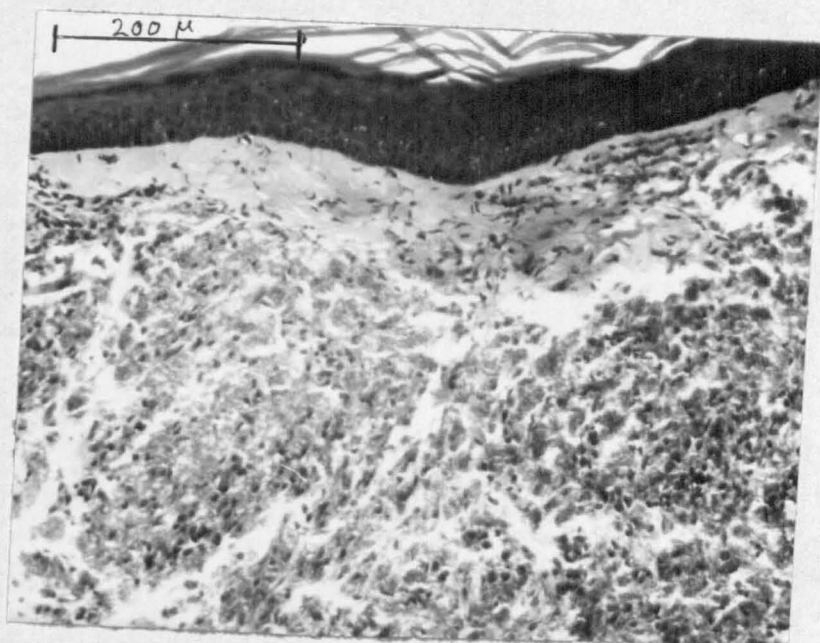


Fig.63

Section of hamster skin showing hyperkeratosis, and slight thickening of the epidermis, destruction of the papillary layer with some breakdown in the clear zone of the sub-papillary region. Note the loose arrangement of the infected histiocytes. Haematoxylin and eosin (X 100).

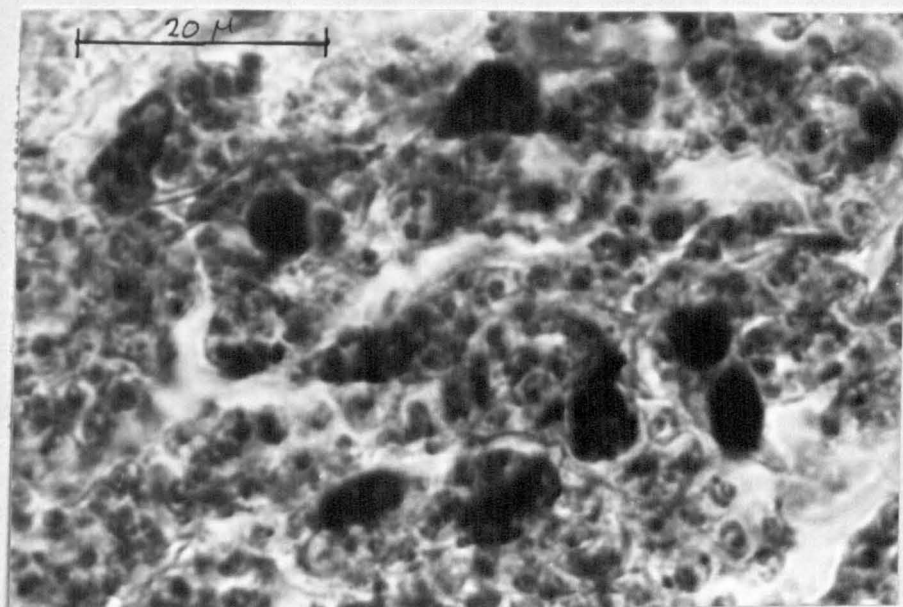


Fig.64

Section of the dermis of hamster showing many very heavily infected histiocytes. Haematoxylin and eosin (X 1000)

layer or they may be grouped together in the form of microabscesses (Figs. 65, 66). These "microabscesses" appear as regular, ellipsoidal spaces, 135-200 μ long and 70-125 μ broad. They are usually located superficially in the Malpighian layer. In the neighbourhood of these spaces, the cells of the Malpighian layer lose their shape and appear to become more compact. A layer of this compact tissue surrounds the "microabscess" and isolates it from the rest of the epidermis. These "microabscesses" are commonly seen in places where other areas of the Malpighian layer are invaded by parasitized histiocytes.

Within the space of the Malpighian layer, the microabscesses consist of large, conspicuous polymorphs and parasitized histiocytes. The latter are most common along the inner margin of the abscesses. The interior of the abscess has a vacuolated loose appearance. It is not certain whether this is due to the presence of oedematous fluid or to fixation artifacts.

In the later stages of development of the dermal lesion, parasitized histiocytes invade the deeper layers of the dermis and extend into the subdermis, which becomes packed with the infected cells. Often the infection extends into the deeper subcutaneous muscular layers, heavily parasitized histiocytes are seen within the interstitial and lymphatic spaces between the muscle fibres or bundles (Fig. 67). This causes destruction of some of the fibres and the compression and atrophy of others.




Fig.65 A section of skin of infected hamster showing histiocytic granuloma in the deep dermis, extending upward to the subpapillary zone and invading the epidermis. Note the formation of the microabscess within the Malpighian layer of the epidermis. Giemsa's stain (X 100).

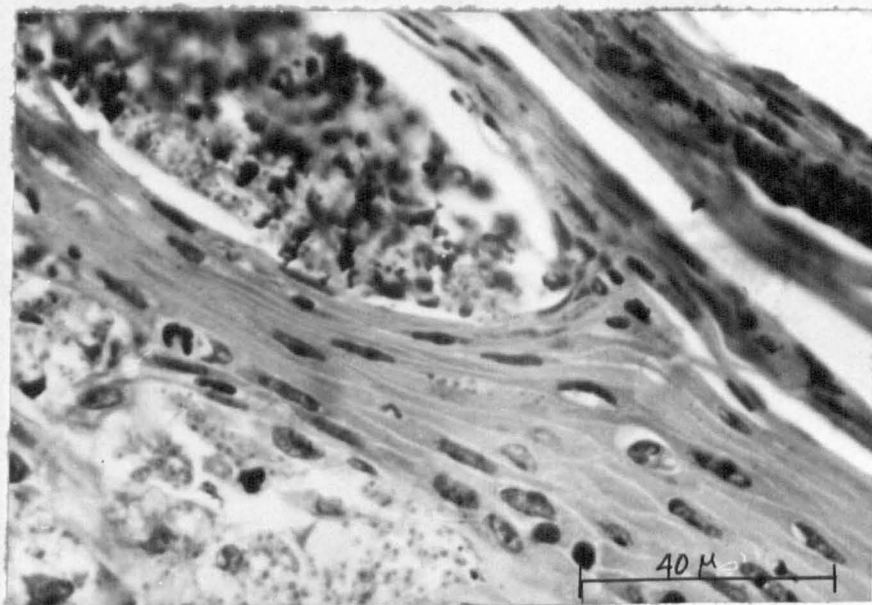


Fig.66 The same section in Fig.65 with higher magnification showing heavily parasitized histiocytes in the papillary zone, Malpighian layer and in the micro abscess. Giemsa's stain (X 400).

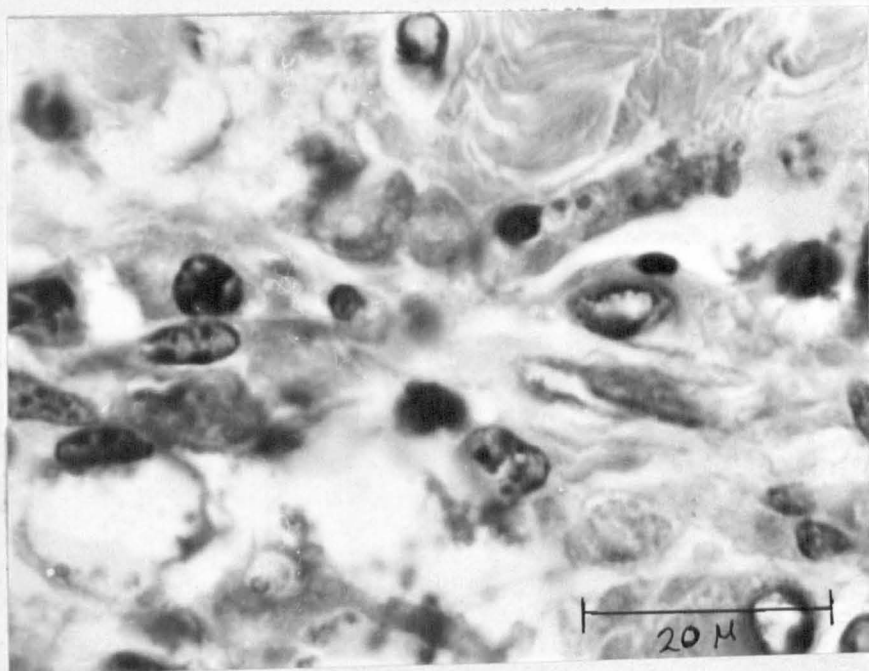


Fig.67 Parasitized histiocytes amongst the muscle fibres of the deep subdermis of a hamster. Haematoxylin and eosin (X 1000).

The papillae of the dermis are destroyed in the advanced stages of the disease.

ii) Secondary lesions:

Histological sections of the lesions formed as a result of metastasis show that most of the lesions start within the dermis. The lesion starts as a small nodule which follows the same stages of development and has a very similar histological structure to that of the primary lesion.

The extension of the lesion never invades the subpapillar clear zone. The lesion does not ^{usually} extend beyond the subdermal layer into the subcutaneous tissues.

The histopathological picture of the lesion varies slightly according to the part of the body to which the parasite becomes disseminated.

Secondary lesions of the ear:

The Malpighian layer of the epidermis becomes thickened, and the stratum corneum shows slight hyperkeratosis.

The gradual growth of the dermal nodule pushes the sebaceous glands and hair follicles upwards towards the epidermis. There is a significant decrease in the number of these follicles and glands in the infected area compared to healthy ear skin.

The growth of the lesion leads to severe destruction of the dermis

which becomes largely replaced with a histiocytic granuloma and scattered plasma cells. The parasites are restricted to the dermal and subdermal layers of the skin and do not invade the cartilage of the ear. The dermis of the inner surface of the ear may become invaded by the creeping of the lesion around but not through the cartilage. The cartilage does not show signs of erosion or atrophy even when the ear becomes transformed into a huge nodular mass (Fig.68).

Secondary lesion of the foot:

Thickening of the Malpighian layer is noted in places in the epidermis, up to 5 layers of cells may be seen. The stratum corneum loses its compact structure, becoming loose and showing signs of hyperkeratosis.

The dermis reveals hyperplasia, mainly due to the histiocytic granuloma. Blood vessels are surrounded by parasitized histiocytes, but no parasites were detected within the lumen or lining of the capillaries.

The dermis remains isolated from the epidermis by a clear zone of collagenous fibres (Fig.69).

Secondary lesion of the snout:

The structure of the lesion on the snout is very similar to that described for the foot.

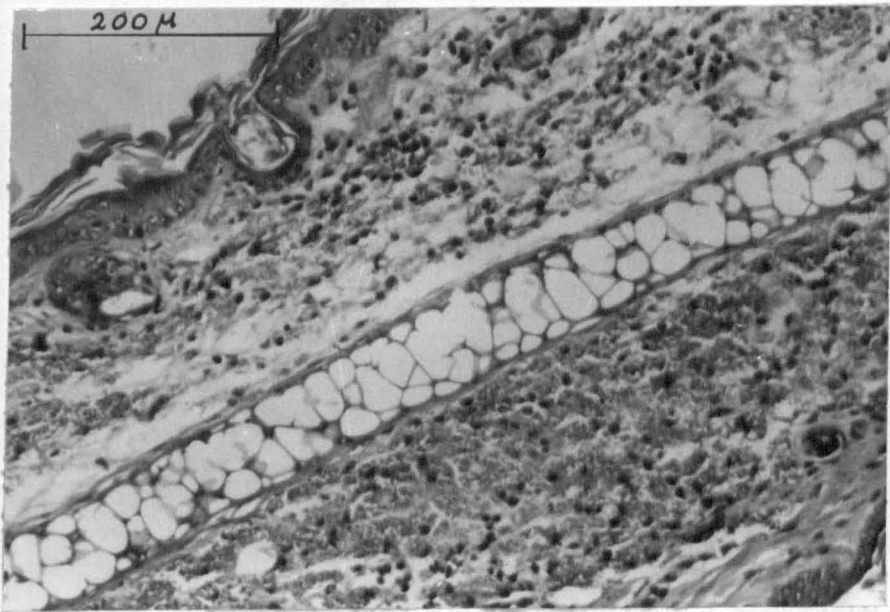


Fig.68 Section through secondary lesion on the ear of a hamster, showing histiocytic granuloma in the dermis, and parasite clear cartilage. Haematoxylin and eosin (X 100).

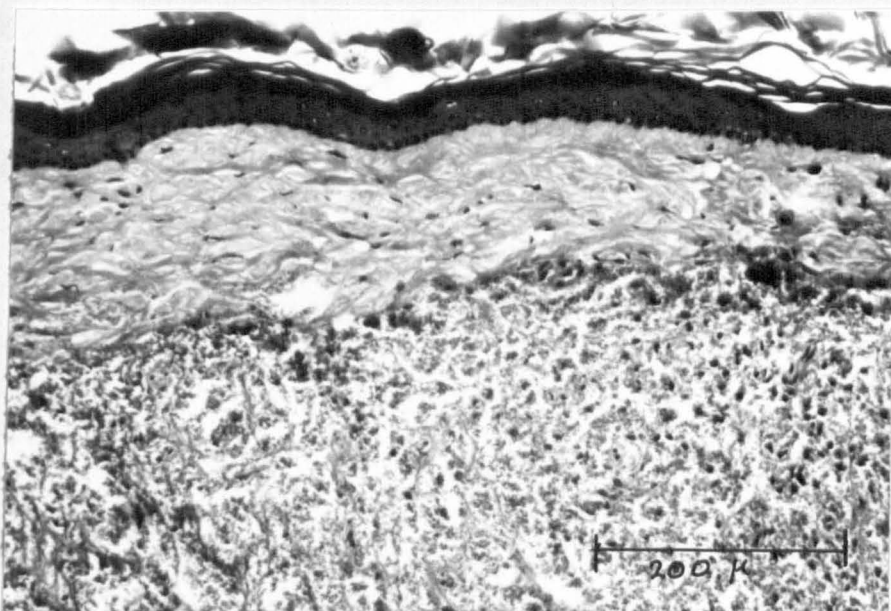


Fig.69 Section through secondary lesion on the foot of a hamster. Haematoxylin and eosin (X100)

Secondary lesion of the scrotum:

This type of lesion usually follows intraperitoneal inoculation.

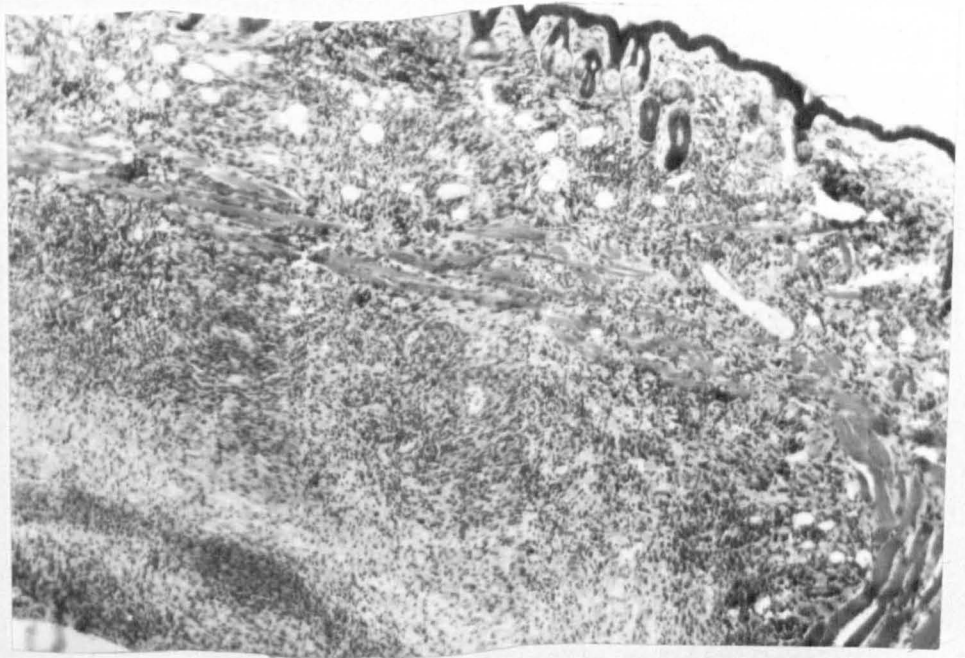The first lesion develops in the tunica vaginalis, followed by the invasion of the deeper parts of the scrotum. The testicular follicles and seminiferous tubules do not become invaded. Later the infection extends to the epididymis and interstitial spaces of the tubules, this invasion being usually accompanied by lymphocytic infiltration. The lesion grows very slowly in this part of the body and remains isolated from the epidermis by the thick layer of collagenous fibres. The epidermis is not affected.

3. Histopathology of the cutaneous lesions of mice


Primary lesions:

The development of the primary lesions in all three strains of mice followed a similar pattern to one another and to that described for hamsters.

In the early stages of infection, 36 - 48 hours after the injection of the parasite, smears from the site of inoculation showed an acute inflammatory reaction, with infiltration of polymorphnuclear cells and plasma cells. A large number of amastigotes were found lying within histiocytes. The inflammatory cells gradually disappeared from the affected area of skin. Sections from the site of inoculation 3 to 4 weeks after inoculation showed a granuloma of histiocytes (Fig.70, 71), each cell being full of amastigotes. Extra-cellular parasites were also observed. A few plasma cells, together with some



a



b

Fig.70

Two magnifications of a section through the snout of an infected mouse, showing mononuclear cell infiltration into the deep subdermal layer. Haematoxylin and eosin - Fig a. (X 12); Fig. b (X 100).

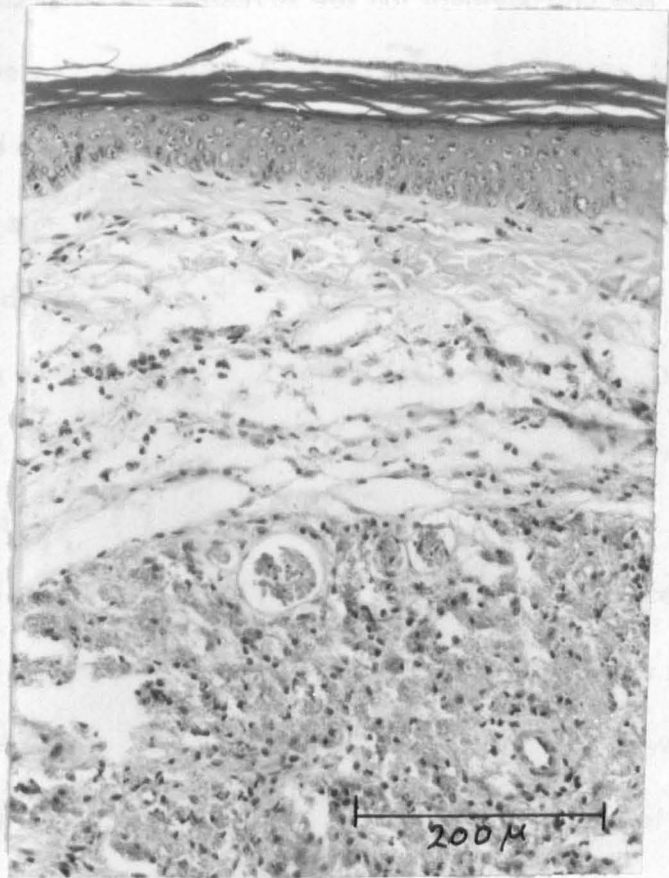


Fig.71 Section of infected mouse skin showing histiocytic granuloma in the deep dermis, clear sub-epidermal zone, destruction of the papillary layer and thickening in the Malpighian layer with hyperkeratosis. Haematoxylin and eosin (X 100).

histiocytes were also present in the inflammatory area.

The histiocytic granuloma extended between the collagen fibres of deeper parts of the dermis up to almost the Malpighian layer of the epidermis. At this stage the epidermis was not involved and was separated from the infected region of the dermis by a clear zone (Figs.72, 73).

The blood capillaries of the dermis in the infected area became congested, and were surrounded by histiocytes. No parasitized macrophages were seen within or in direct contact with these vessels (Fig.74).

The lesion extended deeply into the dermis as well as the subdermis (Figs.75, 76). At its lower end the lesion showed signs of fibrosis, and monocyctic infiltration.

In slightly older lesions (2 to 3 months old), in albino mice, the nodule was larger in size and the lesion extended further into the subdermis as well as through the clear zone up to the Malpighian layer. In "shaven" and hairless mice, the parasites invaded the epidermis at this stage (Fig.77, 78). Infected histiocytes were observed within the Malpighian layer. In all three strains of mice the epidermis became acanthotic, thickened with signs of hyperkeratosis (Fig.79).

The histiocytes within the dermis were more heavily infected with Leishmania than those in the epidermis. The dermis became largely replaced by these heavily infected histiocytes. Parasitized histiocytes were seen ringing the hair follicles and sometimes within them (Figs.80, 81). The

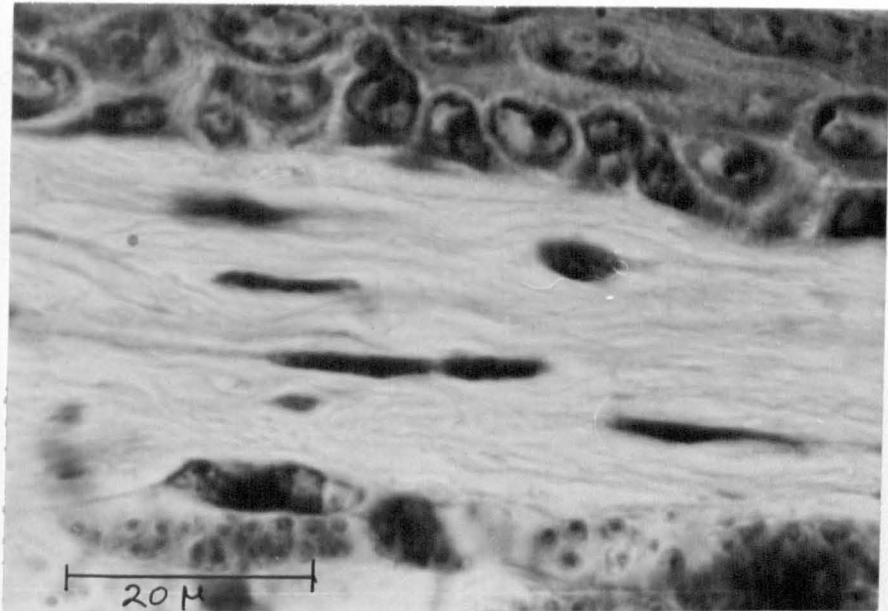


Fig.72 A section of skin of a mouse showing the clear subpapillary zone. Haematoxylin and eosin ($\times 1000$)

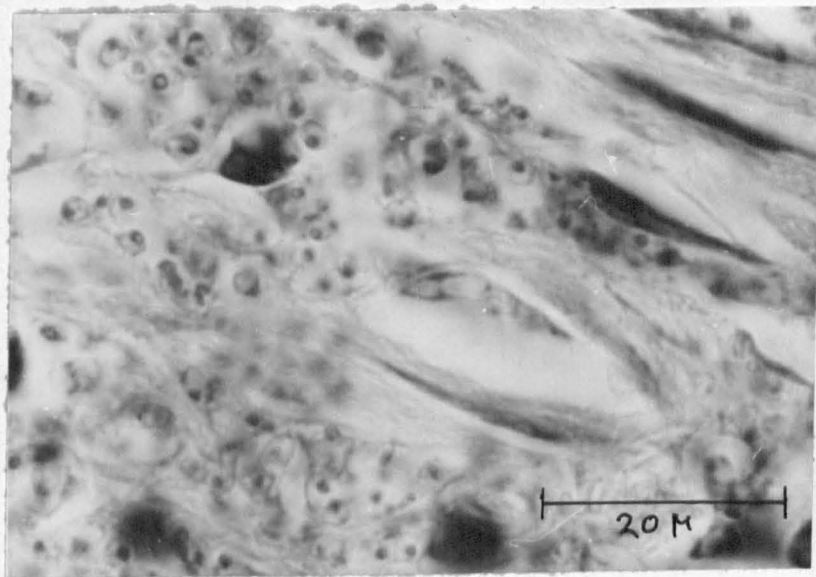


Fig.73 The same section showing parasites in the dermal layer of the skin. ($\times 1000$)

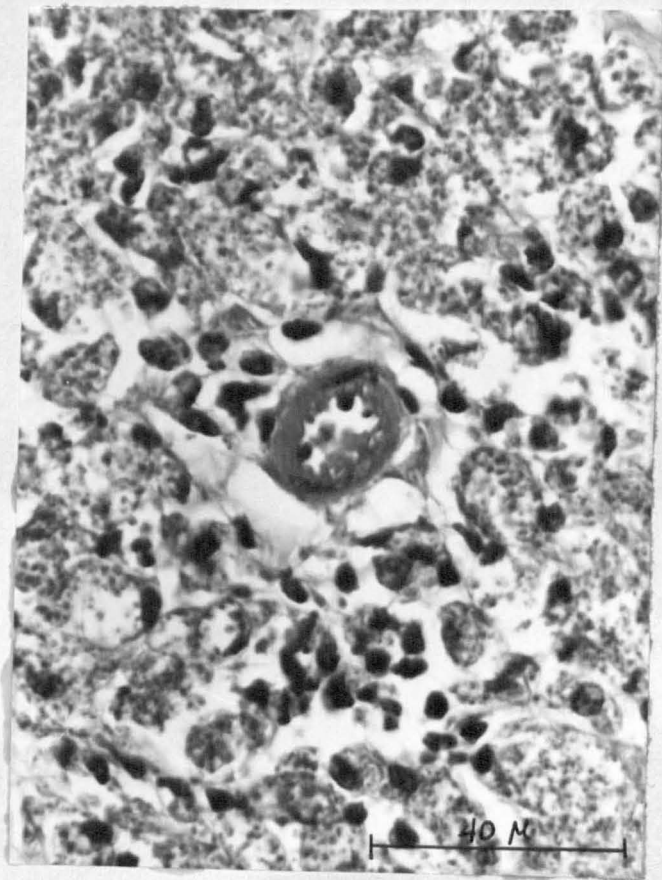


Fig.74 Section of skin of snout of a mouse showing intense histiocytic proliferation in the dermis. The blood vessel is surrounded by a clear area. Haematoxylin and eosin (X 400).

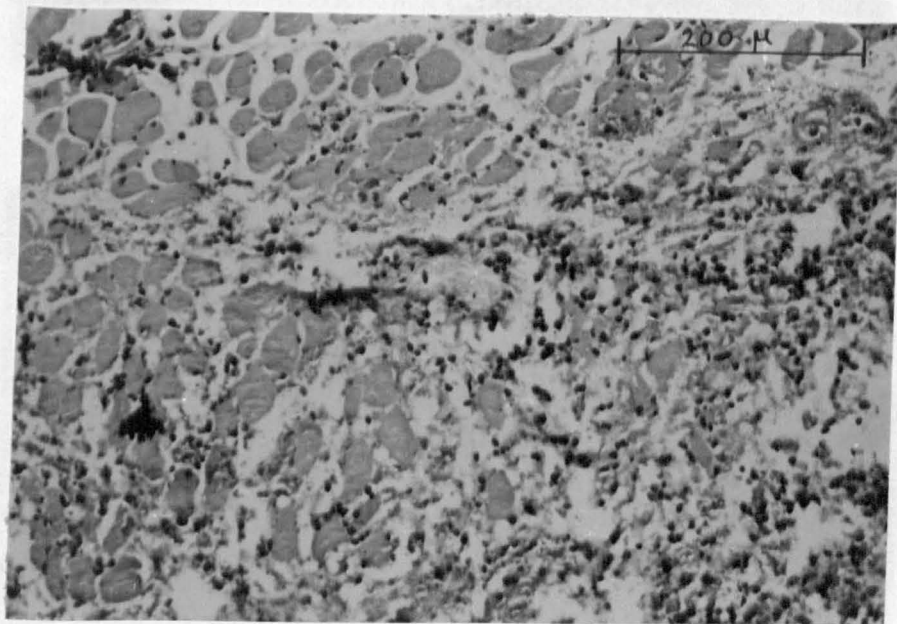


Fig.75 Section through the subdermal muscular layer of a hairless mouse showing massive cellular infiltration and degeneration of the muscle fibres. Haematoxylin and eosin (X 100).

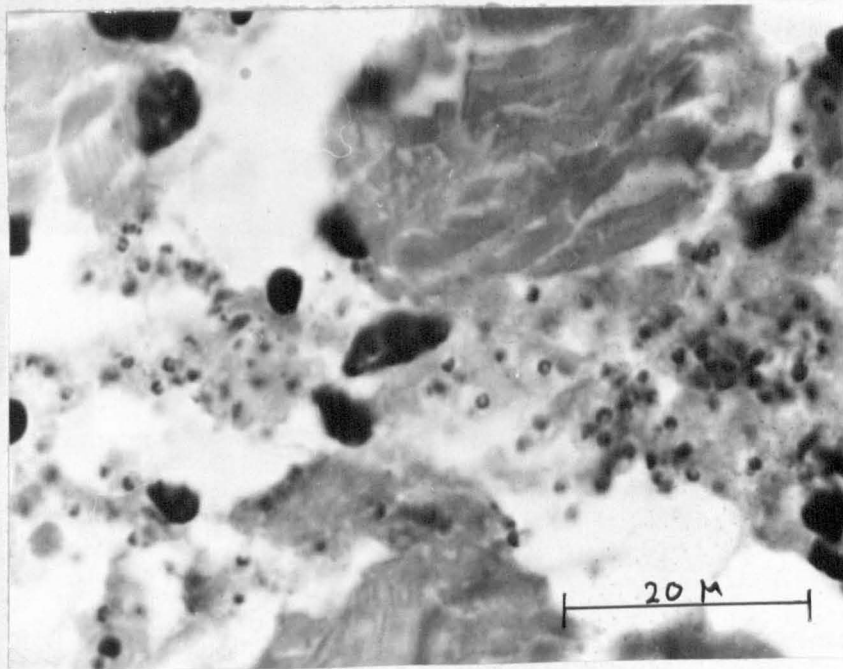


Fig.76 Higher magnification of Fig.75 showing a large number of amastigotes amongst disintegrating muscle fibres. Haematoxylin and eosin (X 1000).

244
244

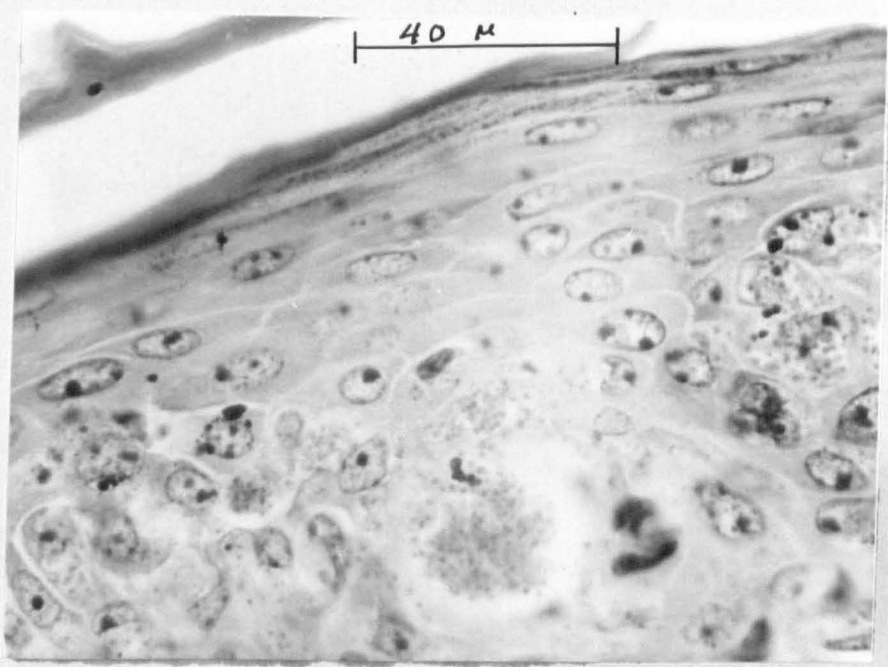


Fig.77 A section of the epidermis of a shaven mouse showing infiltration with a large number of infected histiocytes. Haematoxylin and eosin (X 400).

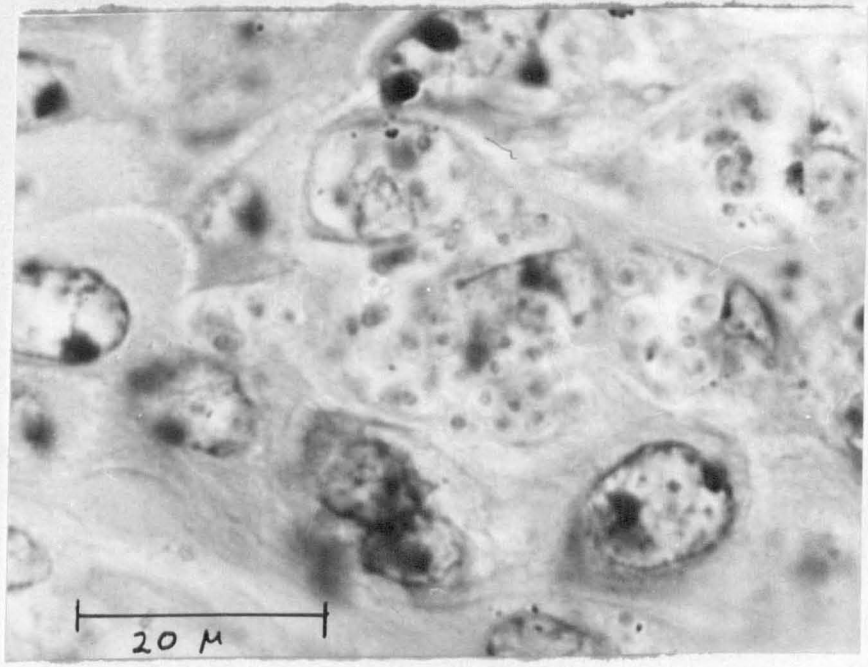


Fig.78 Higher magnification of same section. (X 1000).

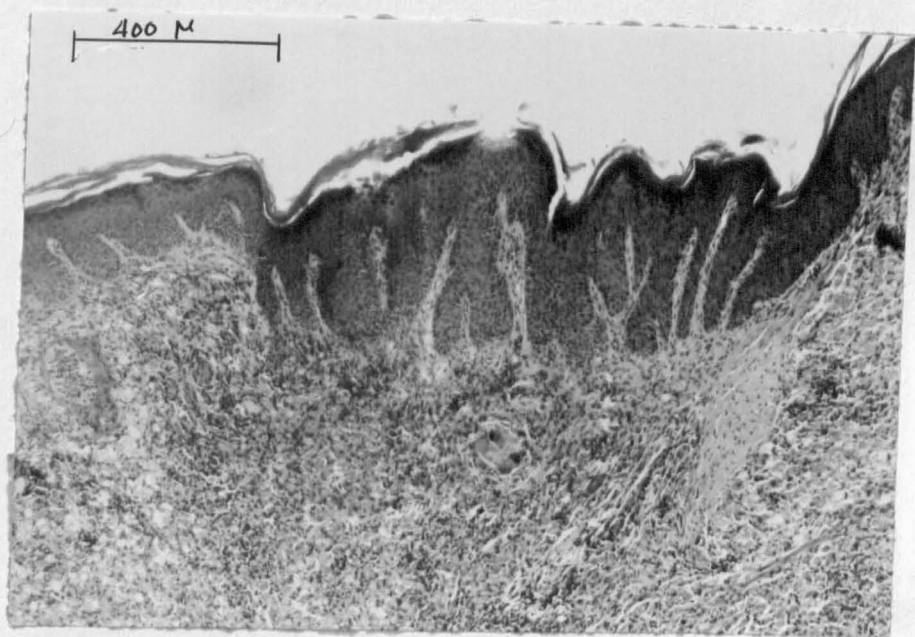


Fig.79 A section through the lesion of the snout of ("shaven" x albino) mouse. Note the acanthosis and moderate hyperkeratosis of the Malpighian layer. Haematoxylin and eosin ($\times 40$).

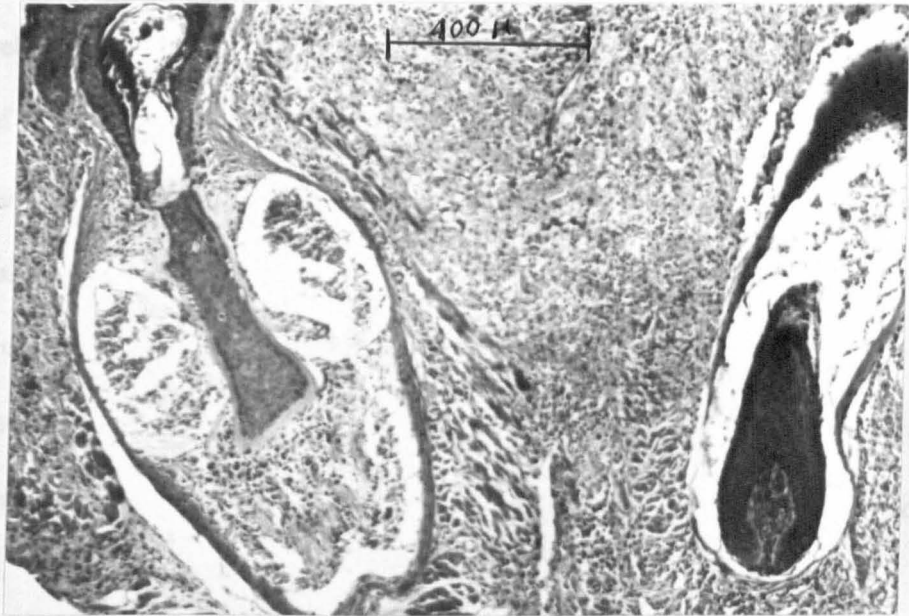


Fig.80 Section of skin of the snout showing a dense infiltration of infected histiocytes in the dermis involving the follicles of the sensory bristle, and slight acanthosis of the epidermis. Giemsa's stain (X 40).

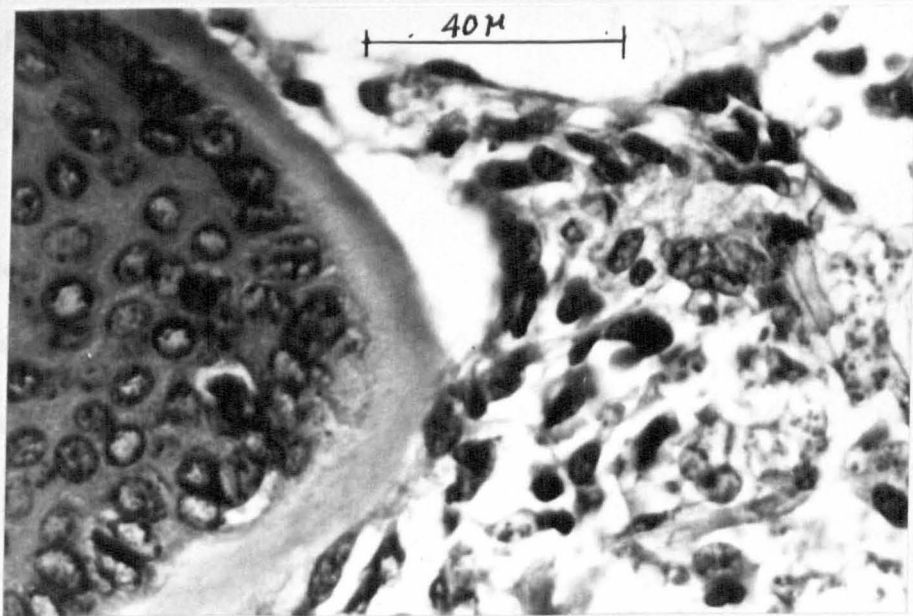


Fig.81 Higher magnification of the basal part of the follicle of the snout bristle in Fig.80 showing many infected histiocytes and some lymphocytes and plasma cells. Giemsa's stain (X 400).

pressure of these cells caused a gradual degeneration and decrease in number of these follicles. The sebaceous glands may be invaded (Fig.82). In very heavily infected lesions, the blood vessels of the dermis were surrounded by, and often in direct contact with, the infected macrophages. No parasites were observed within the lumen of these blood vessels.

Sections of lesions during the following 2 to 3 months did not show any remarkable changes, except that the parasite invaded the subdermal muscular layer. This was most noticeable in hairless mice where it led to severe muscular degeneration and atrophy.

Sections of ulcerating lesions showed a very thin epidermis which had lost its stratum corneum, and assumed a compressed appearance, along the margin of the crater. The centre of the lesion was covered by an exudate of polymorphs. The bottom of the dermal crater of the ulcerating lesion showed some granulation tissue which appeared to be undergoing necrosis.

Secondary bacterial infection due to bacilli or cocci often took place, resulting in purulent discharge from the centre of the lesion (Fig.83). In these cases the margin of the lesion was surrounded by large vacuolated histiocytes, lymphocytes and plasma cells, acting as a wall to separate the deep *Leishmania*-infected skin from the region of secondary bacterial infection.

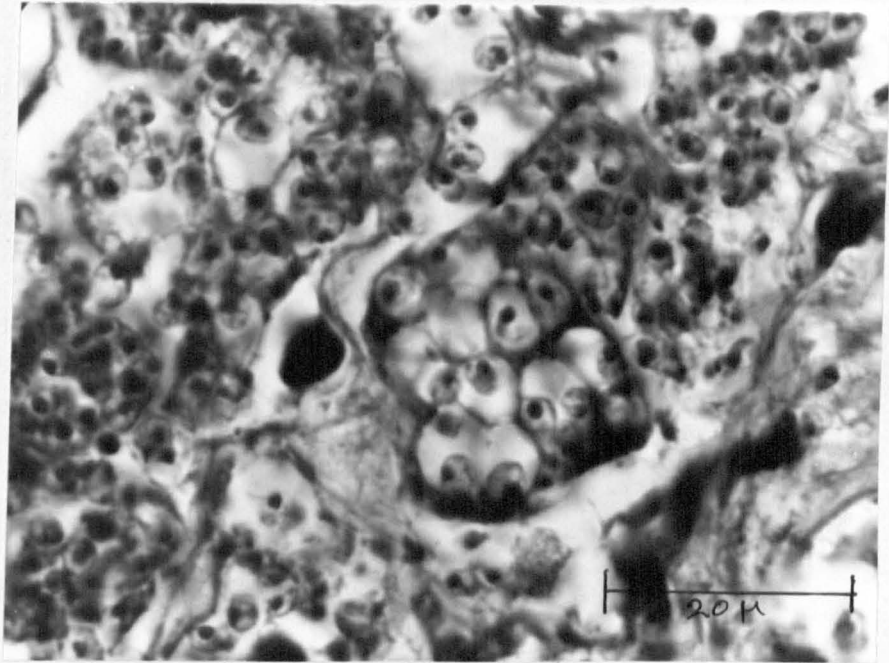


Fig.82 Section of the dermis of an infected mouse showing parasites in the sebaceous glands. Haematoxylin and eosin (X 1000).

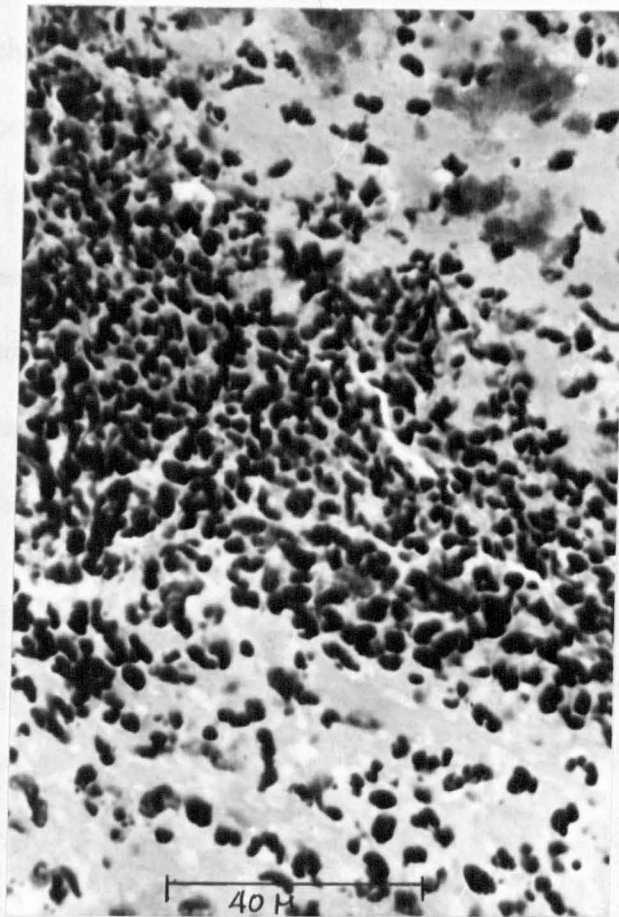


Fig.83 Section of ulcerated lesion of a mouse, showing secondary bacterial infection near the surface of the lesion, isolated from the deeper Leishmania infected zone by an infiltrate of polymorphonuclear cells. Giemsa's stain (X400).

In the flat type of lesion, no great changes in the structure of the skin were observed. The lesion extended into the subcutaneous muscular layer. Within the dermis the parasite was found in the histiocytes within the lymphatic spaces of this layer of the skin, distributed in horizontal bands along collagen fibres. The infection was heavier in the deeper parts of the dermis and subdermis.

The blood vessels near the base of the lesion were dilated. The papillary layer remained clear of parasites. The corneum was slightly thickened and showed signs of hyperkeratosis.

Metastasis:

Microscopically the secondary lesions which appeared after metastasis were very similar to those described in hamsters. The clear zone remained uninvolved (Fig.84). The structure of the secondary lesions on the snout, and scrotum is shown in Figs.85, 86, 87, 88, 89, 90, 91, 92 and 93.

The parasite was observed in smears of liver and bone marrow of 2 mice strain C 57 out of 8 examined, following intradermal inoculation with strain VI (Fig.94). Sections of the infected liver failed to reveal parasites or detectable histopathological variations.

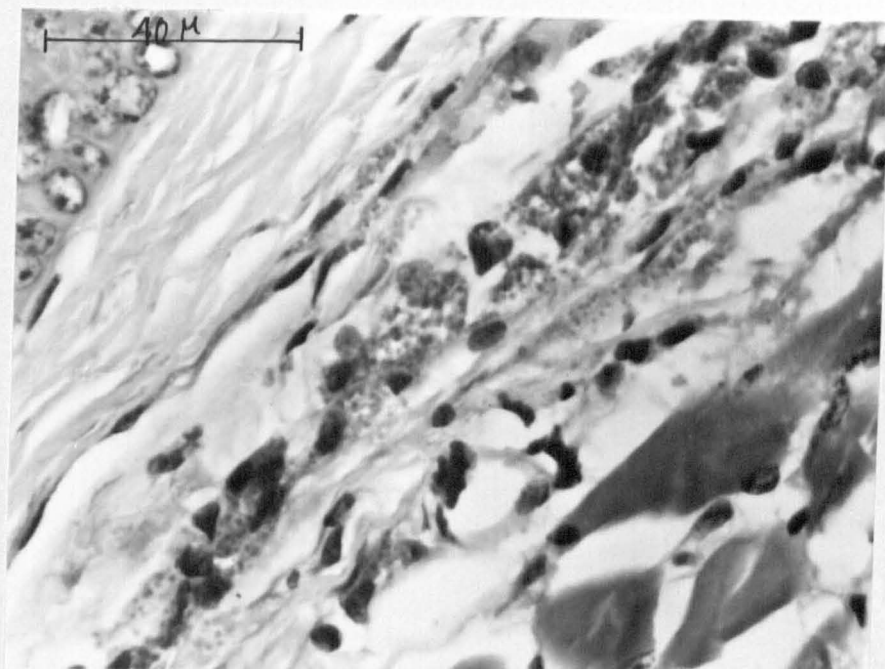


Fig.84 Section through a secondary lesion on the foot of a hairless mouse, showing the extension of the parasitized histiocytes between the collagen fibres of the deep dermis. Haematoxylin and eosin ($\times 400$).

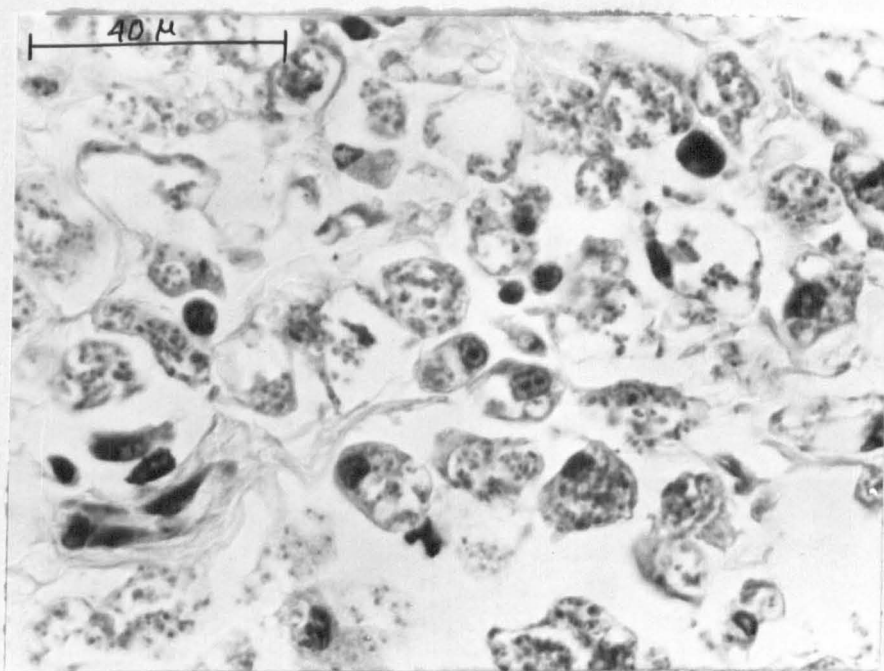


Fig.85 Section through a secondary lesion on the snout of a hairless mouse. Note the vacuolated appearance of the infected histiocytes and their loose arrangement. Giemsa's stain ($\times 400$).

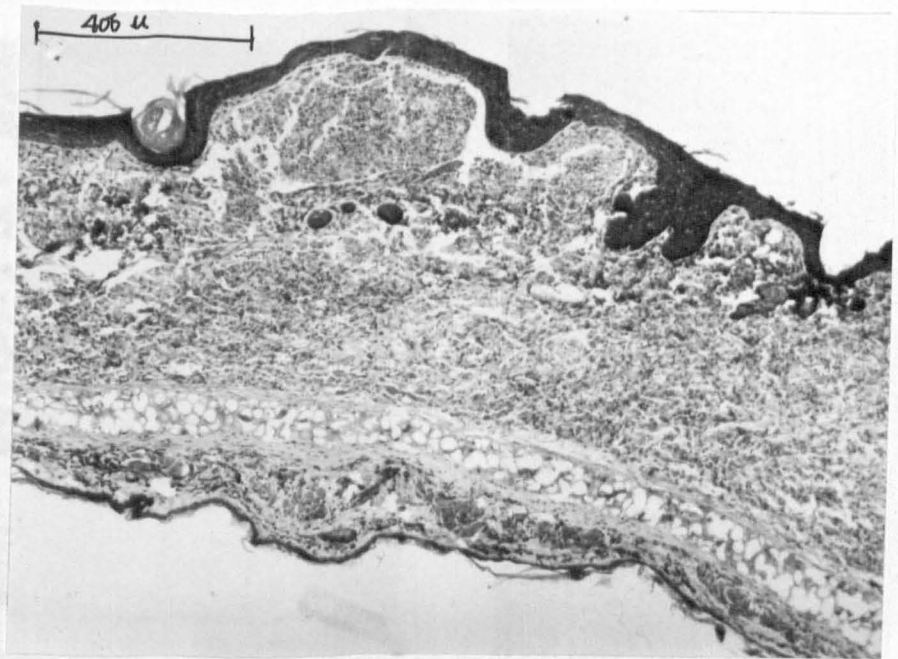


Fig.86 A section through the ear of an albino mouse showing thickening of the epidermis on the infected side of the ear compared to that of the healthy part. Haematoxylin and eosin (X 40).

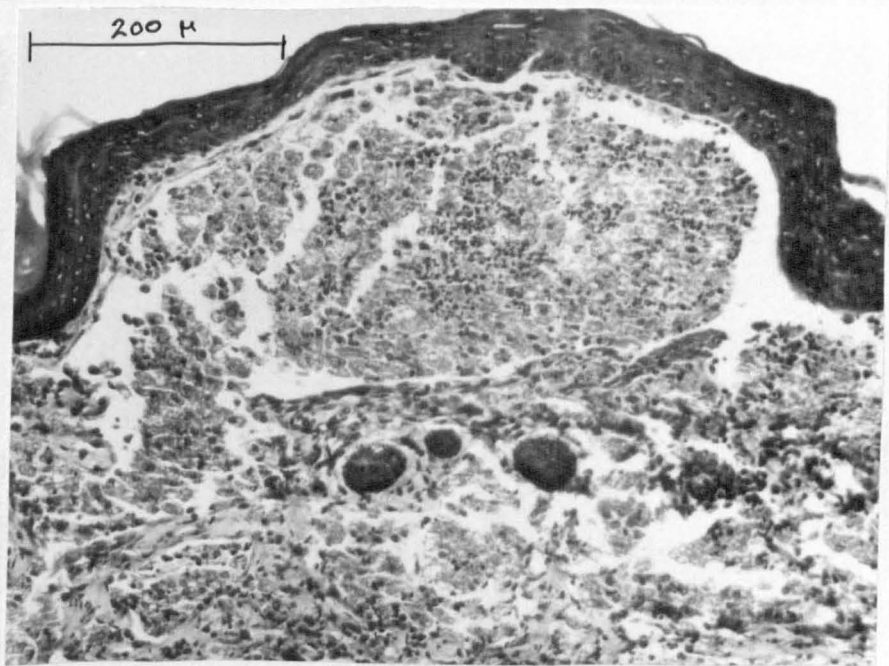


Fig.87 The same section at a higher magnification showing the involvement of the clear zone (X 40).

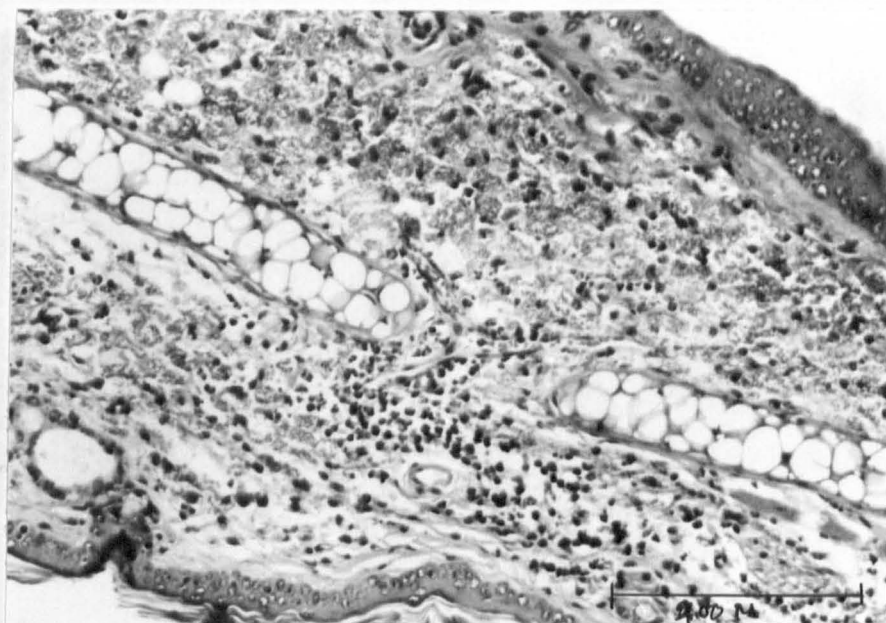


Fig.88

Section of a secondary lesion on the ear of a hairless mouse showing thickening in the epidermis, histiocytic granuloma in the dermis extending through a break in the ear cartilage to the dermis of the inner surface of the ear. Haematoxylin and eosin (X 100),

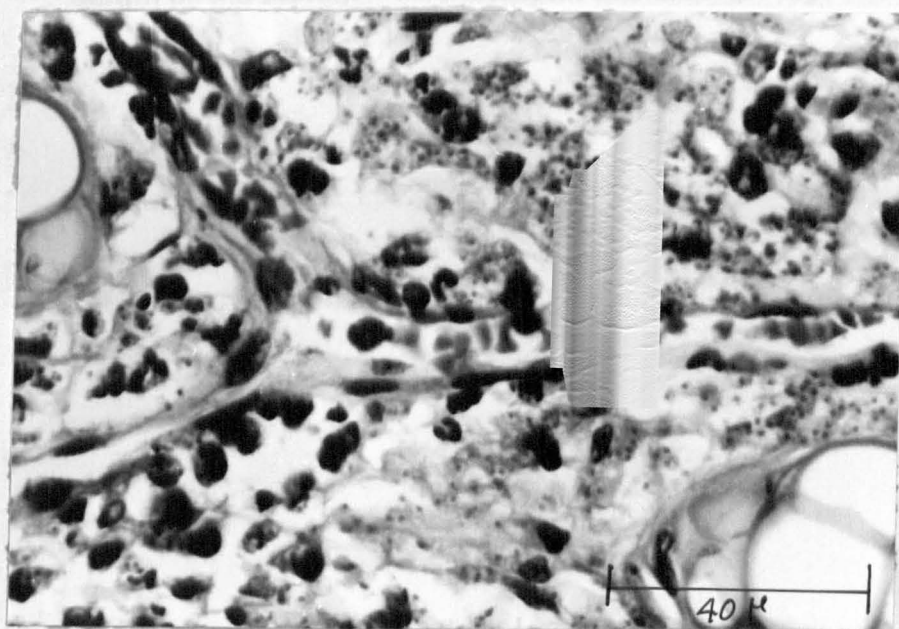


Fig.89

Higher magnification of the break in the cartilage seen in Fig.88 showing infected histiocytes in direct contact with the cartilage matrix; however, neither the cartilage cells nor the neighbouring blood vessel are invaded. Giemsa's stain (X 400).

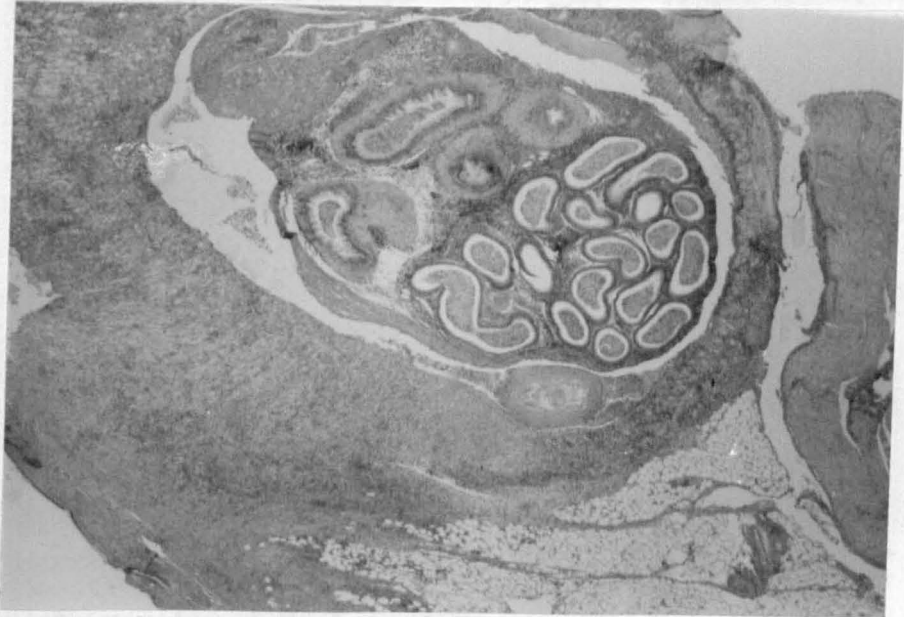


Fig.90

Section through the scrotum of an albino mouse showing cellular infiltration into the epididymis. Note the thickening of the scrotum and ulceration along the left margin of the section. Haematoxylin and eosin (X 12).

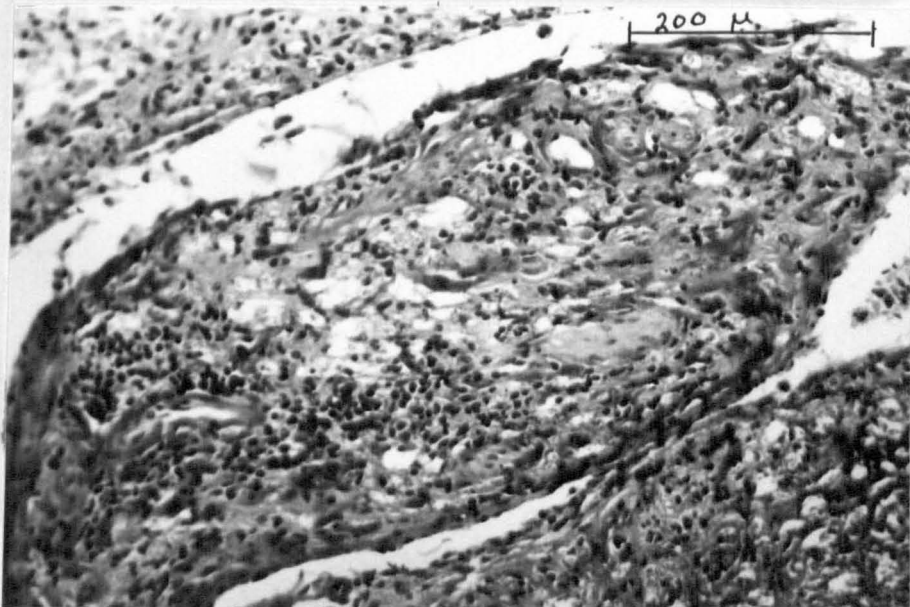


Fig.91

Section through the head of the epididymis in Fig.90 showing infiltration with lymphocytes, plasma cells and infected histiocytes. Haematoxylin and eosin (X 100).

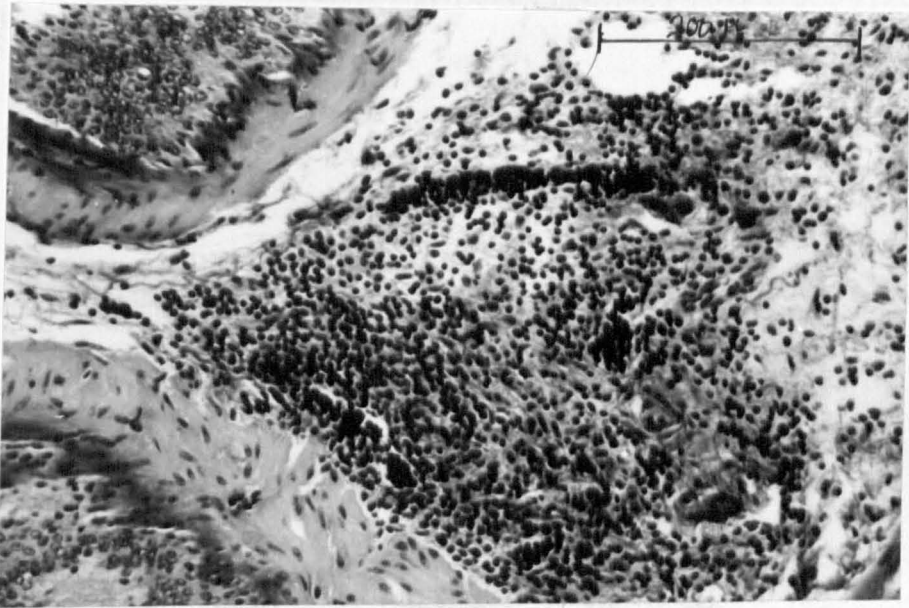


Fig.92

Section through the body of the epididymis in Fig.90 showing cellular infiltration into the interstitial spaces. Haematoxylin and eosin (X 100).

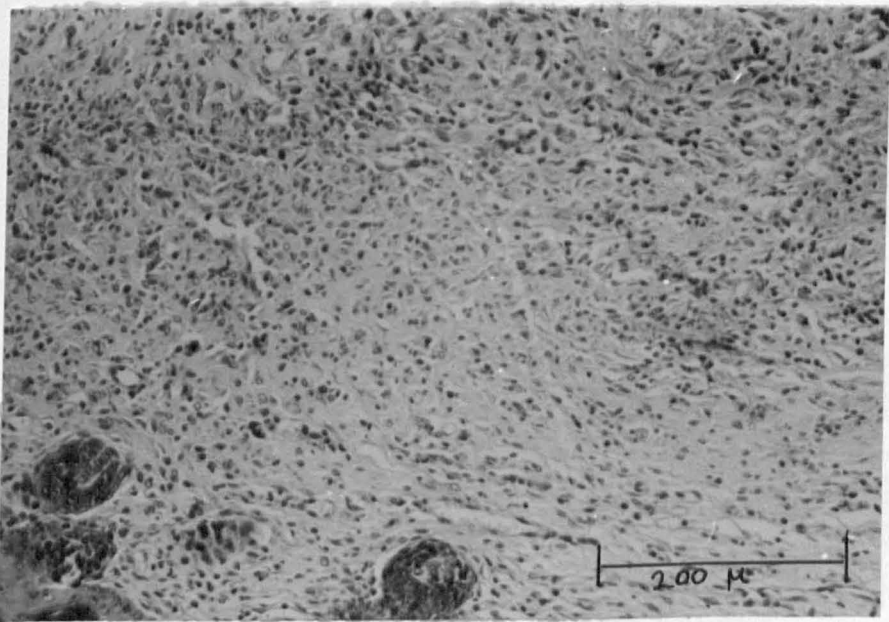


Fig.93

Section through the skin of the scrotum in Fig.90 showing massive histiocytic infiltration in the dermis. Haematoxylin and eosin (X 100).

The histology of lymph nodes of mice
The normal anatomy and histology of lymph nodes
The lymph nodes are the important structures of vertebrate located
in the course of lymph vessels, storing lymph fluid constantly. Nodes are
found in the respiratory tract, subcutaneously, between muscles and
near vessels in the body cavity. The nodes are also of the white matter

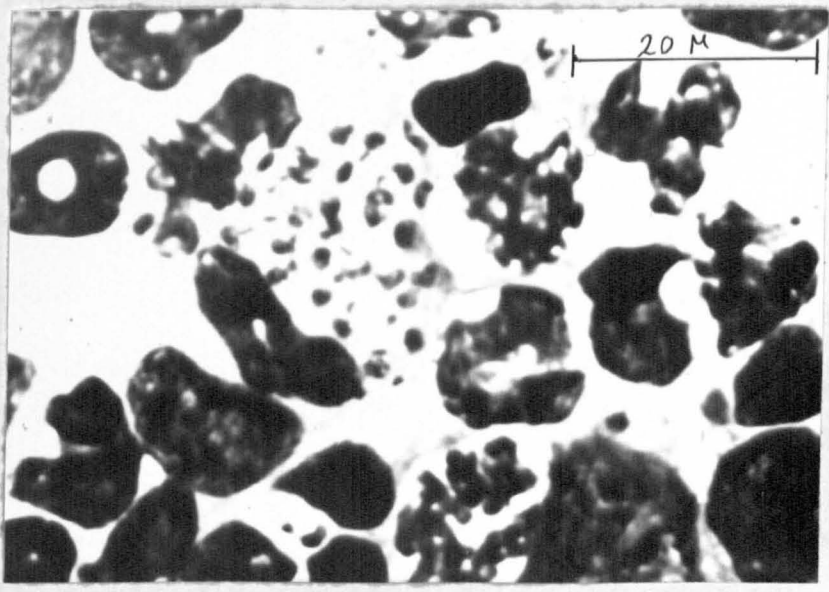


Fig.94 Smear of bone marrow of a mouse showing parasites within a histiocyte. Giemsa's stain (x1000)

4. The histopathology of lymph-nodes of mice

i) The normal anatomy and histology of lymph nodes:

The lymph nodes are bean-shaped structures of varied size located in the course of lymph vessels, interrupting their continuity. Nodes are found in the connective tissue, subcutaneously, between muscles and near viscera in the body cavity. The number and size of the visible nodes varies with the genus of the animal and the individuals of the same species.

Each lymph node consists of a connective tissue capsule which surrounds the entire node. Trabeculae extend from the capsule into the lymph node, forming part of the supporting structure of the node. At one point the surface of the lymph node is depressed and contains a hilus. Efferent lymphatic vessels leave and blood vessels enter and leave the lymph node at this point.

Under the fibrous capsule is a sinus, the cortical sinus. This is followed by a cortex of dense lymphatic tissue followed by a medulla of diffuse lymphatic tissue with large inter-communicating sinusoids, lined by reticular cells. Lymph nodules are recognizable within the body of the cortex. Each nodule has an inner germinal layer. At least three types of lymphocytes can be distinguished within the lymphatic nodule:

1. Closely packed small lymphocytes make up the outer part of the nodule, but may be present in other parts too. These cells have small nuclei which stain very deeply with haematoxylin.

2. Medium sized lymphocytes are the most common cell in the germinal centre of the nodule. These cells have larger, less deeply staining nuclei than the small lymphocytes, and often reveal clear nuclei.
3. Large lymphocytes (plasmablasts) are not as common as the intermediate lymphocytes and have nuclei which may be twice as large as those of the latter.

ii) Histopathology of the lymph node

During the present study amastigotes were found in the regional lymph nodes of both hamsters and mice. When the animals were inoculated at the base of the tail, the sciatic lymph nodes became involved. As the parasite spread to other parts of the skin following metastasis, it was recovered from the lymph nodes associated with each of the organs involved. Fig.95 is a schematic diagram of the location of the peripheral lymph nodes showing their relative position to the usual sites of inoculation of the parasite. Even when all the peripheral lymph nodes became involved, the visceral ones remained clear of parasites.

When the lymph nodes are first invaded, they become slightly enlarged, and the parasites were then located in the sinusoid spaces within histiocytes (Figs 96, 98). The lymph nodules increased in number and became more conspicuous. At this early stage the infected histiocytes

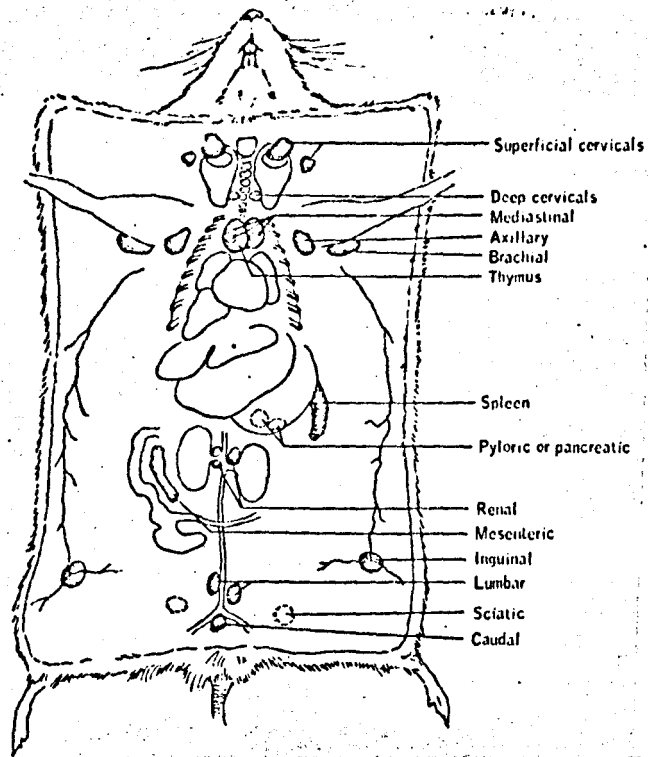


Fig.95 Schematic diagram of a dissected mouse showing the location of the lymph nodes. (After Dunn, 1954).

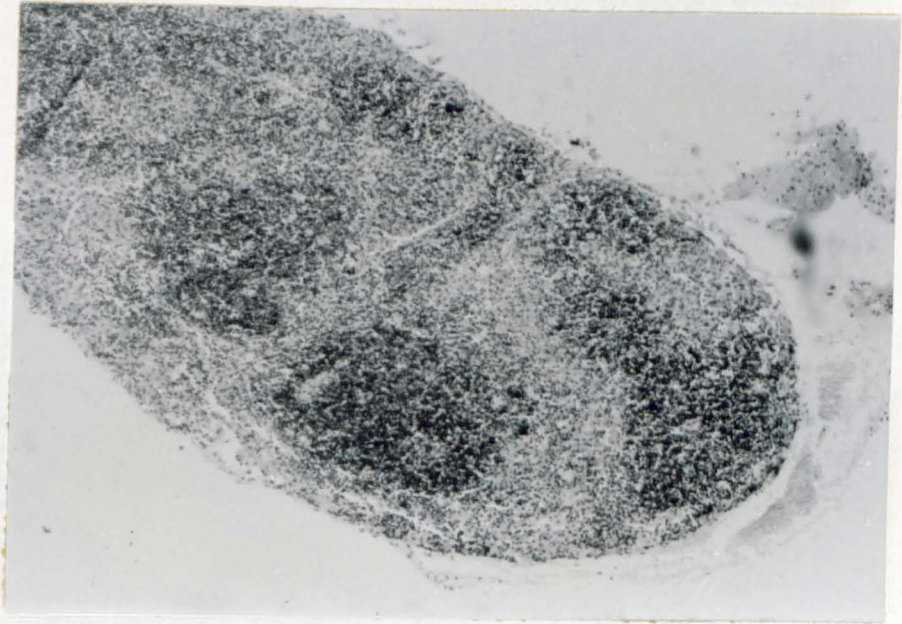

Fig.96

Section through the lymph node of an infected hybrid mouse showing a few intact germinal follicles and masses of histiocytes in the sinusoidal spaces. Haematoxylin and eosin (X 12).

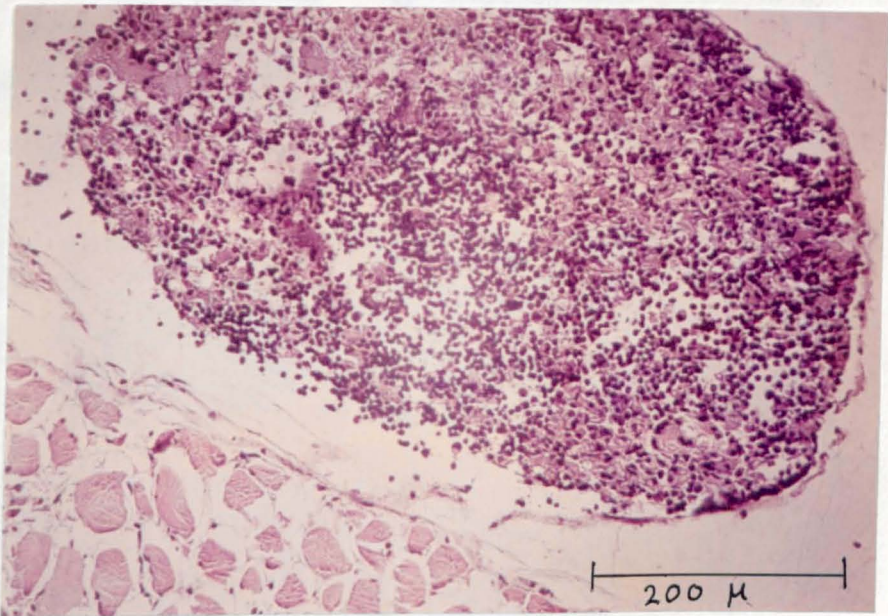


Fig.97

Section through the sciatic lymph node of a hairless mouse, inoculated with *L. b. pifanoi* at the base of the tail, showing massive destruction of the lymph follicles and their overlapping with cellular infiltration. Haematoxylin and eosin (X 100).

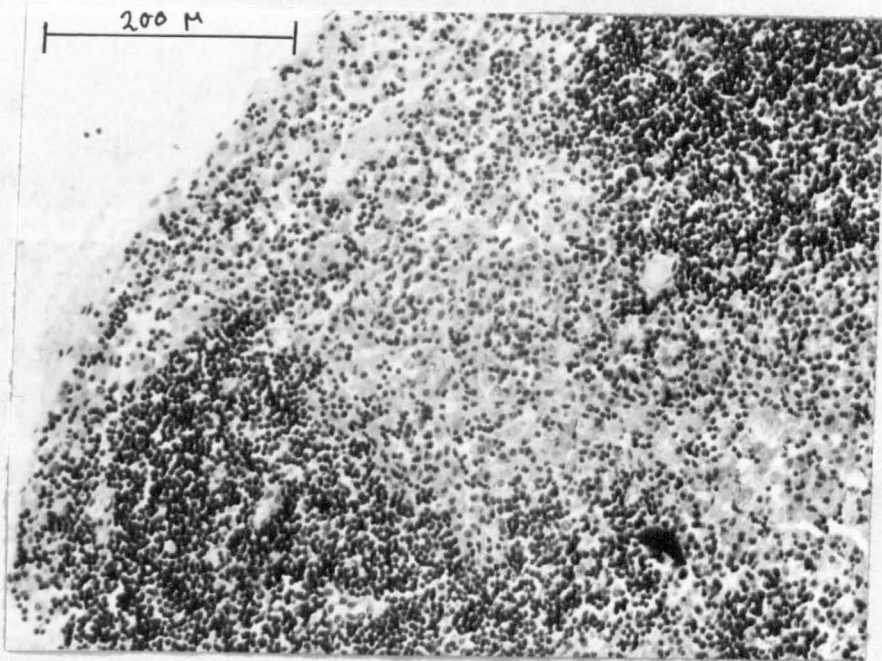


Fig.98

A section of a lymph node from an infected ("shaven" x albino) mouse showing the sinusoidal spaces packed with histiocytes and plasma cells. Haematoxylin and eosin (X 100).

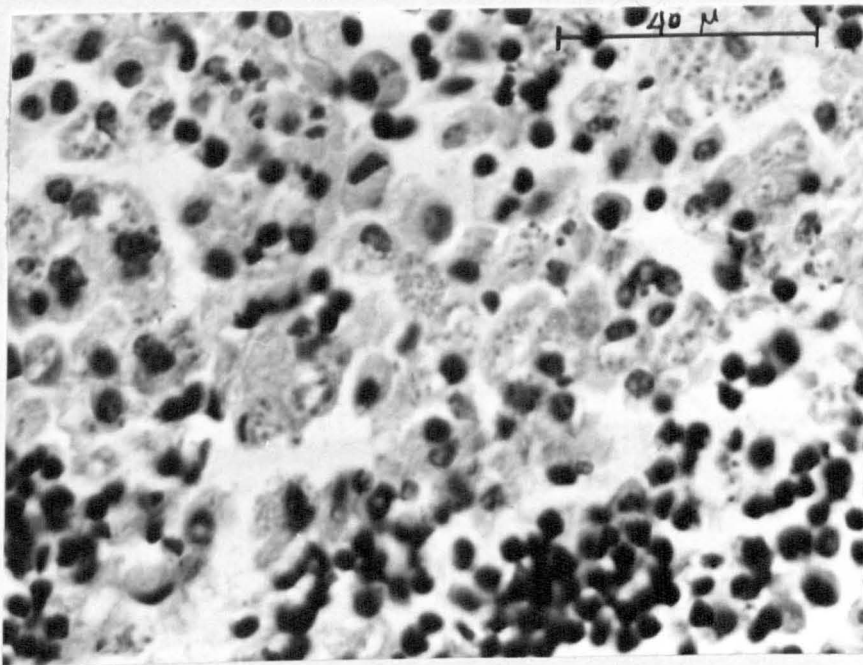


Fig.99

Section of lymph node at a late stage of infection showing parasitized histiocytes and plasma cells (X 400).

extend deeper into the cortex and the medulla. The parasites at this stage are numerous and readily detected (Figs.97, 99).

The general structure of the lymph gland is altered. The follicles disappear and the gland becomes one mass of lymphocytes and infected macrophages. A few plasma cells may be detected too.

The pathological picture is very similar in hamsters and mice.

Discussion

The study of the pathology of L. b. pifanoi in experimental animals revealed interesting information on the stages of development of the primary lesion, the pattern of metastasis and the types of secondary lesions formed as well as the reaction of the host to the infection. It is essential however when assessing the significance of these results regarding human infection to keep in mind the fact that the species and strains of Leishmania do not always behave in experimental animals in the same way as in human hosts. Thus L. tropica, which does not visceralize in human beings, invariably does so in hamsters. L. mexicana gives rise to a benign disease in humans but results in very severe incurable disease in mice and hamsters. Nevertheless, and as experimental infection of human beings with L. b. pifanoi, a mutilating parasite, is too dangerous to perform, animals remain an important tool in helping us to understand this parasite.

The pathology of American cutaneous leishmaniasis in experimental animals is very poorly documented in the literature. All the records refer to the lesions in these animals as 'similar' to those in human beings.

The present study was based on the examination of a large number of mice and hamsters over a period of three years. Hamsters were chosen as they are known to be susceptible to species of Leishmania in general. Mice have been used less often in such research but were found in the present

work to be highly susceptible to L.b. pifanoi. Hairless and "shaven" mice were included in these studies for two main reasons:

1. The hairless body surface was ideal for investigating a parasite which is known to favour hair-free parts of the body of its host. The absence of hair also made examination and sectioning of the lesion much easier.
 2. It is also believed that hairless mice are immunologically deficient animals, and therefore more susceptible to infections than albino mice.
- The present study showed that hairless and "shaven" mice were far more susceptible to the parasite than albino mice.

Gross Pathology:

Unlike the initial lesions in man, the primary lesion in experimental hamsters caused by L.b. pifanoi is not accompanied by satellite lesions; metastasis taking place directly to other hairless parts of the body. The distribution of the lesions and the extent of metastasis of the infection differs in man and experimental animals. The lesions in man may extend to cover all the body surface, while in hamsters and albino mice the lesions are limited to the ears, snout, feet, base of tail and external genitalia. This difference in distribution is obviously related to the presence or absence of hair, as in hairless mice the infection spreads all over the naked body.

The lesions formed by L.b. pifanoi in hamsters was similar to that

of L. mexicana described by Coelho and Coutinho-Abath in 1965.

The primary lesion formed by L. b. pifanoi is very hard to differentiate morphologically from that of L. b. brasiliensis or L. tropica.

The metastasis of the parasite is similar to that of L. b. brasiliensis and L. mexicana, except that L. b. pifanoi does not invade the viscera.

The gross pathology of the lesion in mice was very similar to that in hamsters, except that in addition to the nodular and ulcerating forms described in hamsters, mice showed a flat type of lesion characterized by being on the same level as the healthy skin. This flat form of lesion has not been described in other types of cutaneous leishmaniasis in experimental animals.

An interesting find was the 'warty' type of lesion in two of the hybrid mice. The lesions started as normal nodular lesions which were gradually transformed into the striking cauliflower-like warty appearance. These lesions were reminiscent of the human case of infection with L. tropica described by Balfour in Egypt in 1910. The wart-like lesions in mice were, however, limited to the primary lesion.

Metastasis in hairy mice was similar to hamsters, involving only hairless parts of the body. In the hairless and "shaven" mice lesions extended to parts of the naked skin besides the tail, snout, feet and ears.

Histopathology:

The histopathological picture of the primary lesion in mice and hamsters may be summarized as follows:

- a) An acute inflammatory reaction, with parasites taken by neutrophils and local histiocytes:

The initial inflammatory reaction is similar to other leishmanial or bacterial infection. Inflammatory cells, mainly neutrophils arrive to attack the foreign invading organisms. This acute inflammatory reaction lasts for a short time, after which the local histiocytes should take over the destruction and elimination of the foreign bodies. The amastigotes taken up by the histiocytes instead of being destroyed, survive and multiply. The vacuolated appearance of the engorged histiocytes is similar to that described in man by Convit, 1958; and Bryceson, 1969. These vacuoles do not stain with Sudan III, which shows that they are not lipid in nature.

- b) A histiocytic granuloma replaces the acute inflammatory reaction:

The pathological changes in the dermis and epidermis are partly due to pressure by the granulomata. The invasion by the epidermis has been seen in hamsters and mice and is interesting as it has not been previously observed in L.b. pifanoi in man or experimental animals. The finding of the parasite in the epidermis may be due to infected histiocytes migrating from the invaded papillary layer into the Malpighian layer.

The term "microabscess" was used to describe the invasion of the epidermis by groups of infected histiocytes which became isolated from the rest of the epidermis by a fibrous capsule. This histological picture is not that of a true abscess. The rupture of the thin epidermis by a microabscess may be one of the reasons for ulceration.

Lainson
The invasion of the epidermis has also been observed in human and rodent infections with L. mexicana (Lainson and Strangways-Dixon, 1963, 1964).

S
The acanthosis observed in mice infected with L. b. pifanoi in the present study was similar to that observed in human beings infected with L. mexicana and L. b. brasiliensis and L. tropica. Acanthosis has not been reported in humans infected with diffuse cutaneous leishmaniasis.

The histiocytic granuloma observed in the dermis of hamsters and mice infected with L. b. pifanoi is also seen in experimental infections with other species of Leishmania.

Loss of hair from areas adjacent to lesions on the bodies of hamsters and mice infected with L. b. pifanoi was probably due to the invasion of the hair follicles by the parasite and the pressure of the surrounding granuloma causing the atrophy of the follicle and sebaceous glands.

The invasion of the clear subpapillary zone by parasitized histiocytes, observed during the present study in mice, has been described previously in human cases of diffuse cutaneous leishmaniasis in Ethiopia (Bryceson, 1969). The invasion of the clear subpapillary zone was

i/ was noted mostly in primary lesions. In most secondary lesions this layer remained uninvolved or became involved only very late in the development of the disease. The author is of the opinion that the invasion of the clear zone depends on the layer of the skin in which the amastigotes are found. During experimental infection the parasite is usually injected into the dermal layer of the skin in the form of large numbers of amastigotes. The dose of the inoculum together with the injury to the skin resulting from the process of inoculation may help the parasite to escape into the epidermal layer where it may establish itself. The secondary lesion is usually initiated by a single or a few infected histiocytes invading the dermis. The time taken for the superficial layers of the dermis to become heavily parasitized and to pass the infection to the clear zone and the epidermis is probably much longer in the secondary lesion than the primary one.

The involvement of the sub-dermal muscular layer was similar to that described by Coutinho-Abath and Cohelo (1965) for L. mexicana in hamsters and mice. The atrophy of the muscles was probably caused by pressure of the granulomatous cells and not by direct invasion of the muscle fibres by the parasite.

In the latest stages of infection of the ear, the cartilage was occasionally slightly eroded and parasites were observed in the matrix of the tissue. This has not been observed in human cases of diffuse leishmaniasis but is similar to the invasion of the cartilage in human infection with L. mexicana.

c) The involvement of the local lymph glands:

Enlargement of the local lymph glands has been recorded in human cases of diffuse cutaneous leishmaniasis (Convit and Lapenta, 1948). The invasion of the lymph glands and the overlapping of the lymph follicles observed in the present study is similar to that seen in advanced stages of visceral leishmaniasis in human cases. The presence of parasites in the local lymph glands strongly suggests that the parasite is carried from the primary lesion to the nearby secondary sites in the lymph, although the lymph nodes are supposed to be small centres for the destruction of invading organisms.

The parasites are mainly found in the paracortex area of the lymph nodes, i.e. the infection is concentrated into the thymus dependant area of the gland. This probably explains the reason for the lack of immunological reaction at the site of infection.

d) Ulceration of the lesion:

l.c. The Ulceration of the lesion of L.b. pifanoi appears to be the result of the coalescence of foci of necrosis in the dermis and the sloughing of the epidermis due to this extended necrosis. Secondary bacterial invasion caused the formation of purulent discharge.

PART V - THE EFFECT OF IRRADIATION ON THE INFECTIVITY OF
L.B. PIFANOI AND THE POSSIBILITY OF USING SUCH
MATERIAL AS VACCINE

Review of Past Work

Deliberate immunizing procedures are in general less effective than infections as stimulators of acquired immunity. Not only is the resultant immunity in some cases less effective but in general it is less durable.

Immunization may be achieved by using several types of vaccines. These may be prepared from: (a) the soluble toxins of the causative organism; (b) the infectious agent killed by physical or chemical means; (c) substances produced by the infectious agent; (d) the living attenuated microbes, or (e) from a mild strain inoculated into concealed areas of skin.

Living vaccines are often found superior to dead ones. One of the methods for attenuating a living organism for use in vaccination is by exposure to sublethal doses of X-irradiation. This seems to interfere with the physiological functioning of the organism and frequently inhibits its normal rate of development and multiplication (Duxbury and Sadun, 1969; Giese, 1965).

There remain many diseases for which satisfactory vaccination is not

is not possible, although infection still bestows resistance. The concept of vaccination against parasites is a fairly new one and to date has not been sufficiently developed to make it practical on a large scale. It seems likely however that the strides which have been taken recently in the understanding of what constitutes an adequate vaccine and how it should be administered will result in the making of artificial prophylaxis against parasitic infection available, though not necessarily practical, in the near future.

Developing an effective method of immunization against leishmaniasis has long been an aim of workers in this field. Recovery from dermal leishmaniasis in human beings is known to give solid resistance against re-infection (Garnham and Humphrey, 1968; Adler, 1964; Stauber, 1963; Zuckerman, 1962).

For a very long time, parents in the Middle East deliberately immunized their children against disfiguring facial sores by infecting them on a hidden part of their bodies with Leishmania tropica taken from a sore.

Many workers have attempted vaccination using living parasites. The results show that the development of the lesion follows the same course as that of lesions resulting from the bites of sandflies. The incubation period varies between a few weeks (3 - 4) and many (10 - 12) months. The infection then declines and spontaneous cure results within 6 - 17 months (Zuckerman, 1962; Dostrovsky et al., 1953; Adler and Zuckerman, 1948; Berberian,

1944, 1937; Katzenellenbogen, 1944).

Stauber (1963) considered the vaccination with virulent parasites as infection in hidden parts of the body rather than vaccination.

Berberian (1944) reported unsatisfactory results from attempted vaccination with dead promastigotes of L. tropica. Pessoa (1941) succeeded in immunizing people against L. brasiliensis by vaccination with dead promastigotes after 3 inoculations in 3 - 4 weeks. Challenging them with virulent living promastigotes of the same strain did reveal the resistance of hosts against further infection.

Adler (1964) found that people with healed Leishmania tropica sores failed to develop infection when they were subsequently inoculated with L. mexicana.

Manson-Bahr (1961) used a strain of Leishmania, isolated from gerbils, as a vaccine against L. donovani in East Africa, as the two strains appeared to be identical when grown in cultures containing anti-L. donovani rabbit serum (Adler's test). However, the results of this experiment, conducted on a wide scale in the field, were unsatisfactory (Manson-Bahr, 1964).

Immunization with irradiated helminths larvae was developed against the cattle lung worm, Dictyocaulus viviparus, and induced active immunity (Jarrett et al., 1958, 1959, 1960). Other successful vaccinations with irradiated helminth parasites have been reported against Ancylostoma

caninum (Miller, 1965, 1968), Haemonchus contortus (Urquhart et al., 1964) and Trichostrongylus colubriformis (Mulligan et al., 1961). A marked degree of acquired immunity was induced also by the use of irradiated Trichinella spiralis larvae (Levin and Evans, 1942).

Immunization by inoculating irradiated parasitic protozoa has been attempted in experimental animals. Duxbury and Sadun (1969) found that mice inoculated with non-irradiated Trypanosoma rhodesiense developed progressive infections and died 3 - 5 days after inoculation, while all those inoculated with trypanosomes which had been irradiated with doses of more than 20,000 rads survived. Complete protection against a challenging infection was induced in mice given 2 or 3 immunizing inoculations. Martinez Silva et al. (1969) studied the effect of gamma radiation on growth and infectivity of Trypanosoma cruzi. They found that 6,250 rads reduced the infectivity by 90%; 12,500 reduced it by 99% and 50,000 rads by 99.99%.

Sanders and Wallace (1966) inoculated rats and mice with irradiated Trypanosoma lewisi and induced resistance to normal trypanosomes after 15 to 28 days of inoculation. Wellde and Sadun (1967) noticed that when rats and mice were inoculated with irradiated Plasmodium berghei they became resistant to infection with non-irradiated parasites. *They also found that mice immunized with irradiated P. berghei showed a significant increase in gamma globulins and that their sera contained protective antibodies.* *Vander berg et al. (1968) immunized mice with irradiated sporozoites of P. berghei.*

Warren and Garnham (1969) found that the exoerythrocytic schizonts developing in monkeys infected with irradiated sporozoites of P. cynomolgi were smaller ($\frac{1}{3}$ - $\frac{1}{4}$ the size) than normal schizonts and had much thickened limiting membranes. The schizonts were less dense and had a smaller number of nuclei than those developing from normal sporozoites.

Hein (in preparation), cited by Urquhart (1964), succeeded in immunizing chickens against Eimeria tenella. Urquhart (1964) reported attempts being made to produce a vaccine against East Coast fever, a common and usually fatal cattle disease caused by Theileria parva.

The efficiency of irradiation in treatment of oriental sore was investigated by Druckman and Dostrovsky (1936). They found that exposure of the lesion to 250 - 300 rads in advanced cases and 400 - 600 rads for early lesions gave satisfactory results. The same authors examined the effect of these doses of radiation on the parasites but found none. Ronconi (1934) has reported successful treatment of two cases of oriental sore with X-irradiation.

Chung (1936) studied the effect of irradiation with X-ray on the infectivity of Leishmania donovani amastigotes. He exposed suspensions of emulsified spleen and liver from infected hamsters to 50% S.E.D. (skin erythema dose), 100% S.E.D. and 200% S.E.D. respectively; all the material was subsequently infective to hamsters.

Adler (1940) transmitted visceral leishmaniasis to a man with carcinoma

of the stomach. He noticed no change in the course of infection as a result of irradiation, although the patient received consecutive doses of 5,050, 3,150, and 300 rads. This result might have been due to the large doses of parasites used, since the parasite may have been established in the bone marrow or lymph nodes far from the site of irradiation.

Skinner and Carson (1911), Reinhard (1918) and Rudisell (1945) found improvement in patients infected with malaria and showing splenomegaly when they were treated by roentgen irradiation.

The production of a strain of Leishmania of relatively low virulence by irradiation might help in immunization against virulent visceral or dermal types of leishmanial disease; consequently, a series of investigations was undertaken to study the effect of ionizing radiation on the infectivity of L.b. pifanoi and to determine the extent to which the resulting attenuated parasites might produce mild active lesions which could be used to produce a protective immunity in mice.

Present work

Amastigotes and promastigotes of L. b. pifanoi were exposed to different doses of gamma radiation and subsequently used in inoculating mice. The behaviour of the irradiated parasites in culture and the inoculated animals was studied.

Experiment I: Exposure of amastigotes of strain VI to gamma radiation and their subsequent intradermal inoculation into albino mice.

A suspension of amastigotes was prepared in Hanks's solution (see General Materials and Methods). 2 - 3 mls. of this suspension were transferred to plastic tubes (diameter 0.5 cm., length 10 cm.), sterilized in 70% ethanol, plugged with cotton wool and dried in an oven at 60°C. They were finally plugged with autoclaved rubber bungs. Plastic containers were used to reduce the absorption of ionized radiation (Giese, 1967).

The tubes containing the suspension were kept in an ice bath prior to irradiation, and following it until the material was used. They were exposed to a beam of Gamma rays from a Cobalt 60 source in a deep therapy unit. The plastic tubes were held closely together on a wooden rack to avoid significant variations in the dose of radiation received by each tube.

Samples of the suspension were exposed to 6500, 7500, 8500, 11500, 13500, 15500 rads.

The "shaven" mice, showing diffuse cutaneous lesions of L.b. pifanoi were also irradiated as an additional source of irradiated parasitic material. The mice were placed separately in small plastic containers and exposed to 10500 and 17500 rads. The first mouse was killed one hour after irradiation, the other one 24 hours later.

A suspension of amastigotes was prepared in the usual way from the skin lesions of these animals. Material was also collected from control mice not exposed to Gamma irradiation. All suspensions of the parasite were placed on ice for a few hours until they were used.

Smears prepared from these suspensions were dried in air, fixed in methanol and stained in Giemsa's stain. They showed 25 - 30 amastigotes per microscppic field under oil immersion.

Samples from each of the suspensions of amastigotes, exposed to 6500 7500, 8500, 11500, 13500 and 15500 respectively were inoculated intradermally into the snouts of 10 albino mice. 20 albino mice were inoculated with non irradiated material as control.

All animals were checked for the development of infection once a week. Smears were prepared and material from the site of inoculation was cultivated in 4N medium at regular intervals.

0.1 ml. of the irradiated suspension of amastigotes was put in 4N medium to check on the viability and behaviour in culture of the parasites after irradiation.

Results:

Morphological observations on the parasite:

The amastigotes were observed in smears prepared before and after irradiation and appeared unchanged in size, shape and staining.

Growth in culture:

Irradiated amastigotes were transformed into promastigotes in 4N culture media in the normal way (Fig.100). The motility and rate of reproduction of the promastigotes was similar to that of control cultures.

Subculturing the parasite for 3 - 7 generations did not reveal any morphological variations. The peak of growth was reached 8 to 10 days after subculturing as in controls (Fig.101).

Infectivity to mice:

The inoculation of mice with irradiated amastigotes revealed a percentage of infection almost equal to that using non irradiated material. The incubation period of the disease in mice inoculated with non irradiated material was shorter than in those injected with irradiated amastigotes. However, with the number of animals and the range of irradiation used in the present work there was no clear-cut correlation between the incubation period and the dose of irradiation to which the parasites were exposed.

Table 8 summarizes the results obtained in the experiment. The rate

of growth of the lesion resulting from the inoculation of irradiated material was slower than that of the normal lesions in control animals. The lesions reached a size of 0.7 - 1 cm. in diameter in 8 - 12 months, compared to 0.9 - 1.2 cm. in 6 - 8 months in the control.

Table 9 The effect of irradiation on the infectivity of *L.b. pifanoi*
Strain VI

No. of mice in each Group	Irradiation dose of inoculum	Number of mice becoming infected after:					Total of infected mice
		2 - 4 weeks	5 - 8 weeks	9 - 16 weeks	17 - 32 weeks	33 weeks & later	
10	6500 r	-	2	3	1	2	8
10	7500 r	-	3	3	1	-	7
10	8500 r	-	2	3	2	1	8
10	10500 r	-	4	3	-	1	8
10	11500 r	-	1	3	3	-	7
10	13500 r	-	1	4	3	-	8
10	15500 r	-	2	4	2	1	9
10	17500	-	-	3	3	-	6
10	Control	2	4	3	0	0	9

Most of the lesions produced by the inoculation with irradiated amastigotes had a flattened appearance and did not ulcerate.

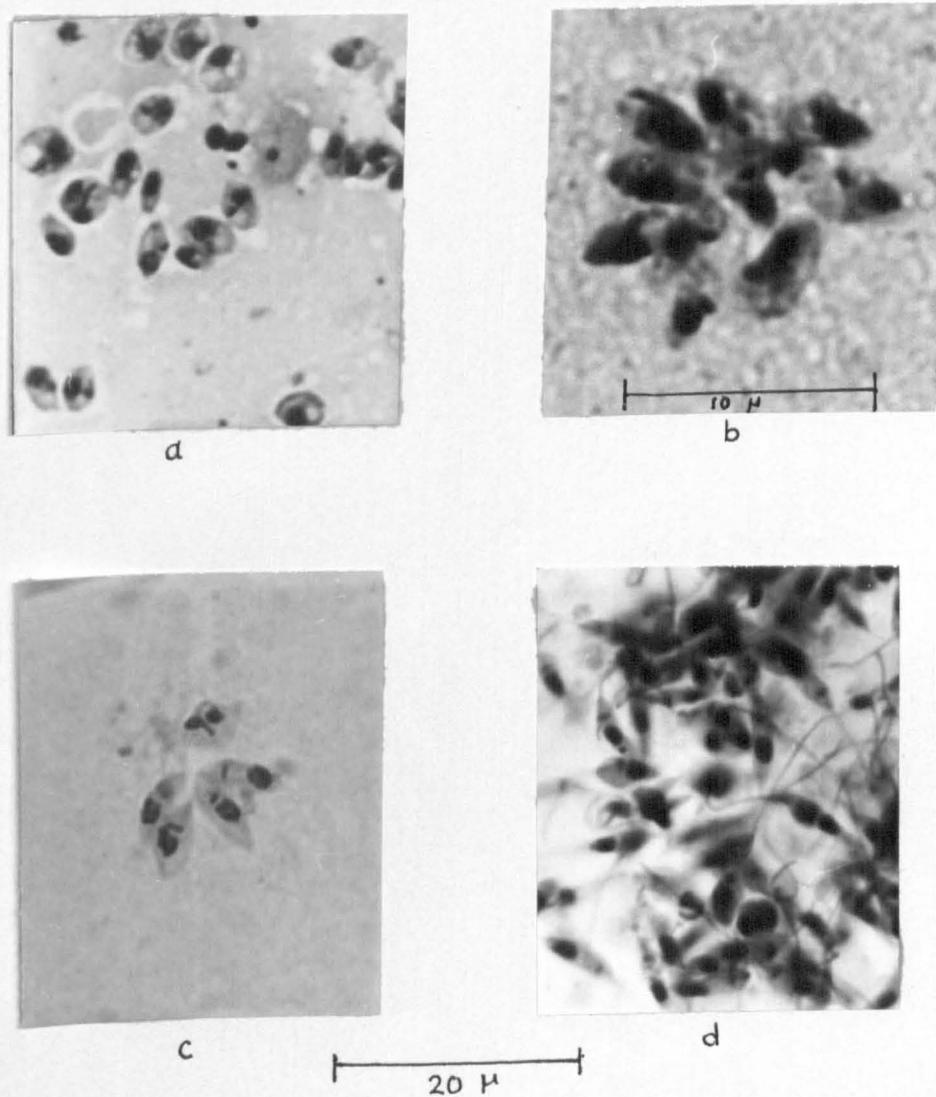


Fig. 100 Stages in the development of irradiated amastigotes in 4N media: a) after 4 hours, b) after 8 hours, c) after 24 hours, d) after 3 days (Giemsa's stain).

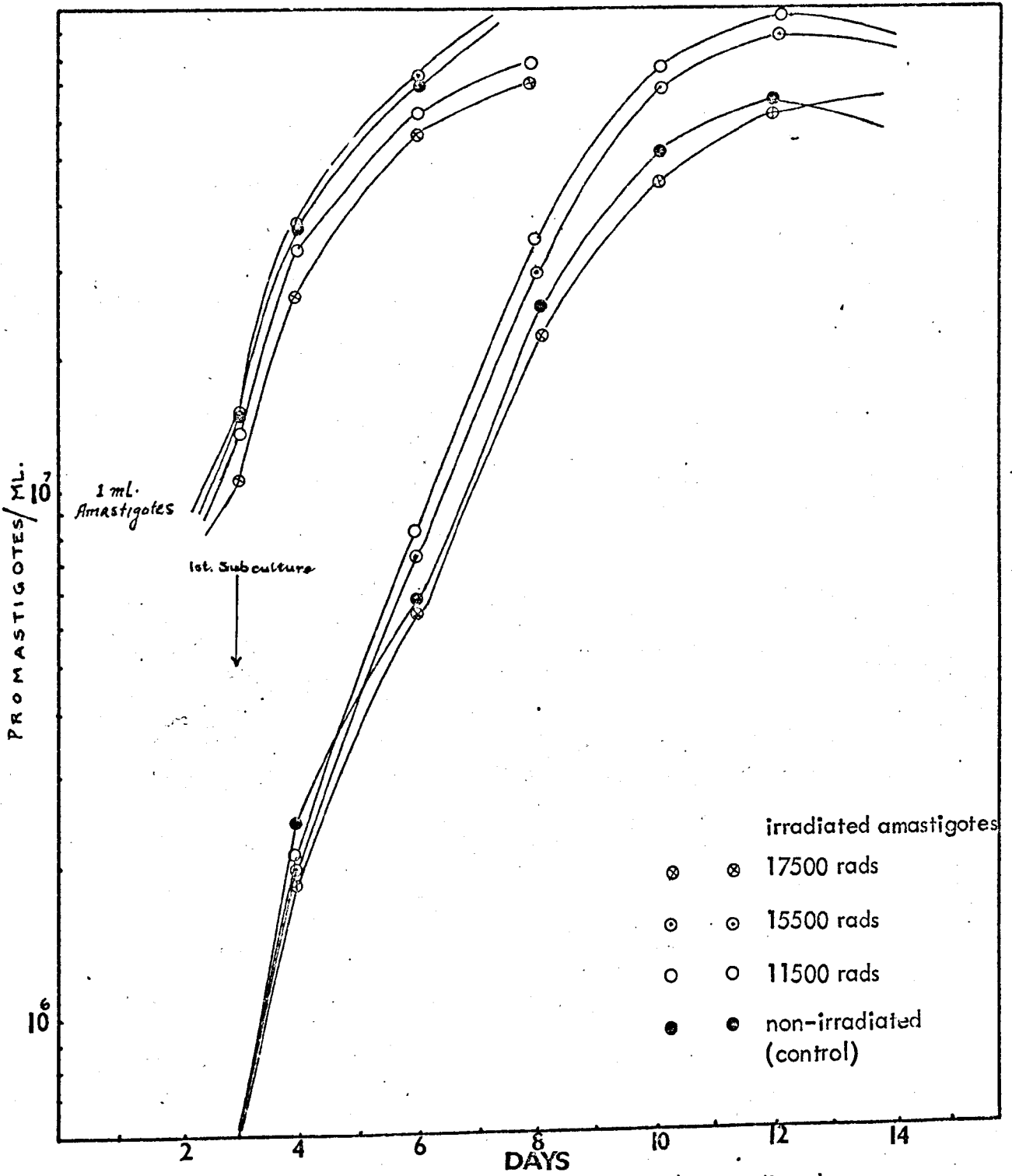


Fig.101 Comparison of the growth of irradiated and non-irradiated amastigotes of L.b. pifanoi in 4N medium.

Experiment 2: Exposure of promastigotes of strains V1 and V2 to Gamma radiation and their subsequent intradermal inoculation into albino mice.

Promastigotes were harvested from one week old cultures. The overlay fluid containing the parasites was transferred into small sterile plastic tubes. The number of promastigotes was counted in a haemocytometer.

Plastic tubes containing suspensions of promastigotes of strain V1 were exposed to 6500, 7500, 8500, 9500, 11500, 13500 and 15500 rads. Similarly, samples of promastigotes of strain V2 were exposed to 7500, 8500, and 9500 rads. They were kept on ice and sampled as in Experiment 1.

Six groups of 10 albino mice were inoculated with the irradiated promastigotes, strain V1, and 3 groups each of 20 albino mice were inoculated with irradiated promastigotes of strain V2.

The infectivity of the irradiated material was compared to non-irradiated controls as before. The rate of growth in culture of irradiated and non irradiated parasites and their morphology were compared as in previous experiments.

Parasites exposed to 9500, 13500 and 15500 rads were subcultured 10 times in 4N media.

Results:

Morphological observations:

No morphological variations in the parasite were observed in smears before and after irradiation. The fresh preparation examined by

phase contrast showed that the parasite was active. The movement of the flagellae was not affected by irradiation. Promastigotes took up the vital stain, Toulidine Blue, in the normal way. Giemsa stained - air-dried smears revealed the presence of volutin granules within the cytoplasm of the organism as in controls. These granules disappeared after hydrolysis of the methanol fixed smears in 1N HCl for three to five minutes at 60°C. Staining with Giemsa's stain or Fucigen following hydrolysis showed stages in binary division taking place in the irradiated parasites. A few promastigotes had abnormal shapes (Fig.102), some being rounded with short flagellae and others slender with long flagellae. These abnormal forms are common in old cultures of un-irradiated material.

Growth in culture:

When samples from irradiated material were put in 4N medium, the promastigotes showed a retarded rate of growth and division, during the first 24 hours, as compared with the control. However, when subcultured these irradiated promastigotes attained the same rate of growth as the control. The rate of growth of the irradiated material, & the control in the ... cultures is shown in Fig.103.

Infectivity to mice:

The inoculation of mice with irradiated promastigotes resulted in a high percentage of infection. As in the irradiated amastigotes, the main

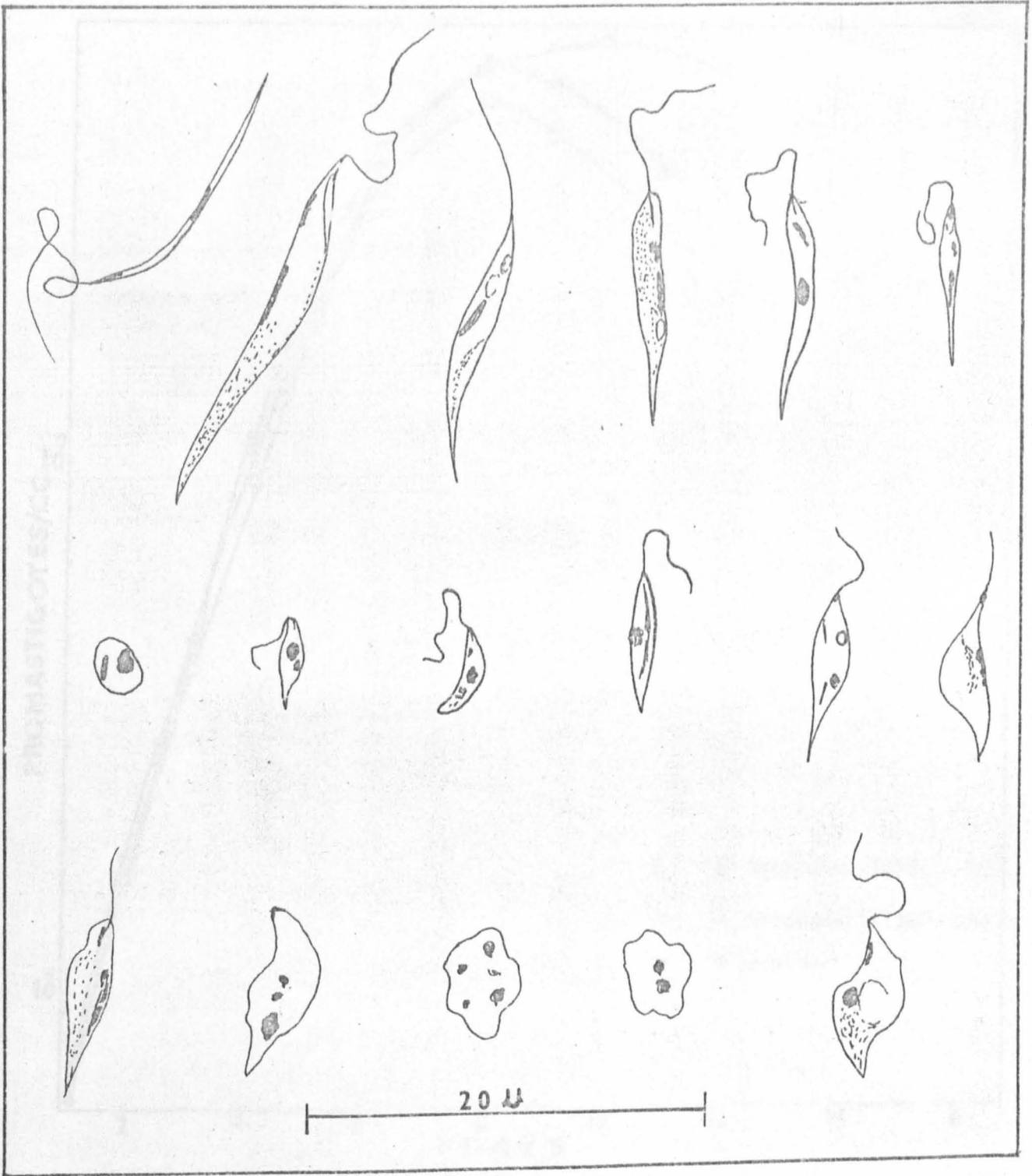


Fig. 102 Different forms of promastigotes of irradiated culture of *L. b. pifanoi* strain VI (Exposed to 13500 rads).

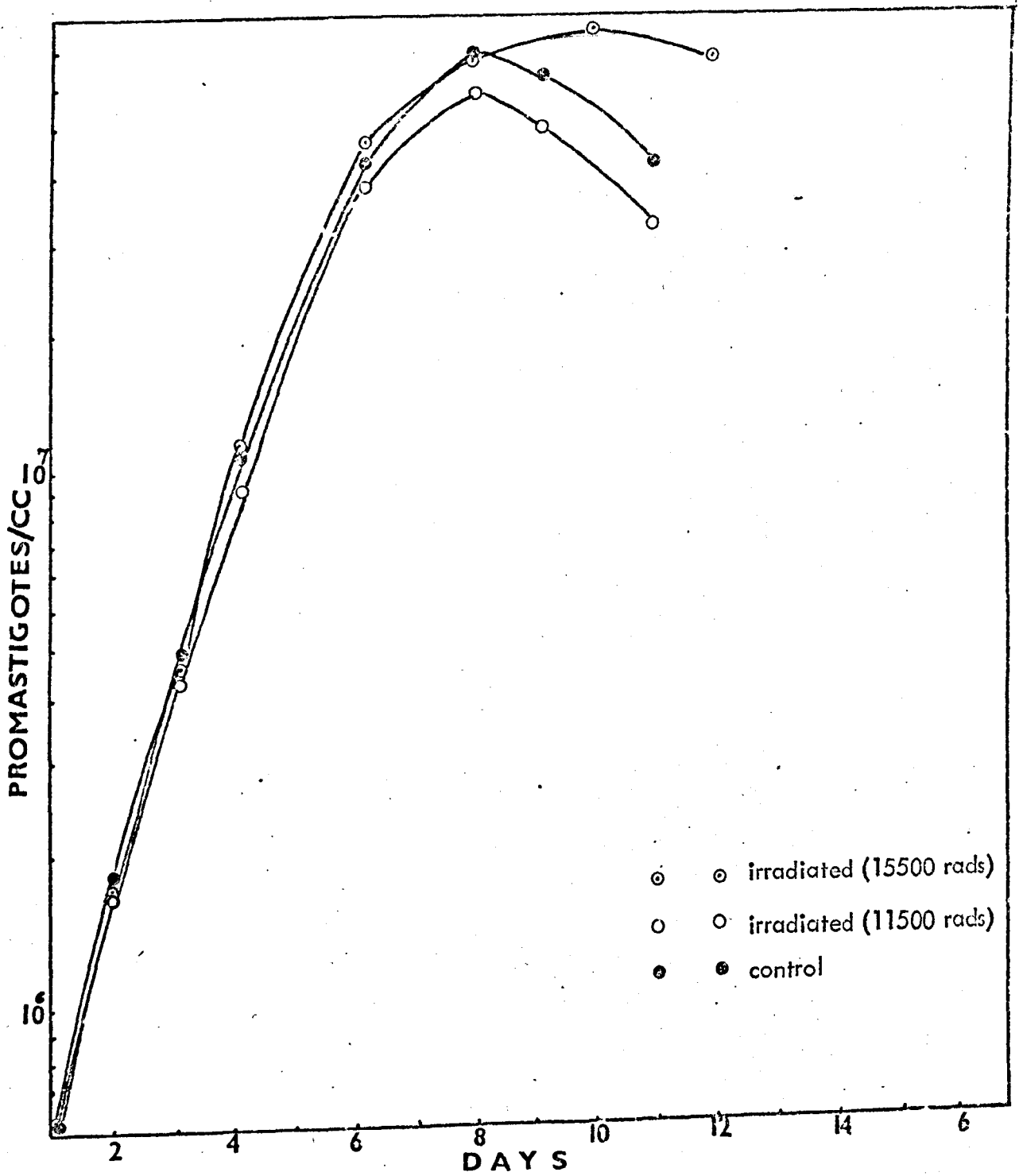


Fig. 103

Comparison of the growth of irradiated and non-irradiated promastigotes of L.b. pifanoi in 4N medium.

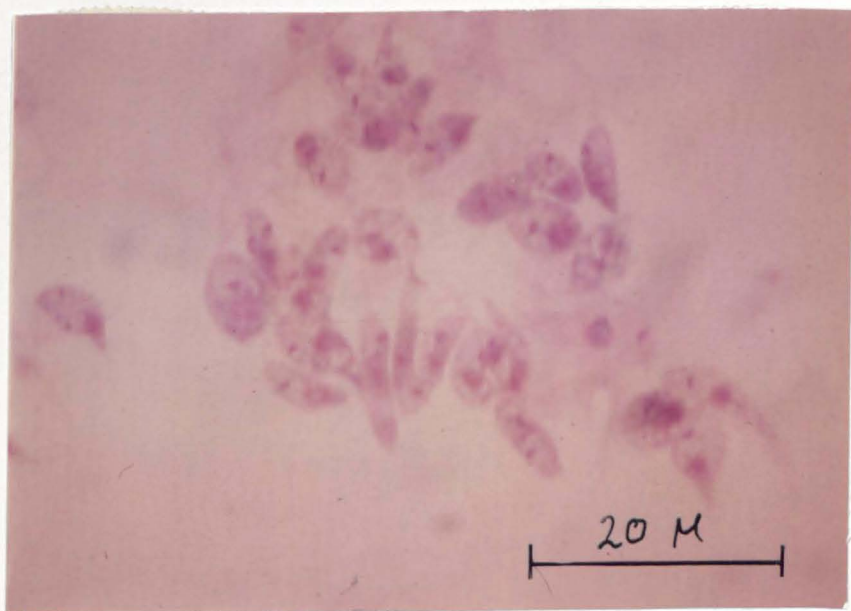
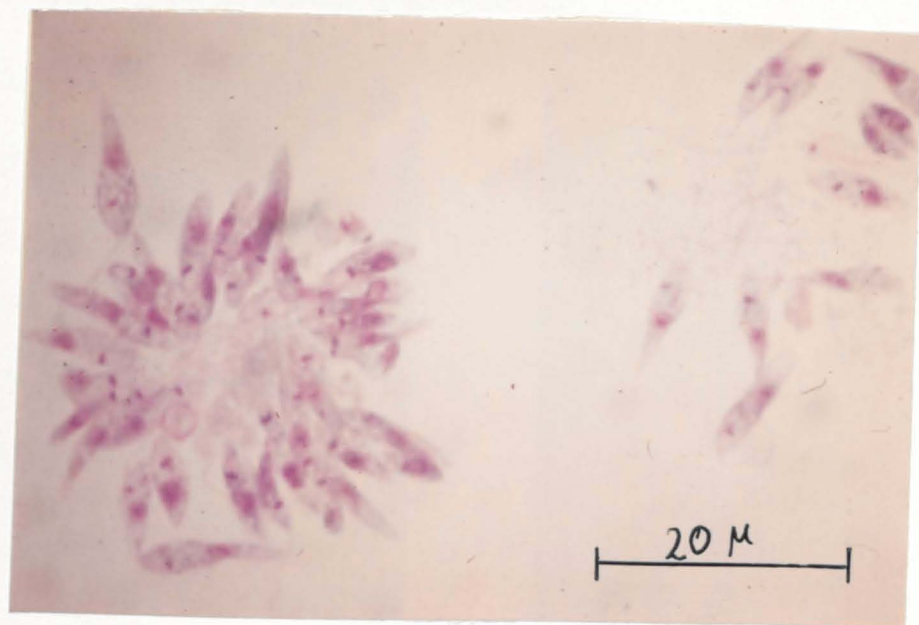


Fig.104 Smears of promastigotes prepared a) before and b) after irradiation (Giemsa's stain).

result of irradiation was a prolongation of the incubation period. A large number of the mice inoculated with irradiated promastigotes showed the infection 9 to 16 weeks after inoculation, compared with 2 - 8 weeks in the control mice inoculated with non irradiated material (Table 10).

The lesions were usually of the flat type. None of the mice showed metastasis during 12 - 18 months of observation. In mice inoculated with irradiated promastigotes strain V2, the infection was mild. Most of the infected animals showed the first sign of infection 9 - 32 weeks after inoculation. The lesions were mainly of the flat type. No hair loss was noted and metastasis was not observed in any of the infected animals.

Experiment 3: Subinoculation of irradiated amastigotes, strain V1, in mice.

One of the albino mice previously infected with the irradiated material (9,500 rads), and showing a nodular lesion on the snout, was sacrificed 10 months after infection. A suspension of amastigotes was prepared from the lesion in Hanks's solution. 8 mice strain C57 were inoculated with the suspension, each mouse receiving .05 mls. intradermally in the snout. The animals were put under observation for one year.

Table 10 The effect of irradiation on the infectivity of *L.b. pifanoi*
Strains V1 and V2

No. of mice in each group	Irradiation dose of inocula	Strain and dose of inocula	No. of mice becoming infected after:					Total of infected animals
			2-4 wks.	5-8 wks.	9-16 wks.	17-32 wks.	33-40 wks.	
10	6500 r	V1 4×10^6 promastigotes	2	1	4	1	0	8
10	7500 r	- " -	0	2	5	2	0	9
10	8500 r	- " -	1	2	6	1	0	10
10	11500 r	- " -	1	1	6	0	0	8
10	13500 r	- " -	0	2	4	3	0	9
10	15500 r	- " -	0	2	5	1	0	8
10	-	- " -	1	4	3	1	0	9
20	7500 r	V2 4×10^6 promastigotes	0	1	5	9	1	17
20	8500 r	- " -	0	2	6	5	4	17
20	9500 r	- " -	0	4	9	3	0	16
10	-	- " -	2	5	2	0	0	9

Results:

All the mice became infected. The incubation period, and the course of development of the lesions was typical of that of non irradiated material. In two of the mice visceralization of the parasite was observed as scanty amastigotes were found within macrophages or scattered extra-cellularly in Giemsa-stained smears of the liver and spleen, although they could not be found in histological sections of either organ.

Experiment 4: Challenging mice by intradermal reinoculation with amastigotes of strain V1.

Ten albino mice which had previously been inoculated with irradiated leishmaniae strains V1 and V2 and which had failed to develop infection, were selected at random for reinoculation with non irradiated amastigotes. Each mouse was intradermally infected with 0.05 ml. of the suspension.

Six clean, stock albino mice were also inoculated with the same dose of parasites as control. All animals were checked weekly for signs of infection.

Results:

Six of the experimental mice became infected and showed small lesions 6 - 15 weeks after inoculation. Three weeks later another mouse developed a lesion. The other 3 mice failed to become infected.

Four out of the 6 control mice showed signs of infection 6 - 10 weeks after inoculation. The other 2 developed lesions 4 weeks later.

The lesions were similar in both groups of mice.

Discussion

The effect of ionizing radiation on protozoa is not fully understood. More work has been done on the effect on free ciliates than on parasitic protozoa. When ciliates are exposed to continuous ionizing radiation changes are observed in the beating rate of their cilia, in the movement of the contractile vacuole and consequently on the rate of osmosis and the shape of the cell. The cytoplasm becomes vacuolated. The permeability of the cell membranes is changed. Finally the cell disintegrates.

Gamma radiations produce ionization in the media that they traverse. Radiation is absorbed in proportion to the density of the medium, the chemical composition of which is of secondary importance. Ionization produces free radicals inside the cells as well as in the fluid medium surrounding them. These free radicals, e.g. the hydroxyl radical, are highly reactive and form peroxides, which in the presence of oxygen form the highly oxidizing radical HO_2 perhydroxyl. These oxidizing radicals oxidize cell constituents.

Another effect of ionizing radiation on the cell is the direct bombardment of macromolecules of the cell. The death of an organism due to X-irradiation is probably due to the destruction of some of these molecules which are essential for cell replication. This lethal effect may be direct or may express itself over the following generations by a gradual decrease in the rate of reproduction and death.

Sublethal doses of X-irradiation may stop or retard the rate of cellular division. Invisible effects on the rate of respiration and heat sensitivity also occur.

Mutations are not uncommon in the progeny.

The temperature following irradiation at which the organism is kept is important in determining the rate at which death is delayed. Survival increases as the temperature decreases to an optimum low temperature. The environmental temperature does not, however, effect the genetically controlled mechanisms of the cell.

Micro-organisms are generally more resistant to ionizing irradiation than cells of higher animals. It has been suggested (Giese, 1967) that a higher content of catalase which removes peroxides may account for this radiation resistance of protozoa.

Different stages in the life cycle of protozoan parasites have different sensitivity to X-irradiation, thus the sporozoites of P. gallinacium are more sensitive to X-irradiation than the trophozoites (Bennison and Coatrey, 1945), but it is generally accepted that protozoan organisms are more susceptible to the effects of ionizing radiation when they are in the dividing stage (Giese, 1967).

Although experiments using ionizing radiation have been done with several parasitic protozoa, e.g. Plasmodium and Trypanosoma spp., the

results have not been conclusive. To date, there is insufficient knowledge of all aspects of this technique to make vaccination against protozoan diseases, with irradiated material, of practical use. Nonetheless, this technique has a promising future.

There is very little information regarding the effect of radiation on Leishmania in the literature. Although a number of the successful experimental immunizations of animals with irradiated parasites were performed using Trypanosoma spp., a flagellate closely related to Leishmania, there are too many differences in the life-cycles, the tissue specificity and the pathogenicity of the two parasites for these results obtained on trypanosomes to be applied theoretically to Leishmania; and unlike the trypanosomes, L. b. pifanoi is a dermatropic intracellular parasite of the histiocytes.

There is, however, some indirect evidence that Leishmania parasites are susceptible to the effects of irradiation. Macleod (1933); Ronconi (1934); Druckman and Dostrovsky (1936) were successful in treating cases of oriental sore by exposing the infected part of the patient to 400 - 600 rads of X-irradiation. Curiously, the exposure of a suspension of L. tropica (Druckman and Dostrovsky, 1936) to the same dose of irradiation did not result in the death of the parasite. nor did it interfere with its infectivity. The authors suggested that the irradiation may have affected the host cells, and increased their ability to overcome the infection. It is not clear how this effect on the host

cells can be explained. It is possible that exposure to very low doses of irradiation may activate the cellular infiltration to the site of the lesion. Lymphocytes and other monocytes may then help in destroying the parasites.

In the present work, and in the absence of indications of the lethal dose of irradiation on L. b. pifanoi in the literature, it was decided to expose this parasite to a low dose of irradiation, gradually increasing it to find the sub-lethal dose which attenuates the parasite sufficiently to be used for immunization.

The highest dose used during the present work (17500 rads) was not, however, lethal to the parasites. Irradiated organisms survived and continued to multiply at the normal rate, although some abnormal forms appeared in culture. These abnormal forms appeared to have vacuolated cytoplasm and had atypical shapes similar to those seen in old, dying cultures.

The main effect of irradiation on the parasites was in prolonging the incubation period of the disease on inoculation into animals. This may have two possible explanations: the rays may have killed a certain percentage of the parasites leaving behind a smaller number, which delayed the prepatent period, i.e. it took longer to give rise to a visible lesion; the other possibility is that the low dose of irradiation may have retarded the rate of growth and division of the surviving parasites. The two factors probably interact.

It was noted that the total percentage of animals which became infected following inoculation with irradiated parasites was approximately the same as in the control. This indicates that the infectivity of the parasites was not affected by irradiation; neither was the pattern of metastasis in the animals inoculated with the irradiated parasites affected.

The parasites from the lesions resulting from the inoculation of animals with irradiated material retained their infectivity. This was shown by the successful infection of other mice by subinoculation.

The visceralization of the disease in two mice strain C 57 was very curious. L.b. pifanoi is not known to visceralize. Examination of the viscera of the numerous experimentally infected animals during the present investigation never revealed parasites. The interesting observation of visceral infection was made on a strain of mice not used in previous experiments. It is therefore difficult to decide whether this abnormal invasion of the viscera by the parasite was the result of the Gamma-irradiation or a peculiar behaviour of the parasite in this particular strain of mice. Unfortunately, this discovery was made too late in the course of the present work to allow the repetition of this experiment.

The failure of the parasite, derived from the viscera of these two mice, to visceralize when subinoculated intradermally and intraheptically into albino mice indicates that irradiation did not alter the basic genetically

controlled physiological characteristics of the parasite.

Challenging mice which had been inoculated with irradiated material and which had failed to become infected with un-irradiated amastigotes resulted in development of normal lesions. This showed that the animals had not become immune.

DISCUSSION ON THE IDENTITY OF THE CAUSATIVE ORGANISM
OF AMERICAN DIFFUSE CUTANEOUS LEISHMANIASIS

Diffuse American cutaneous leishmaniasis has been described under several different names by different authors. These names include: "leishmaniasis tegumentaria diffusa" (Convit, 1958; Portugal and Marques, 1960); "leishmaniasis cutis diffusa" (Convit and Kerdel Vegas, 1960); "dissiminated cutaneous leishmaniasis" (Convit et al., 1962); "dissiminated anergic cutaneous leishmaniasis" (Convit et al., 1962), "dissiminated anergic American cutaneous leishmaniasis" (Convit et al., 1957); "leishmaniasis tegumentaria multiple" (Ortiz and Pardo, 1949); "leishmaniasis cutanée nodulaire dissiminée" (Destombes et al., 1965); "leishmaniasis cutanée pseudolepromateuse" (Balzer et al., 1959); and "lepromatoid leishmaniasis" (Price and Fitzherbert, 1965).

There is considerable controversy regarding the identity of the causative agent of diffuse cutaneous leishmaniasis. All confirmed cases to date have been described from Central and South America and Ethiopia.

When discussing the identity of the causative organism it is important to bear in mind the prevalent species of Leishmania in the regions from which these cases of diffuse leishmaniasis have been reported. Thus, in Central and South America, L. mexicana causes chicleros ulcer, L.b. brasiliensis causes espundia, L.b. guyanensis causes pian boils, L.b. peruana causes uta. In

Ethiopia L. tropica is the prevalent causative agent of leishmaniasis in the high altitude areas from which diffuse cutaneous leishmaniasis has been reported.

Clinically diffuse cutaneous leishmaniasis has several peculiarities, namely abundance of the parasites, histological characteristics, negative leishmanin test, progression of disease and difficulty of treatment, which distinguish the disease from the classical dermal, muco-cutaneous as well as visceral leishmaniasis.

These differences in the clinical picture of diffuse cutaneous leishmaniasis from all other known forms of leishmaniasis has led workers in the field to speculate widely on the identity of the causative organism. There are conflicting opinions regarding the taxonomic position of the parasite responsible for this bizarre disease.

In 1959, Medina and Romero distinguished diffuse cutaneous leishmaniasis from other forms of American leishmaniasis on the basis of the clinical immunological, histopathological and morphological basis and recognized the causative organism as a distinct sub-species of L. brasiliensis, naming it L.b. pifanoi.

In 1962 the same authors on the basis of further investigation on human and experimental infections raised the sub species to the status of a species of L. pifanoi (Medina and Romero, 1962).

Convit and Kerdel-Vegas (1965) considered diffuse cutaneous leishmaniasis as a form of American cutaneous leishmaniasis, suggesting that the parasite may be an unknown genetic variant of L. americana, possibly with enzymetic capacity to destroy the host defensive mechanism. Convit suggested that this variant must be very stable as its characteristics are retained in human and animal hosts.

Alternatively, it has been suggested that diffuse cutaneous leishmaniasis is a rare condition restricted to a few individuals incapable of producing the necessary specific antibodies. Convit used the term "anergy" meaning a paralysis of the host immune response to describe this condition.

A third hypothesis put forward by Galliard (1962) suggested that diffuse cutaneous leishmaniasis may be a complication of abortive kala-azar which remains restricted to the skin.

In spite of these several attractive hypotheses put forward to account for the identity of the causative agent of diffuse cutaneous leishmaniasis, the taxonomic position of this parasite is far from being settled. The problem is complicated by the complexity of the interrelationship of the species and subspecies of Leishmania in America and the absence of a more reliable means of differentiating these species than the variable clinical manifestation.

There seems to be some evidence in support of Convit's theory of specific anergy:

**PAGE
MISSING
IN
ORIGINAL**

of parasites in the lesions, the histological picture, negative leishmanin test, metastasis of the disease to parts of the body and difficulty of treatment. These clinical peculiarities cannot be accepted as conclusive evidence of specific distinction, as they reflect the host response as well as the characteristics of the parasites. In addition, it is distinguished from kala-azar by the absence of visceralization. At present the clinical picture is the most important criterion in the classification of the South American leishmaniae. Diffuse cutaneous leishmaniasis is so strikingly different from other forms of leishmaniasis on that continent, that it seems justifiable to give it a distinctive taxonomic designation. As the speciation of American leishmaniae is still subject to much discussion and argument it seems best at present to give the causative agent of the disease the status of a subspecies of L. brasiliensis as Medina and Romero had suggested in 1959.

Experimental transmission:

L. brasiliensis, when inoculated into hamsters invades the viscera. This is not the case with L.b. pifanoi which remains restricted to the skin. Visceralization of the parasite is not, however, a reliable criterion for the differentiation of the different species, as different strains of the same species of Leishmania may not behave in the same way. Thus some strains of L.b. brasiliensis do not visceralize in experimental animals. In my opinion the inoculation of animals in the absence of any standardized dose, calculated

with a view to the size and life span of the experimental animals, is not a reliable criterion for classification of leishmanial parasites. L.b. brasiliensis, L. mexicana, L. tropica, L. donovani, as well as L.b. pifanoi run a very similar course in experimental animals which makes the differentiation of those parasites, on the basis of results of animal inoculation, of doubtful value.

Medina and Romera (1962) claimed that L.b. pifanoi was larger than L.b. brasiliensis and that L.b. pifanoi was more difficult to cultivate in vitro than L.b. brasiliensis, and that it retains its infectivity longer in culture. However, the evidence is not convincing as the ranges of size of the two parasites overlap. Further, the readiness with which the parasite may be cultivated in culture depends to some extent on the strain and the composition of the culture media. Thus, Lainson and Shaw (1969) found considerable difficulty in growing a strain of Leishmania isolated from South American rodents in culture. Bray and Manford (1967) pointed out that the rate of growth of Leishmania parasites in culture is largely influenced by the physical and chemical nature of the media.

Immunology :

The immunological evidence is rather contradictory and to date not conclusive. There is clear-cut evidence of the immunological deficiency of patients suffering from diffuse cutaneous leishmaniasis. This is shown by

the negative Montenegro reaction shown by these patients (Convit and Kerdel-Vegas, 1965; Bryceson, 1969); the failure of the secondary lesions to ulcerate and heal; the absence of lymphocytes from the dermal infection. Bryceson (1969), however, has shown that the serum globulin of Ethiopian patients is normal, and that immunity may be built up by treatment or immune conversion although relapses are not uncommon. Bryceson (1970b) reports that this immunological deficiency is specific to Leishmania, the patients forming antibodies normally against viruses, bacterial, protozoa etc. The titres obtained in the agglutination reaction to L. tropica were low. In artificial sensitization against artificial chemicals only 6/8 of the patients reacted.

Pifano and Scorza (1960) claimed that they could distinguish L. b. pifanoi from L. b. brasiliensis by the agglutination tests on sera raised in immunized rabbits. These results are not conclusive because the control test on L. b. brasiliensis antiserum was not performed. In ¹⁹⁶⁶1967 Bray and Lainson were unable to distinguish by serological means between L. b. brasiliensis and L. b. pifanoi.

It must be concluded that taxonomic status of the causative organisms of diffuse cutaneous leishmaniasis cannot be determined with certainty at present. There is considerable evidence that the disease is the result of a deficiency in the immune response of the host. This deficiency may be

genetically controlled or acquired by immunological tolerance resulting from previous exposure to Leishmania infection or by some event in the case history of the patient.

On the other hand, it is possible that variants of L. b. brasiliensis and L. tropica are more liable to give rise to diffuse cutaneous infection. At present it seems advisable to regard the causative agents of diffuse cutaneous leishmaniasis in America and Ethiopia as subspecies of L. b. brasiliensis and L. tropica.

There is obviously a need for a great deal of research work to elucidate the identity of the parasite. L. b. pifanoi must be compared to L. b. brasiliensis and L. tropica from the epidemiological, serological and pathological aspects, taking into consideration the need for standardizing the dose of inocula, searching for better experimental animal hosts.

In the light of Bryceson's and co-workers' observations (1970) on the metastasis of L. enriettii in guinea pigs suffering from induced immunological paralysis, it would be of interest to study the effect of immunosuppressive procedures, e.g. high doses of X-irradiation, thymectomy, lymphocytic antiserum, on the course of single lesion infections of L. b. brasiliensis and L. tropica in experimental animals.

BIBLIOGRAPHY

- Acton, H.W., and Napier, L.E. (1927). Post kala-azar dermal leishmaniasis. *Indian J. med. Res.*, 15, 97.
- Adler, S. (1940). Experimental visceral leishmaniasis to man. *Trans. R. Soc. Trop. Med. Hyg.*, 34, 293.
- (1947a). Cellular reactions in leishmaniasis. *Acta med. orient.* 6, 151.
- (1947b). The behaviour of a Sudan strain of L. donovani in Phlebotomus papatasi. A comparison of strains of Leishmania. *Trans. R. Soc. Trop. Med. Hyg.*, 40, 701.
- (1963). Immune phenomena in leishmaniosis. In *Immunity to Protozoa*, ed. Garnham et al., ch.16, 235, Blackwell, Oxford.
- (1964). Leishmania. In *Advance in Parasitology*, 2, 35. ed. Dawes, Ben, Academic Press, London and New York.
- Adler, S. and Halff, L. (1955) Observation on Leishmania enriettii. *Ann. Trop. Med. Parasit.*, 49, 37.
- Adler, S. and Katzenellenbogen, I. (1952). The problem of the association between particular strains of Leishmania tropica and the clinical manifestations produced by them. *Ann. Trop. Med. Parasit.*, 46, 25.
- Adler, S. and Theodore, O. (1930). The inoculation of canine cutaneous leishmaniasis into man and the behaviour of various strains of Leishmania in mice. *Ann. Trop. Med. Parasit.*, 24, 197.
- Adler, S. and Zuckerman, A. (1948). Observations on a strain of Leishmania tropica after prolonged cultivation. Notes on infectivity and immunity. *Ann. Trop. Med. Parasit.*, 42, 178.

- Amrein, Y.U. (1967). Effect of environmental temperature on Trypanosoma cruzi infection in mice. *J. Parasit.*, 53, 1160.
- Anderson, O.S. (1964). Dermal leishmaniasis in a patient with leprosy in Western Tanganyika. *E. Afr. med. J.*, 41, 471.
- Azulay, R.D. (1960). Histopathologia de leishmaniose tegumentar. *Derm. ibero. lat. amer.*, 2, 7a.
- Baker, A.O. and Gutierrez, B.E. (1957). Tratamiento experimental de las ulceras leishmaniasicas por el procedimiento del calor del vapor. *Rev. Inst. Salubr. Enfermedades Trop.*, 17, 115.
- Baker, J.R. (1966). Studies in Trypanosoma avium IV. The development of Infective Metacyclic Trypanosomes in cultures grown in vitro. *Parasitology*, 56, 15.
- Balfour, A. and Thomson, D.S.B. (1911). Two cases of non-ulcerating "Oriental Sore", better termed Leishman nodules. Fourth Report Wellcome Tropical Research Laboratories, 1911
- Balzer, R.J., Destombes, P., Schaller, K.F. and Series, C. (1960). Leishmaniose cutanée pseudolepromateuse en Ethiopia. *Bull. Soc. Path.*, 53, 293.
- Bandieri, V. and Cavalcanti, J. (1965). Leishmaniose tegumentar americana. (Lesoes corniformes). *Hospital (Rio de J.)*, 68, 309.
- Barrientos, L.P. (1948). Un caso atipico de leishmaniosis cutanea mucosa (Espundia). *Mem. Inst. Osw. Cruz.*, 46, 415.
- Bell, D.W., Carmichael, J.A.G., Williams, R.S., Holman, R.L. and Stewart, P.D. (1958). Localized leishmaniasis of lymph node. Report of four cases. *Brit. med. J.*, 1, 704.
- Bendict, F.G. and Lee, R.C. (1936). La production de chaleur de la souris. Étude de plusieurs races de souris. *Ann. de Physiologie*, 12, 983. (Cited Weir, J.A. (1945). *Proc. Iowa Acad. Sci.*, 54, 383.)

- Bennison, B.E. and Coatney, G.R. (1945). Inactivation of malaria parasites by X-rays. *Publ. Hlth. Rep.*, 160, 127.
- Berberian, D.A. (1939). Vaccination and immunity against oriental sore. *Trans. R. Soc. trop. Med. Hyg.*, 33, 87.
- Berberian, D.A. (1944). Cutaneous leishmaniasis (Oriental sore). II. Incubation period. *Arch. Derm. Syph.*, 50, 231.
- Berberian, D.A. (1944). Cutaneous leishmaniasis (Oriental Sore). IV. Vaccination against oriental sore with suspensions of killed Leishmania tropica. *Arch. Derm. Syph.*, 50, 234.
- Berlin, C. (1940). Leishmaniasis recidiva cutis: Leishmanid. *Arch. Derm. Syph. (Chicago)*, 41, 874.
- Bernstein, S.E. (1967). Physiological characteristic in Biology of a laboratory Mouse. ed. Earal L. Green. 2nd edition. McGraw-Hill Book Co., New York and London.
- Biagi, F.F. (1953). Algunos comentarios sobre los leishmaniosis y su agentes etiologicos. Leishmania tropica mexicana, nueve subespecie. *Med. Rev. Mexicana*, 33, 401.
- Bloom and Fawcett. (1962). A textbook of Histology. Eighth edition. W.B. Saunders Co., Philadelphia and London.
- Borovsky, (1898). Uper das sartengeschwur (Wojenno Medizinsky Journal. November, p.925). Cited from Hoare, C.A. (1938). Early discoveries regarding the parasites of Oriental sore. *Trans. R. Soc. Trop. Med. Hyg.*, 32, 67.
- Boyd, G.H. (1929). *J. Expt. Zool.* 54, 111.
(Cited Stauber, L.A. (1953). *Ann. N.Y. Acad. Sci.*, 56, 1064).
- Brahmachari, U.N. (1922). A new form of cutaneous leishmaniasis dermal leishmanoid. *Indian Med. Gaz.*, 57, 125.
- Bray, R.S. and Garnham, P.C.C. (1962). The Giemsa-Colophonium method for staining protozoa in tissue sections. *Indian J. Malariology*, 16, 153.

- Bray, R.S. and Lainson, R. (1964). The growth of various strains of Leishmania spp. and of Lankestrella garnham in tissue cultures. In Proc. 1st. Int. Cong. Parasit, Rome, 1966, London, Milan, 1, 342.
- Bray, R.S. and Lainson, R. (1966). The immunology and serology of leishmaniasis. IV. Result of Ouchterlony double diffusion tests. Trans. R. Soc. Trop. Med. Hyg., 60, 605.
- Bray, R.S. and Lainson, R. (1967). Studies on the immunology and serology of Leishmaniasis. V. The use of particles as vehicles in passive agglutination test. Trans. R. Soc. Trop. Med. Hyg., 61, 490.
- Bray, R.S. and Munford, F. (1967). On the maintenance of strains of Leishmania from Guianas. J. Trop. Med. Hyg., 70, 23.
- Bryceson, A.D.M. (1969). Diffuse cutaneous leishmaniasis in Ethiopia. I. The clinical and histopathological features of the disease. Trans. R. Soc. Trop. Med. Hyg., 63, 708.
- (1971a). Diffuse cutaneous Leishmaniasis in Ethiopia. II. Treatment. Trans. R. Soc. Trop. Med. Hyg., 64, 369.
- (1970b). Diffuse cutaneous leishmaniasis in Ethiopia. III. Immunological studies IV. Pathogenesis of diffuse cutaneous leishmaniasis. Trans. R. Soc. Trop. Med. Hyg., 64, 380.
- Bryceson, A.D.M., Bray, R.S., Wolstencroft, R.A. and Dumonde, D.C. (1970). Immunity in cutaneous leishmaniasis of the guinea-pig. Clin. Exp. Immunol., 7, 301.
- Bryceson, A., Leithead, C.S. (1966). Diffuse cutaneous leishmaniasis in Ethiopia. Ethiop. Med. J., 5., 31.
- Bureau, Y., et al. (1960). Leishmaniose a localisation cutanees multiples et nodules lymphangitiques disseminees. Bull. soc. franc. Derm. Syph., 67, 67.

- Burowa, L. and Moltschanov, S.A. (1930). Einfluss der rontigenstralen auf die kulturen von Leishmania. (Influence of X-rays on culture of Leishmania.) Pensee Med. d'Uzbequistane et de Turqumenistane Tashment. p.47.
- de Castro, M.P. and Pinto, S.C. (1960). Influence of the temperature of the growth of Leishmania enriettii in tissue culture. J. Protozool., 7, suppl. 7.
- Ceithaml, J. and Evans, E.A. (1947). The biochemistry of the malaria parasite. IV. The in vitro effects of X-rays upon Plasmodium gallinaceum. J. Infect. Dis., 78, 190.
- Chatterchjee, K.D. (1952). Human parasites and parasitic diseases. Calcutta 26, India.
- Chen, T.T., Chen, P. and Li, L. (1953). Post kala-azar dermal leishmaniasis. China med. J., 71, 334.
- Chung, H.L. (1936). Studies on the resistance of Leishman-Donovan bodies to various physical, chemical and biological agents. Part I. The resistance of Leishman-Donovan bodies to certain physical agents, namely X-ray, heating, chilling and drying. China med. J., 50, 1039.
- (1942). Localized leishmaniasis of the lymph glands, with a note by V.T. Lieu. China med. J., 61, 19.
- (1944). Localized leishmaniasis of the lymph glands with a note by V.T. Lieu. China med. J., 62, 284.

- Coelho, M. de V., and Coutinho-Abath, E. (1965). Experimental cutaneous leishmaniasis. I. Infection of albino mice and Syrian hamsters by Leishmania mexicana. Rev. Inst. Med. trop. (S. Paulo), 7, 135.
- Congdon, E.D. (1911). The surround of the germ plasm III. The internal temperature of warm blooded animals (Mus decumanus, M. musculus, Myoxus glis) in artificial climates. Arch. Entwicklungsmechanik der Organismen, 33, 703.
- Coutinho-Abath, E., and Coelho, M. de V. (1965). Experimental cutaneous leishmaniasis. II. The pathology of leishmaniasis by Leishmania mexicana. Rev. Inst. Med. trop. (S. Paulo) 7, 145.
- Convit, J. (1958). Leishmaniasis tegumentaria diffusa. Nueva entidad clinica patologica y parasitaria. Rev. Sanid. Asist. soc., 23, 1.
- Convit, J. and Alarcon, C.H. (1957). Leishmaniasis tegumentaria diffusa. Nueva entidad nosologica XI. Congreso Internacional de Dermatologia Estocolmo, Julio, 1957.
- Convit, J., Alarcon, C.J., Medina, R., Reyes, O. and Kerdel-Vegas, F. (1959). Leishmaniasis tegumentaria difusa. Nueva entidad clinica patologica y parasitaria. Arch. Ven. Med. trop., 3, 218.
- Convit J. and Kerdel-Vegas, F. (1960). A new disease of the leishmaniasis group: Leishmaniasis cutis difusa. Hautarzt, 11, 213.
- Convit, J. and Kerdel-Vegas, F. ^{and Gordon, G.} (1962). Disseminated anergic cutaneous leishmaniasis. Brit. J. Derm., 74, 132.
- Convit, J. and Kerdel-Vegas, F. (1965). Dissomiated cutaneous leishmaniasis. Inoculation to laboratory animals, electron-microscopy and fluorescent antibodies studies. Arch. Derm., 91, 439.
- Convit, J. and Lapenta, P. (1948). Sobre un caso de leishmaniosis diseminada. Rev. Policlinica Caracas., 18, 153.
- Convit, J. and Pinaridi, M.E. (1969). Applying the inderect immuno-fluorescency test to the study of American cutaneous leishmaniasis. Derm. Int., 8, 17.

- Convit, J., Reyes, O., Kordel-Vegas, F. (1957). Disseminated anergic American leishmaniasis. Report of three cases of a type clinically resembling lepromatous leprosy. Arch. Derm. Syph. (Chicago), 76, 213.
- Crew, F.A.E. (1922). A suggestion as to the cause of the aspermatic condition of the imperfectly descended testis. J. Anat. Lond., 56, 98.
- Cunningham, D.D. (1885). On the presence of peculiar parasitic organisms in the tissue of specimen of Delhi boil. (Scientific Memoirs by Medical Officers of the Army of India, Calcutta Part 1 (1884), pp.21-31.)
- Cushing, J.E. (1942). An effect of temperature upon antibody-production in fish. J. Immunol., 45, 123.
- Da Fonesca, F. (1929). Possibilidade de injeccao de Camondongo branco com a Leishmania barsiliensis, Vienna, 1911. Bol. Biol. S. Paulo, No.15, 10 Abstract, Trop. Dis. Bull., 27, 97.
- Das Gupta, B.M. (1930). On the differentiation of Leishmania tropica from the parasite of dermal leishmanoid. Indian J. med. Res., 18, 105.
- Deane, M.P., Chaves, J., Torrealba, J.W. and Torrealba, J.F. (1966). Aislamiento de leishmanias de la medula osea y de la sangre de una paciente con leishmaniasis tegumentaria difusa. Gac. Med. Caracas, 74, 367.
- Degos, M.R., Lortat-Jacob, E. and Legrain, M. (1951). Leishmaniose diffuse lupoide. Bull. Soc. franc. Derm. Syph., 58, 10.
- Destombes, P. (1960). Application du concept de "Systematisation Poirier" aux leishmanioses cutanees. Bull. Soc. Path. exot., 53, 299.
- Destombes, P., Poirier, A., and Sérié, C. (1965). Leishmaniose cutanée nodulaire Disseminée en Ethiopie. Archs. Inst. Pasteur Alger., 43, 9.

- Diendonne (1894). Arbeit kaiserl gesundh. I, 497.
(Cited: Stauber, L.A. (1953). Ann. N.Y. Acad. Sci., 56, 1064.)
- Dobrzhanskaya, R.S. (1964). Tuberculous form of cutaneous leishmaniasis. Problems of etiology, pathogenesis, clinical picture and treatment. Vest. Derm. Vener., 38, 29.
- (1965). Migration of Leishmania in surface layers of the skin. Vest. Derm. Vener., 39, 37.
- Donovan, C. (1903). A possible cause of kala-azar. Indian Med. Gaz., 39, 321.
- Dostrovsky, A. (1935). The diagnostic value of Leishmania vaccine. Ann. Trop. Med. Parasit., 29, 123.
- (1936). Relapses in cutaneous leishmaniasis. Ann. Trop. Med. Parasit., 30, 367.
- Dostrovsky, A. and Sagher, F. (1945). Generalized recurrence in Leishmaniasis (Oriental sore): Report of a case with 110 lesions. Ann. Trop. Med. Parasit., 39, 98.
- Dostrovsky, A., and Sagher, F. (1946). The intracutaneous test in cutaneous leishmaniasis. Ann. Trop. Med. Parasit., 40, 265.
- Dostrovsky, A., Zuckerman, A. and Sagher, F. (1952). Successful experimental superinfection of Leishmania tropica in patients with relapsing cutaneous leishmaniasis. Harefuah, 43, 29.
- Dostrovsky, A., Sagher, F. and Zuckerman, A. (1953). Isophasic reaction following experimental superinfection of L. tropica. A.M.A. Arch. Der. Syph, 66, 665.
- Druckman, A. and Dostrovsky, A. (1936). X-ray treatment of Leishmania cutanea. Harefuah, 10, 328.

- Duke, H.L. (1934). On the transmissibility by Glossina of Trypanosoma brucei, T. rhodesiense and T. gambiense, with special reference to old laboratory strains. Ann. trop. Med. Parasit., 26, 153.
- Duna, T.N. (1954). Normal and Pathological anatomy of reticular tissue in laboratory mice. J. Nat. Cancer. Inst., 14, 128.
- Dutt, P.K. and Mithur, M.P. (1955). Treatment of oriental sore by radiotherapy. J. Indian med. Ass., 24, 620.
- Duxbury, R.E. and Sadun, E.H. (1969). Resistance produced in mice & rats by inoculation with irradiated Trypanosoma rhodesiense. J. parasit., 55, 859.
- Eliseev, L.N. and Strelkova, M.V. (1966). Effect of the environmental temperature on the temperature of the skin and the course of cutaneous leishmaniasis in Rhombomys opimus and Meriones libycus. Medskaya Parazit., 35, 696.
- Emmett, J. (1950). Effect of X-radiation on Trypanosoma cruzi. J. Parasit., 36, 45.
- Ercoli, N. (1961). Chemotherapeutic studies on cutaneous leishmaniasis. Proc. Soc. exp. Biol., N.Y., 106, 787.
- Ercoli, N. and Coelho, M.V. (1967). Problems of drug evaluation in cutaneous leishmaniasis. Ann. Trop. Med. Parasit., 61, 488.
- Ercoli, N. & Fink, R.M. (1966). Drug responsiveness in experimental cutaneous leishmaniasis. Exp. Parasit., 19, 320.
- Even-Paz, Z. and Sagher, F. (1961). Some basic medical problems illustrated by experiments with cutaneous leishmaniasis. S. Afr. Med. J., 35, 576.
- Ferguson, A.R. and Richards, O. (1910). Parasitic granuloma: a condition allied to oriental sore, occurring in Egypt. Ann. Trop. Med. Parasit., 4, 155.

- Firth, R.H. (1891). Notes on the appearance of certain sporozoid bodies in the protoplasm of an "Oriental sore". *Brit. Med. J.*, 1, 60.
- Floch, H. (1954). *Leishmania tropica guyanensis* n. sp. tegumentaire des agent de la leishmaniose tegumentaire des Guyanes e de l'Americque Centrale. *Bul. Soc. Path. Exotique.*, 47, 784.
- Fox, H. (1931). American leishmaniasis. Report of cases observed in Brazil. *Arch. Derm. Syph. (N.Y.)*, 23, 480.
- Fuller, H.S. and Gieman, Q.M. (1942). South American Leishmaniasis in experimental animals. *J. Parasit.*, 28, 429.
- Galliard, H. (1962). Nodular and diffuse forms of cutaneous leishmaniasis. *Sci. Rep. Ist. Super. Sanita.*, 2, 154.
- Garnham, P.C.C. (1962). Cutaneous leishmaniasis in the New World with special reference to *L. mexicana*. *Sci. Rep. Ist. Super. Sanita.*, 2, 76.
- Garnham, P.C.C. and Humphrey, J.H. (1969). Problems in Leishmaniasis related to immunology. *Curr. Topics Microbiol. Immunol.*, 48, 29.
- Garnham, P.C.C. and Lewis, D.J. (1959). Parasites of British Honduras with special reference to Leishmaniasis. *Trans. R. Soc. trop. Med. Hyg.*, 53, 12.
- Gibier (1882). *Compt. rend. acad. Sci.* 94, 1605. (Cited: Stauber, L.A. (1953). *Ann. N.Y. Acad. Sci.* 56, 1064.)
- Giese, A.C. (1967). Effect of radiation upon Protozoa in Research in Protozoology, 2, 267. (Ed. Tze-Tuan Chin) Pergamon Press.
- Goldman, L. (1947). Types of American cutaneous leishmaniasis - dermatological aspects. A review. *Amer. J. Trop. Med.*, 27, 561.
- Gonder, R. (1913). Experimentelle Übertragung von Orientbeule auf Mause. *Arch. f. Schiffs. U. Trop. Hyg.*, 17, 397, *Abstract. Trop. Dis. Bull.*, 2, 49.

- Greenblatt, C.L. and Glaser, P. (1965). Temperature effect on Leishmania enriettii in vitro. Exp. Parasit., 16, 36.
- Guimaraes, F.N. (1947). Visceralisacao da "Leishmania braziliensis" Vianna, 1911 em hamsters (Cricetus auratus). Nota preliminar. Bras. Med., 61, 395.
- (1951a). Experimental South American leishmaniasis. J. Amer. med. Ass., 147, 1496.
- (1951b). Leishmaniose experimental. II. Compartamento da Leishmania Braziliensis, Vianna, am hamsters (Cricetus auratus). Hospital (Rio de J.), 40, 25.
- (1951c). Leishmaniose experimental, III (a) Comportamento da L. braziliensis em camundongos (Mus musculus, var. albino); (b) Infeccoes ligeiras em "Cotton rats" Sigmon hispidus hispidus; (c) Animals refractorios. Hospital, (Rio de J.), 40, 153.
- (1951d). Leishmaniose experimental. IV. Reproducao em hamsters (Cricetus auratus) de uma leishmaniose cutanea nodulo-tumoral oriunda da Amazonia (Histiocitoma leishmaniofice). Hospital (Rio de J.), 40, 665.
- (1951e). Leishmaniose experimental. V. Reproducao em camundongos (Mus musculus var. Albino) de uma leishmaniose cutanea nodulo-tumoral (Histiocitoma leishmaniofice) ocorrendo na Amazonia. Hospital (Rio de J.), 40, 919.
- Gurr, E. (1956). A practical Manual of Medical and Biological Staining Techniques. New York, Interscience Publishers Inc.
- Halberstaedter, L. (1938). The effect of X-rays on trypanosomes. Brit. J. Radiol. (new series), 11, 267.
- Hayatee, Z.G. (1969). Course of leishmaniasis diffusa in some laboratory animals. J. Protozool., 16, Suppl., 29.

- Hayatee, Z.G. (1970). Effect of environmental temperature on cutaneous leishmaniasis diffusa in mice. *Trans. R. Soc. Trop. Med. Hyg.*, 64, 17.
- Hindle, E. and Thompson, J.G. (1928). *Leishmania infantum* in Chinese hamsters. *Proc. R. Soc. Med. B.*, 103 252.
- Holtman, D.F. (1946). The effect of environmental temperature on mouse susceptibility to poliomyelitis virus. *Science*, 103, 137.
- Hu, C.H. (1933). Histopathology of kala-azar in experimentally infected hamsters. *Chinese med. J.*, 47, 112.
- Huff, C.G. (1939). Relations between malarial infections and body temperatures in canaries. *Am. J. Hyg.*, 29 (C), 149.
- Hutchison, R.H. and Garnham, L.W. (1914). The influence of experimental trypanosomiasis upon the body temperature of white rats. *Am. J. Trop. Dis. & Prevent. Med.*, 1, 760.
- Ipsen, J. (1952). The effect of environmental temperature on the immune response of mice to Tetanus toxoid. *J. Immunol.*, 69, 273.
- Jannsen, C.W. and Wealer, E. (1967). Body temperature, antibody formation and inflammatory response. *Acta Pathol. Microbiol. Scand.*, 69, 557
- Janovy, J. and Poorman, A.E. (1969). Temperature and metabolism in *Leishmania*. I. Respiration in *L. donovani*, *L. mexicana*, and *L. tarentolae*. *Exptl. Parasit.*, 25, 276.
- Jarrett, W.F.H., Jennings, F.W., Martin, B. McIntyre, W.I.M. Mulligan, W., Sharp, N.C.C. and Urquhart, G.M. (1958). A field trial of parasitic bronchitis vaccine. *Rec.*, 70, 451.

- Jarrett, W.F.H., Jennings, F.W., Martin, B., McIntyre, W.I.M., Mulligan, W., Sharp, N.C.C. and Urquhart, G.M., (1959). Immunological studies on Dictyocaulus viviparus infection. Active immunization with whole worm vaccine. *Immunol.*, 3, 135.
- Jarrett, W.F.H., Jennings, F.W., McIntyre, W.I.M., Mulligan, W., and Urquhart, G.M. (1960). Immunological studies on Dictyocaulus viviparus infection. Active immunization with whole worm vaccine. *Immunol.*, 3, 135.
- Kalbuohov, N.D. and Levinson, L.B. (1936). The effect of temperature upon trypanosomes (Trypanosoma equiperdum) in the organisms of mammals. *Comptes Rendus (Doklady) d Lacademic des Sciences L URSS I (X)*, 47.
- Katzenellenbogen, I. (1944). Vaccination against oriental sore. Report of results of five hundred and fifty five inoculations. *Arch. Dermat. Syph.*, 50, 239.
- Kirk, R. (1942). Studies in leishmaniasis in the Anglo-Egyptian Sudan. V. Cutaneous and muco-cutaneous leishmaniasis. *Trans. R. Soc. Trop. Med. Hyg.*, 32, 533.
- Kirk, R. (1945). Studies in leishmaniasis in the Anglo-Egyptian Sudan. VII. Espundia in monkey infected experimentally with Sudan kala-azar. *Trans. R. Soc. Trop. Med. Hyg.*, 38, 489.
- Kirk, R. (1949). The differentiation and nomenclature of Leishmania. *Parasitology*, 39, 263.
- Kirk, R. and Sati, M.H. (1940). Studies in leishmaniasis in the Anglo-Egyptian Sudan. II. The skin and lymph glands in kala-azar. *Trans. R. Soc. Trop. Med. Hyg.*, 33, 501.
- Klotz, O. and Lindenberg, H. (1923). The pathology of leishmaniasis of the nose. *Am. J. Trop. Med.*, 3, 117.

- Kojevnikof, P.V. (1941). Experimental cutaneous leishmaniasis in white mice. In Problems of cutaneous leishmaniasis. Ashkabad, pp.249.
- Kolodny, M.B. (1940). The effect of environmental temperature upon experimental trypanosomiasis (T. cruzi) of rats. Am. J. Hyg., 32, 21.
- Kopeloff, L.M. and Stanton, A.H. (1942). The effect of body temperature upon hemolysin production in the rat. J. Immunol., 44, 247.
- Kurban, A.K. (1965). Histopathology of cutaneous leishmaniasis. Arch. Derm. (Chicago), 93, 396.
- Kurnick, N.B. (1955). Pyronin y in the methylgreen pyronin histological stain. Stain Technology, 30, 213.
- Kurotchkin, T.J. (1931). An attempt to immunize hamsters against kala-azar. Nat. Med. J. China., 17, 458.
- Lainson, R. and Bray, R.S. (1966). Studies on the immunology and serology of leishmaniasis. 2. Cross immunity experiments among different forms of American cutaneous leishmaniasis in monkeys. Trans. R. Soc. trop. Med. Hyg., 60, 526.
- Lainson, R. and Shaw, J.J. (1969) Some reservoir hosts of Leishmania in wild animals of Mato Grosso State, Brazil. Trans. R. Soc. Trop. Med. Hyg., 63, 408.
- Lainson, R. and Strangways-Dixon, J. (1963). Dermal leishmaniasis in British Honduras. 1. The human disease. Trans. R. Soc. Trop. Med. Hyg., 57, 242.
- Lainson, R. and Strangways-Dixon, J. (1962). Dermal leishmaniasis in British Honduras: Some host reservoirs of L. braziliensis mexicana. Brit. med. J., 1, 1596.
- Lainson, R. and Strangways-Dixon, J. (1964). Leishmania mexicana: the epidemiology of dermal leishmaniasis in British Honduras. II. Reservoir hosts of L. mexicana among the forest rodents. Trans. R. Soc. Trop. Med. Hyg., 58, 136.

- Larson, W.P., Levine, M., Bieter, R.N. and McLimans, W.F. (1940). Study of Mouse temperatures, with reference to the effect of temperature on sulfanilamide therapy. *J. Bact.*, 39, 45.
- Laveran, A. (1912). Infections of mice and rats by Mediterranean and Indian kala-azar. *Bull. Soc. Path. exot.*, 5, 26.
- (1914). Les leishmanioses chez les animaux. *Ann. Inst. Pasteur*, 28, 823.
- (1915). Nouvelle contribution a l'etude des infections experimentales de la souris sur la L. tropica.
- (1917). Les leishmanioses, kala-azar, Bouton d'Orient, Leishmaniose Americaine. Masson & cie. Edit. Paris.
- Laveran, A. and Mesnil, F. (1903). Sur un protozoaire noneveau (Piroplasma donovani Laveran et Mesnil), parasite d'une fièvre de l'Inde. *C.R. Acad. Sci.*, 137, 957.
- Laveran, A. and Mesnil, F. (1904). On a new protozoan (Piroplasma donovani, Laveran and Mesnil). The parasite of an Indian fever. *J.R. Army Med. Cps.*, 2, 216.
- Ledingham, J.C.G. (1908). The influence of temperature on phagocytosis. *Proc. R. Soc. Ser. B.*, 80, 188.
- Leishman, W.B. (1903). On the possibility of the occurrence of trypanosomiasis in India. *Brit. med. J.*, 1, 1252.
- Lelijveld, J. and Atanasiu, P. (1966). Multiplication de L. brasiliensis sur culture cellulaire de rein de hamster. *Ann. Inst. Pasteur*, 110, 788.
- Lemma, A. and Schiller, E.L. (1964). Extracellular cultivation of the leishmanial bodies of species belonging to the protozoan genus Leishmania. *Exptl. Parasit.*, 15, 503.

- Leon, L.A. (1957). Leishmaniasis y leishmaniasis, Universidad Central de Quito, Editorial Universitaria, Quito, Catedra de Medicine Tropical
- Levin, A.J. and Evans, T.C. (1942). The use of roentgen radiation in locating an origin of host resistance to *Trichinella spiralis* infections. *J. Parasit.*, 28, 477.
- Levinson, L.B. and Skadovskaja, N.S. (1946). On the histopathology of cutaneous leishmaniasis. *Med. Parasit. Parasitic. Dis.*, 15, 73.
- Lillie, R.D., Dyer, R.E., Armstrong, C. and Pasternack (1937) Seasonal variation in intensity of brain reaction of St. Louis Encephalitis in mice and of endemic typhus in guinea pigs. *Pub. Health. Rep.*, 32, 1805.
- Lindenberg, A. (1909). Die im Blute schmarotzenden Protozoen und ihre nächsten Verwandten. *Handbuch Tropenkrank.*, 3, 69. Leipzig: J.A. Barth. (Cited from Kirk, 1949).
- Luhe (1906) (Cited from Kirk, 1949)
- Malamos, B. (1949). Quoted by Leon, 1957.
- Manson-Bahr, P.H. (1966). *Manson's Tropical Disease*. 16 Ed. Bailliere, Tindall & Cassell Company Ltd., London.
- Manson-Barth, P.E.C. (1961). Immunity in kala-azar. *Trans. R. Soc. Trop. Med. Hyg.*, 55, 550.
- Manson-Bahr, P.E.C. (1963). Active immunization in leishmaniasis. In *Immunity to Protozoa*, ed. by Garnham et al., ch.17, Blackwell, Oxford.
- Manson-Bahr, P.E.C. (1964). Variations in the clinical manifestations of Leishmaniasis caused by *L. tropica*. *J. Trop. Med. Hyg.*, 67, 85.
- Manson-Bahr, P.E.C. and Southgate, B.A. (1964). Recent research on kala-azar in East Africa. *J. Trop. Med. Hyg.*, 67, 85.
- Martinez Baez, M. and Aleman, P. (1960). Histopatología de la leishmaniasis cutánea en México. *Ref. Inst. Salubr. Enferm. trop.*, 20, 153.

- Martinez, R.J.L., Alvarez, F.G. and Biagi, F.F. (1968). Presencia de la leishmaniasis cutanea generalizada en Mexico. *Revta Invest. Salud Publ.*, 28, 107.
- Martinez-Silva, R., Lopez, V.A., Colon, J.E. and Chiriboga, J. (1969). Trypanosoma cruzi: Effects of Gamma radiation on growth and infectivity. *Exptl. Parasit.*, 25, 162.
- Mata, A.D., Ruiz, C.B., Gasca, E.F., and Morales, M.C. (1968). Infection experimental con cepas mexicanas del agents causal de la leishmaniasis cutanae. *Salud Publ. Mex.*, 10, 159.
- Mayer, M. (1929). Tierver suche mit Leishmania tropica (orient beule). *Derm. Wschr.*, 88, 286. *Abstract. Trop. Dis. Bull.*, 26, 753.
- Mayer, M., Convit, J.Y., Pifano, F. (1949). Estudios experimentalis con una capa de Leishmania brasiliensis proveniente de un caso de leishmaniasis tegumentaria diseminada de aspecto lepromatoso. *Arch. Venez. Patol. Trop. Parasit. Med.*, 1, 183.
- Medina R. (1963). Leishmaniasis tegumentaria con multiples lesions cutanaes y mucosas. *Rev. Derm. Venez.*, 3, 83.
- Medina, R. and Romero, J. (1957). Estudio sobre la leishmaniasis tegumentaria en Venezuela. *Dermatologia Venezualana*, 1, 30.
- Medina, R. and Romera, J. (1959). Estudio clinico y parasitologico de una neuva capa de Leishmania. *Arch. Venez. Patol. trop. Parasit. Med.*, 3, 298.
- Medina, R. and Romero, J. (1962). Leishmania pifanoi N. sp. El agents causal de la leishmaniasis tegumentaria difusa. *Arch. Venez. Med. trop.*, 4, 349.
- Meleney, H.E. (1925). The histopathology of kala-azar in hamsters, monkeys and man. *Am. J. Path.*, 1, 147.

- Miller, T.A. (1965). Persistence of immunity following double vaccination of pups with X-irradiated Ancylostoma caninum larvae. *J. Parasit.*, 51, 705.
- (1968). Pathogenesis and immunity in hookworm infection. *Trans. R. Soc. Trop. Med. Hyg.*, 62, 473.
- Mills, C.A. and Schmidt, L.H. (1942). Environmental temperatures and resistance to infection. *Amer. J. Trop. Med. and Hyg.*, 22, 655.
- Mirzoian, N.A. (1941). Sur l'affection primaire dans la leishmaniose viscerale des enfants. *Med. Parasit. & Parasit Dis.*, 10, 101. *Abstract. Trop. Dis. Bull.*, 40, 295.
- Mohiuddin, A. (1952). An investigation into the relationships between the species (Parasitic in man) of the genus Leishmania Ross, 1903. II. The serological relationship and pathogenicity of the various species. *Indian J. med. Res.*, 40, 171.
- Morgan, F.M., Watten, R.H. and Kuntz, R.E. (1962). Post kala-azar dermal leishmaniasis. A case report from Taiwan (Formosa). *J. Formosan Med. Ass.*, 61, 70.
- Mulligan, W. McL., H., Stewart, D.F. and Wagland, B. (1961). The use of irradiated larvae as immunizing agents in Haemonchus contortus and Trichostrongylus colubriformis infection of sheep. *Aust. J. Agr. Res.*, 12, 1175.
- Napier, L.E. and Das Gupta (1934). Further clinical observations on post kala-azar. *Indian Med. Gaz.*, 69, 121.
- Nicolle, C. (1908a). Sur trois cas d'infection splénique infantile a corps de Leishman observés en Tunisie. *Arch. Inst. Pasteur, Tunis*, 3, 3.
- (1908b). Reproduction expérimentale du kala-azar chez le chien avec le virus humain. *Arch. Inst. Pasteur, Tunis*, 4, 57.
- (1908c). Reproduction expérimentale du kala-azar chez le singe (Macacus sinicus). *Arch. Inst. Pasteur, Tunis*, 4, 63.

- Nicolle, C. and Comte, C. (1909). Kala-azar experimental du chien. *Arc. Inst. Pasteur, Tunis*, 4, 136.
- Nicolle, C. and Manceaux, L. (1909). Kala-azar experimental du singe. *Arc. Inst. Pasteur, Tunis*, 4, 133.
- Novy, F.G. and McNeil, W.J. (1904). On the cultivation of Trypanosoma brucei. *J. Infect. Dis.*, 1, 1.
- Nussenzweig, R., Vanderberg, J., Most, H. and Orton, C. (1967). Protective immunity produced by the injection of X-irradiated sporozoites of Plasmodium berghei. *Nature*, 216, 160.
- Ogle, C. and Mills, C.A. (1933). Animal adaptation to environmental temperature conditions. *Am. J. Physiol.*, 103, 606.
- Ortiz, I. and Pardo, L.E. (1949). Presentacion de un case de leishmania tegumentaria multiple con lesiones lepromatoides. *Bol. Laboratorio Clinica "Luis Razetti". Caracas*. 15, 320.
- Owen, D.U. (1927). A case of oriental sore. *Ann. Trop. Med and Parasit.*, 21, 277.
- Padilla, H.C. and Lainez, N.H. (1968). Leishmaniasis cutaneae diseminada revision del tema e informe del primer caso en Honduras. *Medne Cutanea*, 3, 119.
- Pasteur, L., Joubert, J. and Chamberland, M. (1878). *Compt. rend. acad. sci.*, 87, 47.
- Paraense, W.L. (1953). The spread of Leishmania enriettii through the body of the guinea pig. *Trans. R. Soc. Trop. Med. Hyg.*, 47, 556.
- Parrot, L. and Donatien, A. (1927). Leishmaniose cutanee primitive experimentale de la souris blanche. *C.R. Biol.*, 96, 448.
- Pautrizel, R., Ripert, C. and Duret, J. (1960). Resistance du foetus de rongeur (rat, cobaye, lapin) vis a vis de Trypanosoma equiperdum. *Ann. Parasit. Humaine et Comparée*, 35, 469.

- Pavoni, C. (1915). Contributo all studio della infezione sperimentale del *Mus musculus* con *Leishmania tropica* e *infantum*. *Pathologica.*, 7, 114.
- Pereira, C., de Castro, M.P. and de Mello, D. (1958). Influencia da temperatura cutanea no desenvolvimento de losoes Leishmanioticas. *Arq. Instit. Biolo. S. Paulo*, 25, 121.
- Pessoa, S.B. (1941). Profilaxia da leishmaniose tegumentar no estado de Sao Paulo. *Folha med.*, 22, 157.
- Pessoa, S.B. (1961). Classificao das leishmanioses e das especies do genero *Leishmania*. *Arg. Hig. e Sande Pub. (S. Paulo)*, 26, 41.
- Pessoa, S.B. and Barretto, M.P. (1944). Contribuicao para o estudo de imunidade da leishmaniose tegumentar americana Reunia Annal. des Desmato Sifilografos Brasileiros, Rio do J., 137. *Abstract.Trop. Dis. Bull.*, 43, 1030.
- Pifano, C.F. (1964). Some aspects of comparative geographic pathobiology of tegumentary leishmaniasis in the neo-tropical region. In *Proc. 1st Intern. Parasit. Rome 1964*, 1, 339.
- Pifano, C.F. and Scorza J.V. (1960). Aspectos inmunològicos de las leishmanias que parasitan al hombre, con especial referencia a la *Leishmania brasiliensis pifanoi*. Medina and Romero, 1959. *Arch. Venez. Med. trop.*, 3, 15.
- Poirier, A. (1964). Note preliminaire sur les leishmanioses en Ethiopie. *Inst. Pasteur Ethiopie*, 5, 89.
- Pons, A.R., Fernandez, R. and Soto, U.R. (1967). Un caso de leishmaniasis tegumentaria American diseminada (leishmanides). *Kasmera*, 2, 425. *Abstract Trop. Dis. Bull.* (1968). 65, 1425.
- Portugal, H. and Marques, A. Porte. (1960). Leishmaniose tegumentar difusa. *Hospital (Rio de J.)*, 57, 813.

- Price, E.W. and Fitzherbert, M. (1965). Cutaneous leishmaniasis in Ethiopia. A Clinical study and review of literature. *Ethiop. Med. J.*, 3, 57.
- Reinhard, P. (1918). *Med. Klin.*, 14, 619.
- Rey, H. (1943). Cellular reaction in the dermal connective tissue of the hamster to Leishmania brasilliensis. *J. Inf. Dis.*, 72, 117.
- Rigdon, R.H. and Rudison, H. (1945). Effects of radiation on malaria. An experimental study in the chick and duck. *Proc. Soc. Exp. Biol. Med.*, 59, 167.
- Rodhain, J. (1951). Infection expérimentale par toxoplasme de la marmotte en sommeil hivernal. *Ann. Soc. Belg. M.T.*, 31, 487.
- Ronconi, L. (1934). La rontgenterapia nella leishmaniosi cutanea. *Policlinico, Sez. prat.*, 41, 1480.
- Ross, R. (1903a). Note on the bodies recently described by Leishman and Donovan. *Brit. Med. J.*, 2, 1261.
- (1903b). Further notes on Leishman's bodies. *Brit. Med. J.*, 2, 1401.
- Ross, R. and Thomson, J.C. (1910). Experiments on the treatment of animals infected with Trypanosomes by means of Atoxyl, Vaccines, cold, X-rays and leucocytic extract; enumerative methods employed. *Ann. trop. Med. Parasit.*, 4, 487.
- Ross, R. and Williams, C.L. (1910). Preliminary experiments on the effect of cold on various diseases in small animals. *Ann. trop. Med. Parasit.*, 4, 225.
- Row, R. (1912). Leishmania donovani and Leishmania tropica. *Brit. Med. J.*, 2, 674.

- Row, R. (1914a). Generalized leishmaniasis in a mouse with the culture of Leishmania tropica from oriental sore. Bull. Soc. Path. exot., 7, 272.
- (1914b). Experimental leishmaniasis in the monkey and mouse, induced by the parasite in culture. Indian J. Med. Res., 1, 617.
- (1924). On some pathological observations in experimental leishmaniasis in mice and with special reference to generalized infection set up by Leishmania tropica.
- Rudison, H. (1945). See Rigden.
- Russell, A. (1756). The natural history of Aleppo and parts. London. ch.4 Mal of Aleppo (cited by Geber, E. (1874). Erfahrung aus meiner Orientreise. I. Ueber das Wesen der Aleppobeule. Vierteljahresschrift fur Dermatologie und Syphilis. Wien, 6, 445.)
- Russell, P.F., Mulligan, H.W. and Mohan, B.N. (1942). Active immunization of fowls against sporozoites but not trophozoites of Plasmodium gallinaceum by injections of homologous sporozoites. J. Mal. Inst. Ind., 4, 311.
- Sagher, F. (1946). Activation of an originally negative intracutaneous Leishmania vaccine reaction. Acta. Med. Orient., 3, 82.
- Sagher, F. (1947). Leishmania vaccine test in leishmaniasis (oriental sore). J. invest. Der., 24, 417.
- Sanders, A. and Wallace, F.G. (1966). Immunization of rats with irradiated Trypanosoma lewisi. Exptl. Parasit., 18, 301.

- Sarracino, J.B. and Soule, M.H. (1941). Effect of heat, cold, fatigue and alcohol on resistance of mice to human influenza virus. *Proc. Soc. Exp. Biol. Med.*, 48, 183.
- Seebach (1825). Cited from Sharder, J.E. (1937). *Physics for students of applied science*. 1st edition, McCraw-Hill Book Co., London.
- Senekji, H.A. (1941). Biochemical reactions of the Genus Leishmania. *Am. J. Hyg.*, 34, 67.
- Sen Gupta, P.C. (1956). Observation on post kala-azar dermal leishmaniasis. *Rev. Brasil Malariol. e Doencas Trop.*, 8, 175.
- (1962). Post kala-azar dermal leishmaniasis. *Sci. Rep. 1st Super Sanita.*, 2, 124.
- Sen Gupta, P.C. and Bhattacharyya, B. (1951). The spleen in kala-azar. *J. Ind. Med. Ass.*, 21, 1.
- Sen Gupta, P.C. and Bhattacharyya, B. (1953). Histopathology of post kala-azar dermal leishmaniasis. *J. Trop. Med.*, 56, 110.
- Sen Gupta, P.C., Chakravarty, N.K., Ray, H.N. and Das Gupta, B. (1956). The liver in kala-azar. *Ann. trop. Med. Parasit.*, 50, 252.
- Sergent, Ed. (1915). Infections experimentales de la souris par des cultures de la Leishmania tropica. *Bull. Soc. Path. exot.*, 8, 22.
- Shanbrom, et al. (1955). Quoted by Leon, 1957.
- Shortt, H.E. (1928). Infection of hamsters (Cricetus griseus) with Leishmania donovani by the oral and conjunctival routes. *Indian J. med. Res.*, 16, 271.
- Simpson, M.H., Mullins, J.F. and Stone, O.J. (1968). Disseminated anergic cutaneous leishmaniasis. An autochthonous case in Texas and the Mexican States of Tamaulipas and Nuevo Leon. *Arch. Derm.*, 97, 301.

- Skinner, B. and Carson, H.W. (1911). Br. Med. J., 1, 431.
- Smyly, H.J. and Young, C.W. (1924). The experimental transmission of leishmaniasis to animals. Proc. Soc. exp. Biol. (N.Y.), 21, 354.
- Snow, J.S., Satulsky, E.M. and Bean, B.H. (1948). American cutaneous leishmaniasis; report of 12 cases from the Canal Zone. Arch. Dermat. Syph., 57, 90.
- Splendore, A. (1911). Boubu-Blastomycose leishmaniose. Notes sur quelques affections framboesifrinses observées au Bresil. Annal. Hyg. Med. coloniales, 14, 138.
- Stauber, L.A. (1939). Factors influencing the asexual periodicity of airan malaria. J. Parasitol, 25, 95.
- (1953). Some effects of host environment on the course of leishmaniasis in the hamster. Ann. N.Y. Acad. Sci., 56, 1064.
- (1955). Leishmaniasis of the hamster. In some Physiological Aspects and Consequences of Parasitism, p.76. ed. by Cole, W.H., Rutgers University Press, New Brunswick, New Jersey.
- (1962). Some recent studies in experimental leishmaniasis. Sci. Repts. Ist. Super. Sanita, 2, 63.
- (1963). Immunity to Leishmania. Ann. N.Y. Acad. Sci., 113, 409.
- Strangways-Dixon, J. and Lainson, R. (1962). Dermal leishmaniasis in British Honduras. Transmission of L. braziliensis by Phlebotomas species. Brit. Med. J., 1, 297.
- Sulkin, S.E. (1945). The effect of environmental temperature on experimental influenza in mice. J. Immunol., 52, 291.

- Terzian, L.A. (1961). Morphological changes produced by gamma radiation produced on the sporogonic cycle of Plasmodium gallinaceum. Exptl. Parasit., 11, 102.
- Thomson, D.B. and Balfour, A. (1910). Two cases of non ulcerating "oriental sore" better termed Leishman nodules. J.R. Army Med. Cps., 14, 1.
- Thompson, R.L. and Parker, R.F. (1941). The effect of high external temperature on infectious myxoma of rabbits. J. Bact., 41, 53.
- Thornburgh, D.B., Johnson, C.M. and Elton, N.W. (1952). The histopathology of cutaneous leishmaniasis in Panama. Trans. R. Soc. trop. Med. Hyg., 46, 550.
- Urquhart, G.M. (1964). Development of irradiated vaccines against helminthic diseases. Tech. Rept. Series No.30, Inter. Atom. Energy Ag., Vienna, 11.
- Vassiladis, P., and Jardin, J. (1930). Influence de l'hibernation sur le Trypanosoma rhodesiense. Ann. Soc. Belg. Med. trop., 10, 129.
- Véléz., L. (1913). Uta et espundia. Bull. Soc. Path. exot., 6, 545.
- Vanderberg, J.P., Nussenzweig, R.S., and Most H. (1968). Further studies on the Plasmodium berghei-Anopheles stephensi - rodent system of mammalian malaria. J. Parasit., 54, 1006.
- Vanderberg, J.P., Nussenzweig, R.S., Most, H. and Orgon, C.G. (1968). Protective immunity produced by the injection of X irradiated sporozoites. J. Parasit., 54, 1175.
- Vianna, G. (1911). Sobre uma nova especie de Leishmania (Note preliminar). Brazil Med., 25, 411.
- Vignat, M. (1914). Presentation d'un Malade atteint d'une Lésion Ulcèreuse (Bouton de Biskra) ayant résisté six ans a Divers Traitements et guérie par une seule Cauterisation a l'air chaud. Bull. Soc. Française de Dermatol. et Syph., 25, 194.

- Wallace, F.G. and Hamilton, T.R. (1946). Yolk sac cultivation of Leishmania from tissue and culture. *Am. J. Clinical. Path.*, 16, 101.
- Warren, McW. and Garnham, P.C.C. (1969). The effect of X-irradiation of sporozoites of Plasmodium cynomalgi as seen by abnormal development in the liver. *Trans. R. Soc. trop. Med.*, 63,
- Weir, J.A. (1947). The temperature of the mouse in health and disease. *Proc. Iowa Acad. Sci.*, 54, 383.
- Wellde, B.T. and Sadun, E. & H. (1967). Resistance produced in rats and mice by exposure to irradiated Plasmodium berghei. *Expl. Parasit.*, 21, 310.
- Wenyon, C.M. (1913). A further study note on a case of dermal leishmaniasis from South America with the results of inoculation experiments. *J. Lond. Schl. trop. Med.*, 2, 117.
- Wenyon, C.M. (1926). *Protozoology*, London: Bailliere, Tindall & Cox.
- Wery, M. (1967). Studies on the sporogony of rodent malaria. Ph.D. Thesis, University of London.
- Willet, K.C. and Fairbairn, H. (1955). A study of Trypanosoma rhodesiense during eighteen years of cyclical transmission. *Ann. Trop. Med. Parasit.*, 49, 279.
- Wolf, H.F. (1935). Prevention of poliomyelitis in monkeys by means of hyperpyrexia. *Proc. Soc. Exp. Biol. Med.*, 32, 1083.
- Wright, J.H. (1903). Protozoa in a case of tropical ulcer ("Delhi sore"). *J. Med. Res.*, 10, 472.
- Yakimoff, W.L. (1915). Contribution a l'étude des leishmanioses de l'homme et du chien dans le Turkestan Russe. *Bull. Soc. Path. exot.*, 8, 474.

- Young, C.W. and Hertig, M. (1927). Kala-azar transmission experiments with sandflies (Phlebotomus). Proc. Soc. exp. Biol., 25, 196.
- Zeledon, R. (1960). Comparative physiological studies on four species of hemoflagellates in culture. I. Endogenous respiration and respiration in the presence of glucose. J. Protozool., 7, 146.
- Zeledon, R. and Blanco, E. (1965). Experimental infection in animals with Costa Rican strains of Leishmania braziliensis. J. Parasit., 51, Suppl., 20.
- Zeledon, R. and De Monge, E. and Blanco, E. (1965). Temperature of the host skin and physiology of the parasite in the experimental infection by Leishmania braziliensis, Vianna. Progress Protozool. 2nd Int. Conf. on Protozool. London. 133.
- Zeledon, R., Blanco, E. and De Monge, E. (1965). Comparative experimental infection with Costa Rican strains of Leishmania braziliensis, Vianna, 1911. Acta. Trop.,
- Zeledon, R. and De Monge, E. (1967). Physiological studies on the culture of Leishmania braziliensis. I. Nitrogen content, substrate utilization, and effect of metabolic inhibitors on respiration and its relation to infectivity. J. Parasit. 53, 937.
- Zuckerman, A. (1953). Initial reaction to the subcutaneous inoculation of cultures of Leishmania tropica in the hamster. Acta. med. Orient., 12, 238.
- Zuckerman, A. (1962). Some observations on immunity of L. tropica. Sci. Rep. Ist. Super. Sanita, 2, 95.
- Zuckerman, A. and Sagher, F. (1963). Experimental cutaneous leishmaniasis. The development of multiple cutaneous lesions (leishmanoid) following the prophylactic inoculation of living Leishmania tropica into a single site. J. Invest. Der., 40, 193.