

## CASE IMAGE

## Very mild bilateral ptosis following snakebite

Yoshihiro Aoki<sup>1,2</sup>  | Rustan Arrieta<sup>3</sup> | Grace Joy B. Aquino<sup>4</sup> | Chris Smith<sup>2,5</sup> | Lourdes C. Agosto<sup>4</sup>

<sup>1</sup>Coordination Office for Emergency Medicine and International Response, Acute and Critical Care Center, Nagasaki University Hospital, Nagasaki, Japan

<sup>2</sup>School of Tropical Medicine and Global Health, Nagasaki University, Nagasaki, Japan

<sup>3</sup>Department of Emergency Medicine, Eastern Visayas Medical Center, Tacloban, Philippines

<sup>4</sup>Poison Control Center, Eastern Visayas Medical Center, Tacloban, Philippines

<sup>5</sup>Department of Clinical Research, London School of Hygiene and Tropical Medicine Faculty of Infectious and Tropical Diseases, London, UK

## Correspondence

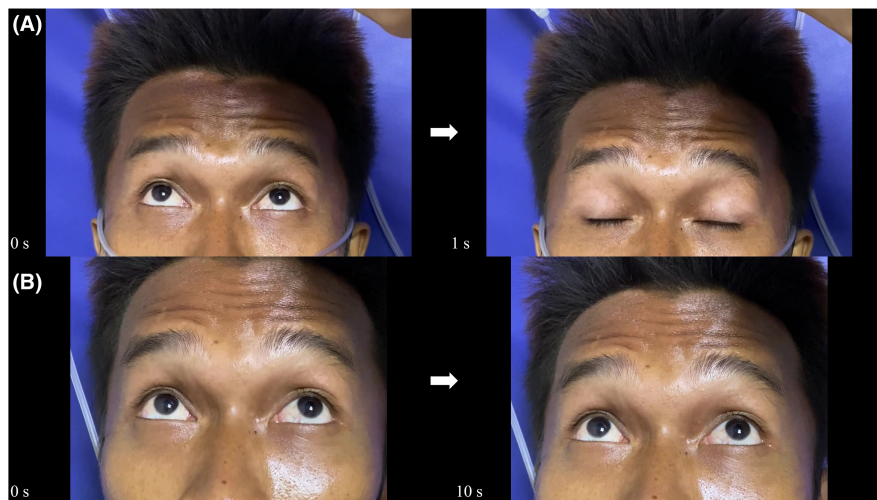
Yoshihiro Aoki, Coordination Office for Emergency Medicine and International Response, Acute and Critical Care Center, Nagasaki University Hospital, 1-7-1 Sakamoto, Nagasaki 852-8102, Japan.

Email: [yaoki-hki@umin.ac.jp](mailto:yaoki-hki@umin.ac.jp)

A 22-year-old male construction worker in Eastern Samar, Philippines, was bitten on his right leg by a black and yellow snake in the coastal area. Despite receiving a local remedy, he was later brought to the emergency department. Twelve hours post-bite, careful examination revealed mild bilateral ptosis, with the patient struggling to keep his eyes open, especially during upward gaze (Figure 1A). The bite site showed mild swelling, tenderness, and two fang marks. Although the snake responsible was not conclusively identified, based

on the geographical distribution, snake description, and clinical signs, *Naja samarensis* envenomation was suspected. Intravenous administration of Purified Cobra Antivenom (Research Institute for Tropical Medicine)<sup>1</sup> significantly improved eye-opening ability within 30 min: the patient could open his eyes fully and sustain eye-opening (Figure 1B).

Although the literature reports a limited number of cases, *Naja samarensis*, Samar cobra, is a WHO category I venomous snake in the Philippines.<sup>2</sup> Often, snakebite envenomation



**FIGURE 1** (A) Upon admission (12h after the bite), the patient was unable to keep his eyes open for more than 1 s, particularly during upward gaze. (B) Thirty minutes after the administration of Purified Cobra Antivenom, the patient was able to keep his eyes open for more than 10 s, indicating an improvement in the bilateral ptosis.

This is an open access article under the terms of the [Creative Commons Attribution-NonCommercial](https://creativecommons.org/licenses/by-nc/4.0/) License, which permits use, distribution and reproduction in any medium, provided the original work is properly cited and is not used for commercial purposes.

© 2024 The Authors. *Acute Medicine & Surgery* published by John Wiley & Sons Australia, Ltd on behalf of Japanese Association for Acute Medicine.

diagnosis depends on clinical observations due to limited diagnostic tools.<sup>3</sup> As demonstrated in our image of the probable *Naja samarensis* case, detection of bilateral ptosis is crucial in recognizing neurological snakebite envenomation. This sign is vital to identify neurotoxic envenomation from various snakes globally, including exotic species.

#### CONFLICT OF INTEREST STATEMENT

The authors declare no conflicts of interest.

#### DATA AVAILABILITY STATEMENT

Data sharing is not applicable to this article as no new data were created or analyzed in this study.

#### ETHICS STATEMENT

Approval of the research protocol: N/A.

Informed Consent: Informed consent was obtained by the patient.

Registry and the Registration No. of the study/trial: N/A.

Animal studies: N/A.

#### ORCID

Yoshihiro Aoki  <https://orcid.org/0000-0003-2011-485X>

#### REFERENCES

1. Research Institute for Tropical Medicine. Purified Cobra Antivenom (PCAV): How is it made? Available from: <https://ritm.gov.ph/purified-cobra-antivenom-pcav-how-is-it-made/>. Accessed 16 Jan 2024
2. Paghubasan J, Aoki Y, Tiglao PJG, Sarmiento MJ, Tan MA, Sarsalijo MS, et al. A case series of samar cobra, *Naja samarensis* Peters, 1861 (Elapidae) envenomation. *Toxicon*. 2023;223:107008.
3. Seifert SA, Armitage JO, Sanchez EE. Snake envenomation. *N Engl J Med*. 2022;386:68–78.

**How to cite this article:** Aoki Y, Arrieta R, Aquino GJB, Smith C, Agosto LC. Very mild bilateral ptosis following snakebite. *Acute Med Surg*. 2024;11:e935. <https://doi.org/10.1002/ams2.935>