

Studies on the Pathogenesis of Trachomatous Scarring



Victor H. Hu

2011

**International Centre for Eye Health
Faculty of Infectious and Tropical Diseases
London School of Hygiene and Tropical Medicine**

**Thesis submitted for the degree of
Doctor of Philosophy, University of London**

Abstract

Trachoma is a chronic keratoconjunctivitis caused by recurrent episodes of infection with the gram negative bacterium *Chlamydia trachomatis*. It is the most common infectious cause of blindness with at least 1.3 million estimated to be blind from the disease, 8 million to have trichiasis and 40 million to have active disease. Trachoma is now predominantly found in poor, rural areas in developing countries and it is classified by the World Health Organization as a Neglected Tropical Disease. Ocular infection with *C. trachomatis* is usually found in children and causes a marked inflammatory response with a follicular conjunctivitis and papillary hypertrophy. After suffering recurrent episodes of infection and inflammation these children are at risk of developing conjunctival scarring which can progress to entropion, trichiasis, corneal opacity and blindness in later life. The pathogenesis of the scarring process is believed to be immune mediated but is poorly understood. The aim of this work was to further our understanding of the pathogenesis of scarring trachoma.

Two case-control studies were undertaken. The Trachomatous Scarring (TS) study included 363 cases with mild-moderate conjunctival scarring and 363 control subjects. Participants underwent a clinical examination, digital photography, *in vivo* confocal microscopy (IVCM) and had conjunctival swabs taken for quantitative gene expression, *C. trachomatis* detection and bacteriological culture. The Trachomatous Trichiasis (TT) study included 34 cases with trachomatous trichiasis who had severe conjunctival scarring and 33 control subjects. Participants underwent similar examination and sample collection procedures as those in the TS study, but in addition had conjunctival biopsy samples taken for histology and immunohistochemistry.

Scarring was associated with evidence of an innate immune response with increased expression of antimicrobial peptides and pro-inflammatory mediators. Confirmation of an innate response was seen with immunohistochemistry with an increased infiltrate of Natural Killer cells seen in scarred tissue. Immunohistochemistry also showed an infiltrate of unidentified CD45 negative cells in cases. Scarring was associated with differential regulation of various modifiers of the extra-cellular matrix. There was no evidence of a Th2 response in scarred cases, but rather a Th1 response was detected. Non-chlamydial bacterial infection was more frequently found in cases than controls and was also associated with upregulation of innate and pro-inflammatory mediators. *C. trachomatis* was very rarely detected, but when seen was associated with a characteristic Th1 response seen in children.

Connective tissue scarring could be seen morphologically with masked grading of IVCM and histological sections. An increased inflammatory cell infiltrate could also be seen with both examination techniques. Gene expression changes in relation to IVCM scarring generally showed good agreement with corresponding changes by clinical scarring. IVCM appeared to be able to detect subclinical scarring and also identified dendritic cells which were strongly associated with the presence of scarring.

This work confirms other studies highlighting the importance of innate immune responses in the pathogenesis of trachomatous scarring. Non-chlamydial bacterial infection may be an important factor in driving this innate response with resulting tissue damage and fibrosis. Tissue changes could be objectively assessed with IVCM for various parameters, especially connective tissue scarring, and allowed some novel observations about the scarring process to be made.

Declaration

I, Victor Hu, confirm that the work presented in this thesis is my own. Where information has been derived from other sources, I confirm that this has been indicated in the thesis.

Signature

Date

Format of the thesis

The thesis for this PhD utilises the “research/review papers” format, recently introduced by the London School of Hygiene and Tropical Medicine. It therefore includes a number of papers which have either been published in, accepted by, or are formatted for submission to, peer-reviewed journals. The chapters listed in italics in the Contents are in this research/review paper format and include publication details in a cover sheet, including acknowledgement of the contributions of other people. The other chapters of the thesis are composed of “linking material” which includes information/data not covered in the papers and helps to make the thesis a coherent body. The linking material was written by Victor Hu.

Contents

Abstract	2
Declaration	4
Format of the thesis	5
Acknowledgements	7

Introduction

Chapter 1. <i>Epidemiology and control of trachoma</i>	9
Chapter 2. <i>Trachoma: an update</i>	30
Chapter 3. <i>Trachoma: protective and pathogenic ocular immune responses to Chlamydia trachomatis</i>	39
Chapter 4. <i>In vivo confocal microscopy of the ocular surface</i>	84
Chapter 5. <i>Clinical grading of trachomatous conjunctival scarring</i>	92
Chapter 6. <i>The problem, overall aims and study summaries</i>	103

Data chapters

Chapter 7. <i>Survey of trachomatous scarring</i>	107
Chapter 8. <i>In vivo confocal microscopy of trachoma in relation to normal tarsal conjunctiva</i>	111
Chapter 9. <i>In vivo confocal microscopy in scarring trachoma</i>	129
Chapter 10. <i>In vivo confocal microscopy and histopathology of the conjunctiva in healthy and trachomatous conjunctiva: a systematic comparison</i>	145
Chapter 11. <i>Bacterial infection in scarring trachoma</i>	177
Chapter 12. <i>Innate immune responses and modified extra-cellular matrix regulation characterize bacterial infection and cellular/connective tissue changes in scarring trachoma</i>	186
Chapter 13. <i>Immunohistological analysis of trachomatous scarring reveals increased CD8+ cells and an infiltrate of CD45 negative inflammatory cells</i>	217

General discussion and future work

Chapter 14. <i>Overall conclusions and future work</i>	255
--	-----

Appendices	262
-------------------	------------

Acknowledgements

This work would not have been possible without the support and contributions of many people.

Matthew Burton has been an incredible supervisor and mentor. He has given great time and care into helping to develop this research and bringing me along as a researcher. I am grateful to have lived with him in Moshi, both to be able to learn from him as we worked and for our families to get to know each other. He is an inspirational figure and I look forward to continue working with him on related projects.

I would not have accomplished this work without the support and encouragement of my wife, Rachel. She helped shape our time in Tanzania into a positive experience and enabled me to get the work done. Her very perceptive insights have helped me to keep things on track. She has also done a great job with our Lauren, Jasmine and Daniel.

My advisory committee have more than just advised. Robin Bailey has provided helpful and encouraging feedback on the field work and analytical issues. David Mabey was one of the first people to encourage me into trachoma research and has always been supportive. Helen Weiss has provided superb statistical and analytical guidance. All three have spent time in Moshi and their input has been much appreciated.

Martin Holland has given very helpful guidance and input as an immunologist and experienced laboratory scientist.

Phil Luthert has provided a massive contribution to this research. His input as a senior histopathologist and researcher has been invaluable. We have spent hours together looking at histological sections and working through grading systems and it has been a privilege to spend this time with him.

The British Council for Prevention of Blindness has generously supported this research.

This thesis is dedicated to the memory of Barrie Jones (1921-2009).

Contributors to the research presented in this thesis:

Person	Position	Contribution
Isaac Afwamba	Technician, KBL	Bacteriological culture
Robin Bailey	Professor, LSHTM	Associates supervisor, study design, field work supervision, analytical help
Matthew Burton	Senior Lecturer, LSHTM	Supervisor, study funding, study design, lab and field work supervision,
Caroline Chevalier	Lab manager for Duke University at KBL	Supervised bacteriological culture
Stefan Claesen	Visbion Chief Exec	Photo data management and software troubleshooting
Colin Clements	Ophthalmic photographer, KCH	Advice on ophthalmic photography
Paul Courtright	Head of KCCO	Advice on conducting research studies in Tanzania
Ian Cree	Professor, University of Portsmouth	Grading of histological sections
John Crump	Associate Professor, Duke University	Advice on lab work
Anthony Hall	Head Ophthalmologist, KCMC	Help with recruitment of controls
Emma Harding-Esch	Research Fellow, LSHTM	Drafting of sections for a review paper
Scott Hau	Optometrist, Moorfields Eye Hospital	Help with learning to use confocal microscope
Martin Holland	Senior Lecturer, LSHTM	Immunological advice
Phil Luthert	Professor, UCL	Grading of histological sections
Rose Lymo	Senior Eye Theatre Sister, KCMC	Preparation of surgical packs
Sarah Lymo	Administrator, KCCO	Data entry, administrative work
David Mabey	Professor, LSHTM	Study design, supervisory committee
William Makupa	Ophthalmologist, KCMC	Study design
Henry Marielle	Field assistant, KCCO	Digital photography
Antipas Massae	Driver, KCCO	Driving, including on rocky and flooded terrain
Patrick Massae	Senior trachoma field worker	Helped to coordinate the field work, trachoma screening
Phillipo Mollel	Field assistant, KCCO	Data recording, translation,
Emily Okello	Administrator, KCCO	Data entry, administrative work
Christopher Onguny	Technician, KBL	Bacteriological culture
Jecinta Onyango	Technician, KBL	Bacteriological culture
Alex Pallangyo	Field assistant, KCCO	Data recording, translation,
Athumani Ramadhani	Technician, KBL	PCR work
Brian Savage	Ophthalmologist, KCMC	Advice with surgical camps
Alice Shoo	Technician, KBL	PCR work
Sonda Tolbert	Technician, KBL	PCR work
Helen Weiss	Reader, LSHTM	Analytical guidance, supervisory committee

KBL = Kilimanjaro Biotechnology Laboratory

LSHTM = London School of Hygiene and Tropical Medicine

KCH = King's College Hospital

KCCO = Kilimanjaro Centre for Community Ophthalmology

KCMC = Kilimanjaro Christian Medical Centre

UCL = University College London

Chapter 1

Epidemiology and control of trachoma: systematic review



Review paper containing detailed summaries of the epidemiology, survey methods and control strategies for trachoma

Cover sheet for each 'research/review paper' included in a research thesis

1. For a 'research/review paper' already published
 - 1.1. Where was the work published? ***Tropical Medicine and International Health***
 - 1.2. When was the work published? ***June 2010***
 - 1.3. Was the work subject to academic peer review? **Yes**
 - 1.4. Have you retained the copyright for the work? **No**

If no, or if the work is being included in its published format, attach evidence of permission from copyright holder (publisher or other author) to include work

See Appendix 7a

2. For multi-authored work, give full details of your role in the research included in the paper and in the preparation of the paper. (Attach a further sheet if necessary)

The following sections of this paper were written by Victor Hu: Introduction; Historical Perspective; Clinical features and natural history; Infection vs disease; Transmission of Chlamydia trachomatis infection; Prevalence and geographical distribution; Risk factors for trachoma; Conclusion. Comments from co-authors were considered.

The other sections of this paper were primarily drafted by Emma Harding-Esch, with final editing done by Victor Hu: Assessing the burden of trachoma; Population-based prevalence surveys; Trachoma rapid assessment; Acceptance sampling TRA; Clinical signs versus infection; Controlling trachoma: the SAFE strategy; Surgery for trichiasis; Antibiotics; Facial cleanliness; Environmental improvement; The SAFE strategy: putting the pieces together.

Candidate's signature.....



Supervisor or senior author's signature to confirm role as stated in (2).....

Systematic Review

Epidemiology and control of trachoma: systematic review

Victor H. Hu^{1,2}, Emma M. Harding-Esch¹, Matthew J. Burton^{1,2}, Robin L. Bailey¹, Julbert Kadimpeul³ and David C. W. Mabey¹

¹ London School of Hygiene and Tropical Medicine, UK

² Kilimanjaro Centre for Community Ophthalmology, Moshi, Tanzania

³ Unité d'Ophthalmologie, Programme de Lutte Contre la Cécité, Région médicale de Ziguinchor, Senegal

Summary

Trachoma is the commonest infectious cause of blindness. Recurrent episodes of infection with serovars A–C of *Chlamydia trachomatis* cause conjunctival inflammation in children who go on to develop scarring and blindness as adults. It was estimated that in 2002 at least 1.3 million people were blind from trachoma, and currently 40 million people are thought to have active disease and 8.2 million to have trichiasis. The disease is largely found in poor, rural communities in developing countries, particularly in sub-Saharan Africa. The WHO promotes trachoma control through a multifaceted approach involving surgery, mass antibiotic distribution, encouraging facial cleanliness and environmental improvements. This has been associated with significant reductions in the prevalence of active disease over the past 20 years, but there remain a large number of people with trichiasis who are at risk of blindness.

keywords trachoma, review, *Chlamydia trachomatis*, epidemiology, control

Introduction

Trachoma is the leading infectious cause of blindness worldwide. It is caused by infection with *Chlamydia trachomatis* and is characterised by inflammatory changes in the conjunctiva in children with subsequent scarring, corneal opacity and blindness in adults. The World Health Organization (WHO) estimated in 2002 that 1.3 million people were blind from trachoma (Resnikoff *et al.* 2004) and it is likely that a further 1.8 million were suffering from low vision (Frick *et al.* 2003a). Many of the additional 1.9 million cases of blindness from 'corneal opacities' were also likely to be because of trachoma in areas where it is endemic (Resnikoff *et al.* 2004). The number of people with active disease is estimated to be 40 million, and the number with trichiasis, 8.2 million (Mariotti *et al.* 2009). Trachoma is an ancient disease and has previously been a significant public health problem in many areas of the world including parts of Europe and North America. Today, however, trachoma is largely found in poor, rural communities in low-income countries, particularly in sub-Saharan Africa. In 1998, the WHO established the Alliance for the Global Elimination of

Blinding Trachoma by 2020 (GET2020). This promotes trachoma control through the SAFE Strategy: surgery for trichiasis, antibiotics for *C. trachomatis* infection, facial cleanliness and environmental improvement. Where control measures have been implemented encouraging reductions in the prevalence of trachoma have been found.

Historical perspective

The earliest references to trachoma come from China in the 27th century BC (Al-Rifai 1988). Features of trachoma were also described in the Ebers papyrus from Egypt, 15th century BC, and epilation forceps discovered in tombs from the 19th century BC (Maccallan 1931, Hirschberg 1982). Trachoma became a major public health problem in Europe at the beginning of the 19th century, when the disease was believed to have been brought back by troops returning from the Napoleonic wars in Egypt. So great was the burden of the disease at that time that many of the major ophthalmic hospitals founded in the 19th century were established to treat trachoma, including Moorfields Eye Hospital and Massachusetts Eye and Ear Infirmary. By the end of the 19th century, immigrants to the United

States were routinely screened for trachoma and sent home if they had signs of the disease. Trachoma has now disappeared from developed countries (with the exception of Aboriginal communities in outback Australia (Tellis *et al.* 2007), probably as a result of general improvements in living and hygiene standards.

Clinical features and natural history

Trachoma is a chronic keratoconjunctivitis caused by recurrent infection with serovars A, B, Ba and C of *C. trachomatis*. Infection is most commonly found in children. With repeated reinfection, some people go on to develop scarring complications and blindness in later life. The clinical manifestations of trachoma are subdivided into those associated with 'active' disease, usually seen in childhood, and those associated with the cicatricial or scarring complications, seen in late childhood and adults (Figure 1). Active disease is characterised by recurrent episodes of chronic, follicular conjunctivitis. Follicles are subepithelial collections of lymphoid cells and appear as small, yellow-white elevations on the conjunctiva of the everted upper lid. Papillary hypertrophy (engorgement of small vessels with surrounding oedema) also occurs and can obscure the deep tarsal vessels if severe enough. Vascular infiltration of the upper cornea (pannus) may also develop in active disease, but this rarely affects vision. Individuals are frequently asymptomatic or have only mild symptoms even if marked signs of inflammation are evident. If present, symptoms are similar to those associated with any chronic conjunctivitis: redness, discomfort, tearing, photophobia and scant muco-purulent discharge. Conjunctival follicles

at the upper margin of the cornea leave shallow depressions after they resolve known as 'Herbert's pits' which, unlike follicles and papillae, are a pathognomonic sign of trachoma.

Repeated and prolonged episodes of infection and inflammation can result in the scarring complications of trachoma. Initially, conjunctival scarring is seen in the subtarsal conjunctiva, which can range from a few linear or stellate scars to thick, distorting bands of fibrosis. Contraction of this scar tissue causes entropion (in-turning of the eyelids) and trichiasis (eyelashes touching the eyeball) which is often painful. Eventually, corneal opacification develops the blinding end-stage of the disease. This is probably a result of multiple insults to the cornea: mechanical trauma from lashes, secondary bacterial or fungal infection and a dry ocular surface.

Over the years, various grading systems for trachoma have been proposed. The one which is currently used by trachoma control programmes is the 1987 WHO simplified grading system (Table 1) (Thylefors *et al.* 1987).

The prevalence of active disease is highest in pre-school children and declines to low levels in adulthood (Dawson *et al.* 1976; West *et al.* 1991b; Dolin *et al.* 1998). This parallels the distribution of *C. trachomatis* infection, with up to half of the community bacterial load being found in children under the age of 1 year in some studies (Solomon *et al.* 2003; Melese *et al.* 2004b). Adult bacterial loads are usually lower than those of children, and the duration of infection and disease also declines with age, presumably as the result of an acquired immune response (Bailey *et al.* 1999; Grassly *et al.* 2008). This is in contrast to the scarring features of trachoma, the prevalence of which

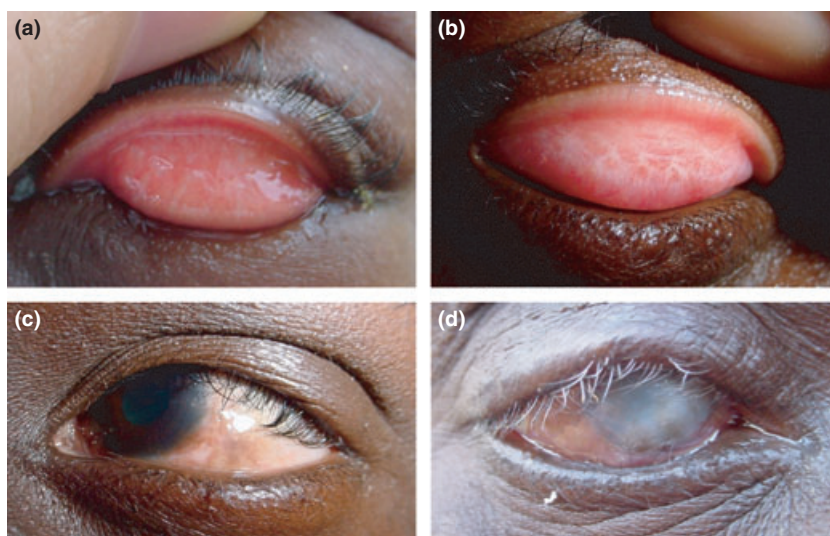


Figure 1 Clinical features of trachoma. (a) Active trachoma in a child, characterised by a mixed papillary (TI) and follicular response (TF). (b) Tarsal conjunctival scarring (TS). (c) Entropion and trichiasis (TT). (d) Blinding corneal opacification (CO) with entropion and trichiasis (TT).

Table 1 1987 WHO simplified trachoma grading (Thylefors *et al.* 1987)

Grade	Description
Trachomatous inflammation – Follicular	TF The presence of five or more follicles (each >0.5 mm in diameter) in the upper tarsal conjunctiva
Trachomatous inflammation – Intense	TI Pronounced inflammatory thickening of the tarsal conjunctiva that obscures more than half of the deep normal vessels
Trachomatous scarring	TS The presence of scarring in the tarsal conjunctiva
Trachomatous trichiasis	TT At least one lash rubs on the eyeball
Corneal opacity	CO Easily visible corneal opacity over the pupil

increase with age, reflecting the cumulative nature of the damage. Where the prevalence of active disease is very high, cicatricial complications may be seen at an early age; trichiasis was reported in 2–3% of children under the age of 15 years in southern Sudan where the prevalence of active disease was 70–80% (Ngondi *et al.* 2006a; King *et al.* 2008).

Cohort studies in trachoma-endemic communities in The Gambia and Tanzania have looked at the progression of the scarring process:

- Worsening of conjunctival scarring was seen in nearly 50% of scarred subjects over 5 years (Tanzania) (Wolle *et al.* 2009).
- Progression from conjunctival scarring to trichiasis was seen in 10% after 7 years and 6% after 12 years (Tanzania and The Gambia) (Munoz *et al.* 1999; Bowman *et al.* 2001).
- Minor trichiasis (<5 lashes touching the eye) progressed to major trichiasis (five or more lashes touching the eye) in 33% after 1 year and in 37% after 4 years; and unilateral progressed to bilateral trichiasis in 46% after 1 year (The Gambia) (Bowman *et al.* 2002b; Burton *et al.* 2006).
- Trichiasis is associated with the development of corneal scarring: 8% of people with trichiasis developed incident corneal scarring after 4 years, and there was worsening of established corneal scarring in 34% after 1 year (The Gambia) (Bowman *et al.* 2002b; Burton *et al.* 2006).

The first study from Tanzania had a standardised, prospective design but the others did not. There is

considerable variation in the reported rates of progression, which may reflect both variation in progression rates in different populations and methodology. A key determinant of the rate of disease progression is probably the burden of *C. trachomatis* infection in a community over time, although the direct evidence for this is limited. Several studies found that the risk of developing scarring complications is greater in those with recurrent or persistent severe inflammatory trachoma (Dawson *et al.* 1990; Munoz *et al.* 1999; West *et al.* 2001; Burton *et al.* 2006).

Infection vs. disease

There is little doubt that *C. trachomatis* is the cause of trachoma; Koch's postulates were largely fulfilled shortly after the first isolation of *C. trachomatis* in 1957 (Tang *et al.* 1957; Collier *et al.* 1958). However, *C. trachomatis* cannot be detected in all cases of active disease, even using highly sensitive nucleic acid amplification tests (NAAT) (Baral *et al.* 1999; Lietman *et al.* 2000; Burton *et al.* 2003; Miller *et al.* 2004b). In low prevalence communities, especially those that have received mass antibiotic treatment, *C. trachomatis* is only found in a minority of those with active disease. Those with intense trachomatous inflammation are more likely to be infected and have higher bacterial loads than those with follicular disease (Burton *et al.* 2003; Solomon *et al.* 2004b; Wright & Taylor 2005). In endemic communities infection is sometimes detected in those who do not fulfil the WHO criteria for active disease. Part of the explanation for this poor correlation is likely to be the kinetics of the disease with a short latent phase (infection before clinical signs with the incubation period for disease), a patent phase (infection and clinical signs) and a recovery phase (infection cleared but clinical signs persist, which can last for many months) (Bailey *et al.* 1994; Wright *et al.* 2008). The mismatch between the presence of infection and clinical findings is also partly explained by use of the simplified WHO grading system, which excludes those with fewer than five follicles in the subtarsal conjunctiva (Ward *et al.* 1990).

Transmission of *Chlamydia trachomatis* infection

Chlamydia trachomatis is probably transmitted between individuals by a variety of mechanisms, including:

- Direct spread from eye to eye during close contact such as during play or sleep.
- Spread of infected ocular or nasal secretions on fingers.
- Indirect spread by fomites such as infected facecloths.

V. H. Hu *et al.* **Epidemiology and control of trachoma**

- Transmission by eye-seeking flies.
- Possible spread from nasopharyngeal infection by aerosol.

A combination of these and other transmission mechanisms probably operates in most environments, although their relative importance may vary. For example, in some environments eye-seeking flies probably contribute to the transmission of infection. *Chlamydia trachomatis* has been detected by polymerase chain reaction in around 20% of *Musca sorbens* caught on the faces of children in Ethiopia (Jones 1975; Miller *et al.* 2004a; Lee *et al.* 2007) and intervention trials to reduce fly density have been associated with a reduction in active trachoma in The Gambia (Emerson *et al.* 1999, 2004). However, in other locations, the density of eye-seeking flies is insignificant and does not appear to contribute towards transmission (Taylor *et al.* 1985). Genital strains of *C. trachomatis* do not cause endemic trachoma, although occasionally they cause a self-limiting conjunctivitis (Brunham *et al.* 1990).

Trachoma is a focal disease and has been found to cluster at the level of the community, the household and within bedrooms, reflecting the infectious nature of the disease and suggesting that prolonged intimate contact is necessary for the transmission of infection (Dawson *et al.* 1976; Katz *et al.* 1988; Bailey *et al.* 1989; West *et al.* 1991b; Burton *et al.* 2003). This is particularly important for trachoma control programmes, as it significantly increases the sample size necessary for estimating the prevalence within a region (Katz *et al.* 1988). Most transmission events occur within the household, and a failure to treat all infected household members during mass antibiotic distribution may result in rapid re-infection of that family followed by more gradual spread across the community (Blake *et al.* 2009).

No non-human reservoir of infection has been found, with flies only acting as passive vectors. The importance of extra-ocular sites of infection has been debated. *Chlamydia trachomatis* can be detected in secretions from the nasopharynx, and a recent study also showed that infected nasal discharge in children at baseline was associated with an increased risk of active disease and conjunctival infection 2 months after systemic treatment (Malaty *et al.* 1981; West *et al.* 1993; Gower *et al.* 2006). However, nasal swabs were taken only from children with visible discharge and were of the discharge rather than from nasal epithelium. Positive results may simply have been a reflection of severe ocular infection which was not cleared with one dose of antibiotic, with infected secretions passing through the nasolacrimal ducts. An earlier study using nasal swabs on all children showed that new ocular infection after treatment was not related to a positive or

negative nasal specimen at baseline (West *et al.* 1993). In addition, genotyping of conjunctival and nasal samples from individuals with concurrent infection showed different genotypes to be present, suggesting that auto-infection was not an important factor (Andreasen *et al.* 2008).

Prevalence and geographical distribution

Trachoma is a major cause of blindness in many less-developed countries, especially in poor, rural areas. Blinding trachoma is believed to be endemic in over 50 countries, with the highest prevalence of active disease and trichiasis in Africa, predominantly in the savannah areas of East and Central Africa and the Sahel of West Africa (Figure 2). It is also endemic in a number of countries in the Middle East, Asia, Latin America and the Western Pacific (Polack *et al.* 2005). Current WHO estimates for the prevalence of active disease, trichiasis and blindness are significantly lower than previous ones and declines in the prevalence have been noted in several countries, but there is considerable uncertainty around these estimates, as little recent information is available from India and China.

About half of the global burden of active trachoma is concentrated in five countries: Ethiopia, India, Nigeria, Sudan and Guinea; while half of the global burden of trichiasis is concentrated in three countries: China, Ethiopia and Sudan (Mariotti *et al.* 2009). Recent studies from southern Sudan, previously inaccessible during the civil war, have shown very high levels of trachoma: up to 80% of children had active disease and one-fifth of adults had trichiasis (Ngondi *et al.* 2006a; King *et al.* 2008). Trachoma was shown to account for 35% of blindness, with 5% of the entire population (including children) suffering from low vision or blindness associated with trachoma (Ngondi *et al.* 2006b, 2007).

Some caution is required in the interpretation of global estimates of trachoma prevalence (Burton & Mabey 2009). These have generally been produced with models that have relied on the results of a limited number of surveys conducted in a few endemic countries. Various assumptions and extrapolations are then made, which have considerable potential for error, such as extrapolating data from a single survey within a district to give the district-level prevalence, and national averages being generated from available district prevalence data. The six million people estimated by the WHO to be blind from trachoma in the 1990s was probably a substantial overestimate as results were based on questionnaires reporting numbers of people who might become blind without treatment (Thylefors *et al.* 1995). More recent estimates have used more reliable survey data.

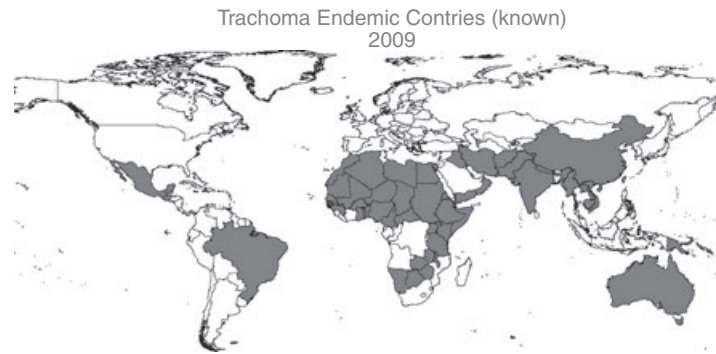


Figure 2 Map of trachoma endemic countries in 2009. Reproduced with permission from Dr Silvio P. Mariotti, WHO/NMH/.

Notwithstanding the aforementioned limitations of the available data, there does appear to be a downward trend in the number of people affected by trachoma. Improved living standards in many countries probably account for at least part of this trend, as was the case with the disappearance of trachoma from industrialised countries a century ago (Dolin *et al.* 1997; Hoechsmann *et al.* 2001). The establishment of trachoma control programmes has probably played a major role, although this is difficult to quantify. Worryingly, the number of people estimated to have trichiasis has shown little decline since 1991, with a slight increase estimated between 2003 and 2008. This suggests that progressive conjunctival scarring can occur even when there has been a marked reduction in active disease and *C. trachomatis* infection, which has long-term implications for control programmes.

The most recent estimate from the WHO places the burden of trachoma at 1.3 million disability-adjusted life years. This measures the gap between a normal, healthy population and the 'cost' of a disease from premature mortality and disability (WHO 2008). The economic cost of trachoma has been estimated at between US\$ 3 billion – 8 billion in lost productivity (Frick *et al.* 2003a,b). Estimates of the global burden of trachoma, however, are faced with several problems including a lack of robust prevalence data and the decision over inclusion of different disease manifestations (Burton & Mabey 2009). Trichiasis without visual impairment, for example, causes a level of disability comparable to that caused by visual impairment from non-trachomatous causes, yet it has not always been included in disease burden calculations (Frick *et al.* 2001b).

Risk factors for trachoma

Many studies have examined potential risk factors for trachoma, which have been previously reviewed (Emerson

et al. 2000; West 2004; Haylor 2008). Studies examining the relationship between trachoma and various environmental, socio-economic and behavioural factors are difficult to interpret as they often lack adequate controls and are potentially confounded with many factors being closely interrelated. For example, establishing what contribution a dirty face makes to trachoma, or vice versa, is difficult, as active disease may cause ocular/nasal discharge, but discharge may be an important route for transmission. In addition, variability in survey methodology and questionnaires may not allow reliable comparisons between studies (Emerson *et al.* 2000).

Trachoma is currently more common in dry areas, and the relationship between water and trachoma has been studied in several settings, with some conflicting results. It is plausible that better access to water would improve hygiene levels and reduce the transmission of infection. Several studies have indeed found an association between increased distance to water and the prevalence of active disease (Mathur & Sharma 1970; Tielsch *et al.* 1988; Taylor *et al.* 1989; West *et al.* 1989; Schemann *et al.* 2002). However, other studies have not supported this and the association appears to be absent when the distance to water is small (West *et al.* 1991b; Zerihun 1997; Kuper *et al.* 2003). This may be explained by the presence of a 'water use plateau' in which *per capita* water consumption between households often seems to be constant when the round trip to collect water is below a threshold of around 30 min (Cairncross & Feachem 1993). The quantity of water brought into a household may be more important than the distance to water. Indeed, one study found the quantity to be independent of distance and that children from households with a greater quantity of water had less active disease (Kupka *et al.* 1968). However, other studies have shown that after controlling for distance the total quantity of water used had no effect on the prevalence of disease (West *et al.* 1989; Bailey *et al.* 1991). The second

of these two studies may unlock the key issue with regard to water and trachoma: the authors actually measured how much water was brought into the house and also observed how the water was used. After controlling for family size, distance to water and other socio-economic factors, families with trachoma used less water for washing children than did control families without trachoma, regardless of the amount of water available for consumption (Bailey *et al.* 1991).

The association between frequent face washing and reduced trachoma has been reported in some, but not all, studies (Taylor *et al.* 1985; Tielsch *et al.* 1988; Bailey *et al.* 1991; Luna *et al.* 1992). Self-reporting may have compromised the results, as washing may be perceived as a desirable activity and hence over-reported. A large-scale randomised trial of an intensive educational intervention to encourage face washing in Tanzania showed that children with a clean face were less likely to have severe inflammatory trachoma (TI). However, there was no reduction in the overall prevalence of active trachoma and intensive behavioural intervention was required (West *et al.* 1991a, 1995; Schemann *et al.* 2002).

As discussed previously, flies are also a risk factor for trachoma by facilitating transmission. *M. sorbens*, the fly most commonly found in contact with eyes, preferentially breeds in human faeces. Latrine access is associated with a lower risk of trachoma. This has been attributed to the removal of faecal material from the environment leading to a smaller fly population (Emerson *et al.* 2004).

Crowding is probably a risk factor for trachoma, especially living in close proximity to children with active disease (Bailey *et al.* 1989; Sahlu & Larson 1992). Women tend to have a higher rate of the scarring complications of trachoma and this is generally considered to be a result of their increased contact with young children, the main reservoir of infection (Turner *et al.* 1993). Migration between communities may also be important in the re-introduction of *C. trachomatis* (Burton *et al.* 2005b).

Assessing the burden of trachoma

Trachoma as a public health problem is defined by the WHO as a prevalence of TF of at least 10% in children aged 1–9, or a prevalence of TT of at least 1% in those aged 15 or more. Trachoma is no longer considered a public health problem when the TF prevalence in children falls below 5% and the prevalence of TT is <0.1% (WHO, 1997; Kuper *et al.* 2003). No specific guidelines are provided for areas where the prevalence falls between these thresholds.

Population-based prevalence surveys (PBPS)

To determine where trachoma is a public health problem, WHO recommends cluster random sampling (Ngondi *et al.* 2009b). Districts likely to be trachoma-endemic are identified using information from previous surveys, written reports, hospital eye surgery records and interviewing people with local experience. A list of all clusters within the districts identified is made. Clusters are preferably areas of approximately the same population size, so that the cluster selection is with probability of selection proportional to size. A random sample of clusters is then selected, which is sufficiently large such that the sample prevalence of TF in 1–9 year olds, or TT in those aged 15 or more, reflects the prevalence in the whole population (WHO, 2006). A two-stage design can be employed, whereby villages (clusters) are selected in the first stage, and households are selected in the second. If household lists are not available, other methods for selecting households are by random walk and compact segment sampling. Reports should present standardisation of the examiners' grading, the sample size parameters, confidence intervals of the estimate, and adjustment for clustering (Ngondi *et al.* 2009b). As well as obtaining accurate estimates of TF and TT prevalence, surveys should collect data on the number of public access and surface water points in the district, and the proportion of households that have access to latrines and that are within 15 min walk of the nearest water source available during the dry season. These data allow planning, monitoring and evaluation of control interventions (WHO, 2006).

Population-based prevalence surveys provide comprehensive prevalence data and are rightly considered the 'gold standard' for trachoma surveys (Wright *et al.* 2005). Although they can be designed to provide precise prevalence estimates over wide areas, they generally do not give accurate estimates at the cluster level, and the sampling needs to incorporate large design effects (four or more) arising from the focal nature of active trachoma and use large numbers of clusters if they are not to overlook hyperendemic clusters of disease (WHO-ITI, 2004). Moreover, they are time consuming and expensive because of the large sample sizes needed. Two alternative methods have been proposed: trachoma rapid assessment (TRA) and acceptance sampling TRA (ASTRA).

Trachoma rapid assessment

Trachoma rapid assessment was designed to allow simple, fast and cost-effective assessment of active disease, trichiasis and environmental risk factors. Existing data are first used to identify areas that are likely to be

trachoma-endemic. The burden of trichiasis, active disease and associated risk factors is then assessed in these areas (Negrel & Mariotti 1999). At least three, but no more than seven, villages are selected per district, with priority given to those areas 'deemed most socio-economically disadvantaged' (Wright *et al.* 2005). In these communities, individuals with TT are identified, leading to a crude estimate of TT prevalence. Fifty children aged 1–9 from at least 15 households that 'appear to have the lowest socio-economic status' are then assessed for TF and/or TI. Finally, a survey is performed to determine household level trachoma risk factors.

Trachoma rapid assessment provides rankings rather than prevalence estimates, and the method of selection of areas, communities and households outlined previously will generally be subjective. This may lead to overestimated and/or inconsistent prevalence data, with the possible extrapolation of biased data to the whole village and district (Negrel *et al.* 2001; Myatt *et al.* 2003; Solomon *et al.* 2004b). Evaluations of TRA rankings in comparison to PBPS in Tanzania and China found comparable ranking of communities, but TRA performed worse in low prevalence settings (Paxton 2001; Liu *et al.* 2002). However, PBPS does not itself provide reliable estimates or rankings for individual clusters, so these comparisons are flawed (Ngondi *et al.* 2009b). In The Gambia, a study comparing two TRA surveys found that active disease prevalence estimates and rankings were inconsistent, indicating that it is not a reliable method (Limburg *et al.* 2001).

Acceptance sampling TRA (ASTRA)

Acceptance sampling TRA, based on the principle of sequential sampling methods, such as lot quality assurance sampling (LQAS), has been proposed as an alternative to TRA. A maximum sample size and an acceptable number of TF cases are set and sampling stops when one of these is met. Villages are classified as high prevalence if sampling is stopped because the set number of TF cases was exceeded, or as low prevalence where sampling is stopped because the maximum sample size was reached (Myatt *et al.* 2003). Thus, there is no fixed sample size. ASTRA was evaluated in Malawi (Myatt *et al.* 2003) and Vietnam (Myatt *et al.* 2005) and found to be more reliable than TRA for the prioritisation of communities with active disease.

The advantages of ASTRA are its speed and low cost as a result of smaller sample sizes than are required for PBPS. Sample sizes may, however, become large if the option of continuing sampling in a lot until the maximum sample size is met is taken, rather than stopping when the expected number of TF cases is met (Ngondi *et al.* 2009b). ASTRA may provide reliable TF prevalence estimates in individual

communities so long as the sample size is not too small and, if combined with Centric Systematic Area Sampling, may provide prevalence estimates over wide areas and basic mapping of TF prevalence (WHO-ITI, 2004). However, LQAS sampling works best when the distribution of cases is homogeneous (Anker *et al.* 1998), and when village populations do not vary too much. Because trachoma clusters both within communities and districts, an optimal rapid and affordable strategy to take clustering into account when choosing households and communities to sample is still a challenge. In the mean time, PBPS remain the only reliable source of prevalence data for trachoma, and have generally been used to prepare national control plans, and to forecast ultimate intervention goals for surgery and antibiotic treatment.

Clinical signs versus infection

An additional concern with all of these survey methods is their reliance on clinical signs as a measure of trachoma prevalence. As mentioned previously, clinical signs are sometimes poorly correlated with ocular *C. trachomatis* infection, especially in low prevalence communities and those that have received mass treatment. As three of the four components of the WHO endorsed SAFE strategy for the control of trachoma aim to interrupt transmission of the bacteria, logic dictates that control measures should be directed to areas with most infection. It has been suggested that NAAT testing should be used to assess the prevalence of ocular *C. trachomatis* infection in areas where the prevalence of TF is <10% or between 10% and 20% (Lansingh & Carter 2007). NAAT testing is not considered necessary in higher prevalence areas as the correlation between disease and infection is more reliable (Lansingh & Carter 2007). However, NAAT testing is beyond the budget of most trachoma control programmes, although cost savings can be made by pooling samples from low prevalence communities (Diamant *et al.* 2001). A simple point of care test for *C. trachomatis* showed promise when evaluated in trachoma-endemic communities in Tanzania (Michel *et al.* 2006) but it is not yet commercially available. Its sensitivity and specificity were lower when evaluated in subsequent, larger studies in The Gambia and Senegal (article in preparation).

Controlling trachoma: the SAFE strategy

Blindness from trachoma is essentially irreversible, but it can be prevented. The Alliance for the Global Elimination of Blinding Trachoma by the year 2020 (GET 2020) was established by the WHO in 1997 and recommends the SAFE strategy for trachoma control: Surgery for trichiasis;

Antibiotics to treat *C. trachomatis* infection; Facial cleanliness through personal hygiene; Environmental improvement with education and improved local economy.

Surgery for trichiasis

The aim of surgery for trichiasis is to reduce the progression to corneal opacity and blindness as a result of lashes abrading the cornea. Surgery has been shown to improve comfort, reduce ocular discharge and improve visual acuity in major trichiasis cases (Reacher *et al.* 1992; Bowman *et al.* 2000a; Burton *et al.* 2005a). While trichiasis surgery has not been directly shown to reduce the progression to corneal opacity (Bowman *et al.* 2001, 2002b), the consensus view is that there is some protective effect. The WHO recommends regular surgical sessions at fixed sites once a week, with periodic outreach stations held in trachoma-endemic communities, and should be offered to anyone with trichiasis, regardless of the number of in-turned eyelashes (WHO, 2006).

What type of surgery?

Several procedures are in routine use by trachoma control programmes. These generally involve a full thickness incision through the tarsal plate combined with several everting sutures to turn the distal part of the eyelid outwards (Yorston *et al.* 2006). In a randomised controlled trial, the bilamellar tarsal rotation (BLTR), which also includes incision of the skin, was found to give the best results of the procedures that were compared and therefore WHO recommends this method (Reacher *et al.* 1992, 1993). The main alternatives in regular use are variations of the posterior lamellar tarsal rotation (PLTR), including the Trabut procedure. In the only study comparing recurrence rates, no significant difference between BLTR or PLTR was found (Adamu & Alemayehu 2002).

What are the challenges for surgery?

One of the major problems is high post-surgery trichiasis recurrence rates, ranging from about 20% in the first 2 years (Reacher *et al.* 1992; Bog *et al.* 1993; Zhang *et al.* 2004a; Merbs *et al.* 2005; El Toukhy *et al.* 2006) to 60% after 3 years (Reacher *et al.* 1993; Bowman *et al.* 2000a). Several factors may contribute to recurrent trichiasis such as the type of procedure used, the surgeon's experience, the severity of pre-operative disease (severe scarring and entropion are associated with increased recurrence), suture type and infection status (Reacher *et al.* 1992; Alemayehu *et al.* 2004; Burton *et al.* 2005c; Merbs *et al.* 2005; El Toukhy *et al.* 2006). The presence of conjunctival

inflammation, which may reflect ongoing inflammatory-cicatricial responses, has been observed in patients with trichiasis and conjunctival scarring and may be important in the process of recurrent trichiasis. It is unclear what is driving this process as infection with *C. trachomatis* is relatively uncommon and has not been associated with recurrent trichiasis (Burton *et al.* 2005c; West *et al.* 2006c). Other bacteria (non-chlamydial) are commonly associated with trichiasis and so may contribute to inflammation in the late stages of the disease (Burton *et al.* 2005c). To explore whether controlling infection improved results, three randomised trials of post-operative azithromycin have been conducted. These have given different results. No effect was found in a low-prevalence Gambian setting (Burton *et al.* 2005c), reduced recurrence was observed in a high-prevalence Ethiopian settings (West *et al.* 2007a), and reduced recurrence was observed for major trichiasis, but increased recurrence for minor trichiasis, in a medium-prevalence area of Nepal (Zhang *et al.* 2006).

In many settings, the up-take of surgical services by patients has been relatively low. Patient barriers include cost, fear of surgery, transport difficulties, need for an escort, lack of awareness about the need for treatment or how to access care (Courtright 1994; West *et al.* 1994; Bowman *et al.* 2002a; Melese *et al.* 2004a; Habte *et al.* 2008). It has been shown that community-based surgery has greater attendance rates (66%) than health centre-based surgery (44%) (Bowman *et al.* 2000c). Surgery is therefore most successful when performed within the community by a trained nurse, with little or no cost to the patient (Mabey *et al.* 2003). Provider-level barriers include lack of training, auditing, availability of sterilised equipment and supplies and surgeons. To increase the number of surgeons, ophthalmic nurses can be successfully trained (Alemayehu *et al.* 2004). Case finding is of crucial importance and is facilitated by having individuals living in endemic communities trained to recognise trichiasis and refer cases (WHO, 2006).

Non-surgical alternatives

In many trachoma-endemic regions, epilation of the eyelashes is commonly practised with home-made equipment. For mild trichiasis with a few peripheral lashes in the absence of significant entropion, this may be a reasonable alternative to surgery; however, this has not yet been formally tested. In a cross-sectional analysis before surgery, epilation was associated with a reduced risk of corneal opacification in people with more severe entropion but made no difference for mild disease (West *et al.* 2006a). A retrospective study showed that epilation neither helped

nor hindered the progression process, although when combined with hot ash there was more corneal damage (Bowman *et al.* 2002b). Eyelid-taping has also been proposed as a non-surgical intervention, but this is generally a short-term measure prior to surgery (Yorston *et al.* 2006). Nevertheless, eyelid-taping alone is more effective than a single episode of epilation at keeping lashes off the eye at 3 months (Graz *et al.* 1999).

Antibiotics

The demonstration that a single oral dose of azithromycin was as effective as 6 weeks of daily tetracycline ointment in the treatment of active disease was a major advance (Bailey *et al.* 1993) and led directly to the launching of the global elimination initiative. Mass treatment of whole districts or communities is recommended, as this is more effective in preventing reinfection than the treatment of individual cases (Schachter *et al.* 1999). The WHO criteria for deciding whether or not to treat are shown in Table 2. A district is defined as a geographical area containing between 100 000 and 150 000 people.

Which antibiotic?

The WHO recommends two antibiotic treatment regimes: either 1% tetracycline eye ointment twice daily for 6 weeks or a single oral dose of azithromycin. Randomised controlled trials comparing these two treatments demonstrated that they are equally efficacious (Bailey *et al.* 1993; Tabbara *et al.* 1996; Dawson *et al.* 1997; Schachter *et al.* 1999) but that azithromycin is more effective in operational use (Bowman *et al.* 2000b). Tetracycline is almost universally available but suffers from poor compliance

because of the length of administration, being difficult and unpleasant to apply, and side-effects such as stinging and blurred vision (West 1999; Kuper *et al.* 2003). Azithromycin is well tolerated by both adults and children, has good compliance, and has fewer side-effects than tetracycline (Schachter *et al.* 1999; West 1999). It is also active against extra-ocular *C. trachomatis*. A recent cluster-randomised trial in Ethiopia showed that at 12 months, there was a 50% reduction in childhood mortality in communities where children had been treated with oral azithromycin compared to those where they had not (Porco *et al.* 2009). Pfizer has donated 135 million doses of azithromycin for use in control programmes, distributed by the ITI. The ITI is active in 18 trachoma-endemic countries. Azithromycin dosage is based on weight for children (20 mg/kg body weight), with adults receiving 1 g. As weighing scales need daily calibration, are cumbersome to carry, and the cooperation of young children can be hard to obtain, height as a surrogate for weight has been suggested and proved successful for dosing (Munoz *et al.* 2003).

Azithromycin for trachoma control is not currently recommended for children under 6 months or pregnant women, and therefore tetracycline ointment is the treatment of choice for these groups. However, azithromycin is recommended by the Centre for Disease Control in infants under 1 month for pertussis prophylaxis (Tiwari *et al.* 2005) and is also recommended for the treatment of genital chlamydial infection in pregnant women (Gray *et al.* 2001; Pitsouni *et al.* 2007). The treatment of infants is important as infants under 1 year have the highest bacterial load, as discussed previously.

While oral azithromycin would seem to be a safe option, a potential alternative is azithromycin eye drops. A clinical trial of short duration azithromycin eye drops found that at 2 months, the cure rate and safety of topical 1.5% azithromycin was non-inferior to oral azithromycin (Cochereau *et al.* 2007), and mass treatment with the eye drops of a district in Cameroon saw the prevalence of active disease fall from 31.5% before treatment to 6.3% 1 year after treatment (Huguet *et al.* 2010).

As with any antibiotic, there are concerns that widespread use might lead to drug resistance. Azithromycin resistance has not yet been observed in *C. trachomatis* (Solomon *et al.* 2005; Hong *et al.* 2009), but resistance in other bacteria, such as *Streptococcus pneumoniae*, has been documented, especially after multiple rounds of mass treatment (Leach *et al.* 1997; Chern *et al.* 1999; Gaynor *et al.* 2005) although this disappeared within 12 months of treatment (Fry *et al.* 2002; Gaynor *et al.* 2003a). The clinical relevance of this resistance has yet to be determined. It has been argued that in communities where

Table 2 WHO criteria for mass antibiotic treatment distribution (WHO-ITI 2004)

Prevalence of TF in children 1–9 years	Recommendation
District level	
≥10%	Mass treat whole district annually for 3 years, then re-assess the prevalence in the district
<10%	Do community-level assessment
Community level	
≥10%	Mass treat whole community annually for 3 years, then re-assess the prevalence in the community
≥5% but <10%	Target treatment to affected children and the household they live in
<5%	Antibiotic treatment not recommended

V. H. Hu *et al.* **Epidemiology and control of trachoma**

macrolide resistance is rare, mass treatment with azithromycin is unlikely to increase the prevalence of resistant *S. pneumoniae* (Batt *et al.* 2003). Nasopharyngeal *S. pneumoniae* resistance to topical tetracycline has also been detected (Gaynor *et al.* 2005). The risk of drug resistance highlights the need for sensitive diagnostic tests, where treatment can be targeted to limit the over-use of antibiotics within the mass treatment policy (Mabey *et al.* 2003).

To whom should treatment be given?

The optimal strategy of mass antibiotic treatment is subject to some debate and probably varies depending on the prevalence. Alternative treatment target groups have been proposed:

- All children under 10 years old, because children are the main reservoir of infection (Holm *et al.* 2001; Solomon *et al.* 2003, 2004a). Frequent mass treatment of all children under 11 years has shown herd protection in the entire community in high-prevalence settings (House *et al.* 2009).
- All people living in a household containing an individual with active disease (Holm *et al.* 2001; Burton *et al.* 2003; Blake *et al.* 2009).
- All people living in a community (e.g. village), where the prevalence of active disease rises above a specific threshold (Burton *et al.* 2003).
- Children with active disease and other children residing with the TF/TI child more than 50% of the time (Laming *et al.* 2000).
- All TI individuals, as they have the highest number of chlamydial DNA copies per swab (Solomon *et al.* 2003).
- Only infected individuals, as this would remove the source of infection from the community, but this requires the means to detect infection in the field (Lietman *et al.* 1999).

In a study from a low-prevalence setting in The Gambia in which the residents of 14 villages were examined and tested for *C. trachomatis* infection, the theoretical effectiveness of several strategies in delivering antibiotic to infected individuals was compared (Burton *et al.* 2003). If only the individuals with active trachoma were treated, then only 24% of infected people would receive antibiotic. If treatment was targeted to all the residents of a household where at least one case of active trachoma was found, then 96% of infections would be treated. However, the number of people needed to be treated for each infection case was 9.6. Finally, if all villages with more than 15% active disease in children were treated, then

90% of infections would have been treated and the number needed to treat was 5.4. Thus, for a low-to-medium prevalence setting, community level treatment, determined by the prevalence of active disease in the children, appears to be a relatively efficient approach.

In a high-prevalence village in Tanzania, it was estimated that if only children under 10 years were treated, only 69% of those with high loads would be treated. If all members of households with children aged <10 years were treated, 90% of the entire population would be treated because most people live in households with children. Treating only those with clinical signs would miss 23% of those with high loads. The authors concluded that it is therefore more practical and effective to treat the entire community, so long as coverage is high enough (West *et al.* 2005a).

Mass treatment is considered the most cost-effective strategy, especially in high-prevalence areas (Frick *et al.* 2001a; Holm *et al.* 2001). Targeted treatment strategies require all children to be examined, which can be expensive and time consuming. In addition, re-infection is more likely to occur, as those treated may be re-infected by untreated individuals (West *et al.* 1993). Mass treatment has the advantage that all infected individuals are captured (Schachter *et al.* 1999; Solomon *et al.* 2004a; West *et al.* 2005a). This is important, as clinical signs are not reliable as a basis for targeted treatment (Baral *et al.* 1999), asymptomatic individuals act as a reservoir of infection (Burton *et al.* 2003; West *et al.* 2005a) and adults can also act as an important reservoir of high load infection (West *et al.* 2005a).

What treatment coverage should be achieved?

WHO recommends that treatment coverage should be between 80% and 90% (WHO, 2004). Mathematical modelling assuming 80% treatment coverage and 3 years of annual treatment demonstrated elimination of infection in 95% of communities (Ray *et al.* 2009). In contrast, data from Tanzania demonstrated that despite overall treatment coverage of 86%, ocular *C. trachomatis* infection remained in the community for up to 18 months after treatment, albeit at a low level (Burton *et al.* 2005b). Much of the near elimination of ocular *C. trachomatis* infection at 2 years after a single round of azithromycin mass treatment in a Tanzanian community has been attributed to the 97.8% treatment coverage (Solomon *et al.* 2004a). However, treatment coverage is not the sole key to success. In a low-prevalence setting in The Gambia, significant re-infection in two villages post-treatment was observed, despite treatment coverage being 86% and 92%. This was attributed to a mass migration event where virtually the entire population of these two communities attended a

religious festival in Senegal shortly after being treated (Burton *et al.* 2005b). In one Ethiopian study, an overall treatment coverage of 91.9% was achieved, but was followed by a 12.3% exponential rate of return of infection (Melese *et al.* 2004b). Also in Ethiopia, it was demonstrated that although treatment coverage was important in determining the prevalence of ocular *C. trachomatis* infection at 2 months post-treatment, coverage was no longer a predictor of infection at 6 months (Lakew *et al.* 2009a).

Factors found to affect the acceptability of azithromycin are local prevention norms (for example, believing that injections are better than oral medicine), perceptions of the distribution team's expertise, witnessing adverse effects in others, and the timing, quality and quantity of information provided. Therefore, to maximise coverage, it is important to understand the community's perceptions, conduct a pre-distribution assessment and community education, provide advance notice of the distribution, build a good relationship with the community, create and follow standardised distribution guidelines, and improve distributor training (Desmond *et al.* 2005).

How often should mass treatment be given?

It has been argued that a single round of mass treatment, with high coverage, may reduce the prevalence of infection to below a threshold at which it cannot persist, and from which it cannot return. This is known as the Allee effect (Chidambaram *et al.* 2005). Alternatively, mass treatment may eliminate some strains of *C. trachomatis* from the community, reducing the antigenic diversity which may enable the bacteria to evade the human immune system, and this less diverse population may never re-attain a high prevalence (Zhang *et al.* 2004b; Burton *et al.* 2005b; Chidambaram *et al.* 2006; Andreasen *et al.* 2008). Factors affecting the success of a single round of mass treatment are the baseline prevalence, treatment coverage, treatment efficacy in the individual, whether 'F' and 'E' component measures are in place, and the amount of in- and out-migration (Lietman *et al.* 1999; Gaynor *et al.* 2003b; Burton *et al.* 2005b; Chidambaram *et al.* 2006).

A single round of mass azithromycin treatment was successful in reducing the prevalence of ocular *C. trachomatis* infection from 9.5% at baseline to 0.1% at 2 years in a Tanzanian community (Solomon *et al.* 2004a). After a second round of mass treatment at 2 years, infection was eliminated by 5 years post-baseline (Solomon *et al.* 2008). This demonstrates that antibiotic treatment alone can result in elimination, as no 'F' or 'E' interventions were introduced. However, the baseline treatment coverage of 97.8% far exceeds that which would normally be achieved under operational conditions. The decline in trachoma

prevalence may not have been a result solely of the mass azithromycin treatment as tetracycline eye ointment was distributed at the 6, 12 and 18 month follow-ups to individuals with active disease. However, 15–100% of the community ocular *C. trachomatis* load at each of the final three follow-ups was found in participants who had received tetracycline in the previous follow-up, indicating tetracycline treatment did not play a major role in the observed prevalence decline. Alternatively, random fluctuation, seasonal effects, secular trend and regression to the mean may have contributed to the outcome. In contrast, two rounds of mass azithromycin treatment (at baseline and 18 months) in a different Tanzanian village did not eliminate active disease or *C. trachomatis* infection 5 years post-baseline (West *et al.* 2007b). In fact, although the infection rate declined between baseline and 18 months, the prevalence of infection was higher at the 5-year follow-up than at 18 months in all age groups.

Several studies have reported moderate success of one round of antibiotic treatment, with infection initially falling immediately post-treatment, but increasing (albeit to a lower prevalence than at baseline) within 12 months of treatment. In Egypt, The Gambia and Tanzania, it was observed that the prevalence of infection at 1 year after mass treatment was substantially lower than at baseline, but was higher than the prevalence at the 3-month follow-up (Schachter *et al.* 1999). Similar results of an initial reduction in infection with re-emergence approximately 1 year after treatment, but which does not return to pre-treatment levels by 2 years, have been reported by others in high-prevalence settings (Melese *et al.* 2004b; West *et al.* 2005b; Chidambaram *et al.* 2006; Lakew *et al.* 2009b). A study of 14 Gambian villages demonstrated that in low or medium prevalence areas, a single round of mass azithromycin treatment could lead to long-term control of infection, but that monitoring is required because of re-infection (Burton *et al.* 2003, 2005b). To help overcome the risk of re-infection from migration, it has been recommended that broader geographical areas should be treated, and people who have immigrated into the village should be treated after the initial mass treatment (Schachter *et al.* 1999; Burton *et al.* 2005b).

The aforementioned studies demonstrate that the effect of a single round of mass azithromycin treatment is heterogeneous, with some communities experiencing elimination of infection whereas others observe rapid re-emergence. In fact, more frequent treatment distributions could be beneficial in high-prevalence settings. Mathematical modelling has shown that where the prevalence of active disease is >50% in children, bi-annual treatment could eliminate disease (Lietman *et al.* 1999). Where disease prevalence is <35%, treatment annually or

every 2 years would suffice. Mathematical simulations for elimination of infection in Ethiopia suggest that 5 years of biannual treatment would lead to elimination in 95% of all villages (Ray *et al.* 2007). Data from Ethiopia demonstrated that the prevalence of infection at 24 months was significantly lower in villages treated biannually than in villages treated annually (Melese *et al.* 2008).

As a result of the re-emergence of infection in these studies, there is empirical evidence to support the need for repeated antibiotic treatment. Mathematical modelling has suggested that treatment could be stopped once the prevalence of infection has fallen below 5% (Ray *et al.* 2009). Socio-economic improvements may then allow the disease to be permanently eliminated without the need for further treatment. This is the rationale adopted by the WHO in their advocacy of the SAFE strategy. However, if the 'F' and 'E' components of the SAFE strategy do not have a strong enough effect, the prevalence of infection may return to pre-intervention level (Gaynor *et al.* 2002).

Facial cleanliness

Improving facial cleanliness (the absence of ocular and nasal discharge) (Negrel & Mariotti 1999) aims to reduce auto-transmission and transmission to others by removing a potential source of infection (Kuper *et al.* 2003). It is promoted through health education and improved water supply, but the evidence-base for this control strategy is limited. As discussed previously, gaining information on face washing is difficult, as the validity of self-reporting is questionable, measures of a clean face are subjective and certain indicators (discharge and flies) are more reliable than others (dust and food on the face) (Harding-Esch *et al.* 2008; Zack *et al.* 2008). Observational data indicate there is an association between having a clean face and not having trachoma but, as already mentioned, this does not establish a causal relationship.

A cross-sectional study in Mexico reported that the frequency of face washing (>7 times a week) was negatively correlated with the likelihood of children having active disease (Taylor *et al.* 1985). Peach *et al.* conducted a randomised trial comparing four groups: a control group (no intervention), eye washing only, tetracycline eye ointment only and tetracycline combined with eye washing. At 3 months, there was no significant benefit to eye washing, either alone or in combination with treatment (Peach *et al.* 1987). In Tanzania, an educational intervention to keep children's faces clean was implemented, and the number of clean pre-school children's faces was recorded. There was an increase in the percentage of clean faces from 9% at baseline to 33% at 1 year (Lynch *et al.* 1994). Subsequently, the only randomised controlled trial

of face washing compared mass tetracycline treatment with mass tetracycline treatment combined with a face-washing programme (West *et al.* 1995). Screening was performed at baseline, 6 and 12 months post-baseline. Children who received both the face-washing programme and treatment were more likely to have sustained clean faces than those who only received treatment, although the difference was not significant (OR 1.61, 95% CI 0.94–2.74). However, 65% of children in the intervention group still had a dirty face at two or more follow-ups. The risk of having severe trachoma (defined as the presence of ≥ 15 follicles or the presence of inflammation that obscured all tarsal plate vessels) in the face-washing group after 1 year was significantly lower than the treatment-only group (OR 0.62, 0.40–0.94), as mentioned previously. However, there was no difference in the overall prevalence of active disease between the two arms. The programme was labour intensive and expensive.

Environmental improvement

The 'E' component of the SAFE strategy aims to reduce transmission of *C. trachomatis* by promoting better personal and environmental hygiene. The elimination of trachoma from Europe and North America in the 19th century in the absence of any specific intervention, demonstrates the importance of environmental improvement components of the SAFE strategy (Mabey *et al.* 2003). Through increasing water supply and quality, improving access to latrines, decreasing fly density, reduced crowding and providing health education, transmission of trachoma should be interrupted (Kuper *et al.* 2003).

Resnikoff *et al.* compared health education alone, mass tetracycline treatment alone, health education combined with tetracycline treatment, and a control group (no intervention), assigning only one village to each arm (Resnikoff *et al.* 1995). They found that at 6 months, the incidence of active disease was lower in the health education only group compared with the control group. However, there was no value in the addition of health education to mass treatment, with mass treatment alone producing the best results in terms of cure rate and lower incidence.

There was little evidence for the fly control component of the SAFE strategy until Emerson *et al.* demonstrated that insecticide spraying in The Gambia led to an overall and significant 61% lower community prevalence of active disease, a reduction of 75% in the *M. sorbens* fly population, and a 96% reduction in fly-eye contacts in the intervention villages at 3 months (Emerson *et al.* 1999). However, the study only compared two pairs of villages and was open to bias. In 2004, Emerson *et al.* compared seven clusters that received spraying with seven that did

not. Insecticide spraying led to an 88% decrease in fly-eye contacts and a significant 55.8% reduction in the prevalence of active disease in the intervention clusters (Emerson *et al.* 2004). West *et al.* randomised 16 Tanzanian communities to receive a single round of mass azithromycin treatment (control group) or to receive azithromycin and frequent rounds of insecticide spraying (intervention group) (West *et al.* 2006b). In contrast to the previous studies, they found no difference in the prevalence of active disease at either 6 or 12 months post-baseline, or of *C. trachomatis* infection at 6 months, between intervention and control communities, despite the mean prevalence of flies being significantly lower in the intervention group. Furthermore, spraying is labour intensive, expensive and not sustainable (Rabiou *et al.* 2007).

Only one randomised controlled trial examining latrine use exists. Emerson *et al.* compared seven clusters that received latrines, with seven that did not (Emerson *et al.* 2004). Latrine provision resulted in a 30% decrease in *M. sorbens*-eye contacts, and an associated 29.5% reduction in trachoma prevalence, which did not reach statistical significance, despite latrine use reported to be 98%. Latrines will only improve environmental sanitation if they are used consistently by a large proportion of the community. Therefore, latrine provision should be in accordance with what already exists and what is acceptable in the community (WHO, 2006).

The SAFE Strategy: putting the pieces together

Although the individual components of the SAFE strategy have demonstrated success in controlling trachoma, it is through the implementation of all four elements together that this control strategy is expected to have most success. Some studies have evaluated the combined effect of multiple components of the SAFE strategy. A cross-sectional analysis of implementation of the A, F and E components in Ethiopia demonstrated that receiving three rounds of azithromycin treatment, having a clean face, and increased face-washing frequency, were independently associated with a reduced prevalence of active disease in children (Ngondi *et al.* 2008). Thus, implementation of the different SAFE components would have an additive effect in trachoma control.

Implementation of the entire SAFE strategy in five Ethiopian districts showed that uptake of all components was high by the 3-year evaluation time-point (Ngondi *et al.* 2009a). The declines in TF, TI and unclean face prevalence in children aged 1–9 were statistically significant, and the prevalence of TT significantly decreased in three of the districts. The overall prevalence of ocular *C. trachomatis* infection at 3 years was 3.1%, but was higher in districts

last treated over a year ago (4.3%) and lower in those treated recently (1.4%), suggesting on-going transmission. In Zambia, introduction of SAFE measures led to a reduction in the prevalence of total trachoma in children under 10 years from 55% at baseline to 10.6% at 2 years. The prevalence of TF fell from 24.9% to 4.5% in children, and the prevalence of TT in adults fell from 0.6% to 0.3% (Astle *et al.* 2006). However, in the absence of control groups, secular trend cannot be excluded as an explanation. In addition, without investigating these interventions through a randomised controlled trial, the relative impact of each component cannot be elucidated.

In Sudan, a control area was included with which to compare four areas in which the SAFE strategy had been implemented. The evaluation at 3 years showed heterogeneous uptake of interventions and results. All four intervention areas experienced declines in the prevalence of TF, TI and unclean faces. This was substantial in two of the areas, moderate in one, and non-significant in one, compared with the control. The decline in active disease was most likely attributable to antibiotic treatment and improved facial cleanliness was a result of hygiene health education combined with water provision, as the greatest trachoma declines were achieved where uptake of these activities was highest (Ngondi *et al.* 2006c). In Ethiopia, Cumberland *et al.* conducted a trial where 40 communities were randomised to either health promotion by national radio only (control); mass azithromycin treatment and radio; mass treatment, radio and information, education and communication (IEC) materials; or mass treatment, radio, IEC and community video and drama shows (Cumberland *et al.* 2008). The exact allocation schedule was unable to be followed, but the 3 year evaluation demonstrated a significantly reduced risk of active disease in communities given antibiotics combined with IEC (OR 0.35, 95% CI 0.13–0.89), and in communities additionally receiving video health messages (OR 0.31, 0.11–0.89). Similarly, the risk of having ocular *C. trachomatis* infection was significantly lower in these two intervention groups. Although antibiotic treatment was identified as being the most active component for all outcomes, the addition of health education was beneficial.

Conclusion

Blinding trachoma disappeared from Western Europe and North America at the beginning of the 20th century, yet it continues to cause an enormous burden of disease in poor rural communities in the developing world. There have been encouraging reductions in the prevalence of active disease in many countries in the past 20 years. However, a large backlog of unoperated trichiasis cases which remains

V. H. Hu *et al.* **Epidemiology and control of trachoma**

in many countries will have to be addressed by national eye care programmes if blinding trachoma is to be eliminated by 2020.

Acknowledgements

Robin Bailey and David Mabey are members of the EpiGen Chlamydia Consortium.

References

- Adamu Y & Alemayehu W (2002) A randomized clinical trial of the success rates of bilamellar tarsal rotation and tarsotomy for upper eyelid trichomatous trichiasis. *Ethiopian Medical Journal* **40**, 107–114.
- Alemayehu W, Melese M, Bejiga A, Worku A, Kebede W & Fantaye D (2004) Surgery for trichiasis by ophthalmologists versus integrated eye care workers: a randomized trial. *Ophthalmology* **111**, 578–584.
- Al-Rifai KM (1988) Trachoma through history. *International Ophthalmology* **12**, 9–14.
- Andreasen AA, Burton MJ, Holland MJ *et al.* (2008) *Chlamydia trachomatis* ompA variants in trachoma: what do they tell us? *PLoS Neglected Tropical Diseases* **2**, e306.
- Anker M, Bessinger R, Holt E *et al.* (1998) *Report of a Technical Meeting on the Use of Lot Quality Assurance Sampling (LQAS) in Polio Eradication Programs* Chapel-Hill, NC, USA.
- Astle WF, Wiafe B, Ingram AD, Mwanga M & Glassco CB (2006) Trachoma control in Southern Zambia—an international team project employing the SAFE strategy. *Ophthalmic Epidemiology* **13**, 227–236.
- Bailey R, Osmond C, Mabey DC, Whittle HC & Ward ME (1989) Analysis of the household distribution of trachoma in a Gambian village using a Monte Carlo simulation procedure. *International Journal of Epidemiology* **18**, 944–951.
- Bailey R, Downes B, Downes R & Mabey D (1991) Trachoma and water use; a case control study in a Gambian village. *Transactions of the Royal Society of Tropical Medicine & Hygiene* **85**, 824–828.
- Bailey RL, Arullendran P, Whittle HC & Mabey DC (1993) Randomised controlled trial of single-dose azithromycin in treatment of trachoma. *Lancet* **342**, 453–456.
- Bailey RL, Hampton TJ, Hayes LJ, Ward ME, Whittle HC & Mabey DC (1994) Polymerase chain reaction for the detection of ocular chlamydial infection in trachoma-endemic communities. *The Journal of Infectious Diseases* **170**, 709–712.
- Bailey R, Duong T, Carpenter R, Whittle H & Mabey D (1999) The duration of human ocular *Chlamydia trachomatis* infection is age dependent. *Epidemiology and Infection* **123**, 479–486.
- Baral K, Osaki S, Shrestha B *et al.* (1999) Reliability of clinical diagnosis in identifying infectious trachoma in a low-prevalence area of Nepal. *Bulletin of the World Health Organization* **77**, 461–466.
- Batt SL, Charalambous BM, Solomon AW *et al.* (2003) Impact of azithromycin administration for trachoma control on the carriage of antibiotic-resistant *Streptococcus pneumoniae*. *Antimicrobial Agents & Chemotherapy* **47**, 2765–2769.
- Blake IM, Burton MJ, Bailey RL *et al.* (2009) Estimating household and community transmission of ocular *chlamydia trachomatis*. *PLoS Neglected Tropical Diseases* **3**, e401.
- Bog H, Yorston D & Foster A (1993) Results of community-based eyelid surgery for trichiasis due to trachoma. *The British Journal of Ophthalmology* **77**, 81–83.
- Bowman RJ, Jatta B, Faal H, Bailey R, Foster A & Johnson GJ (2000a) Long-term follow-up of lid surgery for trichiasis in the Gambia: surgical success and patient perceptions. *Eye (London, England)* **14**, 864–868.
- Bowman RJ, Sillah A, Van Dehn C *et al.* (2000b) Operational comparison of single-dose azithromycin and topical tetracycline for trachoma. *Investigative Ophthalmology & Visual Science* **41**, 4074–4079.
- Bowman RJ, Soma OS, Alexander N *et al.* (2000c) Should trichiasis surgery be offered in the village? A community randomised trial of village vs. health centre-based surgery. *Tropical Medicine & International Health* **5**, 528–533.
- Bowman RJ, Jatta B, Cham B *et al.* (2001) Natural history of trichomatous scarring in The Gambia: results of a 12-year longitudinal follow-up. *Ophthalmology* **108**, 2219–2224.
- Bowman RJ, Faal H, Jatta B *et al.* (2002a) Longitudinal study of trichomatous trichiasis in The Gambia: barriers to acceptance of surgery. *Investigative Ophthalmology and Visual Science* **43**, 936–940.
- Bowman RJ, Faal H, Myatt M *et al.* (2002b) Longitudinal study of trichomatous trichiasis in the Gambia. *The British Journal of Ophthalmology* **86**, 339–343.
- Brunham RC, Laga M, Simonsen JN *et al.* (1990) The prevalence of *Chlamydia trachomatis* infection among mothers of children with trachoma. *American Journal of Epidemiology* **132**, 946–952.
- Burton MJ & Mabey DC (2009) The global burden of trachoma: a review. *PLoS Neglected Tropical Diseases* **3**, e460.
- Burton MJ, Holland MJ, Faal N *et al.* (2003) Which members of a community need antibiotics to control trachoma? Conjunctival *Chlamydia trachomatis* infection load in Gambian villages. *Investigative Ophthalmology & Visual Science* **44**, 4215–4222.
- Burton MJ, Bowman RJ, Faal H *et al.* (2005a) Long term outcome of trichiasis surgery in the Gambia. *The British Journal of Ophthalmology* **89**, 575–579.
- Burton MJ, Holland MJ, Makalo P *et al.* (2005b) Re-emergence of *Chlamydia trachomatis* infection after mass antibiotic treatment of a trachoma-endemic Gambian community: a longitudinal study. *Lancet* **365**, 1321–1328.
- Burton MJ, Kinteh F, Jallow O *et al.* (2005c) A randomised controlled trial of azithromycin following surgery for trichomatous trichiasis in the Gambia. *The British Journal of Ophthalmology* **89**, 1282–1288.
- Burton MJ, Bowman RJ, Faal H *et al.* (2006) The long-term natural history of trichomatous trichiasis in the Gambia. *Investigative Ophthalmology & Visual Science* **47**, 847–852.

V. H. Hu *et al.* **Epidemiology and control of trachoma**

- Cairncross S & Feachem R (1993) *Environmental Health Engineering in the Tropics*. John Wiley & Sons, London.
- Chern KC, Shrestha SK, Cevallos V *et al.* (1999) Alterations in the conjunctival bacterial flora following a single dose of azithromycin in a trachoma endemic area. *The British Journal of Ophthalmology* **83**, 1332–1335.
- Chidambaram JD, Lee DC, Porco TC & Lietman TM (2005) Mass antibiotics for trachoma and the Allee effect. *The Lancet Infectious Diseases* **5**, 194–196.
- Chidambaram JD, Alemayehu W, Melese M *et al.* (2006) Effect of a single mass antibiotic distribution on the prevalence of infectious trachoma. *The Journal of the American Medical Association* **295**, 1142–1146.
- Cochereau I, Goldschmidt P, Goepogui A *et al.* (2007) Efficacy and safety of short duration azithromycin eye drops versus azithromycin single oral dose for the treatment of trachoma in children: a randomised, controlled, double-masked clinical trial. *The British Journal of Ophthalmology* **91**, 667–672.
- Collier LH, Duke-Elder S & Jones BR (1958) Experimental trachoma produced by cultured virus. *The British Journal of Ophthalmology* **42**, 705–720.
- Courtright P (1994) Acceptance of surgery for trichiasis among rural Malawian women. *East African Medical Journal* **71**, 803–804.
- Cumberland P, Edwards T, Hailu G *et al.* (2008) The impact of community level treatment and preventative interventions on trachoma prevalence in rural Ethiopia. *International Journal of Epidemiology* **37**, 549–558.
- Dawson CR, Daghfous T, Messadi M, Hoshiwara I & Schachter J (1976) Severe endemic trachoma in Tunisia. *The British Journal of Ophthalmology* **60**, 245–252.
- Dawson CM, Daghfous R, Juster R & Schachter J (1990) *What Clinical Signs are Critical in Evaluating the Impact of Intervention in Trachoma? Chlamydia Infections. Proceedings of the Seventh International Symposium on Human Chlamydial Infections* Cambridge University Press, London.
- Dawson CR, Schachter J, Sallam S, Sheta A, Rubinstein RA & Washton H (1997) A comparison of oral azithromycin with topical oxytetracycline/polymyxin for the treatment of trachoma in children. *Clinical Infectious Diseases: an official publication of the Infectious Diseases Society of America* **24**, 363–368.
- Desmond N, Solomon AW, Massae PA *et al.* (2005) Acceptability of azithromycin for the control of trachoma in Northern Tanzania. *Transactions of the Royal Society of Tropical Medicine & Hygiene* **99**, 656–663.
- Diamant J, Benis R, Schachter J *et al.* (2001) Pooling of Chlamydia laboratory tests to determine the prevalence of ocular *Chlamydia trachomatis* infection. *Ophthalmic Epidemiology* **8**, 109–117.
- Dolin PJ, Faal H, Johnson GJ *et al.* (1997) Reduction of trachoma in a sub-Saharan village in absence of a disease control programme. *Lancet* **349**, 1511–1512.
- Dolin PJ, Faal H, Johnson GJ, Ajewole J, Mohamed AA & Lee PS (1998) Trachoma in The Gambia. *The British Journal of Ophthalmology* **82**, 930–933.
- El Toukhy E, Lewallen S & Courtright P (2006) Routine bilamellar tarsal rotation surgery for trachomatous trichiasis: short-term outcome and factors associated with surgical failure. *Ophthalmic Plastic & Reconstructive Surgery* **22**, 109–112.
- Emerson PM, Lindsay SW, Walraven GE *et al.* (1999) Effect of fly control on trachoma and diarrhoea. *Lancet* **353**, 1401–1403.
- Emerson PM, Cairncross S, Bailey RL & Mabey DC (2000) Review of the evidence base for the ‘F’ and ‘E’ components of the SAFE strategy for trachoma control. *Tropical Medicine & International Health* **5**, 515–527.
- Emerson PM, Lindsay SW, Alexander N *et al.* (2004) Role of flies and provision of latrines in trachoma control: cluster-randomised controlled trial. *Lancet* **363**, 1093–1098.
- Frick KD, Lietman TM, Holm SO, Jha HC, Chaudhary JS & Bhatta RC (2001a) Cost-effectiveness of trachoma control measures: comparing targeted household treatment and mass treatment of children. *Bulletin of the World Health Organization* **79**, 201–207.
- Frick KD, Melia BM, Buhrmann RR & West SK (2001b) Trichiasis and disability in a trachoma-endemic area of Tanzania. *Archives of Ophthalmology* **119**, 1839–1844.
- Frick KD, Basilion EV, Hanson CL & Colchero MA (2003a) Estimating the burden and economic impact of trachomatous visual loss. *Ophthalmic Epidemiology* **10**, 121–132.
- Frick KD, Hanson CL & Jacobson GA (2003b) Global burden of trachoma and economics of the disease. *The American Journal of Tropical Medicine & Hygiene* **69**, 1–10.
- Fry AM, Jha HC, Lietman TM *et al.* (2002) Adverse and beneficial secondary effects of mass treatment with azithromycin to eliminate blindness due to trachoma in Nepal. *Clinical Infectious Diseases: an official publication of the Infectious Diseases Society of America* **35**, 395–402.
- Gaynor BD, Yi E & Lietman T (2002) Rationale for mass antibiotic distribution for trachoma elimination. *International Ophthalmology Clinics* **42**, 85–92.
- Gaynor BD, Holbrook KA, Whitcher JP *et al.* (2003a) Community treatment with azithromycin for trachoma is not associated with antibiotic resistance in *Streptococcus pneumoniae* at 1 year. *The British Journal of Ophthalmology* **87**, 147–148.
- Gaynor BD, Miao Y, Cevallos V *et al.* (2003b) Eliminating trachoma in areas with limited disease. *Emerging Infectious Diseases* **9**, 596–598.
- Gaynor BD, Chidambaram JD, Cevallos V *et al.* (2005) Topical ocular antibiotics induce bacterial resistance at extraocular sites. *The British Journal of Ophthalmology* **89**, 1097–1099.
- Gower EW, Solomon AW, Burton MJ *et al.* (2006) Chlamydial positivity of nasal discharge at baseline is associated with ocular chlamydial positivity 2 months following azithromycin treatment. *Investigative Ophthalmology & Visual Science* **47**, 4767–4771.
- Grassly NC, Ward ME, Ferris S, Mabey DC & Bailey RL (2008) The natural history of trachoma infection and disease in a gambian cohort with frequent follow-up. *PLoS Neglected Tropical Diseases* **2**, e341.
- Gray RH, Wabwire-Mangen F, Kigozi G *et al.* (2001) Randomized trial of presumptive sexually transmitted disease therapy

V. H. Hu *et al.* **Epidemiology and control of trachoma**

- during pregnancy in Rakai, Uganda. *American Journal of Obstetrics & Gynecology* 185, 1209–1217.
- Graz B, Xu JM, Yao ZS, Han SR & Kok A (1999) Trachoma: can trichiasis be treated with a sticking-plaster? A randomized clinical trial in China. *Tropical Medicine & International Health* 4, 222–228.
- Habte D, Gebre T, Zerihun M & Assefa Y (2008) Determinants of uptake of surgical treatment for trachomatous trichiasis in North Ethiopia. *Ophthalmic Epidemiology* 15, 328–333.
- Harding-Esch EM, Edwards T, Sillah A *et al.* (2008) Risk factors for active trachoma in The Gambia. *Transactions of the Royal Society of Tropical Medicine & Hygiene* 102, 1255–1262.
- Haylor HR (2008) *Trachoma: A Blinding Scourge from the Bronze Age to the Twenty-First Century*. Haddington Press, Melbourne.
- Hirschberg J (1982) *The History of Ophthalmology in Eleven Volumes. 1: Antiquity*. Wayenborg, Verlag.
- Hoechsmann A, Metcalfe N, Kanjaloti S *et al.* (2001) Reduction of trachoma in the absence of antibiotic treatment: evidence from a population-based survey in Malawi. *Ophthalmic Epidemiology* 8, 145–153.
- Holm SO, Jha HC, Bhatta RC *et al.* (2001) Comparison of two azithromycin distribution strategies for controlling trachoma in Nepal. *Bulletin of the World Health Organization* 79, 194–200.
- Hong KC, Schachter J, Moncada J, Zhou Z, House J & Lietman TM (2009) Lack of macrolide resistance in *Chlamydia trachomatis* after mass azithromycin distributions for trachoma. *Emerging Infectious Diseases* 15, 1088–1090.
- House JI, Ayele B, Porco TC *et al.* (2009) Assessment of herd protection against trachoma due to repeated mass antibiotic distributions: a cluster-randomised trial. *Lancet* 373, 1111–1118.
- Huguet P, Bella L, Einterz E, Goldschmidt P & Bensaïd P (2010) Trachoma mass treatment with azithromycin 1.5% eye drops in Cameroon: feasibility, tolerance and effectiveness. *The British Journal of Ophthalmology* 94, 157–160.
- Jones BR (1975) The prevention of blindness from trachoma. *Transactions of the Ophthalmological Societies of the United Kingdom* 95, 16–33.
- Katz J, Zeger SL & Tielsch JM (1988) Village and household clustering of xerophthalmia and trachoma. *International Journal of Epidemiology* 17, 865–869.
- King JD, Ngondi J, Gatpan G, Lopidia B, Becknell S & Emerson PM (2008) The burden of trachoma in ayod county of southern Sudan. *PLoS Neglected Tropical Diseases* 2, e299.
- Kuper H, Solomon AW, Buchan J, Zondervan M, Foster A & Mabey D (2003) A critical review of the SAFE strategy for the prevention of blinding trachoma. *Lancet Infectious Diseases* 3, 372–381.
- Kupka K, Nizetic B & Reinhardt J (1968) Sampling studies on the epidemiology and control of trachoma in southern Morocco. *Bulletin of the World Health Organization* 39, 547–566.
- Lakew T, Alemayehu W, Melese M *et al.* (2009a) Importance of coverage and endemicity on the return of infectious trachoma after a single mass antibiotic distribution. *PLoS Neglected Tropical Diseases* 3, e507.
- Lakew T, House J, Hong KC *et al.* (2009b) Reduction and return of infectious trachoma in severely affected communities in Ethiopia. *PLoS Neglected Tropical Diseases* 3, e376.
- Laming AC, Currie BJ, Difrancesco M, Taylor HR & Mathews JD (2000) A targeted, single-dose azithromycin strategy for trachoma. *The Medical Journal of Australia* 172, 163–166.
- Lansingh VC & Carter MJ (2007) Trachoma surveys 2000–2005: results, recent advances in methodology, and factors affecting the determination of prevalence. *Survey of Ophthalmology* 52, 535–546.
- Leach AJ, Shelby-James TM, Mayo M *et al.* (1997) A prospective study of the impact of community-based azithromycin treatment of trachoma on carriage and resistance of *Streptococcus pneumoniae*. *Clinical Infectious Diseases: an official publication of the Infectious Diseases Society of America* 24, 356–362.
- Lee S, Alemayehu W, Melese M *et al.* (2007) Chlamydia on children and flies after mass antibiotic treatment for trachoma. *The American Journal of Tropical Medicine & Hygiene* 76, 129–131.
- Lietman T, Porco T, Dawson C & Blower S (1999) Global elimination of trachoma: how frequently should we administer mass chemotherapy? *Nature Medicine* 5, 572–576.
- Lietman TM, Dawson CR, Osaki SY & Zegans ME (2000) Clinically active trachoma versus actual Chlamydial infection. *The Medical Journal of Australia* 172, 93–94.
- Limburg H, Bah M & Johnson GJ (2001) Trial of the Trachoma Rapid Assessment methodology in The Gambia. *Ophthalmic Epidemiology* 8, 73–85.
- Liu H, Ou B, Paxton A *et al.* (2002) Rapid assessment of trachoma in Hainan Province, China: validation of the new World Health Organization methodology. *Ophthalmic Epidemiology* 9, 97–104.
- Luna EJ, Medina NH, Oliveira B *et al.* (1992) Epidemiology of trachoma in Bebedouro State of Sao Paulo, Brazil: prevalence and risk factors. *International Journal of Epidemiology* 21, 169–177.
- Lynch M, West SK, Munoz B, Kayongoya A, Taylor HR & Mmbaga BB (1994) Testing a participatory strategy to change hygiene behaviour: face washing in central Tanzania. *Transactions of the Royal Society of Tropical Medicine & Hygiene* 88, 513–517.
- Mabey DC, Solomon AW & Foster A (2003) Trachoma. *Lancet* 362, 223–229.
- Maccallan AF (1931) The epidemiology of trachoma. *The British Journal of Ophthalmology* 15, 369–411.
- Malaty R, Zaki S, Said ME, Vastine DW, Dawson DW & Schachter J (1981) Extraocular infections in children in areas with endemic trachoma. *The Journal of Infectious Diseases* 143, 853.
- Mariotti SP, Pascolini D & Rose-Nussbaumer J (2009) Trachoma: global magnitude of a preventable cause of blindness. *The British Journal of Ophthalmology* 93, 563–568.
- Mathur GM & Sharma R (1970) Influence of some socio-economic factors on the prevalence of trachoma. *Indian Journal of Medical Sciences* 24, 325–334.
- Melese M, Alemayehu W, Friedlander E & Courtright P (2004a) Indirect costs associated with accessing eye care services as a

V. H. Hu *et al.* **Epidemiology and control of trachoma**

- barrier to service use in Ethiopia. *Tropical Medicine & International Health* 9, 426–431.
- Melese M, Chidambaram JD, Alemayehu W *et al.* (2004b) Feasibility of eliminating ocular *Chlamydia trachomatis* with repeat mass antibiotic treatments. *The Journal of the American Medical Association* 292, 721–725.
- Melese M, Alemayehu W, Lakew T *et al.* (2008) Comparison of annual and biannual mass antibiotic administration for elimination of infectious trachoma. *The Journal of the American Medical Association* 299, 778–784.
- Merbs SL, West SK & West ES (2005) Pattern of recurrence of trachomatous trichiasis after surgery surgical technique as an explanation. *Ophthalmology* 112, 705–709.
- Michel CE, Solomon AW, Magbanua JP *et al.* (2006) Field evaluation of a rapid point-of-care assay for targeting antibiotic treatment for trachoma control: a comparative study. *Lancet* 367, 1585–1590.
- Miller K, Pakpour N, Yi E *et al.* (2004a) Pesky trachoma suspect finally caught. *The British Journal of Ophthalmology* 88, 750–751.
- Miller K, Schmidt G, Melese M *et al.* (2004b) How reliable is the clinical exam in detecting ocular chlamydial infection? *Ophthalmic Epidemiology* 11, 255–262.
- Munoz B, Bobo L, Mkocho H, Lynch M, Hsieh YH & West S (1999) Incidence of trichiasis in a cohort of women with and without scarring. *International Journal of Epidemiology* 28, 1167–1171.
- Munoz B, Solomon AW, Zingales J *et al.* (2003) Antibiotic dosage in trachoma control programs: height as a surrogate for weight in children. *Investigative Ophthalmology & Visual Science* 44, 1464–1469.
- Myatt M, Limburg H, Minassian D & Katyola D (2003) Field trial of applicability of lot quality assurance sampling survey method for rapid assessment of prevalence of active trachoma. *Bulletin of the World Health Organization* 81, 877–885.
- Myatt M, Mai NP, Quynh NQ *et al.* (2005) Using lot quality-assurance sampling and area sampling to identify priority areas for trachoma control: Viet Nam. *Bulletin of the World Health Organization* 83, 756–763.
- Negrel AD & Mariotti SP (1999) Trachoma rapid assessment: rationale and basic principles. *Community Eye Health* 12, 51–53.
- Negrel AD, Taylor HR & West S (2001) *Guidelines for Rapid Assessment for Blinding Trachoma* World Health Organization, Geneva.
- Ngondi J, Ole-Sempele F, Onsarigo A *et al.* (2006a) Blinding trachoma in postconflict southern Sudan. *PLoS Medicine* 3, e478.
- Ngondi J, Ole-Sempele F, Onsarigo A *et al.* (2006b) Prevalence and causes of blindness and low vision in southern Sudan. *PLoS Medicine* 3, e477.
- Ngondi J, Onsarigo A, Matthews F *et al.* (2006c) Effect of 3 years of SAFE (surgery, antibiotics, facial cleanliness, and environmental change) strategy for trachoma control in southern Sudan: a cross-sectional study. *Lancet* 368, 589–595.
- Ngondi J, Reacher M, Matthews F *et al.* (2007) The epidemiology of low vision and blindness associated with trichiasis in southern Sudan. *BMC Ophthalmology* 7, 12.
- Ngondi J, Matthews F, Reacher M, Baba S, Brayne C & Emerson P (2008) Associations between active trachoma and community intervention with antibiotics, facial cleanliness, and environmental improvement (A,F,E). *PLoS Neglected Tropical Diseases* 2, e229.
- Ngondi J, Gebre T, Shargie EB *et al.* (2009a) *Evaluation of Three Years of the SAFE Strategy (Surgery, Antibiotics, Facial cleanliness and Environmental Improvement) for Trachoma Control in Five Districts of Ethiopia Hyperendemic for Trachoma*. Transactions of the Royal Society of Tropical Medicine & Hygiene.
- Ngondi J, Reacher M, Matthews F, Brayne C & Emerson P (2009b) Trachoma survey methods: a literature review. *Bulletin of the World Health Organization* 87, 143–151.
- Paxton A (2001) Rapid assessment of trachoma prevalence – Singida, Tanzania. A study to compare assessment methods. *Ophthalmic Epidemiology* 8, 87–96.
- Peach H, Piper S, Devanesen D & Al E (1987) *Northern Territory Trachoma Control and Eye Health Committee's Randomised Controlled Trial of the Effect of Eye Drops and Eye Washing on Follicular Trachoma Among Aboriginal Children*. Report of the Northern Territory Trachoma and Eye Health Committee Incorporated.
- Pitsouni E, Iavazzo C, Athanasiou S & Falagas ME (2007) Single-dose azithromycin versus erythromycin or amoxicillin for *Chlamydia trachomatis* infection during pregnancy: a meta-analysis of randomised controlled trials. *International Journal of Antimicrobial Agents* 30, 213–221.
- Polack S, Brooker S, Kuper H, Mariotti S, Mabey D & Foster A (2005) Mapping the global distribution of trachoma. *Bulletin of the World Health Organization* 83, 913–919.
- Porco TC, Gebre T, Ayele B *et al.* (2009) Effect of mass distribution of azithromycin for trachoma control on overall mortality in Ethiopian children: a randomized trial. *The Journal of the American Medical Association* 302, 962–968.
- Rabiu M, Alhassan M & Ejere H (2007) Environmental sanitary interventions for preventing active trachoma. *Cochrane Database of Systematic Reviews* CD004003.
- Ray KJ, Porco TC, Hong KC *et al.* (2007) A rationale for continuing mass antibiotic distributions for trachoma. *BMC Infectious Diseases* 7, 91.
- Ray KJ, Lietman TM, Porco TC *et al.* (2009) When can antibiotic treatments for trachoma be discontinued? Graduating communities in three african countries *PLoS Neglected Tropical Diseases* 3, e458.
- Reacher MH, Munoz B, Alghassany A, Daar AS, Elbualy M & Taylor HR (1992) A controlled trial of surgery for trachomatous trichiasis of the upper lid. *Archives of Ophthalmology* 110, 667–674.
- Reacher M, Foster A & Huber MJ (1993) *Trichiasis Surgery for Trachoma. The Bilamellar Tarsal Rotation Procedure*. World Health Organization, Geneva.
- Resnikoff S, Peyramaure F, Bagayogo CO & Huguet P (1995) Health education and antibiotic therapy in trachoma control. *Revue internationale du trachome et de pathologie oculaire tropicale et subtropicale et de sante publique: organe de la Ligue contre le trachome avec la collaboration de l'International*

V. H. Hu *et al.* **Epidemiology and control of trachoma**

- Organization against Trachoma et des organisations nationales et internationales de sante publique 72, 89–98, 101–110.
- Resnikoff S, Pascolini D, Etya'ale D *et al.* (2004) Global data on visual impairment in the year 2002. *Bulletin of the World Health Organization* 82, 844–851.
- Sahlu T & Larson C (1992) The prevalence and environmental risk factors for moderate and severe trachoma in southern Ethiopia. *The Journal of Tropical Medicine & Hygiene* 95, 36–41.
- Schachter J, West SK, Mabey D *et al.* (1999) Azithromycin in control of trachoma. *Lancet* 354, 630–635.
- Schemann JF, Sacko D, Malvy D *et al.* (2002) Risk factors for trachoma in Mali. *International Journal of Epidemiology* 31, 194–201.
- Solomon AW, Holland MJ, Burton MJ *et al.* (2003) Strategies for control of trachoma: observational study with quantitative PCR. *Lancet* 362, 198–204.
- Solomon AW, Holland MJ, Alexander ND *et al.* (2004a) Mass treatment with single-dose azithromycin for trachoma. *The New England Journal of Medicine* 351, 1962–1971.
- Solomon AW, Peeling RW, Foster A & Mabey DC (2004b) Diagnosis and assessment of trachoma. *Clinical Microbiology Reviews* 17, 982–1011. table of contents.
- Solomon AW, Mohammed Z, Massae PA *et al.* (2005) Impact of mass distribution of azithromycin on the antibiotic susceptibilities of ocular *Chlamydia trachomatis*. *Antimicrobial Agents & Chemotherapy* 49, 4804–4806.
- Solomon AW, Harding-Esch E, Alexander ND *et al.* (2008) Two doses of azithromycin to eliminate trachoma in a Tanzanian community. *The New England Journal of Medicine* 358, 1870–1871.
- Tabbara KF, Abu-El-Asrar A, Al-Omar O, Choudhury AH & Al-Faisal Z (1996) Single-dose azithromycin in the treatment of trachoma. A randomized, controlled study. *Ophthalmology* 103, 842–846.
- Tang FF, Huang YT, Chang HL & Wong C (1957) Isolation of trachoma virus in chick embryo. *Journal of Hygiene, Epidemiology, Microbiology & Immunology* 1, 109–120.
- Taylor HR, Velasco FM & Sommer A (1985) The ecology of trachoma: an epidemiological study in southern Mexico. *Bulletin of the World Health Organization* 63, 559–567.
- Taylor HR, West SK, Mmbaga BB *et al.* (1989) Hygiene factors and increased risk of trachoma in central Tanzania. *Archives of Ophthalmology* 107, 1821–1825.
- Tellis B, Keeffe JE & Taylor HR (2007) Surveillance report for active trachoma, 2006: National Trachoma Surveillance and Reporting Unit. *Communicable Diseases Intelligence* 31, 366–374.
- Thylefors B, Dawson CR, Jones BR, West SK & Taylor HR (1987) A simple system for the assessment of trachoma and its complications. *Bulletin of the World Health Organization* 65, 477–483.
- Thylefors B, Negrel AD, Pararajasegaram R & Dadzie KY (1995) Global data on blindness. *Bulletin of the World Health Organization* 73, 115–121.
- Tielsch JM, West KP Jr, Katz J *et al.* (1988) The epidemiology of trachoma in southern Malawi. *The American Journal of Tropical Medicine & Hygiene* 38, 393–399.
- Tiwari T, Murphy TV & Moran J (2005) Recommended antimicrobial agents for the treatment and postexposure prophylaxis of pertussis: 2005 CDC Guidelines. MMWR. Recommendations and reports: morbidity and mortality weekly report. *Recommendations and reports / Centers for Disease Control* 54, 1–16.
- Turner VM, West SK, Munoz B *et al.* (1993) Risk factors for trichiasis in women in Kongwa, Tanzania: a case-control study. *International Journal of Epidemiology* 22, 341–347.
- Ward M, Bailey R, Lesley A, Kajbaf M, Robertson J & Mabey D (1990) Persisting inapparent chlamydial infection in a trachoma endemic community in The Gambia. *Scandinavian Journal of Infectious Diseases. Supplementum* 69, 137–148.
- West SK (1999) Azithromycin for control of trachoma. *Community Eye Health* 12, 55–56.
- West SK (2004) Trachoma: new assault on an ancient disease. *Progress in Retinal & Eye Research* 23, 381–401.
- West S, Lynch M, Turner V *et al.* (1989) Water availability and trachoma. *Bulletin of the World Health Organization* 67, 71–75.
- West SK, Congdon N, Katala S & Mele L (1991a) Facial cleanliness and risk of trachoma in families. *Archives of Ophthalmology* 109, 855–857.
- West SK, Munoz B, Turner VM, Mmbaga BB & Taylor HR (1991b) The epidemiology of trachoma in central Tanzania. *International Journal of Epidemiology* 20, 1088–1092.
- West S, Munoz B, Bobo L *et al.* (1993) Nonocular Chlamydia infection and risk of ocular reinfection after mass treatment in a trachoma hyperendemic area. *Investigative Ophthalmology & Visual Science* 34, 3194–3198.
- West S, Lynch M, Munoz B, Katala S, Tobin S & Mmbaga BB (1994) Predicting surgical compliance in a cohort of women with trichiasis. *International Ophthalmology* 18, 105–109.
- West S, Munoz B, Lynch M *et al.* (1995) Impact of face-washing on trachoma in Kongwa, Tanzania. *Lancet* 345, 155–158.
- West SK, Munoz B, Mkocho H, Hsieh YH & Lynch MC (2001) Progression of active trachoma to scarring in a cohort of Tanzanian children. *Ophthalmic Epidemiology* 8, 137–144.
- West ES, Munoz B, Mkocho H *et al.* (2005a) Mass treatment and the effect on the load of *Chlamydia trachomatis* infection in a trachoma-hyperendemic community. *Investigative Ophthalmology & Visual Science* 46, 83–87.
- West SK, Munoz B, Mkocho H *et al.* (2005b) Infection with *Chlamydia trachomatis* after mass treatment of a trachoma hyperendemic community in Tanzania: a longitudinal study. *Lancet* 366, 1296–1300.
- West ES, Munoz B, Imeru A, Alemayehu W, Melese M & West SK (2006a) The association between epilation and corneal opacity among eyes with trachomatous trichiasis. *The British Journal of Ophthalmology* 90, 171–174.
- West SK, Emerson PM, Mkocho H *et al.* (2006b) Intensive insecticide spraying for fly control after mass antibiotic treatment for trachoma in a hyperendemic setting: a randomised trial. *Lancet* 368, 596–600.

V. H. Hu *et al.* **Epidemiology and control of trachoma**

- West SK, West ES, Alemayehu W *et al.* (2006c) Single-dose azithromycin prevents trichiasis recurrence following surgery: randomized trial in Ethiopia. *Archives of Ophthalmology* **124**, 309–314.
- West S, Alemayehu W, Munoz B & Gower EW (2007a) Azithromycin prevents recurrence of severe trichiasis following trichiasis surgery: STAR trial. *Ophthalmic Epidemiology* **14**, 273–277.
- West SK, Munoz B, Mkocho H, Gaydos C & Quinn T (2007b) Trachoma and ocular *Chlamydia trachomatis* were not eliminated three years after two rounds of mass treatment in a trachoma hyperendemic village. *Investigative Ophthalmology & Visual Science* **48**, 1492–1497.
- WHO (1997) *Planning for the Global Elimination of Trachoma (GET)*. World Health Organization, Geneva.
- WHO (2004) *Report of the Eighth Meeting of the WHO Alliance for the Global Elimination of Blinding Trachoma*. World Health Organization, Geneva.
- WHO (2006) *Trachoma Control – A Guide for Programme Managers*. World Health Organization, Geneva.
- WHO (2008) *The Global Burden of Disease: 2004 Update*. World Health Organization, Geneva.
- WHO-ITI (2004) *Joint Research Agenda Meeting for the Elimination of Blinding Trachoma*. World Health Organization, Geneva.
- Wolle MA, Munoz B, Mkocho H & West SK (2009) Age, sex, and cohort effects in a longitudinal study of trachomatous scarring. *Investigative Ophthalmology & Visual Science* **50**, 592–596.
- Wright HR & Taylor HR (2005) Clinical examination and laboratory tests for estimation of trachoma prevalence in a remote setting: what are they really telling us? *Lancet Infectious Diseases* **5**, 313–320.
- Wright HR, Vu H & Taylor HR (2005) How to assess the prevalence of trachoma. *The British Journal of Ophthalmology* **89**, 526–527.
- Wright HR, Turner A & Taylor HR (2008) Trachoma. *Lancet* **371**, 1945–1954.
- Yorston D, Mabey D, Hatt S & Burton M (2006) Interventions for trachoma trichiasis. *Cochrane Database of Systematic Reviews* **3**, D004008.
- Zack R, Mkocho H, Zack E, Munoz B & West SK (2008) Issues in defining and measuring facial cleanliness for national trachoma control programs. *Transactions of the Royal Society of Tropical Medicine & Hygiene* **102**, 426–431.
- Zerihun N (1997) Trachoma in Jimma zone, south western Ethiopia. *Tropical Medicine & International Health* **2**, 1115–1121.
- Zhang H, Kandel RP, Sharma B & Dean D (2004a) Risk factors for recurrence of postoperative trichiasis: implications for trachoma blindness prevention. *Archives of Ophthalmology* **122**, 511–516.
- Zhang J, Lietman T, Olinger L, Miao Y & Stephens RS (2004b) Genetic diversity of *Chlamydia trachomatis* and the prevalence of trachoma. *The Pediatric Infectious Disease Journal* **23**, 217–220.
- Zhang H, Kandel RP, Atakari HK & Dean D (2006) Impact of oral azithromycin on recurrence of trachomatous trichiasis in Nepal over 1 year. *The British Journal of Ophthalmology* **90**, 943–948.

Corresponding Author Victor H. Hu, KCCO, KCMC, P.O. Box 2254, Moshi, Tanzania. Tel.: +255 76 258 2948; E-mail: victor.hu@lshtm.ac.uk

Chapter 2

Trachoma: an update



Review paper containing a general summary of the features of trachoma

Cover sheet for each ‘research/review paper’ included in a research thesis

1. For a ‘research/review paper’ already published

1.1. Where was the work published? ***Ophthalmology International***

1.2. When was the work published? ***Winter 2010***

1.3. Was the work subject to academic peer review? ***Yes***

1.4. Have you retained the copyright for the work? ***No***

If no, or if the work is being included in its published format, attach evidence of permission from copyright holder (publisher or other author) to include work

See Appendix 7b

2. For multi-authored work, give full details of your role in the research included in the paper and in the preparation of the paper. (Attach a further sheet if necessary)

This paper was written and submitted by myself, with consideration of comments from the co-author.

Candidate’s signature.....

A handwritten signature in black ink, appearing to read 'J. Barton.', is centered within a light gray rectangular box.

Supervisor or senior author’s signature to confirm role as stated in (2).....

Trachoma: an update

Trachoma is the most common infectious cause of blindness worldwide. There are currently estimated to be 40 million people with active disease, 8 million with trachomatous trichiasis and 6 million blind or visually impaired from trachoma. The disease is mainly found in poor, rural areas in developing countries, especially in isolated communities with little infrastructural support. Conjunctival infection with *Chlamydia trachomatis* causes inflammation in children who are at risk of developing scarring and blindness as adults. Trachoma control measures utilise surgery for trichiasis along with ways of reducing the prevalence and transmission of infection including mass antibiotic treatment, promoting facial cleanliness and environmental improvements. Recent decades have seen encouraging reductions in the levels of active disease, but not of trichiasis. Much work remains if blindness from trachoma is to be eliminated in the next decade, the target of Vision 2020.

Trachoma is a chronic keratoconjunctivitis caused by serovars A–C of *Chlamydia trachomatis*. It is an ancient disease with references to it having been made many centuries BC, but is still the most common infectious cause of blindness worldwide. The World Health Organisation (WHO) currently estimates there to be 6 million blind or visually impaired from trachoma.¹ Trachoma is found in poor, rural areas in developing countries, typically in isolated communities with poor water access. It has been identified as a priority by the WHO both within the Neglected Tropical Diseases Programme and Vision 2020. This review outlines the main features of the disease with attention to recently published findings.

CLINICAL FEATURES AND NATURAL HISTORY

Infection with *C. trachomatis* is mostly found in children who develop a chronic, follicular conjunctivitis and/or papillary hypertrophy, which, if severe enough, can obscure visualisation of the deep blood vessels (Figure 1). Pannus of the upper cornea may also occur. Follicles at the limbus, after resolving, may leave shallow depressions ('Herbert's pits'), which are a pathognomonic sign of trachoma. Symptoms are generally mild, with infection often going unnoticed by the patient. All children in an endemic area will usually be infected at some point, with recurrent episodes of infection being common. It is believed that recurrent episodes of infection drive the scarring complications of trachoma including entropion, trichiasis, corneal opacity and blindness. Unlike the blindness resulting from cataract, which is painless and treatable, trachomatous blindness is painful and, in practice, irreversible.

Chlamydial infection and signs of active disease are most commonly found in young children and decline with age. The duration of infection and disease and the level of bacterial loads all decrease with age, probably as the result of an acquired immune response.² However, the scarring complications are cumulative and increase with age so that trichiasis and corneal opacity are more common in the older members of a community. Where there is a very high prevalence of active disease, up to 80% of children in southern Sudan, for example, trichiasis has been seen in those less than 15 years of age.^{3,4}

Various grading systems for trachoma have been proposed, most of which recognise that the disease has an initial active/inflammatory stage, which is most commonly found in children, and a cicatricial stage, which is usually seen in adults. Trachoma control programmes currently use the 1987 WHO simplified grading system (Table 1 and Figure 1).

PREVALENCE AND GEOGRAPHICAL DISTRIBUTION

Trachoma is endemic in over 50 countries, with the highest burden of active disease and trichiasis in parts of Africa. It is also found in the Middle East, Asia, Latin America and the Western Pacific (Figure 2). Australia is the only high-income country in which trachoma is still a problem, where it is found in the Aboriginal community.⁵ While trachoma was a major public health problem in Europe and North America a century ago, it has now disappeared from these areas with improvements in living and hygiene standards.

It was estimated that in 2002 there were 1.3 million people blind from trachoma.² However, this number may be much higher when considering those categorised as being blind from 'corneal opacities' in trachoma endemic countries, and there is a further large number suffering from trachomatous low vision.^{6,7} There are currently estimated to be 40 million people with active trachoma, and 8.2 million with trichiasis.⁸ These numbers are significantly lower than previous estimates, probably partly because of previous poor data collection and unwarranted extrapolations between populations. However, there are probably also significantly fewer people now affected by the disease.⁹ This reduction mirrors improvements in living standards, as was the case in industrialised countries, and trachoma control programmes are also likely to have played a role. Good prevalence data from India and China is lacking, however, and small changes in these countries could have a large effect on global data. Of note, there has been little reduction in the number of people with trichiasis, with a slight increase estimated between 2003 and 2008.¹⁰ This suggests that conjunctival scarring can progress even when active disease and *C. trachomatis* infection has been successfully combated,

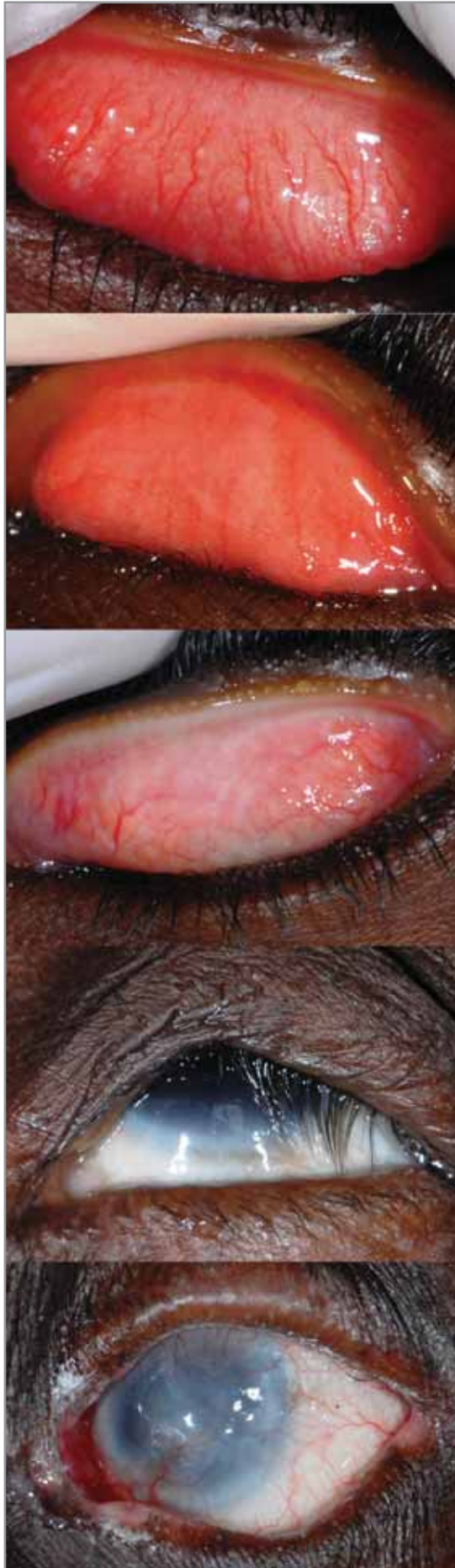VH Hu MB BCh, MRCOphth, MJ Burton PhD, MRCP, FRCOphth, International Centre for Eye Health, Department of Infectious and Tropical Diseases, London School of Hygiene and Tropical Medicine, London, UK
Kilimanjaro Centre for Community Ophthalmology, Moshi, Tanzania

Table 1. The simplified World Health Organisation trachoma grading system

Grade	Description
Trachomatous Inflammation – Follicular (TF)	The presence of five or more follicles, each at least 0.5 mm in diameter, in the upper tarsal conjunctiva
Trachomatous Inflammation – Intense (TI)	Pronounced inflammatory thickening of the tarsal conjunctiva that obscures more than half of the normal deep vessels
Trachomatous Scarring (TS)	The presence of easily visible lines, bands or sheets of scarring in the tarsal conjunctiva
Trachomatous Trichiasis (TT)	At least one lash rubbing on the eyeball, or evidence of recent epilation
Corneal Opacity (CO)	Easily visible corneal opacity causing blurring of the pupil margin and usually causing significant visual impairment (<0.3)



Figure 1. Clinical features/simplified grading system for trachoma. Top: Trachomatous Inflammation – Follicular (TF); second top: Trachomatous Inflammation – Intense (TI); middle: Trachomatous Scarring (TS); second bottom: Trachomatous Trichiasis (TT); bottom: Corneal Opacity (CO).



which has significant implications for future trachoma control planning.

THE BURDEN OF DISEASE

The WHO estimated that in 2004 the burden of disease was around 1.3 million disability-adjusted life years (DALYs, which measure the gap between an ‘ideal’ healthy population and the premature mortality and morbidity caused by a specific disease).¹¹ There has been significant variation in different estimates of the burden of disease. This is unsurprising as there have been differences in the prevalence data used, the weightings given to disabilities and whether or not trichiasis is included as causing disabling disease independently of visual impairment.¹² Most estimates have not included trichiasis even though it may be as disabling as visual impairment alone.^{13,14} The economic cost of trachoma has been calculated as being as much as US\$8 billion.¹⁴

DIAGNOSTIC TESTS: INFECTION VS. DISEASE

Various tests have been used to diagnose ocular infection with *C. trachomatis*. The earliest, Giemsa staining and microscopy of conjunctival scrapings, shows intracytoplasmic inclusions and helped to confirm the infectious nature of trachoma. Tissue culture is expensive and time consuming, but has excellent specificity. It also shows that viable organism is present and has the potential to assess for antimicrobial resistance.¹⁵ Serological or tear antibody assays have been used in epidemiological research but are not helpful in detecting current infection.¹⁶ Direct immunofluorescent cytology and enzyme immunoassay (EIA) have also been used to detect infection, but are less sensitive than nucleic acid amplification tests (NAAT).

NAAT tests are extremely sensitive for the presence of the organism, and can theoretically detect one elementary body in a sample. However, poor correlation has generally been shown with clinical grading. Individuals with follicular inflammation are more likely to be positive with NAAT tests in hyperendemic regions than in hypoendemic, and those with intense trachomatous inflammation are more likely to be positive than those with follicular inflammation.¹⁷ Part of the explanation for this poor correlation is likely to be the kinetics of the disease, with a latent phase (infection before clinical signs), a patent phase (infection and clinical signs) and a recovery phase (infection cleared but clinical signs persist).¹⁸ The mismatch between NAAT testing and clinical findings is probably also partly explained by the use of grading systems such as the simplified WHO system in which individuals with less than five follicles will be graded as not having trachoma. NAAT testing has become accepted as the gold standard for detecting infection in research, but is unsuitable for use in trachoma control programmes, being complex, expensive and time consuming.

A rapid test or ‘point of care’ assay, which was developed to detect chlamydial lipopolysaccharide using EIA in the field and was relatively cheap and easy to perform, showed initial promise.¹⁹ However, when evaluated subsequently in larger studies in the Gambia and Senegal, the sensitivity and specificity were lower than previously thought.²⁰

THE BIOLOGY OF CHLAMYDIA

Chlamydia are small, Gram-negative, obligate intracellular bacteria. *C. trachomatis* only naturally infects humans. It contains the ocular serovars A, B, Ba and C, which are responsible for endemic trachoma, genital serovars D to K and the



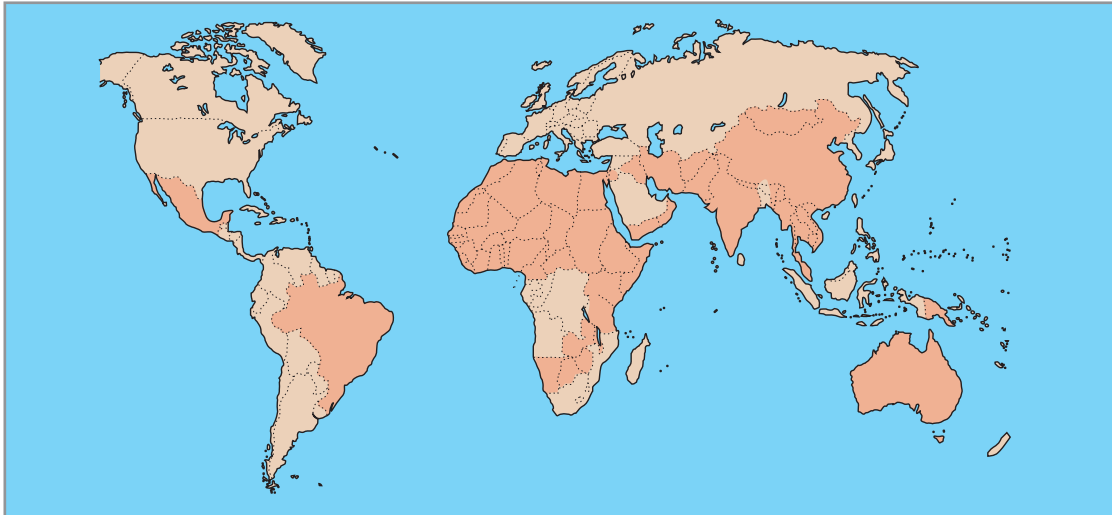


Figure 2. Map of trachoma endemic countries in 2009. Reproduced with permission of Dr Silvio P. Mariotti, WHO/NMH/PBD.

lymphogranuloma venereum serovars 1, 2 and 3. Serovars D to K can also cause a follicular conjunctivitis, generally known as ‘inclusion conjunctivitis’, which may appear similar to the initial infection seen in trachoma, but is sporadic in nature and not associated with the long-term sequelae.

Chlamydia have a unique developmental life cycle with an extracellular, infectious form – the elementary body (EB) – and an intracellular, replicative form – the reticulate body (RB). The EB is typically 0.5 µm in diameter, metabolically inert and actively taken up by epithelial cells into intracellular inclusions. EBs here transform into RBs, which are up to 1.5 µm in diameter, and multiply by binary fission until there are thousands of organisms within the host cell

cytoplasmic inclusion body. RBs then transform back into EBs and are released on lysis of the host cell. The developmental cycle typically takes 24–48 hours.

TRANSMISSION OF INFECTION

Ocular infection with *C. trachomatis* is probably spread in a variety of ways, including direct contact, spread of infected secretions on fingers or fomites and transmission by eye-seeking flies. Trachoma is a focal disease that clusters at the level of the community and the household, reflecting the infectious nature of the disease.^{21,22} During mass antibiotic treatment it is important that all infected members of a household are treated or re-infection within that family and

advertisement



subsequently across the community is likely to happen. Non-human reservoirs of infection have not been identified and extra-ocular sites of infection do not appear to play an important role in the transmission of infection.²³

RISK FACTORS

Various environmental, socio-economic and behavioural factors have been associated with trachoma. Determining which of these have a causative relationship with the disease is more difficult as many of the studies have lacked adequate controls and results may be confounded by factors being closely related. For example, trachoma is associated with poor access to water;²⁴ however, the more important factor seems to be how water is used in the household. Families with trachoma use less water for washing children than control families without trachoma after controlling for various factors.²⁵ There is some evidence that unclean faces are associated with trachoma and that promoting face washing may reduce the prevalence of trachoma.^{26,27} Flies are a risk factor for trachoma by facilitating transmission, and reducing the fly density and latrine provision lowers the risk of trachoma.^{28,29} The transmission of trachoma also occurs in the absence of flies, however.³⁰ Other risk factors for trachoma include crowding, female gender and migration between communities.^{21,31,32}

PROGRESSION OF SCARRING

Blindness from trachoma is thought to start with recurrent episodes of infection with *C. trachomatis* in childhood, as outlined above. These infectious episodes lead to the development of conjunctival scarring, usually in late childhood or adulthood. Progression of this scarring leads to deformation of the eyelid, including the tarsal plate, with entropion and trichiasis developing. Trauma from the trichiasis, a dry ocular surface (from destruction of the Meibomian glands and goblet cells, reduced lacrimal gland output and defective lid closure) and secondary bacterial or fungal infection result in corneal scarring and blindness. A number of epidemiological studies have looked at progression of the scarring process and these have shown that TS (conjunctival scarring) can progress to TT (trichiasis) in 10% of cases over seven years and TT to CO (corneal opacity) in 8% over four years.^{33,34} Marked variation has been found between these studies. These differences may be partly because of a genuine difference between the study areas and partly because of short follow-up times.

PATHOGENESIS

Ocular inoculation with trachoma secretions in human volunteer studies have shown that naive individuals almost always developed infection, but that on rechallenge with the same serovar only half became re-infected and the disease was milder and more short-lived.^{35,36} More rapid disease resolution with age has also been found in longitudinal studies.² These findings suggest that some serovar-specific protective immune response can develop, and has a role in the resolution of infection. However, it is also generally accepted that the immune response to *C. trachomatis* is responsible for much of the damage found in the disease. The cellular paradigm suggests that non-immune host cells, particularly epithelial cells, release pro-inflammatory cytokines and chemokines in response to chlamydial and other bacterial infection, which induce an inflammatory response leading to tissue damage. This is in contrast to the immunological

paradigm, which argues that the damage is driven by an acquired immune cell response, which is important for defence against infection but also leads to collateral tissue damage.³⁷

Histopathological studies show a mixed inflammatory cell infiltrate with lymphoid follicles, which, in children, are composed largely of B cells.³⁸ Animal models and examination of peripheral blood samples suggest that an effective cell-mediated immune response appears to be important in the resolution of infection.³⁹ A strong T_H1 response seems to be particularly important in clearing infection, while a predominantly T_H2 response may be associated with failure to clear infection.^{40,41} Gene expression analysis has shown that the levels of various pro-/anti-inflammatory cytokines and extra-cellular matrix modifiers are altered in trachoma.^{42,43} An imbalance in this response may result in immunopathological tissue damage.

SURVEY METHODS

The WHO defines trachoma as being a public health problem when the prevalence of follicular trachoma is at least 10% in 1–9-year-olds or the prevalence of trachomatous trichiasis is at least 1% in over 14-year-olds. A population-based prevalence survey (PBPS) is the gold standard for determining where trachoma is a public health problem and should yield good prevalence data on the level of active disease and trichiasis.⁴⁴ However, it is an expensive and time-consuming process. Alternative survey methods are trachoma rapid assessment (TRA) and acceptance sampling trachoma rapid acceptance (ASTRA). TRA provides rankings rather than prevalence estimates, is quick to perform and may have a role in prioritising areas for treatment or ascertaining absence of disease. However, it has limited reliability.⁴⁵ ASTRA sampling continues until either a maximum sample size has been reached or a preset number of TF cases have been found. It is also relatively quick and may be able to provide TF prevalence estimates. However, it works best when the distribution of cases is homogenous, while trachoma is a disease which clusters. PBPS remains the only way of providing trachoma prevalence data and is the WHO recommended survey method.

MATHEMATICAL MODELS

Trachoma is a disease in which the disabling complications – trichiasis and blindness – take decades to manifest, and this presents challenges to epidemiological and intervention studies of the disease. Various mathematical models of trachoma have been proposed as an alternative means of analysis.⁴⁶ These have been used to suggest, for example, that discontinuing antibiotic treatment when the prevalence of infection falls below 5% would be appropriate for most areas and could significantly reduce the amount of antibiotic distribution required.⁴⁷

TRACHOMA CONTROL

In 1997 the WHO established the Global Alliance for the Elimination of Blinding Trachoma by the year 2020 (GET 2020), which recommends the 'SAFE' strategy: S for surgery for trichiasis; A for antibiotics to reduce the reservoir of infection; F for facial cleanliness through personal hygiene; and E for environmental improvement to reduce the transmission of infection.⁴⁸ A more comprehensive review of the SAFE strategy than is outlined below has been presented elsewhere.^{49,50}



Surgery for trichiasis

The WHO recommends the bilamellar tarsal rotation procedure (BTR) following the results of a randomised surgical trial in Oman.⁵¹ Recurrence rate at two years in this study was 18%; however, recurrence rates after 2–3 years vary greatly, from 20% to 60%.¹⁸ Various factors seem to be involved, including surgeon variability, disease severity and infection status. It should be borne in mind, however, that recurrence may be defined as only a single lash touching the globe and so-called surgical failure may still be a significant improvement to the preoperative status of the patient. Poor uptake of surgery amongst people with trichomatous trichiasis is a major obstacle to be overcome. Barriers to uptake include constraint by duties such as child care, lack of time, perceived cost of surgery, lack of an escort, distance to travel to surgery and fear of the operation.⁵²

Antibiotics to reduce the community burden of *C. trachomatis* infection

Mass antibiotic treatment of a community aims to reduce the reservoir of chlamydial infection. If treatment is given only to those individuals with clinically evident active disease, then reinfection will likely occur from those with clinically unapparent infection. The WHO recommends mass antibiotic treatment of all people over 6 months of age where the prevalence of active trachoma in children aged 1–9 years exceeds 10%. The macrolide antibiotic azithromycin (20 mg/kg up to 1 g) should be used, or, where this drug cannot be used, topical tetracycline ointment can be used twice daily for six weeks. Azithromycin has been generously donated by Pfizer through the International Trachoma Initiative, which has transformed the availability of treat-

ment. The WHO currently recommends that treatment should be given annually for three years and then the prevalence reassessed.

Studies have suggested that mass antibiotic treatment can significantly reduce the level of infection, especially in areas with a low/moderate level of disease.⁵³ However, in the absence of other interventions, reinfection tends to occur in hyperendemic areas.⁵⁴ Biannual treatment may be more effective in this context.⁵⁵ As with any mass antibiotic distribution, one of the major concerns is the potential development of resistant organisms. To date, this has not been an issue with *Chlamydia* spp.; however, azithromycin resistance in pneumococci develops soon after mass treatment. The prevalence of macrolide-resistant strains does appear to decrease after 6–12 months, but if mass treatment were given six-monthly then resistance may become more of an issue.¹⁸

A recent cluster-randomised trial in Ethiopia showed that at 12 months, there was a 50% reduction in childhood mortality in communities where children had been treated with oral azithromycin compared to those where they had not.⁵⁶ This noteworthy finding needs to be validated in other studies, but may have important implications for mass antibiotic distribution.

Facial cleanliness to interrupt the transmission of trachoma

Improved facial cleanliness may reduce ocular and nasal secretions, which are potential sources of *C. trachomatis* infection, thereby reducing transmission. Clean faces may also be less of a target for flies, which can act as a vector. Studies on facial cleanliness confront several problems

advertisement



including measuring cleanliness accurately, face washing occurring only before examination by alert carers and deciding whether dirty faces lead to trachoma or trachoma leads to dirty faces. A Cochrane review on the promotion of face washing for prevention of active trachoma concluded that there is some evidence that face washing, when combined with topical tetracycline ointment, can be effective in reducing severe trachoma (TI).⁵⁷ However, a beneficial effect was not found for face washing, either alone or in combination with tetracycline ointment, in reducing the overall prevalence of active trachoma (TF and/or TI).

Environmental changes to interrupt the transmission of trachoma

This is potentially the most important area in trachoma control – trachoma disappeared from Europe and North America as a result of improved living conditions rather than mass antibiotic distribution or surgical practice. However, it is also the area with the least evidence to support it. Strategies generally involve components such as increasing water supply, improving latrine access, reducing the density of flies and health education. A Cochrane review concluded that there is evidence that insecticide spray as a fly control measure reduces trachoma significantly, that latrine provision has not demonstrated significant trachoma reduction and that health education may be effective in reducing trachoma.⁵⁸ While many trachoma control measures currently being implemented may have some support from observational studies, there is a need for further rigorous clinical trials.

The SAFE strategy as a whole

Implementation of the four components of the SAFE strategy is expected to have most success in eliminating ocular chlamydial infection and blindness from trachoma.^{59,60} Studies assessing the SAFE strategy with the use of comparable control areas suggest that antibiotic treatment has the greatest impact in reducing trachoma but that provision of the other components does provide additional benefit.^{61,62}

CONCLUSION

There have been considerable reductions in the prevalence of trachoma over the last few decades, probably due to the widespread implementation of the SAFE strategy and secular changes. Reductions in the level of disease in some countries have meant that trachoma is no longer considered a public health threat there. However, it remains an important cause of blindness in poor, rural communities in many parts of the developing world. Major obstacles exist in tackling trachoma in many areas, including scarce resources or armed conflict, and these factors tend to be found more commonly in those countries where trachoma is still an important problem. The outcomes of operational programmes in this context may be disappointing compared to those of research studies, for example, in the antibiotic coverage achieved or the results of trichiasis surgery. Even if ocular chlamydia infection were to be eliminated tomorrow there would remain a large cohort of people with a history of infection who are still at risk of developing progressive scarring complications and blindness. The GET 2020 has been instrumental in advancing control efforts but trachoma cannot be forgotten about for the foreseeable future.

REFERENCES

1. WHO. Trachoma. www.who.int/water_sanitation_health/diseases/trachoma/en/index.html. Date last accessed: September 9 2010.
2. Bailey R, Duong T, Carpenter R, Whittle H, Mabey D. The duration of human ocular Chlamydia trachomatis infection is age dependent. *Epidemiol Infect* 1999; **123**: 479–486.
3. King JD, Ngondi J, Gatpan G, *et al*. The burden of trachoma in ayod county of southern Sudan. *PLoS Negl Trop Dis* 2008; **2**: e299.
4. Ngondi J, Ole-Sempele F, Onsarigo A, *et al*. Blinding trachoma in postconflict southern Sudan. *PLoS Med* 2006; **3**: e478.
5. Wright HR, Keeffe JE, Taylor HR. Trachoma, cataracts and uncorrected refractive error are still important contributors to visual morbidity in two remote indigenous communities of the Northern Territory, Australia. *Clin Experiment Ophthalmol* 2009; **37**: 550–557.
6. Resnikoff S, Pascolini D, Etya'ale D, *et al*. Global data on visual impairment in the year 2002. *Bull World Health Organ* 2004; **82**: 844–851.
7. Frick KD, Basilion EV, Hanson CL, Colchero MA. Estimating the burden and economic impact of trachomatous visual loss. *Ophthalmic Epidemiol* 2003; **10**: 121–132.
8. Mariotti SP, Pascolini D, Rose-Nussbaumer J. Trachoma: global magnitude of a preventable cause of blindness. *Br J Ophthalmol* 2009; **93**: 563–568.
9. Thylefors B, Negrel AD, Pararajasegaram R. [Epidemiological surveillance of trachoma: evaluation and perspective]. *Rev Int Trach Pathol Ocul Trop Subtrop Sante Publique* 1992; **69**: 107–114.
10. World Health Organization. Report of the 2nd Global Scientific Meeting on Trachoma. Geneva: World Health Organization; 2003.
11. World Health Organization. The Global Burden of Disease: 2004 Update. Geneva: World Health Organization; 2008.
12. Burton MJ, Mabey DC. The global burden of trachoma: a review. *PLoS Negl Trop Dis* 2009; **3**: e460.
13. Frick KD, Melia BM, Buhmann RR, West SK. Trichiasis and disability in a trachoma-endemic area of Tanzania. *Arch Ophthalmol* 2001; **119**: 1839–1844.
14. Frick KD, Hanson CL, Jacobson GA. Global burden of trachoma and economics of the disease. *Am J Trop Med Hyg* 2003; **69**(Suppl 5): 1–10.
15. Mabey DC, Solomon AW, Foster A. Trachoma. *Lancet* 2003; **362**: 223–229.
16. West SK. Trachoma: new assault on an ancient disease. *Prog Retin Eye Res* 2004; **23**: 381–401.
17. Wright HR, Taylor HR. Clinical examination and laboratory tests for estimation of trachoma prevalence in a remote setting: what are they really telling us? *Lancet Infect Dis* 2005; **5**: 313–320.
18. Wright HR, Turner A, Taylor HR. Trachoma. *Lancet* 2008; **371**: 1945–1954.
19. Michel CE, Solomon AW, Magbanua JP, *et al*. Field evaluation of a rapid point-of-care assay for targeting antibiotic treatment for trachoma control: a comparative study. *Lancet* 2006; **367**: 1585–1590.
20. Harding-Esch EM. Trachoma Control and Elimination: Field studies in The Gambia and Senegal. PhD thesis. London: University of London; 2010.
21. Bailey R, Osmond C, Mabey DC, Whittle HC, Ward ME. Analysis of the household distribution of trachoma in a Gambian village using a Monte Carlo simulation procedure. *Int J Epidemiol* 1989; **18**: 944–951.
22. Katz J, Zeger SL, Tielsch JM. Village and household clustering of xerophthalmia and trachoma. *Int J Epidemiol* 1988; **17**: 865–869.
23. Andreasen AA, Burton MJ, Holland MJ, *et al*. Chlamydia trachomatis ompA variants in trachoma: What do they tell us? *PLoS Negl Trop Dis* 2008; **2**: e306.
24. West S, Lynch M, Turner V, *et al*. Water availability and trachoma. *Bull World Health Organ* 1989; **67**: 71–75.
25. Bailey R, Downes B, Downes R, Mabey D. Trachoma and water use: a case control study in a Gambian village. *Trans R Soc Trop Med Hyg* 1991; **85**: 824–828.
26. West SK, Congdon N, Katala S, Mele L. Facial cleanliness and risk of trachoma in families. *Arch Ophthalmol* 1991; **109**: 855–857.
27. West S, Munoz B, Lynch M, *et al*. Impact of face-washing on trachoma in Kongwa, Tanzania. *Lancet* 1995; **345**: 155–158.
28. Forsey T, Darougar S. Transmission of chlamydiae by the housefly. *Br J Ophthalmol* 1981; **65**: 147–150.
29. Emerson PM, Lindsay SW, Alexander N, *et al*. Role of flies and provision of latrines in trachoma control: cluster-randomised controlled trial. *Lancet* 2004; **363**: 1093–1098.
30. Taylor HR, Velasco FM, Sommer A. The ecology of trachoma: an epidemiological study in southern Mexico. *Bull World Health Organ* 1985; **63**: 559–567.
31. Turner VM, West SK, Munoz B, *et al*. Risk factors for trichiasis in women in Kongwa, Tanzania: a case-control study. *Int J Epidemiol* 1993; **22**: 341–347.
32. Burton MJ, Holland MJ, Makalo P, *et al*. Re-emergence of Chlamydia trachomatis infection after mass antibiotic treatment of a trachoma-endemic Gambian community: a longitudinal study. *Lancet* 2005; **365**: 1321–1328.



33. Munoz B, Bobo L, Mkocho H, *et al*. Incidence of trichiasis in a cohort of women with and without scarring. *Int J Epidemiol* 1999; **28**: 1167–1171.
34. Burton MJ, Bowman RJ, Faal H, *et al*. The long-term natural history of trachomatous trichiasis in the Gambia. *Invest Ophthalmol Vis Sci* 2006; **47**: 847–852.
35. Jawetz E, Rose L, Hanna L, Thygeson P. Experimental inclusion conjunctivitis in man: measurements of infectivity and resistance. *JAMA* 1965; **194**: 620–632.
36. Tarizzo ML, Nataf R, Nabli B. Experimental inoculation of thirteen volunteers with agent isolated from inclusion conjunctivitis. *Am J Ophthalmol* 1967; **63**(Suppl): 1120–1128.
37. Darville T, Hiltke TJ. Pathogenesis of genital tract disease due to Chlamydia trachomatis. *J Infect Dis* 2010; **201**(Suppl 2): S114–125.
38. el-Asrar AM, Van den Oord JJ, Geboes K, *et al*. Immunopathology of trachomatous conjunctivitis. *Br J Ophthalmol* 1989; **73**: 276–282.
39. Ramsey KH, Rank RG. Resolution of chlamydial genital infection with antigen-specific T-lymphocyte lines. *Infect Immun* 1991; **59**: 925–931.
40. Williams DM, Grubbs BG, Pack E, Kelly K, Rank RG. Humoral and cellular immunity in secondary infection due to murine Chlamydia trachomatis. *Infect Immun* 1997; **65**: 2876–2882.
41. Holland MJ, Bailey RL, Hayes LJ, Whittle HC, Mabey DC. Conjunctival scarring in trachoma is associated with depressed cell-mediated immune responses to chlamydial antigens. *J Infect Dis* 1993; **168**: 1528–1531.
42. Burton MJ, Bailey RL, Jeffries D, Mabey DC, Holland MJ. Cytokine and fibrogenic gene expression in the conjunctivas of subjects from a Gambian community where trachoma is endemic. *Infect Immun* 2004; **72**: 7352–7356.
43. Faal N, Bailey RL, Sarr I, *et al*. Temporal cytokine gene expression patterns in subjects with trachoma identify distinct conjunctival responses associated with infection. *Clin Exp Immunol* 2005; **142**: 347–353.
44. Ngondi J, Reacher M, Matthews F, Brayne C, Emerson P. Trachoma survey methods: a literature review. *Bull World Health Organ* 2009; **87**: 143–151.
45. Limburg H, Bah M, Johnson GJ. Trial of the Trachoma Rapid Assessment methodology in The Gambia. *Ophthalmic Epidemiol* 2001; **8**: 73–85.
46. Gambhir M, Basanez MG, Burton MJ, *et al*. The development of an age-structured model for trachoma transmission dynamics, pathogenesis and control. *PLoS Negl Trop Dis* 2009; **3**: e462.
47. Ray KJ, Lietman TM, Porco TC, *et al*. When can antibiotic treatments for trachoma be discontinued? Graduating communities in three African countries. *PLoS Negl Trop Dis* 2009; **3**: e458.
48. Global elimination of blinding trachoma. World Health Assembly Resolution WHA 51.11. www.who.int/ncd/vision2020_actionplan/documents/WHA51.11.pdf; Geneva: WHO; 1998.
49. Hu VH, Harding-Esch EM, Burton MJ, *et al*. Epidemiology and control of trachoma: systematic review. *Trop Med Int Health* 2010; **15**: 673–691.
50. Sumamo E, Emerson P, Harvey K, Burton M. The Cochrane library and trachoma: an overview of reviews. *Evid Based Child Health* 2007; **2**: 943–964.
51. Reacher MH, Munoz B, Alghassany A, *et al*. A controlled trial of surgery for trachomatous trichiasis of the upper lid. *Arch Ophthalmol* 1992; **110**: 667–674.
52. Kuper H, Solomon AW, Buchan J, *et al*. A critical review of the SAFE strategy for the prevention of blinding trachoma. *Lancet Infect Dis* 2003; **3**: 372–381.
53. Solomon AW, Harding-Esch E, Alexander ND, *et al*. Two doses of azithromycin to eliminate trachoma in a Tanzanian community. *N Engl J Med* 2008; **358**: 1870–1871.
54. Lakew T, House J, Hong KC, *et al*. Reduction and return of infectious trachoma in severely affected communities in Ethiopia. *PLoS Negl Trop Dis* 2009; **3**: e376.
55. Biebesheimer JB, House J, Hong KC, *et al*. Complete local elimination of infectious trachoma from severely affected communities after six biannual mass azithromycin distributions. *Ophthalmology* 2009; **116**: 2047–2050.
56. Porco TC, Gebre T, Ayele B, *et al*. Effect of mass distribution of azithromycin for trachoma control on overall mortality in Ethiopian children: a randomized trial. *JAMA* 2009; **302**: 962–968.
57. Ejere H, Alhassan MB, Rabiu M. Face washing promotion for preventing active trachoma. *Cochrane Database Syst Rev* 2004, Issue 3: CD003659.
58. Rabiu M, Alhassan M, Ejere H. Environmental sanitary interventions for preventing active trachoma. *Cochrane Database Syst Rev* 2007, Issue 4: CD004003.
59. Astle WF, Wiafe B, Ingram AD, Mwanga M, Glassco CB. Trachoma control in Southern Zambia – an international team project employing the SAFE strategy. *Ophthalmic Epidemiol* 2006; **13**: 227–236.
60. Ngondi J, Gebre T, Shargie EB, *et al*. Estimation of effects of community intervention with antibiotics, facial cleanliness, and environmental improvement (A,F,E) in five districts of Ethiopia hyperendemic for trachoma. *Br J Ophthalmol*; **94**: 278–281.
61. Ngondi J, Onsarigo A, Matthews F, *et al*. Effect of 3 years of SAFE (surgery, antibiotics, facial cleanliness, and environmental change) strategy for trachoma control in southern Sudan: a cross-sectional study. *Lancet* 2006; **368**: 589–595.
62. Cumberland P, Edwards T, Hailu G, *et al*. The impact of community level treatment and preventative interventions on trachoma prevalence in rural Ethiopia. *Int J Epidemiol* 2008; **37**: 549–558. ■

CORRESPONDENCE TO:

Victor Hu
International Centre for Eye Health
London School of Hygiene and Tropical Medicine
Keppel Street
London, WC1E 7HT
United Kingdom
E-mail: victor.hu@lshtm.ac.uk

Chapter 3

Trachoma: protective and pathogenic ocular immune responses to *Chlamydia trachomatis*



Review paper including clearance of infection, protective immunity and models of pathogenesis in trachoma

Cover sheet for each ‘research/review paper’ included in a research thesis

1. For a ‘research paper/review’ prepared for publication but not yet published
 - 1.1. Where is the work intended to be published? ***Lancet Infectious Diseases***
 - 1.2. List the paper’s authors in the intended authorship order
Victor H. Hu, Martin J. Holland, Matthew J. Burton
 - 1.3. Stage of publication ***Under review***
2. For multi-authored work, give full details of your role in the research included in the paper and in the preparation of the paper. (Attach a further sheet if necessary)

This paper was written and submitted by myself, with consideration of comments and edits from the co-authors.

Candidate’s signature.....

A handwritten signature in black ink, appearing to read 'M. J. Burton', is centered within a light gray rectangular box.

Supervisor or senior author’s signature to confirm role as stated in (2).....

Title Page

Title

Trachoma: protective and pathogenic ocular immune responses to *Chlamydia trachomatis*

Authors & Affiliations:

Victor H. Hu^{1,2}, Martin J. Holland¹, Matthew J. Burton^{1,2}

¹ Clinical Research Department, Faculty of Infectious and Tropical Diseases, London School of Hygiene and Tropical Medicine, London, UK

² Kilimanjaro Centre for Community Ophthalmology, Moshi, Tanzania

There were no other authors, contributors, medical writers or editors involved in the preparation of this manuscript.

Corresponding author details:

Victor Hu

International Centre for Eye Health,

London School of Hygiene and Tropical Medicine,

Keppel Street,

London, WC1E 7HT, UK

Telephone number: +255 76 258 2948

Email: victor.hu@lshtm.ac.uk

Online supplemental material

Supplemental Tables S1 to S6.

Conflict of interest:

None of the authors have had, or will receive, any financial support or other benefit which may be viewed as creating a potential conflict of interest.

Search strategy and selection criteria

References for this review were identified through searches of PubMed for articles published, at any date, by use of the terms “trachoma” and “immunology”, “pathogenesis”, “pathology”, “scarring” or “histology”. Articles resulting from these searches and relevant articles cited in those articles were reviewed. Articles published in English were included.

Abstract

Trachoma, caused by *Chlamydia trachomatis* (Ct), is the leading infectious blinding disease worldwide. Chronic conjunctival inflammation develops in childhood and leads to eyelid scarring and blindness in adulthood. The immune response to Ct provides only partial protection against re-infection, which is common, and causes scarring pathology through incompletely characterised mechanisms. We review the current literature on both protective and pathological immune responses in trachoma. The resolution of Ct infection is probably IFN γ -dependent, involving both Th1 and Natural Killer cells. However, an increasing number of studies indicate that innate immune responses, possibly arising from the epithelium, may be important in the development of tissue damage and scarring, which involves matrix metalloproteinase activity. Current trachoma control measures that are centred on repeated mass antibiotic treatment of populations are logistically challenging and have the potential to drive anti-microbial resistance. Development and introduction of a vaccine would offer significant benefits, but a clearer understanding of the mechanisms of immunopathology remain elusive and a barrier to vaccine progress.

Introduction

Trachoma results from infection of the conjunctiva with *Chlamydia trachomatis* (*Ct*) and is the commonest infectious cause of blindness worldwide. The World Health Organization (WHO) estimates that at least 1.3 million people are blind from trachoma and 40 million have active disease; it is included in the Neglected Tropical Diseases Programme.^{1, 2} The WHO recommends the SAFE Strategy for trachoma control: Surgery for trichiasis; mass Antibiotic distribution to treat infection; improved Facial hygiene and Environmental improvements to interrupt *Ct* transmission.³

Trachoma is caused by *Ct* serovars A to C. Whereas genital tract *Ct* infection, the commonest bacterial sexually transmitted disease worldwide, infecting 90 million people each year, is caused by serovars D to K.⁴ The ocular and genital strains are strictly differentiated with ocular strains lacking a functional tryptophan synthase operon.⁵ Both ocular and genital infections produce inflammatory reactions, which are often asymptomatic, leading to scarring complications with significant morbidity in a subset of those infected.

This article reviews the literature on immunity and immunopathogenesis in trachoma. We focus on results from human studies of ocular *Ct* infection, but also draw on relevant studies of genital tract infection and animal models. Human studies of the pathology, immune response and immunopathogenesis in trachoma are comprehensively summarised in Supplemental Tables S1 to S6.

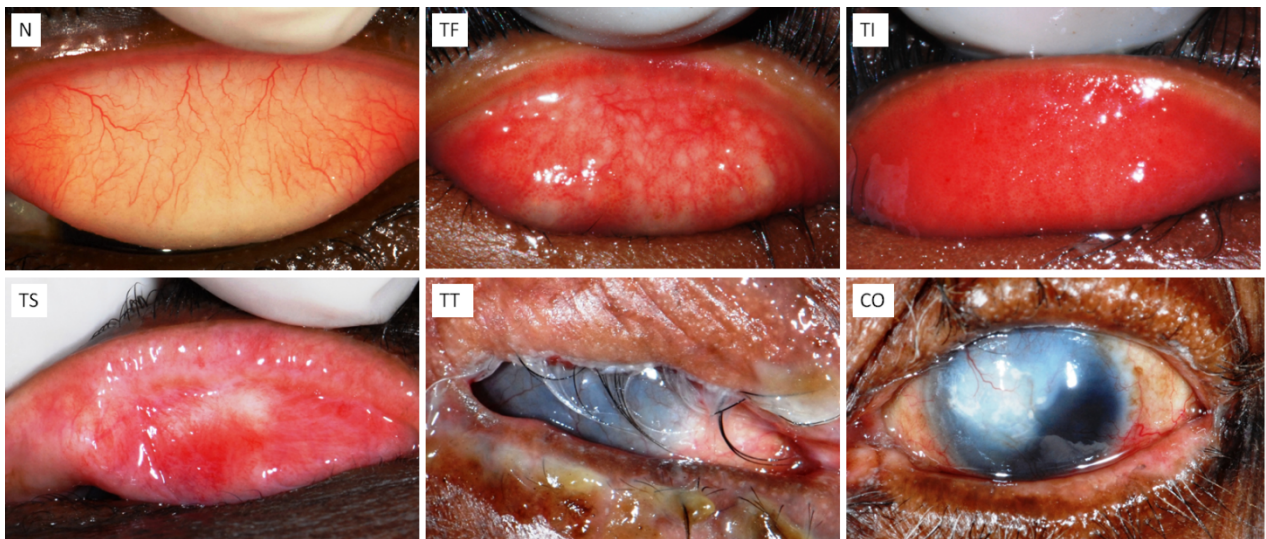
Clinical features, natural history and infection

Infection with *Ct* causes a chronic conjunctivitis, “active trachoma”, which is characterised by follicles (sub-epithelial collections of lymphoid cells appearing as small, yellow-white elevations) and papillae (engorgement of small vessels with inflammatory conjunctival thickening). Infection may be detected in the absence of clinical disease and, conversely, active disease may be present without detectable current *Ct* infection.⁶ Children experiencing repeated episodes of infection are at increased risk of subsequent conjunctival scarring, which causes in turning of the eyelids (entropion) so that the eyelashes scratch the eye (trichiasis). Eventually sight is lost as irreversible corneal opacification develops from a combination of insults, which compromise the ocular surface (trichiasis, dryness, secondary bacterial or fungal infections). Clinical features are shown in Figure 1. The scarring complications of trachoma usually develop slowly over many years. Several longitudinal studies support this pathway to blindness, although there is considerable variation in reported disease progression rates, possibly reflecting differences in both the natural history in different populations and in study methodology (Table 1).

A key question is why only a minority of people living in trachoma endemic regions develop severe scarring complications. It is likely that the answer to this is a complex interaction between the individual's lifetime burden of infection and their local immune response. Severe, persistent or recurrent conjunctival inflammation is strongly associated with the risk of scarring complications.⁷⁻¹¹ Females are at increased risk of conjunctival scarring and trichiasis, possibly from greater lifetime *Ct* exposure through close contact with children. There is good evidence that the immune response to *Ct* is partly determined by host genetic variations. Several studies from different populations have identified genetic polymorphisms related to immune system function which are associated with trachomatous scarring, indicating the importance of host immuno-genetic variations in modifying the risk of developing blinding disease (Table S1).¹²⁻²³

Trachoma was initially thought to result from a single episode of infection. However, the importance of repeated re-infection in the pathogenesis of scarring disease is now supported by various lines of investigation: animal models require repeated inoculation to induce disease; absence of scarring following a single inoculation in human volunteer studies; and cohort studies from trachoma-endemic areas demonstrating repeated infection.^{11, 24-28} However, *in vitro* studies have shown that persistent, non-replicating forms of *Ct* develop in response to various stress stimuli (penicillin, interferon- γ , iron or nutrient depletion).²⁹ While the relevance of these findings to human infection is not known, it has been suggested that persistent infection may drive the disease. There is very limited *in vivo* evidence for persistent ocular infection.³⁰ An important observation about *Ct* infection and ocular disease is that infection is infrequently detected in older adults, who are the group in which progressive scarring and blinding complications usually develop.^{10, 31-33} This is partly explained by the shorter duration of infection with increasing age.³⁴ However, other factors may also be important in scarred conjunctiva, such as non-chlamydial bacterial infection (discussed below).

Figure 1: Clinical features and grades of trachoma. N: normal. TF: Trachomatous inflammation - Follicular. TI: Trachomatous inflammation - Intense. TS: Trachomatous Scarring. TT: Trachomatous Trichiasis. CO: Corneal Opacity.



Histopathology

Active disease

Histological studies of conjunctival biopsies from children with active trachoma found mild to moderate epithelial hyperplasia with a mixed inflammatory infiltrate consisting of many macrophages with some T cells and polymorphonuclear leucocytes (Table S2).³⁵⁻³⁷ Dendritic cells are seen in the deeper epithelium and underlying stroma. Plasma cells form a band directly beneath the epithelium and around accessory lacrimal glands. Lymphoid follicles, the clinical and pathological hallmark of active trachoma, are found in the stroma (Figure 2). In children these consist mainly of B cells with some macrophages and T-cells, and are surrounded with a lymphocytic mantle. Around the follicle a diffuse infiltrate consisting of a mixed population of leucocytes (T-cells, neutrophils, macrophages, mast cells and eosinophils) is seen. Schematic diagrams of normal conjunctiva and active disease shown in Figures 3 and 4.

Figure 2: Histological section of the conjunctiva from a child with active trachoma. Kindly supplied by Professor Ahmed El-Asrar.

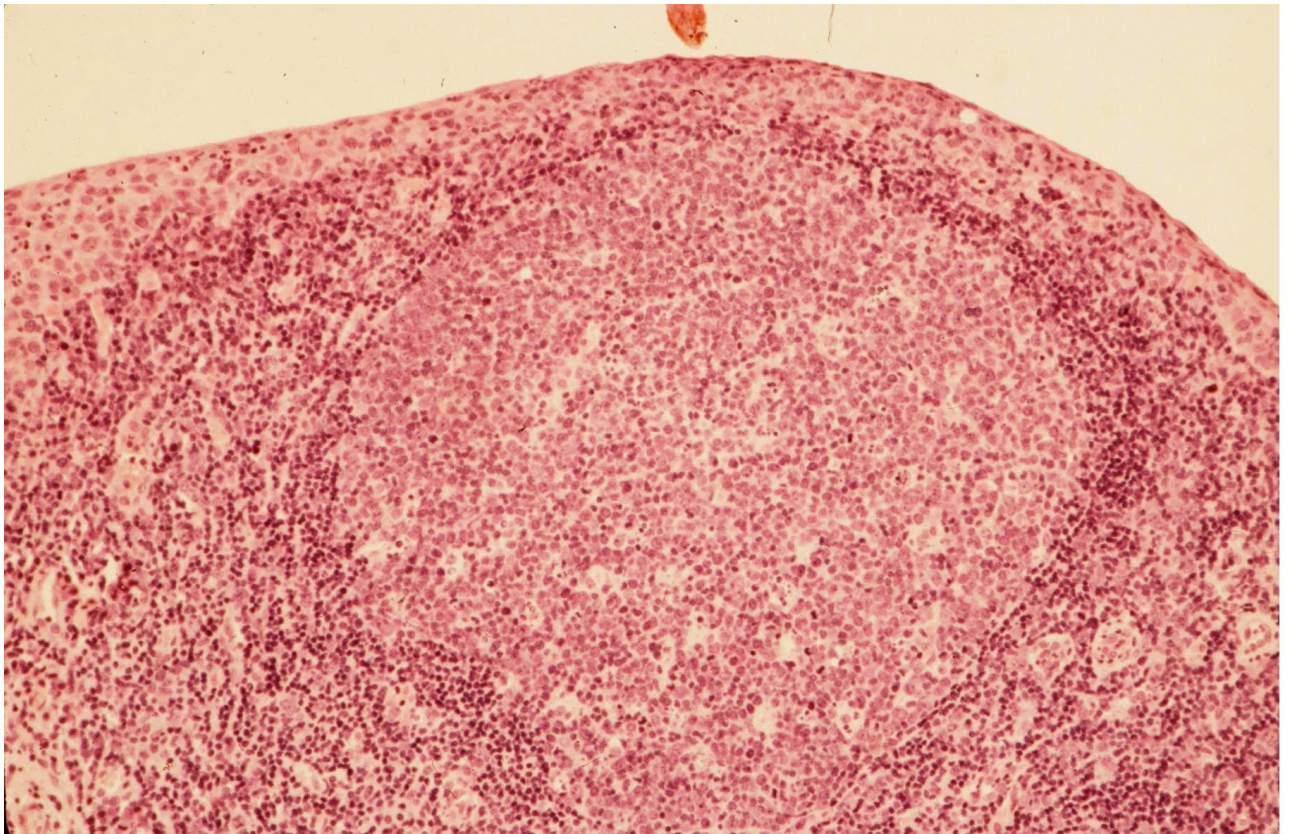


Figure 3: Schema of the normal conjunctiva.

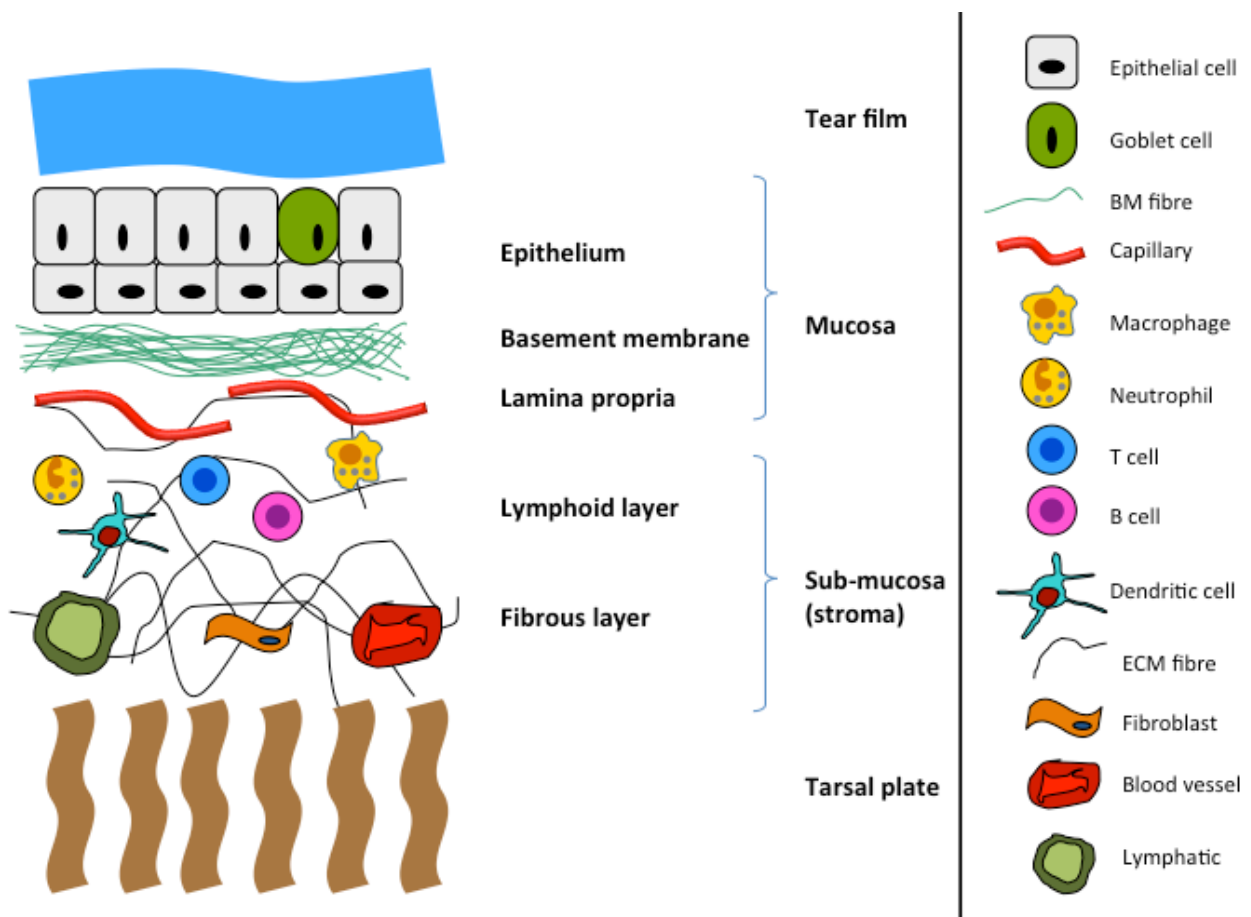
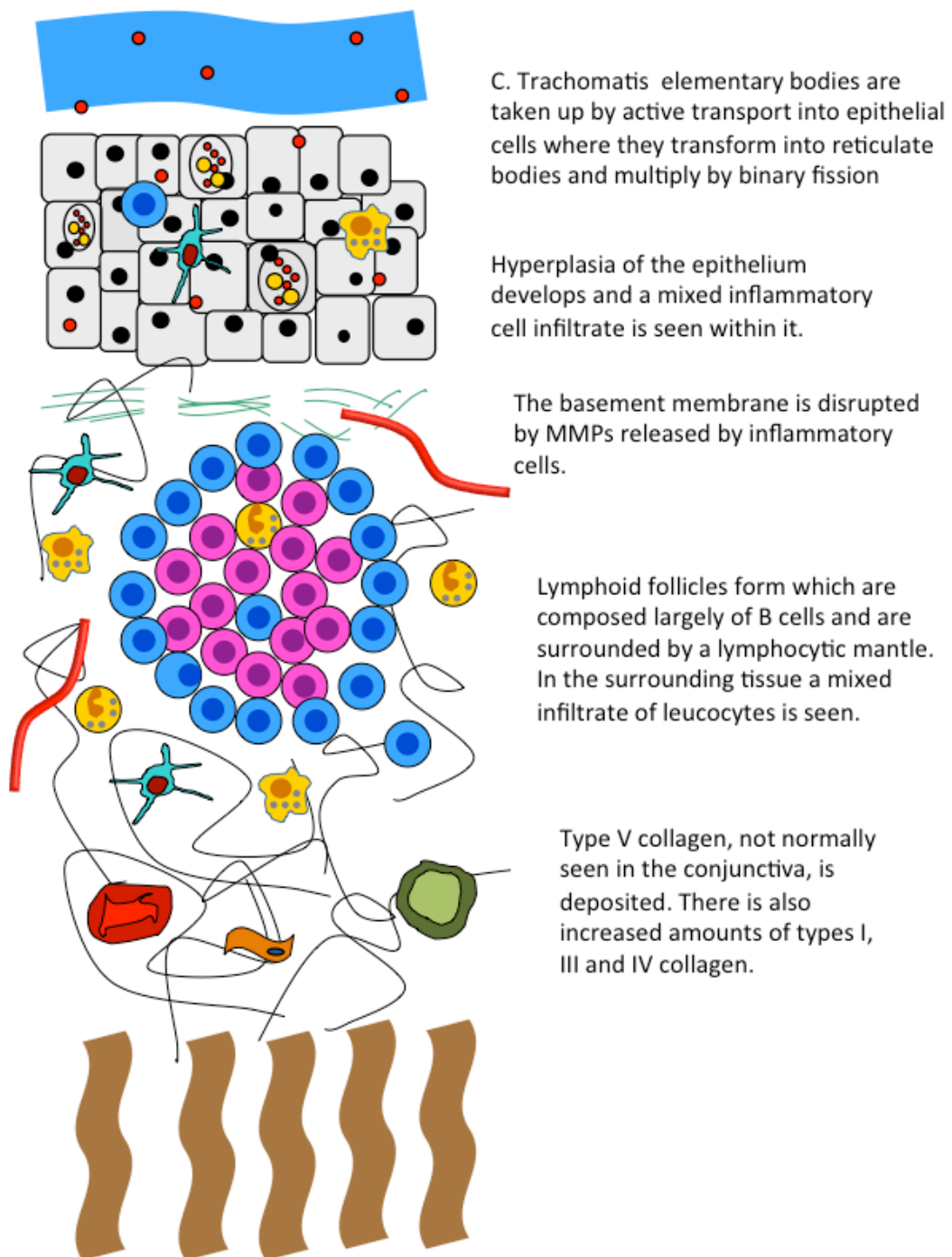


Figure 4: Schema of the conjunctiva in active disease. See Figure 3 for the key.



Scarring disease

Adults with conjunctival scarring have an epithelium which may show either squamous metaplasia or atrophy with focally denuded areas replaced by fibrinous exudate and cellular debris (Figure 5).^{37, 38} A chronic inflammatory cell infiltrate is found, most marked in the substantia propria with lymphocytes predominating.^{35, 39} CD4+ and CD8+ T-cells are present, and these generally outnumber B-cells. Follicles may be seen histologically in very inflamed subjects, even when absent clinically, and these contain monocytes, macrophages and plasma cells, but lack the germinal centres or centrally located B-cells seen in follicles of children. Underneath the epithelium the stroma is replaced by abnormal, compact, thick and mostly avascular scar tissue.³⁸ This subepithelial fibrous membrane has vertically aligned fibres parallel to the surface epithelium and is firmly adherent to the tarsal plate (Figure 6).

Figure 5: Histological sections of healthy conjunctiva and trachomatous scarring. Top: healthy. Middle and bottom: scarred, note disruption of the normal epithelial cell morphology and loss of epithelial cells; an increased inflammatory cell infiltrate; and loss of the normal connective tissue architecture.

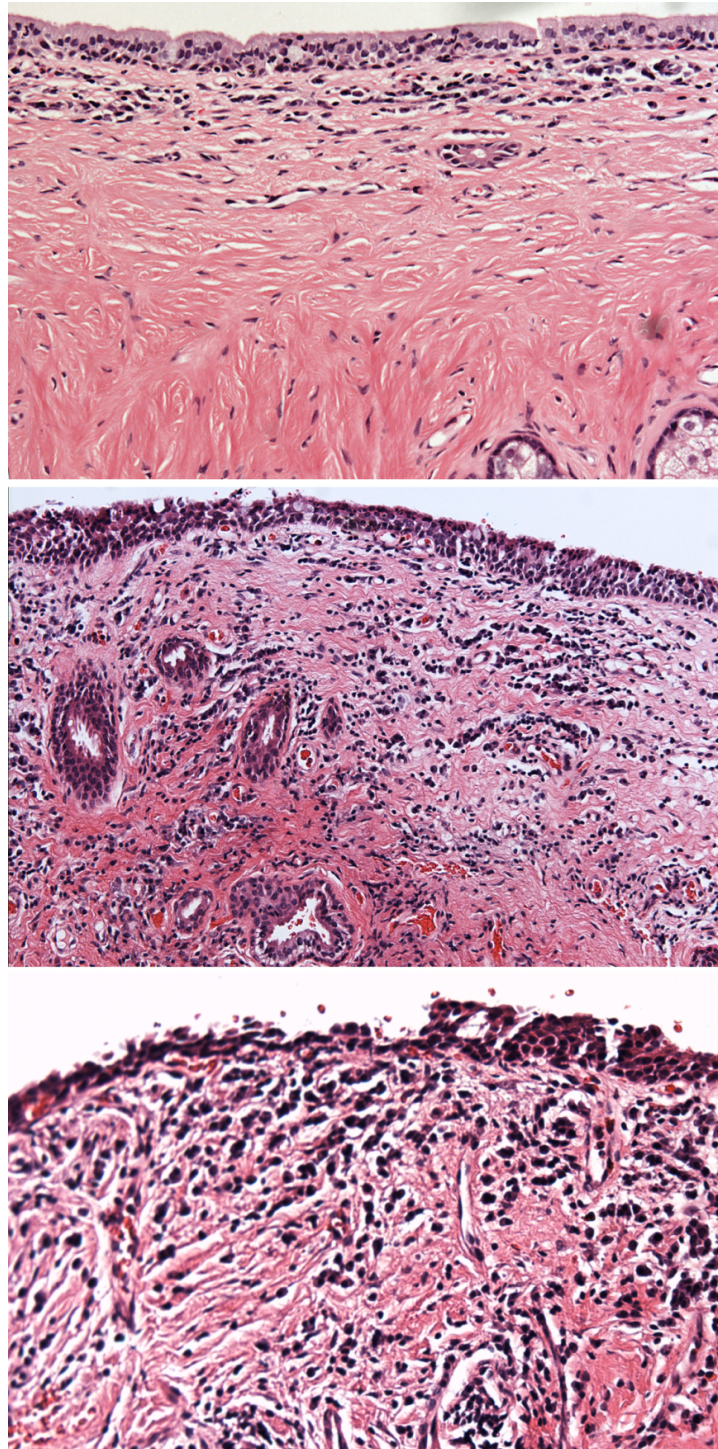
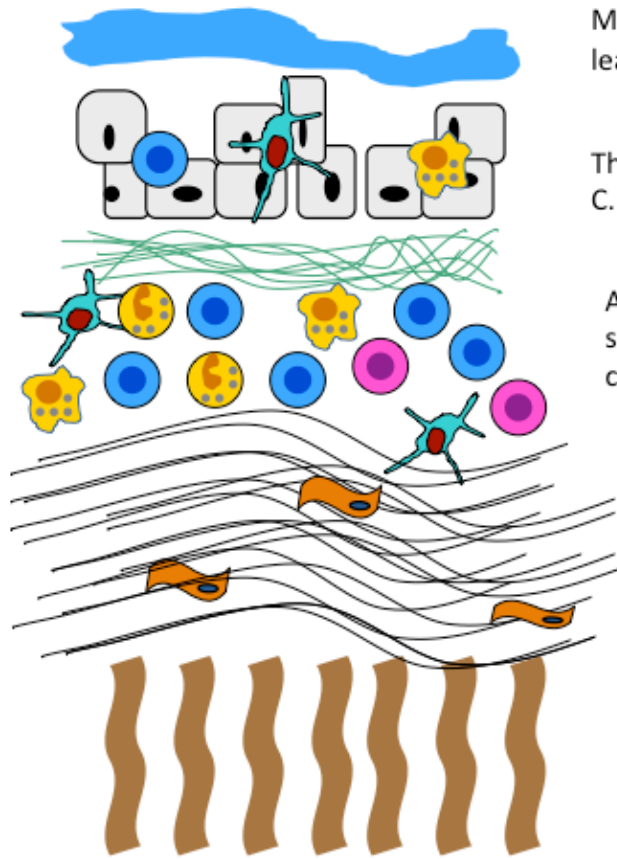


Figure 6: Schema of the conjunctiva with trachomatous scarring. See Figure 3 for the key.



Defective lid closure, damage to goblet cells and Meibomian glands, and lacrimal gland scarring lead to tear film disruption.

The epithelium becomes atrophied. Infection with *C. trachomatis*, however, is not usually found.

A chronic inflammatory cell infiltrate is seen, but follicles are rarely found compared to children.

Thick, compact, avascular scar tissue is seen in the submucosa which becomes firmly adherent to the tarsal plate. There is increased deposition of types IV and V collagen.

Resolution of *C. trachomatis* infection

Epithelial cells mount a pro-inflammatory and chemotactic response

Several *in vitro* studies of *Ct* infected epithelial cell lines have found that this infection provokes pro-inflammatory responses with epithelial cells producing pro-inflammatory and chemotactic cytokines such as interleukin-6 (IL-6), IL-8, growth regulated oncogene α (GRO α) and granulocyte macrophage colony-stimulating factor (GM-CSF).^{40, 41} The secretion of these factors was prolonged and required synthesis of chlamydial proteins. In contrast, other bacterial species provoked a rapid but transient cytokine induction.⁴⁰

Human studies are consistent with the epithelium producing pro-inflammatory factors constituting an initial innate response to *Ct*. Immunohistochemistry of conjunctival epithelium from children with active trachoma has shown IL-1 expression.⁴² Gene expression studies on conjunctival surface swab samples find enriched expression of multiple pro-inflammatory / chemotactic factors, Table S3.^{28, 43-45} In active trachoma, the epithelium shows increased MHC class I expression and induction of MHC class II (not normally found at this site).^{36, 46} There is evidence for natural killer (NK) cell and neutrophil recruitment and activation in active disease/infection, as part of an acute inflammatory responses.^{44, 47, 48}

Importance of cell-mediated immunity and IFN γ production

The results of animal studies of genital chlamydial infection suggest that resolution of infection is dependent on a Type-1 T-helper lymphocyte (Th1) response mediated primarily through interferon- γ (IFN γ). Congenitally athymic (nude) mice are unable to clear *C. muridarum* genital tract infection.⁴⁹ However, adoptive transfer to nude mice of CD4+ or CD8+ T-cells derived from normal mice previously infected with *C. muridarum* resolved the infection.⁵⁰ The CD4+ enriched cell line was much more efficient at clearing infection. However, recent murine studies using *Ct* instead of *C. muridarum* as the infectious agent did not find the absence of CD4+ cells altered the course of infection; limitations of animal models of *Ct* infection need to be recognised.⁵¹ Although, CD8+ T-cells can help resolve infection, they seem less important in animal models, as they were not an absolute requirement for immunity.⁵²

IFN γ is produced by several cell types including Th1 lymphocytes, CD8+ cytotoxic T lymphocytes (CTL) and NK cells. The production of IFN γ characterises the Th1 response and has several anti-chlamydial actions, which probably play a central role in clearing infection. IFN γ induces indoleamine-2,3-dioxygenase (IDO) expression, which lowers the intracellular pool of the essential amino acid tryptophan, which is necessary for chlamydial

metabolism.⁵³ It can also up-regulate inducible nitric oxide synthase (iNOS), which may help control *Ct* and protect against chronic sequelae in murine models.⁵⁴ Chlamydial growth can also be limited by IFN γ -mediated intracellular iron depletion.⁵⁵

Several human studies point to the importance of the cell-mediated immune (CMI) response to ocular *Ct* infection. Biopsies from children with active trachoma show heavy cellular infiltrates with both CD4+ and CD8+ lymphocytes.³⁶ Children who resolved active disease (associated with infection) had stronger peripheral blood lymphoproliferative responses to *Ct* antigens compared to children with persistent disease, Table S4.⁵⁶ Gene expression studies have shown increased expression of *IFN γ* , *IL12p40*, *Perforin*, *IDO*, *IL4*, *IL10* and forkhead box p3 (*FOXP3*) in infection and/or disease, with levels generally being highest if both were present.^{28, 43, 44, 57} Increased expression of *IFN γ* , *IL10* and *FOXP3* has been associated with longer episodes of infection.⁵⁸ A recent study using *Ct* elementary bodies (EB) to stimulate PBMC in individuals exposed to ocular infection showed that NK cells were a major source of IFN γ .⁴⁸

Protective immunity to *C. trachomatis*

Human volunteer studies of trachoma have provided some evidence that a partial, protective immune response develops following ocular *Ct* infection.⁵⁹⁻⁶¹ Conjunctival inoculation with *Ct* led to a characteristic follicular / papillary conjunctivitis in nearly all volunteers after 2-14 days. However, when previously infected individuals were re-challenged with the same serovar there was an attenuated clinical response with reduced re-isolation rates. This apparent immunity to re-infection was serovar-specific: if a different serovar was used then disease and infection levels were similar to the primary infection. Presumed complete immunity after primary infection, in which no clinical signs developed and the organism was never detected, despite multiple re-challenge inoculations, was rare. Despite the concerns over the induction of presumed delayed type hypersensitivity (DTH), the trachoma vaccine trials in the 1960s did demonstrate short-term, serovar-specific immunity could be induced.⁶² ⁶³ Trachoma models in non-human primates also showed that, after recovery from a primary infection, on secondary challenge there was less severe disease which resolved more rapidly.²⁵ With regular weekly re-inoculations it also became progressively more difficult to detect the organism, suggesting the development of protective immunity.

A longitudinal study in which a cohort from a trachoma endemic population was regularly assessed for disease and infection, found the duration of both shortened considerably with increasing age.³⁴ This could be a result of an increasingly effective protective immune response developing with repeated exposure to *Ct*. The clinical manifestations also

appeared to be modulated: adults experienced short bursts of intense disease and children more prolonged episodes of follicular disease.³⁴

Acquired T-cell dependent cell-mediated immune responses, as outlined above, probably contribute to protection against or more rapid resolution of re-infection, although direct evidence for this from human trachoma studies is limited. Fading immunity in animal models is correlated with a reduction in CD4+ T-cells, which leave the genital tract following resolution of infection.⁶⁴ A study of the incidence of genital tract infection amongst sex workers in Nairobi, Kenya, found that IFN γ production by PBMC stimulated with chlamydial heat shock protein 60 (cHsp60) was associated with reduced risk of re-infection compared to women without such responses.⁶⁵

The importance of humoral immunity to *Ct* is unclear. Several human studies have detected anti-chlamydial antibodies in tear fluid and serum (Table S5).⁶⁶⁻⁶⁹ However, in a longitudinal study, anti-chlamydial IgG in tears from clinically normal individuals was associated with an increased incidence of subsequently developing clinically active trachoma.⁷⁰ In contrast, there was an opposite (non-significant) trend with anti-chlamydial IgA. Individuals with conjunctival scarring have been found to have significantly higher plasma titres of anti-chlamydial IgG and lower titres of IgA compared with normal controls.⁷¹ However, a consistent picture has not emerged from these studies. The presence of antibodies may simply indicate previous infection and may not necessarily be protective.

Various animal models of genital tract infection have yielded a mixed pattern of results on the relative importance of the humoral response. Some have shown that B-cell deficient mice can resolve a primary chlamydial infection and are only slightly delayed in clearing secondary infections, compared to control mice.^{72, 73} However, other studies found that B-cell deficient mice that also had their CD4+ cells depleted were completely unable to control secondary infection, whereas mice depleted of CD4+ cells alone only showed slight delay in clearing secondary infection.^{74, 75} In addition, transfer of monoclonal antibodies to *Ct* major outer membrane protein (MOMP) and LPS into B-cell deficient, CD4+ T-cell depleted mice restored the ability of these mice to control secondary infection.⁷⁶ Antibodies to polymorphic membrane protein D (PmpD) have also been shown to be neutralising *in vitro*.⁷⁷ However, whether similar protective effects occur in human ocular infection is unknown.

Immunopathogenesis of trachoma

In 1974 Silverstein proposed that tissue damage and scarring sequelae in trachoma are the result of a chronic, immunopathogenic response to an otherwise seemingly innocuous,

superficial infection.⁷⁸ He observed that *Ct* infection itself is limited to a small minority of epithelial cells and is not particularly cytopathic, with cells accommodating large chlamydial inclusion bodies. The infection can be quite prolonged suggesting that the immune response is relatively inefficient or that *Ct* is effective at avoiding immune responses. At the tissue level the inflammatory infiltrate and subsequent scarring is in the conjunctival stroma, below the level of the epithelium, where the infection is located.

A key clinical observation pointing to the immunopathogenic nature of trachoma is that visible conjunctival inflammation is frequently found in the absence of detectable *Ct*.^{6, 24, 28, 43, 79} In longitudinal studies discrete episodes of active disease persist long after the associated initiating infectious episode has resolved.³⁴ In one trachoma vaccine trial the incidence of trachoma was higher in the vaccinated group and another reported a possible increase in disease severity.^{63, 80}

Monkey models of *Ct* infection support the importance of immunopathology in trachoma.²⁵ Treatment of infected animals with corticosteroids markedly reduced the inflammation and in monkey vaccine studies re-challenge was associated with more severe inflammatory disease and scarring complications.^{81, 82}

Several theories for the pathogenesis and scarring caused by chlamydial infection have been proposed, none of which entirely explain the observed data. These broadly divide into two paradigms: the “cellular” paradigm in which the response of the epithelial cell layer is central and sufficient to explain the pathology and the “immunological” paradigm in which cell mediated immunity causing either DTH or autoimmune mimicry explains disease pathology.^{41, 52, 78, 83} These processes are not mutually exclusive and may both contribute.

The immunological paradigm

The immunological paradigm suggests that tissue damage and fibrosis in chlamydia related disease results from CMI responses against specific chlamydial antigens. It argues that specific T-cell responses, which are important in clearing *Ct* infection, also cause collateral tissue damage. There are two major lines of investigation that have provided a degree of support for this hypothesis.

Delayed-type hypersensitivity and cHsp60

During early trachoma vaccine studies on non-human primates it was observed that the disease phenotype could be more severe on re-challenge. This led the investigators to propose that a DTH reaction to chlamydial antigens was responsible for the disease.²⁶

Subsequently, in a guinea pig model of ocular infection, a *Ct* antigen, extracted using the detergent triton X-100, was able to provoke an inflammatory reaction in animals previously infected with *Ct*.⁸⁴ The active component was identified as the 57kDa protein, cHsp60.⁸⁵ Similar experiments were conducted in cynomolgus monkeys, with comparable results.⁸⁶ There was some concern that the conjunctival inflammatory response observed in these monkeys might have been partly provoked by the triton X-100 detergent itself, as repeated installation of the buffer alone also led to significant inflammation. However, when experiments were repeated with recombinant cHsp60, inflammation was provoked in guinea pig eyes and in the subcutaneous abdominal salpingitis pocket model in monkeys.^{85, 87, 88} However, initial priming with the triton extract in monkey eyes or recombinant cHsp60 in a guinea pig model, rather than with viable *Ct*, does not result in inflammation following re-challenge, suggesting that the antigen alone is insufficient to sensitise the animals.^{86, 89}

Human studies on cHsp60 have delivered equivocal results on its role in pathogenesis. Antibodies to cHsp60 are associated with trachomatous scarring, pelvic inflammatory disease and tubal infertility.⁹⁰⁻⁹² It is unclear, however, whether these antibodies have a pathogenic role or are simply markers of previous infection. Other studies have suggested that immune responses to cHsp60 may even be protective; examination of PBMC proliferation responses to chlamydial antigens in trachoma endemic populations found that conjunctival scarring was associated with weaker responses to cHsp60, while the resolution of infection was associated with increased responses.^{56, 71} Also, as noted above, IFN γ production by PBMC stimulated with cHsp60 is associated with protection against subsequent genital tract re-infection.⁶⁵

Differential activity of CD4+ T-cell subsets

A Th2 dominated response has been linked to the development of scarring complications in some infectious diseases such as schistosomiasis.⁹³ However, there is little evidence for a similar role in trachoma. Conjunctival gene expression profiling in children found an increase in both Th1 and Th2 cytokine expression including IFN γ , *IL12B* and *IL4*.^{28, 43} Adults with scarring, compared to controls, have reduced lymphoproliferative responses and IFN γ production in response to stimulation with *Ct* EB and some antigens, but an increased number of IL-4 producing cells in response to cHsp60.^{71, 94} This seems to support the hypothesis that individuals with scarring may have weaker Th1 cell-mediated responses to *Ct*, leading to prolonged infection and inflammation possibly as a result of Th2 responses with pro-fibrotic effects. However, two recent studies comparing the conjunctival gene expression transcriptome by microarray in subjects with scarring trachoma and matched controls found no evidence for Th2 responses and only indirect evidence of increased expression of genes associated with Th1 cells.^{45, 95} Furthermore, the expression of *IL13* was

lower in individuals with established conjunctival scarring and inflammation, compared to healthy controls. Additionally, Th2 cytokine levels in tear fluid were not increased in scarred individuals, Table S6.⁹⁶

The role other types of CD4+ T-cells play in trachoma pathogenesis has received little attention. One study showed that the expression of *FOXP3*, a marker of regulatory T-cell activity, was increased in children who had clinical signs of trachoma but in whom infection had resolved.⁵⁷ However, whether this role is beneficial, by dampening the immune response and subsequent tissue damage once infection has been cleared, or detrimental, by impeding removal of infectious agent, is unknown. The expression of *IL17A*, suggestive of Th17 cell activity, has been found to be significantly increased in active trachoma (discussed below).^{44, 97, 98}

The cellular paradigm

In the cellular paradigm tissue damage and scarring are driven by infected epithelial cells, which serve as early innate system responders. Pro-inflammatory chemokines, cytokines and growth factors produced by *Ct* infected epithelial cells initiate the recruitment of inflammatory immune cells (neutrophils, macrophages and NK cells). Infected epithelial cells express multiple factors, which also promote the CMI response and are chemotactic for lymphocytes. The cellular paradigm does not differentiate between damage resulting from professional innate immune cells, such as neutrophils and monocytes, and adaptive immune cells.⁴¹ However, it does propose that chronic inflammatory responses, tissue damage and fibrosis in *Ct* related disease is largely driven from the epithelium rather than by DTH. There is now increasing evidence that innate immune responses are a prominent feature of responses in trachoma and likely interact with the adaptive response.

Animal studies have shown an influx of neutrophils into genital tract tissue following *Ct* inoculation.⁹⁹ Neutrophils were not required to clear infection the intensity of the neutrophil infiltrate was related to subsequent fibrotic sequelae.¹⁰⁰ A guinea pig model of trachoma examining neutrophil depletion showed no affect on the burden of infection, however, there was less clinical inflammation and fewer mucosal erosions histologically.⁴⁷ In this study adaptive immune responses were also affected with reduced CD4+ and CD8+ cell recruitment and changes in the expression of various cytokines and chemokines such as decreased *CCL5* (T-cell chemokine). This study only evaluated animals for up to 7 days and once again caution needs to be exercised in extrapolating results of animal models to humans. However, it does provide an insight into the role of innate immunity in trachoma

pathogenesis, and how this might partly be mediated through its interaction with adaptive responses.

The production of pro-inflammatory cytokines in response to *Ct* infection is mediated in part through recognition of pathogen-associated molecular patterns (PAMP) by Toll-like receptors (TLR) and other pattern recognition receptors (PRR).¹⁰¹ While TLR2 knockout (KO) mice were able to eradicate infection in a similar manner to control mice they had reduced TNF α and CXCL2.¹⁰² Of particular note is the observation that TLR2-KO mice also had a marked reduction in late oviduct pathology. Human genetic studies on TLR polymorphisms have yet to identify significant associations with chlamydial diseases.¹⁰³⁻¹⁰⁵

In children with active trachoma IL-1 has been found in the surface epithelial cells of cases, but not controls.⁴² This might promote recruitment of innate immune cells, including neutrophils and macrophages, which are indeed seen in large numbers in the sub-epithelial substantia propria of children with active trachoma.^{35, 36} *In vivo* confocal microscopy of the conjunctival surface has shown that most of the cellular infiltrate in active and scarring trachoma is concentrated just below the epithelium, supporting the importance of the epithelial cell layer as a source of chemotactic factors.¹⁰⁶

For both active and scarring trachoma conjunctival transcriptome studies found prominent innate immune responses.^{44, 45} In children with active disease and / or *Ct* infection there was marked enrichment of neutrophil and NK cell related transcripts.⁴⁴ In addition, several PRR and chemokines including the neutrophil chemotactic factor *CXCL5* were increased.⁹⁸ In adults with scarring and little *Ct* infection there was also strong evidence for an innate immune response, with some of the most abundant increases in gene expression found for pro-inflammatory mediators such as Psoriasisin-1 (*S100A7*), *IL1B* and *CXCL5*.⁴⁵ These factors induce neutrophil chemotaxis, and were particularly increased in inflamed cases. The importance of the chemokine response in trachoma is further supported by the finding that defined SNP-haplotypes in *IL8* were associated with scarring.²²

TNF α , while not specific to innate immune processes, is a key cytokine in acute inflammation and has been associated with scarring trachoma in several studies: a SNP in the *TNFA* promoter region, elevated levels in tear fluid, and increased secretion from peripheral blood mononuclear cells (PBMC) from scarred subjects stimulated with EBs.^{14, 18, 20, 96} Increased transcript levels of *TNFA*, as well as *IL1B*, have also been associated with active disease/infection.^{28, 43, 107}

There is increasing evidence that non-chlamydial bacterial infection could play a role in the pathogenesis of trachoma, and that this is likely to be through innate mechanisms. While infection with *Ct* is often found in children with active trachoma, it is only rarely identified in adults, as discussed above. Infection with bacteria other than *Ct*, however, is more common in individuals with conjunctival scarring, trichiasis or its recurrence after surgery, compared to controls, and it is also more common in active disease.^{31, 32, 108-110} This non-chlamydial bacterial infection is associated with elevated expression of *IL1B* and matrix metalloproteinases (*MMP*) 1 and 9 a year after trichiasis surgery, and with a number of pro-inflammatory cytokines in children.^{98, 111}

A possible role for IL-17A

Neither the immunological nor cellular paradigms completely accommodate the published data regarding trachoma pathogenesis. Initial studies suggest that IL17A may be important in trachoma pathogenesis.^{44, 98} IL17A is the signature cytokine of Th17 cells, a CD4+ T-cell population which act in an antigen-specific manner.¹¹² However, it is also produced by several other cell types, notably innate immune cells ($\gamma\delta$ T-cells, NK cells, macrophages, neutrophils) and it can contribute to innate inflammatory responses.^{113, 114} The IL-17A receptor is found on various cell types including dendritic cells, lymphocytes, epithelial cells and fibroblasts.¹¹⁵ IL17A is pro-inflammatory and plays an important role in host immunity to extracellular and some intracellular pathogens.¹¹⁶ Recently, it has become apparent that IL17A may contribute to fibrosis through several mechanisms including epithelial-mesenchymal transition (EMT) and increased collagen production in a TGF β 1-dependant manner.¹¹⁷ Infection of mice with *Mycobacterium tuberculosis* followed by repeated BCG injections led to an IL17A dominated response, which was refractory to regulation by IFN γ .¹¹⁸ This led to extensive lung tissue damage by neutrophils that could be reduced by anti-IL17A antibody. This may have parallels with trachoma, which would have major implications for our understanding of the immunopathology and vaccine design.

Tissue damage and fibrogenesis in trachoma

Neutrophil infiltration appears important in causing tissue damage; they produce toxic reactive oxygen and nitrogen species and animal models of genital tract infection have suggested that these may result in damage to host tissue.¹¹⁹ Neutrophils may also mediate tissue damage through the production of MMPs. The MMPs constitute a group of more than 25 endopeptidases which are capable of degrading extracellular matrix proteins and are important in ocular surface disease.¹²⁰ Following tissue injury they degrade the basement membrane thereby aiding the recruitment of inflammatory cells.¹²¹ They have also been

shown to have wide-ranging effects on inflammatory and immune processes such as modulating chemokine activity and activation of TGF β , IL-1 β and TNF α .¹²² While MMPs are required for normal tissue homeostasis some have also been associated with tissue damage in trachoma. MMP9 in particular has been implicated in the pathogenesis of *Ct* infections: it is part of the neutrophil lysosome and may mediate epithelial dissolution associated with infection through degradation of type IV collagen; MMP9 gene knockout mice had a reduced rate of scarring sequelae in a model of genital tract infection; elevated MMP9 is found in active and scarring trachoma; and scarring trachoma is associated with a coding SNP that is adjacent to the active binding site of the MMP9 enzyme^{17, 43, 119, 123, 124} Scarring trachoma is also associated with elevated *MMP7* and *MMP12* expression,^{45, 95} and recurrence of trichiasis after surgery is associated with a reduced *MMP1/TIMP1* transcript ratio.¹¹¹

Fibrosis develops when the normal tissue architecture is replaced by excessive connective tissue through the abnormal accumulation of extracellular-matrix components. Macrophages are key effector cells in this process and studies on patients with trachoma have shown that they produce a number of pro-fibrogenic mediators including TGF- β , PDGF, CTGF (a profibrotic downstream mediator of TGF- β) and bFGF (stimulates fibroblasts and endothelial cells and is involved in tissue remodelling).^{42, 98, 125} Chemokines have been shown to act as fibrogenic mediators, in particular, the CC- and CXC-chemokine families, and various members of these families have been associated with scarring including the pro-fibrogenic CCL18.^{45, 93, 96-98, 121} This pro-fibrotic milieu results in the production and deposition of inappropriate ECM proteins, including collagen, by fibroblasts and the laying down of scar tissue. The role EMT may play in trachoma has so far not been examined, but this may prove to be an important area of research in the future.

Programmatic implications

Trachoma is still endemic in over 50 countries and current trachoma control strategies face major obstacles. With regards to mass antibiotic distribution the coverage levels in practice are often disappointing; there are concerns that mass distribution of azithromycin may lead to an increase in antibiotic resistance; and the “arrested immunity hypothesis” suggests that shortening the duration of chlamydial infection with treatment results in population-wide reductions in protective immunity.¹²⁶⁻¹²⁸ The number of people estimated to have sight-threatening trichiasis has shown little reduction since 1991 and many countries have very large backlogs of people requiring corrective lid surgery.² As well as being potentially the most effective way of reducing blindness from trachoma, a chlamydial vaccine could be very cost effective and have major benefits for genital tract disease caused by *Ct*.^{129, 130}

The human trachoma vaccine studies in the 1960s using inactivated whole EB tended to show only partial, short-term, serovar-specific protection which was little better than natural immunity and may even have resulted in more severe disease.^{62, 63, 80, 131-134} Understanding the immunobiology of trachoma, including both how infection is successfully cleared and its pathogenesis, is important in the rational design of an effective vaccine which avoids immunopathology. Understanding the immunology of trachoma could also facilitate the development of interventions that block scarring progression, which could be of benefit in other ocular surface scarring diseases.

Conclusion

The immunology and pathogenesis of trachoma is a challenging but fascinating area of study. Recent data has revealed the importance of the human innate immune response in both active disease and the pathogenesis of scarring. The role of IL17A in inflammatory pathology in trachoma requires further investigation. There is still a pressing need for further research to better understand this ancient blinding disease. The development of new interventions, especially a vaccine, would help to overcome the many obstacles that lie in the way of eliminating blinding trachoma.

Contributors

MJB conceived this Review. VHH drafted the manuscript. MJB and MJH critically appraised and revised the manuscript.

Acknowledgements

VHH is supported by the British Council for Prevention of Blindness. MJH is supported by the Wellcome Trust (Grant Number 093368/Z/10/Z). MJB is supported by the Wellcome Trust (Grant Number 080741/Z/06/Z).

Table S1: Human trachoma genetic studies

Title	Study summary	Sample size / Participants	Location	Key findings	Comments
HLA class I and II polymorphisms and trachomatous scarring in a Ct endemic population ¹²	Case-control study of scarred subjects and controls, measuring HLA class I and II polymorphisms using serotyping and PCR. Chlamydial antibody titres were measured using MIF.	153 cases and 153 controls.	The Gambia	Scarring was associated with increased HLA-A28, specifically, the allele subtype A*6802.	Uncorrected p-values presented for serological testing of HLA class I antigens.
HLA antigens in Omanis with blinding trachoma: markers for disease susceptibility and resistance ¹³	Case-control study of subjects with severe scarring and controls, measuring HLA class I and II polymorphisms using serotyping and PCR.	50 cases (TT and CO) and 100 controls.	Oman	Scarring was associated with increased HLA-A32, DR2, DR16 and DQ1, and with decreased HLA-A30, DR4, DR7, DR5 and DR53.	Controls were not matched for age or risk of trachoma (included university students and blood donors). Odds ratios would have been more appropriate to present than risk ratios.
Scarring trachoma is associated with polymorphism in the TNF- α gene promoter and with elevated TNF- α levels in tear fluid ¹⁴	Case-control study of subjects with scarring and controls analysing SNPs of TNF- α using PCR, and HLA polymorphisms using serotyping. TNF- α level in tear fluid measured.	153 cases and 153 controls.	The Gambia	Scarring independently associated with increased TNF- α -308A and HLA-A*6802 (which were themselves also associated). Elevated tear TNF- α was associated with scarring and infection, but not the SNPs.	Same subjects as previous study in The Gambia. ¹²
Polymorphisms in candidate genes and risk of scarring trachoma in a Ct endemic population ¹⁵	Case-control study of cases with scarring and controls, analysing SNPs of IL-4, IL-10, TNF- α and MBP using PCR.	238 cases and 239 controls.	The Gambia	In the Mandinka ethnic sub-group scarring was associated with increased IL-10-1082G.	TNF- α -308A not analysed. Overlap of subjects with previous study. ¹²
Risk of trachomatous scarring and trichiasis in Gambians varies with SNP haplotypes at the INF- γ and IL-10 loci ¹⁶	Case-control study of cases with scarring and controls, analysing SNPs of INF- α and IL-10 using PCR. The potential effect of LD was examined by analysing SNP haplotypes.	344 cases with TS and 344 controls; 307 cases with TT and 307 controls.	The Gambia	Scarring was associated with increased IFN- γ +3234C (TS only), IL-10-3575A and IL-10+5009G. There was a stronger association with TT compared to TS cases for the IL-10 alleles. SNP haplotypes were also associated with scarring.	Overlap of subjects with previous study. ¹⁵
A coding polymorphism in MMP-9 reduces risk of scarring sequelae of ocular Ct infection ¹⁷	Case-control study of cases with scarring and controls, analysing for SNPs and SNP haplotypes of MMP-9 using PCR.	344 cases with TS and 344 controls; 307 cases with TT and 307 controls.	The Gambia	Scarring was associated with decreased MMP-9-Q279RG, with a stronger association for TT compared to TS cases. The association was only with the heterozygous genotype. Haplotype analysis supported a direct association with the SNP.	The SNP adjacent to the active site of the enzyme, potentially having a direct effect on function. Although a coding SNP, direct evidence of a functional difference not yet proven. Same subjects as previous study ¹⁶

Genetic variation at the TNF locus and the risk of severe sequelae of ocular <i>Ct</i> infection in Gambians ¹⁶	Case-control study of cases with scarring and controls, analysing SNPs and SNP haplotypes of TNF and neighbouring <i>I_kBL</i> and <i>LTA</i> alleles using PCR	344 cases with TS and 344 controls; 307 cases with TT and 307 controls.	The Gambia	Scarring in TT cases was associated with increased TNF- α -308A, <i>I_kBL</i> -63T and <i>LTA</i> +252G. The TNF- α association was only with the heterozygous genotype.	Same subjects as previous study. ¹⁶ A weaker association for TNF- α -308A was found than in the earlier study despite a larger sample size.
Susceptibility to sequelae of human ocular chlamydial infection associated with allelic variation in IL10 cis-regulation ¹⁹	Relative allelic expression of IL-10 transcript levels were measured in individuals with active disease who were heterozygous for an IL-10 haplotype previously shown to be associated with scarring.	23 children with active disease	The Gambia	The haplotype associated with scarring generated relatively more IL-10 transcripts.	
Identification of novel SNPs in inflammatory genes as risk factors associated with TT ²⁰	Case-control study analysing for SNPs in IL-1 α , IL-1 β , IL-4, IL-4R, IL-5R α , IL-6, IL-9, IL-10, IL-13, ADRB-2, C3, C5, CCR-2, CCR-3, CCR-5, CD14, CSF-2, CTLA-4, ICAM-1, FCER-1 β , LTA, LTC-4S, NOS-2A, NOS-3, SDF-1, SELE, SELP, SCYA-11, TCF-7, TGF-1 β , TNF- α , UGB, VCAM-1 and VDR.	135 cases with TT and 232 controls.	Nepal	After adjusting for age, sex, inflammation and <i>Ct</i> infection: scarring in TT cases was associated with increased IL-9+T13MC, TNF- α -308G, <i>LTA</i> -252G and VCAM1-1594T (most of which were for heterozygous genotypes).	Unclear subject selection with mean age of active cases being 35 years. The results for active cases and TS cases are not shown or discussed. The p-value was not adjusted for multiple testing.
HLA-B, DRB1, and DQB1 alleles associated with disease and protection of trachoma endemic villagers ²¹	Case-control study measuring HLA-DRB1, DQB1 and B polymorphisms in cases and controls using PCR.	21 older girls and women with TT (+/- TT) and 77 controls; 11 children with persistent infection and 11 controls.	Tanzania	Scarring was associated with increased HLA-B*7 and HLA-B*8 and with decreased DR-B*11.	12 of the "controls" in the TT study had TF. Buccal swabs used for DNA collection so that low resolution HLA typing only was possible. The p-value was not adjusted for multiple testing.
Innate immunity in ocular <i>Ct</i> infection: contribution of IL8 and CSF2 gene variants to risk of trachomatous scarring in Gambians ²²	Case-control study using LD to measure risk associations across chromosomal regions including the IL-8 and CSF-2 genes.	344 cases with TS and 344 controls; 307 cases with TT and 307 controls.	The Gambia	Scarring was associated with variation at the IL-8 and CSF-2 loci.	TS and TT subjects divided between different studies. The p-value was not adjusted for multiple testing.
Host genetic contribution to the cellular immune response to <i>Ct</i> : heritability estimate from a Gambian twin study ²³	Twin study measuring lymphoproliferative responses to <i>Ct</i> EBs	19 monozygotic and 45 dizygotic twin pairs.	The Gambia	Genetic factors were estimated to contribute to 39% of the variation in responses.	The p-value of the heritability estimate was of borderline significance at 0.07.

Table S2: Histology and immunohistochemistry studies using human tarsal conjunctival biopsies

Title	Study summary	Sample size / Participants	Location	Key findings	Comments
The pathology of trachoma in a black South African population ³⁵	Descriptive case series of active and scarring trachoma.	33 cases of varying ages.	South Africa	A mixed inflammatory cell infiltrate, especially in children. Older adults also had a marked infiltrate, mainly of plasma cells.	
Conjunctival lymphocyte subsets in trachoma ¹³⁵	Case-control study of adults with TT and (unmatched) controls measuring T cell subtypes, B cells and IgG/IgM/IgA.	21 cases (11 with inflammation) and 3 controls.	Saudi Arabia	Cases had increased T cells of different subtypes. Inflamed cases had increased B cells. Antibodies were found in all cases (IgM only if inflamed).	No demographic details.
Immunopathology of trachomatous conjunctivitis ³⁶	Descriptive case series of children with active trachoma.	8 cases.	Egypt	Epithelial hyperplasia and HLA-DR expression. A mixed inflammatory cell infiltrate of the epithelium and stroma. Follicles composed largely of B cells. Plasma cells predominantly IgA, some IgG also.	
T cells and trachoma. Their role in cicatricial disease ³⁹	Case-control study of adults with TT and (unmatched) controls.	14 cases (3 with inflammation) and 3 controls.	USA	A chronic inflammatory cell infiltrate was seen in cases, mainly lymphocytes. T cells (consisting of CD4+ and CD8+) outnumbered B cells.	Unclear whether cases a controls comparable - no demographic details; cor subjects all had fatal systemic disease.
The histopathology and mechanism of entropion in patients with trachoma ³⁸	Descriptive case series of adults with TT.	11 cases (without inflammation).	Saudi Arabia	Atrophic epithelium; compact scar tissue with parallel fibres; loss of goblet cells.	
Immunopathogenesis of conjunctival scarring in trachoma ⁴²	Case-control study of children with active trachoma and controls looking for IL-1 α , IL-1 β , TNF- α and PDGF.	9 cases and 4 controls.	Saudi Arabia	Epithelial cells expressed IL-1 α and IL-1 β . Macrophages expressed IL-1 α , IL-1 β , TNF- α and PDGF. No cytokines detected in controls.	
Collagen content and types in trachomatous conjunctivitis ¹³⁶ & An immunohistochemical study of collagens in trachoma and vernal keratoconjunctivitis ¹³⁷	Case-control studies of different stages of trachoma analysing collagen types.	9 children with active disease and 4 controls; 9 adults with scarring and 5 controls.	Saudi Arabia	Active disease showed increased types I, III and IV collagen, and some type V collagen (not seen in controls). Scarring showed marked deposition of types IV and V collagen.	Overlap of patients with previous study. ⁴²
A survey of trachoma: the histopathology and the mechanism of progressive cicatrization	Descriptive case series of different stages of trachoma.	5 children with active disease; 21 adults with TT.	Turkey	Active disease showed lymphoid follicles with surrounding mixed inflammatory cell infiltrate. Scarring showed epithelial squamous metaplasia/atrophy and collagen scar tissue.	

of eyelid tissues ³⁷					
Expression of gelatinase B (MMP-9) in trachomatous conjunctivitis ¹²⁴	Case-control study of children with active trachoma and controls using immunohistochemistry to look for MMP-9 and CD68 and zymography for MMP-9.	6 active trachoma cases and 7 controls.	Saudi Arabia	MMP-9 found in macrophages in all cases but no controls. Cases also had more MMP-9 with zymography.	
Expression of growth factors in the conjunctiva from patients with active trachoma ¹²⁵	Case-control study of children with active trachoma and control children, using mono/poly-clonal antibodies for CTGF, bFGF, VEGF and tenascin.	6 active trachoma cases and 6 controls	Saudi Arabia	Trachomatous epithelium had upregulated VEGF, and macrophages had increased expression of CTGF and bFGF. Cases also had increased CD105 and tenascin.	Overlap of patients with previous study. ¹²⁴

Table S3: Quantitative gene expression and microarray studies from human tarsal conjunctival swab samples

Title	Study summary	Sample size / Participants	Location	Key findings	Comments
Evidence for a predominantly proinflammatory conjunctival cytokine response in individuals with trachoma ¹⁰⁷	Cross-sectional study measuring INF- γ , IL-1 β , IL-2, IL-4, IL-5, IL-6, IL-10, IL-12p40, TGF- β 1, TNF- α and CD3- δ .	50 people of varying ages and disease status.	Tanzania	Infection was associated with upregulated INF- γ , IL-1 β , IL-2, TGF- β 1 and TNF- α . Active disease was associated with upregulated INF- γ , IL-2, IL-12p40, TGF- β 1 and TNF- α . Scarring was associated with upregulated TGF- β 1.	β -actin used as housekeeping gene. TGF- β 1 is post-transcriptionally regulated and subsequent studies have not found it to be associated with disease.
Cytokine and fibrogenic gene expression in the conjunctivas of subjects from a Gambian community where trachoma is endemic ⁴³	Population based cross-sectional study measuring INF- γ , IL-1 β , IL-2, IL-4, IL-10, IL-12p35, IL-12p40, TGF- β 2, TNF- α , MMP-1, MMP-9, perforin and Collagen I.	248 people of varying ages, 42 of whom had active trachoma, 17 had Ct infection.	The Gambia	Active disease without Ct infection associated with upregulated IL-1 β , IL-10, TNF- α , and MMP-9. Ct infection (with or without disease) was additionally associated with upregulated INF- γ , IL-12p40, perforin and IL-4.	No comment made on individuals with scarring. TGF- β 1 levels too low to measure. TGF- β 2 was constitutively expressed across all clinical categories.
Temporal cytokine gene expression patterns in subjects with trachoma identify distinct conjunctival responses associated with infection ²⁸	Longitudinal study of children, with examination every 2 weeks for 24 weeks including swabs for measuring INF- γ , IL-1 β , IL-10, IL-12p40 and TNF- α .	16 children: at baseline 9 had active disease, 7 were clinically normal.	The Gambia	Infection without disease associated with upregulated INF- γ , IL-1 β , IL-12p40. Infection with disease associated with greater upregulation of all cytokines.	Simplified WHO grading system used despite small sample size.
Conjunctival FOXP3 expression in trachoma: do regulatory T cells have a role in human ocular chlamydia trachomatis infection? ⁵⁷	Cross-sectional study of children measuring INF- γ , IDO, IL-10 and FOXP3.	345 children: 74 with active disease, 20 with scarring, 251 clinically normal.	The Gambia	Infection without disease associated with upregulated INF- γ and IDO. FOXP3 upregulated in disease without infection. Infection with disease was associated with greater upregulation of INF- γ , IDO, IL-10 and FOXP3.	
Conjunctival expression of MMP and proinflammatory cytokine genes after trichiasis surgery ¹¹¹	Longitudinal study measuring IL-1 β , TNF- α , MMP-1, MMP-2, MMP-9, TIMP-1, and TIMP-2 a year after TT surgery.	240 cases	The Gambia	Recurrent TT associated with reduced MMP-1/TIMP-1 ratio. Inflammation associated with upregulated IL-1 β , TIMP-2 and, if non-Ct bacterial infection also present, with TNF- α and MMP-9.	
Pathway-focused arrays reveal increased MMP-7 transcription in trachomatous trichiasis ⁹⁵	Case-control study of adults with TT and controls involving microarray experiments focused on ECM and adhesion molecules and human Th1/Th2/Th3 cells. Confirmatory qPCR	11 cases and 11 controls. N=94 for qPCR study.	The Gambia	MMP-7 upregulation was the only consistent result between array and qPCR results. No evidence for Th1/Th2/Th3 polarization was found.	

gene expression of selected targets performed in an independent case-control study. MMP-7 level was measured.			
Human conjunctival transcriptome analysis reveals the prominence of innate defense in <i>Ct</i> infection ⁴⁴	Case-control study of children with active disease and controls involving transcriptome-wide microarray experiments. Confirmatory qPCR gene expression of selected targets was performed in an independent case-control study.	20 cases with active disease and infection; 20 cases with active disease without infection; 20 controls.	The Gambia Gene enrichment showed the top-ranking gene ontology terms for disease/infection were typical of immune system activation, epithelial cell integrity, apoptosis, cell death, leukocyte migration and IL-receptor activity. Quantitative PCR results were consistent with the array data.
Conjunctival transcriptome in scarring trachoma ⁴⁵	Case-control study of adults with TT and control subjects involving transcriptome-wide microarray experiments. Confirmatory qPCR gene expression of selected targets was performed in an independent case-control study.	Microarray analysis: 15 TT without inflammation; 13 TT with inflammation; 14 controls. qPCR study: 386 TT cases, 386 controls	Ethiopia Gene enrichment results were consistent with squamous metaplasia of the epithelium, an activated innate immune response especially when inflammation was present (IL1B, CXCL5, S100A7), cytoskeletal remodelling (MMP7, MMP9, MMP12), limited Th1 response (INDO, NOS2A), and no evidence for a Th2 response. Quantitative PCR results were consistent with the array data.
Active trachoma is associated with increased conjunctival expression of IL17A and pro-fibrotic cytokines ⁹⁸	Population based cross-sectional study measuring S100A7, IL1B, IL17A, IL23A, CXCL5, CCL18, TLR2, NLRP3, KLRD1, CTGF and MMP9.	470 children.	Tanzania Active disease was associated with upregulated S100A7, IL17A, CCL18, CXCL5 and CTGF. Non-chlamydial bacterial infection was associated with upregulated IL17A, CXCL5, CCL18 and KLRD1.

Table S4: Lymphoproliferative and cytokine studies using human PBMCs

Title	Study summary	Sample size / Participants	Location	Key findings	Comments
Conjunctival scarring in trachoma is associated with depressed cell-mediated immune responses to chlamydial antigens ⁷¹	Case-control study of cases with scarring and controls, measuring lymphoproliferative responses and INF- γ production in response to Ct EB, MOMP and cHsp60. Ct LPS was detected by ELISA and Ct DNA detected by PCR.	29 TS cases (uninflamed) and 29 controls	The Gambia	Cases had reduced proliferative responses to all 3 Ct antigens, a small reduction in INF- γ secretion and more Ct infection.	
Subjects recovering from human ocular chlamydial infection have enhanced lymphoproliferative responses to chlamydial antigens compared with those of persistently diseased controls ⁵⁶	Longitudinal study following children with active trachoma for 6 months, examined every 2-4 weeks. Lymphoproliferative responses and INF- γ production to Ct EB, MOMP and cHSP60 measured after 4-5 months. Ct LPS was detected by IDEIA.	47 active trachoma cases; 26 had persistent clinical disease throughout the study period; 21 resolved disease.	The Gambia	Children who resolved disease had stronger proliferative responses to all Ct antigens. No difference in INF- γ production. Persistent disease was associated with Ct infection.	
Th1/Th2 profiles of peripheral blood mononuclear cells; responses to antigens of Ct in subjects with severe trachomatous scarring ⁹⁴	Case-control study of cases with scarring and controls, measuring lymphoproliferative responses, INF- γ production and gene expression (INF- γ , IL-4 and IL-10) in response to Ct EBs, MOMP and cHsp60. Ct LPS was detected by ELISA.	30 TS cases (uninflamed) and 30 controls.	The Gambia	cHsp60 caused increased IL-4 producing cells in cases and increased INF- γ production in controls. MOMP caused increased INF- γ producing cells in controls.	
Systemic effector and regulatory immune responses to chlamydial antigens in trachomatous trichiasis ⁴⁸	Case-control study of cases with scarring and controls, measuring lymphoproliferative responses and production of IFN γ , TNF α , IL5, IL10, IL12p40, and IL13 and also cellular source of IFN γ , IL10, FOXP3, CTLA4, GITR, in response to Ct EBs, MOMP, PmpD, PmpG and Omp2.	42 TT cases and 42 controls (17 pairs analysed for cellular source; 15 pairs analysed for NK cell markers).	The Gambia	No significant differences in lymphoproliferation, cytokine levels or cell types between cases and controls detected. NK cells identified to be a major, early source of IFN γ , which increased with age.	

Table S5: Antibody / B cell responses from human serum, conjunctival and tear samples

Title	Study summary	Sample size / Participants	Location	Key findings	Comments
Fluorescent antibodies in the fluid of the conjunctival sac of trachoma patients ⁶⁶	Case-control study of children with active disease and controls measuring antibodies to TRIC in conjunctival fluid and (in a subset only) serum.	21 cases and 22 controls.	Israel	10 cases had antibodies detected compared to none of the controls. Conjunctival titres were higher than serum titres in some patients.	Method of recruitment and demographic details not given. MacCallan grading classification used.
Antibodies to trachoma in eye secretions of Saudi Arab children ⁶⁷	Case-control study of children measuring antibodies to TRIC in conjunctival fluid and tears. Chlamydial culture and detection of inclusion bodies from conjunctival swabs also performed.	81 Saudi Arabian children (and 30 Caucasian children).	Saudi Arabia	50 Saudi Arabian children had antibodies compared to none of the Caucasian children. Saudi Arabian children who were antibody positive were more likely to have active trachoma, to have inclusion bodies seen and to be culture positive.	MacCallan grading classification used.
The serum and conjunctival antibody response to trachoma in Gambian children ⁶⁸	Longitudinal study measuring IgG and IgA antibodies to TRIC in tears and IgG antibodies in serum, on 6 occasions over 61 weeks. Detection of inclusion bodies from conjunctival swabs also performed.	99 children, the majority of whom had active disease at some point.	The Gambia	Higher serum antibody titres were strongly associated with clinical disease. Tear IgG was less strongly associated, and IgA even less. Serum IgG titres were higher in diseased children if inclusions were found.	Modified MacCallan grading classification used.
Local and humoral chlamydial antibodies in trachoma patients of different age groups ¹³⁸	Cross-sectional study measuring antibodies to TRIC in tears and serum in cases with trachoma.	194 cases of varying ages with different stages of trachoma.	Israel	Average antibody titres in tears tended to decrease with age, and in sera to increase with age.	MacCallan grading classification used. Infection status and comparison with controls not shown.
Antichlamydial antibody in tears and sera, and serotypes of Ct isolated from schoolchildren in Sourthern Tunisia ⁶⁹	Cross-sectional study measuring antibodies to TRIC in tears and serum. Chlamydial culture was also performed.	94 school children aged 6-10 years (tears collected in 71 children).	Tunisia	Antibody titres, especially in tears, showed some correlation with level of conjunctival inflammation. Titres were higher if culture positive.	
Conjunctival scarring in trachoma is associated with depressed cell-mediated immune responses to chlamydial antigens ⁷¹	Same study as in section above: serum antibody responses to Ct EB, MOMP and cHsp60 also measured.	29 cases and 29 controls	The Gambia	Scarring was associated with increased IgG and decreased IgA to Ct EB.	
The influence of local antichlamydial antibody on the acquisition and persistence of human ocular chlamydial	Longitudinal, community-wide study with examinations at 0, 7 and 20 months including conjunctival swabs for Ct antibodies and infection. Serum for Ct antibody responses taken at baseline	771 without disease at baseline (37 developed disease); 184	The Gambia	High levels of IgG from swab samples associated with an increased risk of developing incident active disease, there was an opposite trend for IgA (p=0.13). Serum antibody responses not	Results were adjusted for sharing a room with an active case as a marker of exposure to infection. Unclear whether results

infection: IgG antibodies are not protective ⁷⁰	and from a subset at 7 months.	with disease at baseline (64 with persistent disease).	significantly different.	refer to risk of incident infection or clinical disease.
Characterization of B-cell responses to Ct antigens in humans with trachoma ¹³⁹	Case-control study using the ELISPOT assay to measure cells actively secreting antibody to Ct EB, MOMP and cHsp60 in the serum. Serum IgG and IgA responses to MOMP also measured.	41 children with active disease (36 with TF, 5 with TI) and 19 controls; 17 adults with scarring and 17 controls.	Children with TI had an almost absent B cell response of all isotypes to all Ct antigens (lower than controls). Children with TF had increased IgA secreting cells. Adults had similar numbers of B cells. Antibody responses not significantly different.	Control children and adults had clearly detectable actively secreting B cells. Infection with Ct not confirmed.
Antibody response to the 60-kDa cHsp is associated with scarring trachoma ⁹⁰	Case-control study of scarred subjects and controls, measuring serum IgG responses to Ct EB and cHsp60.	148 cases and 148 controls.	The Seroprevalence of Ct infection around 90% in cases and controls. cHsp60 IgG was detected in more cases than controls (32% vs 16%), even after stratifying for Ct titre.	Although more cases than controls were seropositive for cHsp60, the overall proportion positive was relatively low compared to genital tract infection.
Immune response to chlamydial 60-kilodalton heat shock protein in tears from Nepali trachoma patients ¹⁴⁰	Cross-sectional study measuring serum and tear antibody responses to cHsp60, MOMP and cHsp60 fusion proteins. Chlamydial antibody titres were measured using MIF to EBs.	146 people of varying ages: 40 with TF, 53 with TI, 37 with TS, 16 disease-free.	Nepal Active and scarring disease were associated with tear cHsp60 IgG. Serum cHsp60 IgG was associated with TI only. Almost all individuals were seropositive by MIF.	
Characterization of humoral immune responses to chlamydial Hsp60, CPAF and CT795 in inflammatory and severe trachoma ¹⁴¹	Case-control study measuring tear antibody responses to cHsp60, CPAF and CT795.	65 cases with active disease and 65 controls; 59 cases with TT and 59 controls.	Nepal Active cases had elevated IgG to all antigens (more so when infection was present) and elevated IgA to cHsp60, compared to controls. TT cases had significantly elevated IgG to CPAF and reduced IgA to CT795.	

Table S6: Miscellaneous human trachoma studies

Title	Study summary	Sample size / Participants	Location	Key findings	Comments
Expression of MHC class II antigens by conjunctival epithelial cells in trachoma: implications concerning the pathogenesis of blinding disease ⁴⁶	Case-control study of children with active disease and controls, assessing MHC class II expression on conjunctival epithelial cells from swab samples. <i>Ct</i> antigen was detected by IDEIA.	40 cases and 38 controls.	The Gambia	MHC class II expression found and was associated with papillary inflammation.	
Cell-mediated immunity in trachomatous scarring ¹⁴²	Comparative study of subjects with leprosy compared to siblings without leprosy, in whom the grade of trachomatous conjunctival scarring was discordant.	50 sibling pairs involving paucibacillary and 12 involving multibacillary leprosy.	Ethiopia	Multibacillary leprosy (taken to indicate suppressed cell-mediated immunity) was associated with reduced conjunctival scarring. Paucibacillary leprosy (taken to indicate enhanced cell-mediated immunity) was associated with increased scarring.	
Synthetic peptides based on <i>Ct</i> antigens identify cytotoxic T lymphocytes in subjects from a trachoma-endemic population ¹⁴³	Case-control study of adults with conjunctival scarring, control adults and children with active trachoma but no infection. CTL responses to synthetic peptides based on MOMP and cHsp60 were measured in appropriate HLA individuals.	12 adult cases, 10 adult controls and 4 children.	The Gambia	CTL responses were found in 6 subjects (3 to MOMP and 3 to cHsp60), all of whom were either adult controls or children.	Method for detecting <i>Ct</i> infection not shown.
Serum complement components in patients with trachoma ¹⁴⁴	Case-control study measuring serum C1q, C3, C4 and C5 levels.	98 cases and 56 controls, of varying ages.	India	Serum C1q and C3 were lower in active disease and returned to normal after treatment.	Controls probably not matched for risk of trachoma. MacCallan grading classification used.
Failure to detect HLA-A*6802-restricted T cells specific for <i>Ct</i> antigens in subjects from trachoma-endemic communities ¹⁴⁵	Case-control study of subjects with conjunctival scarring and controls. CD8+ T cell responses were measured to synthetic HLA-A*6802 predicted peptides based on MOMP, MIP and cHsp70.	10 cases with scarring and 10 controls (children and adults).	The Gambia	No significant responses were observed.	
The frequency of <i>Ct</i> major outer membrane protein-specific CD8+ T lymphocytes in active trachoma is associated with current ocular	Longitudinal study with examinations every 2 weeks for 28 weeks. Peptide tetramers to MOMP were used to detect CD8+ cells in appropriate HLA individuals. PCR was used to detect <i>Ct</i> DNA.	86 children, around 20% of whom had infection and/or disease at the outset.	The Gambia	<i>Ct</i> -specific cells were found relatively infrequently, but there was some association with <i>Ct</i> infection. Such cells were not associated with disease.	

<p>Role of secreted conjunctival mucosal cytokine and chemokines proteins in different stages of trachomatous disease⁹⁶</p>	<p>Cross-sectional study with matched controls using multiplex bead analysis to measure levels of IFN-α, IFN-γ, IL-1β, IL-1Ra, IL-2, IL-2R, IL-4, IL-5, IL-6, IL-7, IL-8, IL-10, IL-12p40, IL-13, IL-15, IL-17, TNF-α, GM-CSF, CCL2, CCL3, CCL4, CCL5, CCL11, CXCL9 and CXCL10 in tear samples. <i>Cf</i> DNA level was measured (with or without PCR).</p>	<p>208 individuals of varying ages and disease status.</p>	<p>Nepal</p>	<p>Active disease was associated with increased IL-6, IL-8, IL-10, TNF-α and CCL-2. Scarring was associated with increased IL-1β, IL-2, IL-6, IL-8, IL-10, IL-15, TNF-α, CCL-2, CCL-11 and CXCL-2; and with reduced IL-1Ra, IL-4, IL-12p40 and IL-13. Infection in cases was associated with increased IL-6, IL-10, IL-15, TNF-α, CCL-4 and CCL-5.</p>	<p>Selection of subjects unclear. Further significant associations are presented for clinical subgroups, but p-values are unadjusted.</p>
--	--	--	--------------	---	---

Table 1: Summary of the incidence and progression rates of trachomatous scarring

Progression factor	Sample size	Follow-up interval	Rate	Setting	Prospective design?	Associated factors
Incident conjunctival scarring	367	5 years	20.4%	Tanzania ¹⁴⁷	Yes	In children <10yrs: Active disease/persistent infection Female gender Age
Incident conjunctival scarring	236 (age <7yrs)	7 years	29.2% vs 9.6%	Tanzania ⁷	No	Higher rate was in children with severe-constant active disease Female gender Age
Worsening of conjunctival scarring	85	5 years	47.1%	Tanzania ¹⁴⁷	Yes	Not specified
Worsening of conjunctival scarring	213 [†]	14 years	68.5%	Tunisia ⁸	No	Active disease Household density
From conjunctival scarring to trichiasis	523 (all women)	7 years	9.2%	Tanzania ⁹	No	Active disease Chlamydial infection Increasing age
From conjunctival scarring to trichiasis	297	12 years	6.4%	Gambia ¹⁴⁸	No	Mandinka ethnicity
From conjunctival scarring to trichiasis	4898	5 years	3.2% - 15.1%	Tanzania ¹⁴⁹	No*	Increasing age
From minor to major trichiasis	55	1 year	33%	Gambia ¹⁵⁰	No	None mentioned
From minor to major trichiasis	75	4 years	37%	Gambia ¹⁰	No	Conjunctival inflammation
From unilateral to bilateral trichiasis	46	1 year	46%	Gambia ¹⁵⁰	No	Baseline pannus Hot ash as an aid to epilation
From conjunctival scarring +/- trichiasis to corneal scarring	302	12 years	6.0%	Gambia ¹⁴⁸	No	Baseline trichiasis
From trichiasis to corneal scarring	211	4 years	7.6%	Gambia ¹⁰	No	Increasing trichiasis severity Conjunctival inflammation
From trichiasis to corneal opacity	4898	10 years	27.2% - 53.5%	Tanzania ¹⁴⁹	No*	Increasing age
Worsening of corneal scarring	96	1 year	34%	Gambia ¹⁵⁰	No	Conjunctival inflammation Bacterial growth

† Including 82 people with no scarring at baseline

* Estimated incidence rates based on age-specific prevalence of scarring, trichiasis and corneal opacity among women

References

1. Resnikoff S, Pascolini D, Etya'ale D, Kocur I, Pararajasegaram R, Pokharel GP, et al. Global data on visual impairment in the year 2002. *Bull World Health Organ.* 2004; **82**(11): 844-51.
2. Mariotti SP, Pascolini D, Rose-Nussbaumer J. Trachoma: global magnitude of a preventable cause of blindness. *Br J Ophthalmol.* 2009; **93**(5): 563-8.
3. WHO. Global elimination of blinding trachoma. World Health Assembly Resolutin WHA 51.11. http://www.who.int/ncd/vision2020_actionplan/documents/WHA51111pdf; 1998; Geneva: WHO; 1998.
4. http://www.who.int/hiv/pub/sti/en/who_hiv_aids_2001.02.pdf. [cited; Available from:
5. Caldwell HD, Wood H, Crane D, Bailey R, Jones RB, Mabey D, et al. Polymorphisms in *Chlamydia trachomatis* tryptophan synthase genes differentiate between genital and ocular isolates. *J Clin Invest.* 2003; **111**(11): 1757-69.
6. Wright HR, Taylor HR. Clinical examination and laboratory tests for estimation of trachoma prevalence in a remote setting: what are they really telling us? *Lancet Infect Dis.* 2005; **5**(5): 313-20.
7. West SK, Munoz B, Mkocha H, Hsieh YH, Lynch MC. Progression of active trachoma to scarring in a cohort of Tanzanian children. *Ophthalmic Epidemiol.* 2001; **8**(2-3): 137-44.
8. Dawson CR MR, Daghfous R, Juster R, Schachter J. What clinical signs are critical in evaluating the impact of intervention in trachoma? *Chlamydia Infections. Proceedings of the Seventh International Symposium on Human Chlamydial Infections.* London: Cambridge University Press; 1990. p. 271-5.
9. Munoz B, Bobo L, Mkocha H, Lynch M, Hsieh YH, West S. Incidence of trichiasis in a cohort of women with and without scarring. *Int J Epidemiol.* 1999; **28**(6): 1167-71.
10. Burton MJ, Bowman RJ, Faal H, Aryee EA, Ikumapayi UN, Alexander ND, et al. The long-term natural history of trachomatous trichiasis in the Gambia. *Invest Ophthalmol Vis Sci.* 2006; **47**(3): 847-52.
11. Wolle MA, Munoz BE, Mkocha H, West SK. Constant ocular infection with *Chlamydia trachomatis* predicts risk of scarring in children in Tanzania. *Ophthalmology.* 2009; **116**(2): 243-7.
12. Conway DJ, Holland MJ, Campbell AE, Bailey RL, Krausa P, Peeling RW, et al. HLA class I and II polymorphisms and trachomatous scarring in a *Chlamydia trachomatis*-endemic population. *J Infect Dis.* 1996; **174**(3): 643-6.
13. White AG, Bogh J, Leheny W, Kuchipudi P, Varghese M, al Riyami H, et al. HLA antigens in Omanis with blinding trachoma: markers for disease susceptibility and resistance. *Br J Ophthalmol.* 1997; **81**(6): 431-4.
14. Conway DJ, Holland MJ, Bailey RL, Campbell AE, Mahdi OS, Jennings R, et al. Scarring trachoma is associated with polymorphism in the tumor necrosis factor alpha (TNF-alpha) gene promoter and with elevated TNF-alpha levels in tear fluid. *Infect Immun.* 1997; **65**(3): 1003-6.
15. Mozzato-Chamay N, Mahdi OS, Jallow O, Mabey DC, Bailey RL, Conway DJ. Polymorphisms in candidate genes and risk of scarring trachoma in a *Chlamydia trachomatis*--endemic population. *J Infect Dis.* 2000; **182**(5): 1545-8.
16. Natividad A, Wilson J, Koch O, Holland MJ, Rockett K, Faal N, et al. Risk of trachomatous scarring and trichiasis in Gambians varies with SNP haplotypes at the interferon-gamma and interleukin-10 loci. *Genes Immun.* 2005; **6**(4): 332-40.
17. Natividad A, Cooke G, Holland MJ, Burton MJ, Joof HM, Rockett K, et al. A coding polymorphism in matrix metalloproteinase 9 reduces risk of scarring sequelae of ocular *Chlamydia trachomatis* infection. *BMC Med Genet.* 2006; **7**: 40.
18. Natividad A, Hanchard N, Holland MJ, Mahdi OS, Diakite M, Rockett K, et al. Genetic variation at the TNF locus and the risk of severe sequelae of ocular *Chlamydia trachomatis* infection in Gambians. *Genes Immun.* 2007; **8**(4): 288-95.
19. Natividad A, Holland MJ, Rockett KA, Forton J, Faal N, Joof HM, et al. Susceptibility to sequelae of human ocular chlamydial infection associated with allelic variation in IL10 cis-regulation. *Hum Mol Genet.* 2008; **17**(2): 323-9.

20. Atik B, Skwor TA, Kandel RP, Sharma B, Adhikari HK, Steiner L, et al. Identification of novel single nucleotide polymorphisms in inflammatory genes as risk factors associated with trachomatous trichiasis. *PLoS ONE*. 2008; **3**(10): e3600.
21. Abbas M, Bobo LD, Hsieh YH, Berka N, Dunston G, Bonney GE, et al. Human leukocyte antigen (HLA)-B, DRB1, and DQB1 allotypes associated with disease and protection of trachoma endemic villagers. *Invest Ophthalmol Vis Sci*. 2009; **50**(4): 1734-8.
22. Natividad A, Hull J, Luoni G, Holland M, Rockett K, Joof H, et al. Innate immunity in ocular *Chlamydia trachomatis* infection: contribution of IL8 and CSF2 gene variants to risk of trachomatous scarring in Gambians. *BMC Med Genet*. 2009; **10**: 138.
23. Bailey RL, Natividad-Sancho A, Fowler A, Peeling RW, Mabey DC, Whittle HC, et al. Host genetic contribution to the cellular immune response to *Chlamydia trachomatis*: Heritability estimate from a Gambian twin study. *Drugs Today (Barc)*. 2009; **45 Suppl B**: 45-50.
24. Bailey RL, Hampton TJ, Hayes LJ, Ward ME, Whittle HC, Mabey DC. Polymerase chain reaction for the detection of ocular chlamydial infection in trachoma-endemic communities. *J Infect Dis*. 1994; **170**(3): 709-12.
25. Taylor HR, Johnson SL, Prendergast RA, Schachter J, Dawson CR, Silverstein AM. An animal model of trachoma II. The importance of repeated reinfection. *Invest Ophthalmol Vis Sci*. 1982; **23**(4): 507-15.
26. Grayston JT, Wang SP, Yeh LJ, Kuo CC. Importance of reinfection in the pathogenesis of trachoma. *Rev Infect Dis*. 1985; **7**(6): 717-25.
27. Taylor HR. *Trachoma: a blinding scourge from the Bronze Age to the twenty-first century*. Melbourne: Haddington Press; 2008.
28. Faal N, Bailey RL, Sarr I, Joof H, Mabey DC, Holland MJ. Temporal cytokine gene expression patterns in subjects with trachoma identify distinct conjunctival responses associated with infection. *Clin Exp Immunol*. 2005; **142**(2): 347-53.
29. Wyrick PB. *Chlamydia trachomatis* persistence in vitro: an overview. *J Infect Dis*. **201 Suppl 2**: S88-95.
30. Smith A, Munoz B, Hsieh YH, Bobo L, Mkocha H, West S. *OmpA* genotypic evidence for persistent ocular *Chlamydia trachomatis* infection in Tanzanian village women. *Ophthalmic Epidemiol*. 2001; **8**(2-3): 127-35.
31. Burton MJ, Kinteh F, Jallow O, Sillah A, Bah M, Faye M, et al. A randomised controlled trial of azithromycin following surgery for trachomatous trichiasis in the Gambia. *Br J Ophthalmol*. 2005; **89**(10): 1282-8.
32. Burton MJ, Adegbola RA, Kinteh F, Ikumapayi UN, Foster A, Mabey DC, et al. Bacterial infection and trachoma in the gambia: a case control study. *Invest Ophthalmol Vis Sci*. 2007; **48**(10): 4440-4.
33. West ES, Mkocha H, Munoz B, Mabey D, Foster A, Bailey R, et al. Risk factors for postsurgical trichiasis recurrence in a trachoma-endemic area. *Invest Ophthalmol Vis Sci*. 2005; **46**(2): 447-53.
34. Bailey R, Duong T, Carpenter R, Whittle H, Mabey D. The duration of human ocular *Chlamydia trachomatis* infection is age dependent. *Epidemiol Infect*. 1999; **123**(3): 479-86.
35. Abrahams C, Ballard RC, Sutter EE. The pathology of trachoma in a black South African population. Light microscopical, histochemical and electron microscopical findings. *S Afr Med J*. 1979; **55**(27): 1115-8.
36. el-Asrar AM, Van den Oord JJ, Geboes K, Missotten L, Emarah MH, Desmet V. Immunopathology of trachomatous conjunctivitis. *Br J Ophthalmol*. 1989; **73**(4): 276-82.
37. Guzey M, Ozardali I, Basar E, Aslan G, Satıcı A, Karadede S. A survey of trachoma: the histopathology and the mechanism of progressive cicatrization of eyelid tissues. *Ophthalmologica*. 2000; **214**(4): 277-84.
38. al-Rajhi AA, Hidayat A, Nasr A, al-Faran M. The histopathology and the mechanism of entropion in patients with trachoma. *Ophthalmology*. 1993; **100**(9): 1293-6.
39. Reacher MH, Pe'er J, Rapoza PA, Whittum-Hudson JA, Taylor HR. T cells and trachoma. Their role in cicatricial disease. *Ophthalmology*. 1991; **98**(3): 334-41.

40. Rasmussen SJ, Eckmann L, Quayle AJ, Shen L, Zhang YX, Anderson DJ, et al. Secretion of proinflammatory cytokines by epithelial cells in response to Chlamydia infection suggests a central role for epithelial cells in chlamydial pathogenesis. *J Clin Invest*. 1997; **99**(1): 77-87.
41. Darville T, Hiltke TJ. Pathogenesis of genital tract disease due to Chlamydia trachomatis. *J Infect Dis*. **201 Suppl 2**: S114-25.
42. Abu el-Asrar AM, Geboes K, Tabbara KF, al-Kharashi SA, Missotten L, Desmet V. Immunopathogenesis of conjunctival scarring in trachoma. *Eye*. 1998; **12 (Pt 3a)**: 453-60.
43. Burton MJ, Bailey RL, Jeffries D, Mabey DC, Holland MJ. Cytokine and fibrogenic gene expression in the conjunctivas of subjects from a Gambian community where trachoma is endemic. *Infect Immun*. 2004; **72**(12): 7352-6.
44. Natividad A, Freeman TC, Jeffries D, Burton MJ, Mabey DC, Bailey RL, et al. Human conjunctival transcriptome analysis reveals the prominence of innate defense in Chlamydia trachomatis infection. *Infect Immun*. 2010; **78**(11): 4895-911.
45. Burton MJ, Rajak SN, Bauer J, Weiss HA, Tolbert SB, Shoo A, et al. Conjunctival transcriptome in scarring trachoma. *Infect Immun*. 2011; **79**(1): 499-511.
46. Mabey DC, Bailey RL, Dunn D, Jones D, Williams JH, Whittle HC, et al. Expression of MHC class II antigens by conjunctival epithelial cells in trachoma: implications concerning the pathogenesis of blinding disease. *J Clin Pathol*. 1991; **44**(4): 285-9.
47. Lacy HM, Bowlin AK, Hennings L, Scurlock AM, Nagarajan UM, Rank RG. Essential role for neutrophils in pathogenesis and adaptive immunity in Chlamydia caviae ocular infections. *Infect Immun*. 2011; **79**(5): 1889-97.
48. Gall A, Horowitz A, Joof H, Natividad A, Tetteh K, Riley E, et al. Systemic effector and regulatory immune responses to chlamydial antigens in trachomatous trichiasis. *Front Microbiol*. 2011; **2**: 10.
49. Rank RG, Soderberg LS, Barron AL. Chronic chlamydial genital infection in congenitally athymic nude mice. *Infect Immun*. 1985; **48**(3): 847-9.
50. Ramsey KH, Rank RG. Resolution of chlamydial genital infection with antigen-specific T-lymphocyte lines. *Infect Immun*. 1991; **59**(3): 925-31.
51. Morrison SG, Farris CM, Sturdevant GL, Whitmire WM, Morrison RP. Murine Chlamydia trachomatis genital infection is unaltered by depletion of CD4+ T cells and diminished adaptive immunity. *J Infect Dis*. **203**(8): 1120-8.
52. Brunham RC, Rey-Ladino J. Immunology of Chlamydia infection: implications for a Chlamydia trachomatis vaccine. *Nat Rev Immunol*. 2005; **5**(2): 149-61.
53. Thomas SM, Garrity LF, Brandt CR, Schobert CS, Feng GS, Taylor MW, et al. IFN-gamma-mediated antimicrobial response. Indoleamine 2,3-dioxygenase-deficient mutant host cells no longer inhibit intracellular Chlamydia spp. or Toxoplasma growth. *J Immunol*. 1993; **150**(12): 5529-34.
54. Ramsey KH, Miranpuri GS, Sigar IM, Ouellette S, Byrne GI. Chlamydia trachomatis persistence in the female mouse genital tract: inducible nitric oxide synthase and infection outcome. *Infect Immun*. 2001; **69**(8): 5131-7.
55. Igietseme JU, Ananaba GA, Candal DH, Lyn D, Black CM. Immune control of Chlamydial growth in the human epithelial cell line RT4 involves multiple mechanisms that include nitric oxide induction, tryptophan catabolism and iron deprivation. *Microbiol Immunol*. 1998; **42**(9): 617-25.
56. Bailey RL, Holland MJ, Whittle HC, Mabey DC. Subjects recovering from human ocular chlamydial infection have enhanced lymphoproliferative responses to chlamydial antigens compared with those of persistently diseased controls. *Infect Immun*. 1995; **63**(2): 389-92.
57. Faal N, Bailey RL, Jeffries D, Joof H, Sarr I, Laye M, et al. Conjunctival FOXP3 expression in trachoma: do regulatory T cells have a role in human ocular Chlamydia trachomatis infection? *PLoS Med*. 2006; **3**(8): e266.
58. Holland MJ, Faal N, Jeffries D, Joof H, Sarr I, Laye M, et al. Human ocular Chlamydia trachomatis disease, infection and immune responses examine using quantitative conjunctival gene expression with intensive longitudinal follow-up and gene co-expression analysis. *Proceedings of the Twelfth International Symposium on Human Chlamydial Infections*; 2010; Salzburg; 2010. p. 145-8.
59. Jawetz E, Rose L, Hanna L, Thygeson P. Experimental inclusion conjunctivitis in man: measurements of infectivity and resistance. *JAMA*. 1965; **194**(6): 620-32.

60. Dawson C, Jawetz E, Hanna L, Rose L, Wood TR, Thygeson P. Experimental inclusion conjunctivitis in man. II. Partial resistance to reinfection. *Am J Epidemiol.* 1966; **84**(3): 411-25.
61. Tarizzo ML, Nataf R, Nabli B. Experimental inoculation of thirteen volunteers with agent isolated from inclusion conjunctivitis. *Am J Ophthalmol.* 1967; **63**(5): Suppl:1120-8.
62. Nichols RL, Bell SD, Jr., Haddad NA, Bobb AA. Studies on trachoma. VI. Microbiological observations in a field trial in Saudi Arabia of bivalent trachoma vaccine at three dosage levels. *Am J Trop Med Hyg.* 1969; **18**(5): 723-30.
63. Sowa S, Sowa J, Collier LH, Blyth WA. Trachoma vaccine field trials in The Gambia. *J Hyg (Lond).* 1969; **67**(4): 699-717.
64. Rank RG, Whittum-Hudson JA. Protective immunity to chlamydial genital infection: evidence from animal studies. *J Infect Dis.* **201 Suppl 2**: S168-77.
65. Cohen CR, Koochesfahani KM, Meier AS, Shen C, Karunakaran K, Ondondo B, et al. Immunoepidemiologic profile of *Chlamydia trachomatis* infection: importance of heat-shock protein 60 and interferon- γ . *J Infect Dis.* 2005; **192**(4): 591-9.
66. Bernkopf H, Orfila J, Maythar B. Fluorescent antibodies in the fluid of the conjunctival sac of trachoma patients. *Nature.* 1966; **209**(5024): 725-6.
67. McComb DE, Nichols RL. Antibodies to trachoma in eye secretions of Saudi Arab children. *Am J Epidemiol.* 1969; **90**(4): 278-84.
68. Collier LH, Sowa J, Sowa S. The serum and conjunctival antibody response to trachoma in Gambian children. *J Hyg (Lond).* 1972; **70**(4): 727-40.
69. Treharne JD, Dwyer RS, Darougar S, Jones BR, Daghfous T. Antichlamydial antibody in tears and sera, and serotypes of *Chlamydia trachomatis* isolated from schoolchildren in Southern Tunisia. *Br J Ophthalmol.* 1978; **62**(8): 509-15.
70. Bailey RL, Kajbaf M, Whittle HC, Ward ME, Mabey DC. The influence of local antichlamydial antibody on the acquisition and persistence of human ocular chlamydial infection: IgG antibodies are not protective. *Epidemiol Infect.* 1993; **111**(2): 315-24.
71. Holland MJ, Bailey RL, Hayes LJ, Whittle HC, Mabey DC. Conjunctival scarring in trachoma is associated with depressed cell-mediated immune responses to chlamydial antigens. *J Infect Dis.* 1993; **168**(6): 1528-31.
72. Ramsey KH, Soderberg LS, Rank RG. Resolution of chlamydial genital infection in B-cell-deficient mice and immunity to reinfection. *Infect Immun.* 1988; **56**(5): 1320-5.
73. Su H, Feilzer K, Caldwell HD, Morrison RP. *Chlamydia trachomatis* genital tract infection of antibody-deficient gene knockout mice. *Infect Immun.* 1997; **65**(6): 1993-9.
74. Morrison SG, Su H, Caldwell HD, Morrison RP. Immunity to murine *Chlamydia trachomatis* genital tract reinfection involves B cells and CD4(+) T cells but not CD8(+) T cells. *Infect Immun.* 2000; **68**(12): 6979-87.
75. Morrison SG, Morrison RP. Resolution of secondary *Chlamydia trachomatis* genital tract infection in immune mice with depletion of both CD4+ and CD8+ T cells. *Infect Immun.* 2001; **69**(4): 2643-9.
76. Morrison SG, Morrison RP. A predominant role for antibody in acquired immunity to chlamydial genital tract reinfection. *J Immunol.* 2005; **175**(11): 7536-42.
77. Crane DD, Carlson JH, Fischer ER, Bavoi P, Hsia RC, Tan C, et al. *Chlamydia trachomatis* polymorphic membrane protein D is a species-common pan-neutralizing antigen. *Proc Natl Acad Sci U S A.* 2006; **103**(6): 1894-9.
78. Silverstein AM. The immunologic modulation of infectious disease pathogenesis. Friedenwald Lecture, 1973. *Invest Ophthalmol.* 1974; **13**(8): 560-74.
79. Burton MJ, Holland MJ, Faal N, Aryee EA, Alexander ND, Bah M, et al. Which members of a community need antibiotics to control trachoma? Conjunctival *Chlamydia trachomatis* infection load in Gambian villages. *Invest Ophthalmol Vis Sci.* 2003; **44**(10): 4215-22.
80. Woolridge RL, Grayston JT, Chang IH, Cheng KH, Yang CY, Neave C. Field trial of a monovalent and of a bivalent mineral oil adjuvant trachoma vaccine in Taiwan school children. *Am J Ophthalmol.* 1967; **63**(5): Suppl:1645-50.

81. Taylor HR, Johnson SL, Schachter J, Prendergast RA. An animal model of trachoma: IV. The failure of local immunosuppression to reveal inapparent infection. *Invest Ophthalmol Vis Sci.* 1983; **24**(5): 647-50.
82. Wang SP, Grayston JT, Alexander ER. Trachoma vaccine studies in monkeys. *Am J Ophthalmol.* 1967; **63**(5): Suppl:1615-30.
83. Stephens RS. The cellular paradigm of chlamydial pathogenesis. *Trends Microbiol.* 2003; **11**(1): 44-51.
84. Watkins NG, Hadlow WJ, Moos AB, Caldwell HD. Ocular delayed hypersensitivity: a pathogenetic mechanism of chlamydial-conjunctivitis in guinea pigs. *Proc Natl Acad Sci U S A.* 1986; **83**(19): 7480-4.
85. Morrison RP, Belland RJ, Lyng K, Caldwell HD. Chlamydial disease pathogenesis. The 57-kD chlamydial hypersensitivity antigen is a stress response protein. *J Exp Med.* 1989; **170**(4): 1271-83.
86. Taylor HR, Johnson SL, Schachter J, Caldwell HD, Prendergast RA. Pathogenesis of trachoma: the stimulus for inflammation. *J Immunol.* 1987; **138**(9): 3023-7.
87. Patton DL, Sweeney YT, Kuo CC. Demonstration of delayed hypersensitivity in *Chlamydia trachomatis* salpingitis in monkeys: a pathogenic mechanism of tubal damage. *J Infect Dis.* 1994; **169**(3): 680-3.
88. Lichtenwalner AB, Patton DL, Van Voorhis WC, Sweeney YT, Kuo CC. Heat shock protein 60 is the major antigen which stimulates delayed-type hypersensitivity reaction in the macaque model of *Chlamydia trachomatis* salpingitis. *Infect Immun.* 2004; **72**(2): 1159-61.
89. Rank RG, Dascher C, Bowlin AK, Bavoil PM. Systemic immunization with Hsp60 alters the development of chlamydial ocular disease. *Invest Ophthalmol Vis Sci.* 1995; **36**(7): 1344-51.
90. Peeling RW, Bailey RL, Conway DJ, Holland MJ, Campbell AE, Jallow O, et al. Antibody response to the 60-kDa chlamydial heat-shock protein is associated with scarring trachoma. *J Infect Dis.* 1998; **177**(1): 256-9.
91. Eckert LO, Hawes SE, Wolner-Hanssen P, Money DM, Peeling RW, Brunham RC, et al. Prevalence and correlates of antibody to chlamydial heat shock protein in women attending sexually transmitted disease clinics and women with confirmed pelvic inflammatory disease. *J Infect Dis.* 1997; **175**(6): 1453-8.
92. Toye B, Laferriere C, Claman P, Jessamine P, Peeling R. Association between antibody to the chlamydial heat-shock protein and tubal infertility. *J Infect Dis.* 1993; **168**(5): 1236-40.
93. Wynn TA. Fibrotic disease and the T(H)1/T(H)2 paradigm. *Nat Rev Immunol.* 2004; **4**(8): 583-94.
94. Holland MJ, Bailey RL, Conway DJ, Culley F, Miranpuri G, Byrne GI, et al. T helper type-1 (Th1)/Th2 profiles of peripheral blood mononuclear cells (PBMC); responses to antigens of *Chlamydia trachomatis* in subjects with severe trachomatous scarring. *Clin Exp Immunol.* 1996; **105**(3): 429-35.
95. Holland MJ, Jeffries D, Pattison M, Korr G, Gall A, Joof H, et al. Pathway-focused arrays reveal increased matrix metalloproteinase-7 (matrilysin) transcription in trachomatous trichiasis. *Invest Ophthalmol Vis Sci.* **51**(8): 3893-902.
96. Skwor TA, Atik B, Kandel RP, Adhikari HK, Sharma B, Dean D. Role of secreted conjunctival mucosal cytokine and chemokine proteins in different stages of trachomatous disease. *PLoS Negl Trop Dis.* 2008; **2**(7): e264.
97. Natividad A, Holland M, Mabey D, Bailey R. Expression profiling of cytokines, chemokines and their receptors during human ocular chlamydial infection. 12th International Symposium on Human Chlamydial Infections; 2010; Salzburg; 2010. p. 149-52.
98. Burton MJ, Ramadhani A, Weiss HA, Hu VH, Massae P, Burr SE, et al. Active trachoma is associated with increased conjunctival expression of IL17A and pro-fibrotic cytokines. *Infect Immun.* In Press.
99. Kelly KA. Cellular immunity and *Chlamydia* genital infection: induction, recruitment, and effector mechanisms. *Int Rev Immunol.* 2003; **22**(1): 3-41.
100. Frazer LC, O'Connell CM, Andrews CW, Jr., Zurenski MA, Darville T. Enhanced neutrophil longevity and recruitment contribute to the severity of oviduct pathology during *C. muridarum* infection. *Infect Immun.* 2011.

101. Roan NR, Starnbach MN. Immune-mediated control of Chlamydia infection. *Cell Microbiol.* 2008; **10**(1): 9-19.
102. Darville T, O'Neill JM, Andrews CW, Jr., Nagarajan UM, Stahl L, Ojcius DM. Toll-like receptor-2, but not Toll-like receptor-4, is essential for development of oviduct pathology in chlamydial genital tract infection. *J Immunol.* 2003; **171**(11): 6187-97.
103. Karimi O, Ouburg S, de Vries HJ, Pena AS, Pleijster J, Land JA, et al. TLR2 haplotypes in the susceptibility to and severity of Chlamydia trachomatis infections in Dutch women. *Drugs Today (Barc).* 2009; **45 Suppl B**: 67-74.
104. den Hartog JE, Lyons JM, Ouburg S, Fennema JS, de Vries HJ, Bruggeman CA, et al. TLR4 in Chlamydia trachomatis infections: knockout mice, STD patients and women with tubal factor subfertility. *Drugs Today (Barc).* 2009; **45 Suppl B**: 75-82.
105. Ouburg S, Lyons JM, Land JA, den Hartog JE, Fennema JS, de Vries HJ, et al. TLR9 KO mice, haplotypes and CPG indices in Chlamydia trachomatis infection. *Drugs Today (Barc).* 2009; **45 Suppl B**: 83-93.
106. Hu VH, Massae P, Weiss HA, Cree IA, Courtright P, Mabey DC, et al. In vivo confocal microscopy of trachoma in relation to normal tarsal conjunctiva. *Ophthalmol.* 2010.
107. Bobo L, Novak N, Mkocha H, Vitale S, West S, Quinn TC. Evidence for a predominant proinflammatory conjunctival cytokine response in individuals with trachoma. *Infect Immun.* 1996; **64**(8): 3273-9.
108. Burton MJ, Bowman RJ, Faal H, Aryee EA, Ikumapayi UN, Alexander ND, et al. Long term outcome of trichiasis surgery in the Gambia. *Br J Ophthalmol.* 2005; **89**(5): 575-9.
109. Hu VH, Massae P, Weiss HA, Chevallier C, Onyango JJ, Afwamba IA, et al. Bacterial infection in scarring trachoma. *Inves Ophthalmol Vis Sci.* 2010: In press.
110. Burton MJ, Hu VH, Massae P, Burr SE, Chevallier C, Afwamba IA, et al. What is causing active trachoma? The role of nonchlamydial bacterial pathogens in a low prevalence setting. *Invest Ophthalmol Vis Sci.* 2011; **52**(8): 6012-7.
111. Burton MJ, Bailey RL, Jeffries D, Rajak SN, Adegbola RA, Sillah A, et al. Conjunctival expression of matrix metalloproteinase and proinflammatory cytokine genes after trichiasis surgery. *Invest Ophthalmol Vis Sci.* 2010; **51**(7): 3583-90.
112. Onishi RM, Gaffen SL. Interleukin-17 and its target genes: mechanisms of interleukin-17 function in disease. *Immunology.* **129**(3): 311-21.
113. Reynolds JM, Angkasekwinai P, Dong C. IL-17 family member cytokines: regulation and function in innate immunity. *Cytokine Growth Factor Rev.* **21**(6): 413-23.
114. Khader SA, Gaffen SL, Kolls JK. Th17 cells at the crossroads of innate and adaptive immunity against infectious diseases at the mucosa. *Mucosal Immunol.* 2009; **2**(5): 403-11.
115. Torrado E, Cooper AM. IL-17 and Th17 cells in tuberculosis. *Cytokine Growth Factor Rev.* **21**(6): 455-62.
116. Kolls JK, Khader SA. The role of Th17 cytokines in primary mucosal immunity. *Cytokine Growth Factor Rev.* **21**(6): 443-8.
117. Mi S, Li Z, Yang HZ, Liu H, Wang JP, Ma YG, et al. Blocking IL-17A Promotes the Resolution of Pulmonary Inflammation and Fibrosis Via TGF- β 1-Dependent and -Independent Mechanisms. *J Immunol.* 2011; **187**(6): 3003-14.
118. Cruz A, Fraga AG, Fountain JJ, Rangel-Moreno J, Torrado E, Saraiva M, et al. Pathological role of interleukin 17 in mice subjected to repeated BCG vaccination after infection with Mycobacterium tuberculosis. *J Exp Med.* **207**(8): 1609-16.
119. Ramsey KH. Alternative Mechanisms of Pathogenesis. *Chlamydia: Genomics and Pathogenesis.* Norfolk, UK: Horizon Bioscience; 2006. p. 435-74.
120. Wong TT, Sethi C, Daniels JT, Limb GA, Murphy G, Khaw PT. Matrix metalloproteinases in disease and repair processes in the anterior segment. *Surv Ophthalmol.* 2002; **47**(3): 239-56.
121. Wynn TA. Cellular and molecular mechanisms of fibrosis. *J Pathol.* 2008; **214**(2): 199-210.
122. Parks WC, Wilson CL, Lopez-Boado YS. Matrix metalloproteinases as modulators of inflammation and innate immunity. *Nat Rev Immunol.* 2004; **4**(8): 617-29.

123. Imtiaz MT, Distelhorst JT, Schripsema JH, Sigar IM, Kasimos JN, Lacy SR, et al. A role for matrix metalloproteinase-9 in pathogenesis of urogenital *Chlamydia muridarum* infection in mice. *Microbes Infect.* 2007; **9**(14-15): 1561-6.
124. El-Asrar AM, Geboes K, Al-Kharashi SA, Al-Mosallam AA, Missotten L, Paemen L, et al. Expression of gelatinase B in trachomatous conjunctivitis. *Br J Ophthalmol.* 2000; **84**(1): 85-91.
125. Abu El-Asrar AM, Al-Kharashi SA, Missotten L, Geboes K. Expression of growth factors in the conjunctiva from patients with active trachoma. *Eye.* 2006; **20**(3): 362-9.
126. Thylefors B, Negrel AD, Pararajasegaram R. [Epidemiological surveillance of trachoma: evaluation and perspective]. *Rev Int Trach Pathol Ocul Trop Subtrop Sante Publique.* 1992; **69**: 107-14.
127. Leach AJ, Shelby-James TM, Mayo M, Gratten M, Laming AC, Currie BJ, et al. A prospective study of the impact of community-based azithromycin treatment of trachoma on carriage and resistance of *Streptococcus pneumoniae*. *Clin Infect Dis.* 1997; **24**(3): 356-62.
128. Brunham RC, Rekart ML. The arrested immunity hypothesis and the epidemiology of chlamydia control. *Sex Transm Dis.* 2008; **35**(1): 53-4.
129. Woodall JP. Proceedings of the Chlamydia Vaccine Development Colloquium. 2003: The Albert B. Sabin Vaccine Institute; 2003.
130. Frick KD, Colchero MA, Dean D. Modeling the economic net benefit of a potential vaccination program against ocular infection with *Chlamydia trachomatis*. *Vaccine.* 2004; **22**(5-6): 689-96.
131. Grayston JT, Woolridge RL, Wang SP, Yen CH, Yang CY, Cheng KH, et al. Field studies of protection from infection by experimental trachoma virus vaccine in preschool-aged children on Taiwan. *Proc Soc Exp Biol Med.* 1963; **112**: 589-95.
132. Grayston JT, Wang SP, Woolridge RL, Alexander ER. PREVENTION OF TRACHOMA WITH VACCINE. *Arch Environ Health.* 1964; **8**: 518-26.
133. Nichols RL, Bell SD, Jr., Murray ES, Haddad NA, Bobb AA. Studies on trachoma. V. Clinical observations in a field trial of bivalent trachoma vaccine at three dosage levels in Saudi Arabia. *Am J Trop Med Hyg.* 1966; **15**(4): 639-47.
134. Clements C, Dhir SP, Grayston JT, Wang SP. Long term follow-up study of a trachoma vaccine trial in villages of Northern India. *Am J Ophthalmol.* 1979; **87**(3): 350-3.
135. Burd EM, Tabbara KF, Nasr AM, Taylor PB. Conjunctival lymphocyte subsets in trachoma. *Int Ophthalmol.* 1988; **12**(1): 53-7.
136. Abu el-Asrar AM, Geboes K, al-Kharashi SA, Tabbara KF, Missotten L. Collagen content and types in trachomatous conjunctivitis. *Eye.* 1998; **12 (Pt 4)**: 735-9.
137. Abu el-Asrar AM, Geboes K, al-Kharashi SA, al-Mosallam AA, Tabbara KF, al-Rajhi AA, et al. An immunohistochemical study of collagens in trachoma and vernal keratoconjunctivitis. *Eye.* 1998; **12 (Pt 6)**: 1001-6.
138. Maythar B, Zakay-Rones Z. Local and humoral chlamydial antibodies in trachoma patients of different age groups. *Invest Ophthalmol.* 1972; **11**(8): 651-4.
139. Ghaem-Maghami S, Bailey RL, Mabey DC, Hay PE, Mahdi OS, Joof HM, et al. Characterization of B-cell responses to *Chlamydia trachomatis* antigens in humans with trachoma. *Infect Immun.* 1997; **65**(12): 4958-64.
140. Hessel T, Dhital SP, Plank R, Dean D. Immune response to chlamydial 60-kilodalton heat shock protein in tears from Nepali trachoma patients. *Infect Immun.* 2001; **69**(8): 4996-5000.
141. Skwor T, Kandel RP, Basravi S, Khan A, Sharma B, Dean D. Characterization of humoral immune responses to chlamydial heat shock protein 60, protease-like activity factor and hypothetical protein CT795 in inflammatory and severe trachoma. *Invest Ophthalmol Vis Sci.*
142. Courtright P, Lewallen S, Howe R. Cell-mediated immunity in trachomatous scarring. Evidence from a leprosy population. *Ophthalmology.* 1993; **100**(1): 98-104.
143. Holland MJ, Conway DJ, Blanchard TJ, Mahdi OM, Bailey RL, Whittle HC, et al. Synthetic peptides based on *Chlamydia trachomatis* antigens identify cytotoxic T lymphocyte responses in subjects from a trachoma-endemic population. *Clin Exp Immunol.* 1997; **107**(1): 44-9.
144. Sen DK, Sarin GS, Hiranandani M, Baveja UK. Serum complement components in patients with trachoma. *Br J Ophthalmol.* 1985; **69**(9): 707-10.

145. Mahdi OS, Whittle HC, Joof H, Mabey DC, Bailey RL. Failure to detect HLA-A*6802-restricted CD8+ T cells specific for Chlamydia trachomatis antigens in subjects from trachoma-endemic communities. *Clin Exp Immunol.* 2001; **123**(1): 68-72.
146. Holland MJ, Faal N, Sarr I, Joof H, Laye M, Cameron E, et al. The frequency of Chlamydia trachomatis major outer membrane protein-specific CD8+ T lymphocytes in active trachoma is associated with current ocular infection. *Infect Immun.* 2006; **74**(3): 1565-72.
147. Wolle MA, Munoz B, Mkocha H, West SK. Age, sex, and cohort effects in a longitudinal study of trachomatous scarring. *Invest Ophthalmol Vis Sci.* 2009; **50**(2): 592-6.
148. Bowman RJ, Jatta B, Cham B, Bailey RL, Faal H, Myatt M, et al. Natural history of trachomatous scarring in The Gambia: results of a 12-year longitudinal follow-up. *Ophthalmology.* 2001; **108**(12): 2219-24.
149. Munoz B, Aron J, Turner V, West S. Incidence estimates of late stages of trachoma among women in a hyperendemic area of central Tanzania. *Trop Med Int Health.* 1997; **2**(11): 1030-8.
150. Bowman RJ, Faal H, Myatt M, Adegbola R, Foster A, Johnson GJ, et al. Longitudinal study of trachomatous trichiasis in the Gambia. *Br J Ophthalmol.* 2002; **86**(3): 339-43.

Chapter 4

A review of *in vivo* confocal microscopy of the ocular surface

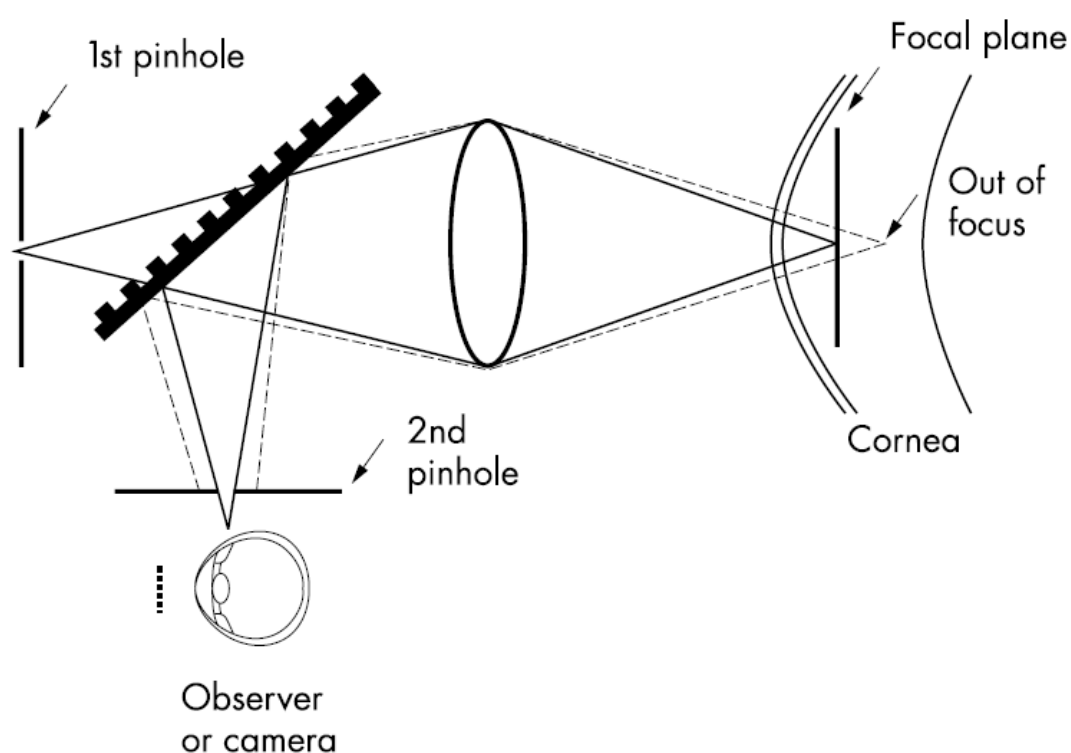


Introductory linking material on types of ocular *in vivo* confocal microscopy and studies which have been applied to the ocular surface

Principles of in vivo confocal microscopy (IVCM)

IVCM is based on the optical principle of confocality of the examined object with the light source and the detector plane.¹⁻³ Light is focused through a pinhole onto a single point on the object of interest. The light is reflected back through a second confocal pinhole and onto a light sensitive detector. The illumination (condenser) and observation (objective) systems are therefore focused on the same focal point, hence the term *confocal*. Any light originating from outside the focal plane is highly suppressed by the pinholes and only the layer of the object located at the focal plane contributes to the image. This suppression of light outside of the focal plane allows a greater resolution to be gained, but this is at the expense of the field of view which is very small. It is necessary to rapidly scan the focal point across the sample and for the image to be reconstructed to allow a real-time view. An image is gained which is *en face* or parallel to the surface being examined. By moving the position of the focal plane to different depths further optical sections can be acquired allowing imaging in three dimensions.

Figure 1: Diagrammatic representation of the optical principles of confocal microscopy. The broken lines show light reflected from behind the focal plane which is limited by the pinholes from reaching the observer. (Reproduced from Brit J Ophthalmol, Jalbert *et al*, 87:225-236, 2003, with permission from BMJ Publishing Group Ltd).



Light biomicroscopy, for example with the use of a slit-lamp, uses an optical section which is perpendicular or oblique to the surface being seen with a high proportion of scattered light. Resolution is decreased by interference from light reflected from structures in front of and behind the plane of examination. The slit-lamp microscope gives a maximum magnification of about 40 times, or a lateral resolution of approximately 20-30 μm .³ Increasing the magnification only results in blurring as the light reflected on adjacent structures obscures the image being observed.

Types of ocular surface confocal microscopes

Tandem scanning confocal microscopes

These utilise a Nipkow disc which consists of a metal plate with multiple pinhole apertures arranged in an archimedian spiral and a white light source.³⁻⁷ The focal plane is exposed to multiple spots of illumination and rotation of the disc allows the whole sample to be scanned. Each pinhole has a conjugate pinhole diametrically opposite to it on the disc. The small pinhole diameters (around 30 μm) limit light transmission and visualisation of structures less than 5 μm is difficult. A bright illuminating light source is necessary and appears very bright to the subject being scanned. The Tandem Scanning Corporation (Reston, USA), subsequently purchased by Advanced Scanning Corporation (New Orleans, USA), produced the first commercially available ophthalmic confocal microscope, but it is no longer in production.

Slit-scanning confocal microscopes

These use two optically conjugate vertical slit apertures for illumination and observation of the field of interest and so are only truly confocal in the axis perpendicular to the slit height.³⁻⁷ White light from a halogen bulb is used as the light source. A rapidly oscillating two-sided mirror scans the confocal image across the field. A wide slit aperture (300 μm for the Nidek ConfoScan 4) allows improved field brightness and contrast, and is also quicker, compared to the tandem scanning microscope, but this is partly at the expense of an increased depth of field and partial lack of confocalilty. The most commonly used slit-scanning confocal microscope is the ConfoScan produced by Nidek Technologies (Gamagori, Japan). This can be used either in a non-contact mode, or with a contact probe which gives great magnification. The manufacturer states the magnification with the contact probe to be 500 \times , the lateral resolution to be 0.6 μm per pixel and the scan size to be 640 \times 345 μm .⁸

Laser scanning confocal microscopes

The Heidelberg Retina Tomograph (HRT) uses a diode laser with a wavelength of 670 nm (Class I laser) to acquire images.³⁻⁷ This machine was originally developed to scan the posterior pole of the eye, in particular the optic nerve head for use in glaucoma. A microscope lens, the Rostock Cornea Module (RCM), is used to image anterior segment

structures using a contact technique with a polymethyl methacrylate cap contacting the ocular surface. Two scanning mirrors split the laser beam in two perpendicular directions in order to scan the image. The manufacturer states the lateral resolution to be $\sim 1\mu\text{m}$ per pixel, and the image size to be $400\times 400\mu\text{m}$, the magnification is not stated.⁹

Human ocular surface studies using IVCM

There have been a large number of publications which have used IVCM to study the ocular surface. Different types of studies are summarised below, with a focus on larger studies with more quantitative data. However, much of what has been published has included only descriptive case reports/series and there is a relative paucity of robust studies with a well-defined, repeatable methodology and rigorous data analysis.

Normal ocular surface

A number of studies have characterised the IVCM appearance of the normal cornea including epithelial cell density, nerve density and diameter, keratocyte density, endothelial cell density, corneal thickness and changes with ageing.⁵⁻⁷ The tear film and corneoscleral limbus have also been imaged.¹⁰⁻¹² Studies on the conjunctiva have looked at epithelial cell density, dendritiform cell density and changes with ageing.^{10, 13-21}

Inflammatory-fibrotic diseases of the conjunctiva

Measurement of an apparent IVCM inflammatory cell infiltrate in the palpebral conjunctiva of patients with atopic keratoconjunctivitis has been shown to be significantly lower in control subjects and in patients on cyclosporine compared to patients on standard treatment.²² The infiltrate was also found to have a positive association with clinical inflammation and fluorescein and Rose Bengal staining scores and a negative association with corneal sensitivity and tear film break-up time. A similar publication found the infiltrate to be positively correlated with the inflammatory cell density on brush cytology specimens.²³ A study of vernal keratoconjunctivitis found an increased inflammatory cell infiltrate and dendritiform cells compared to controls.²⁴ In these studies the IVCM scans are stated to be analysed by masked observers with the “three best focused scans” selected for cell counts. However, it is not completely clear exactly how the scans for the cell counts were chosen from all of the scans initially taken.

A number of studies have been done on Sjogren’s syndrome. The inflammatory cell density has been found to be higher in Sjogren’s and non-Sjogren’s dry eye compared to controls, and to show a positive association with vital staining scores and a negative association with tear stability and quantity.²⁵ Another study calculated the mean individual epithelial cell area and epithelial nuclear/cytoplasmic ratio using scans from the bulbar conjunctiva and found

these to be increased and decreased respectively in patients diagnosed with Sjogrens' syndrome.²⁶ These measurements also significantly correlated with corresponding measurements from impression cytology specimens. Similar findings were found in a study by the same group on patients with superior limbic keratoconjunctivitis.²⁷

Microbial keratitis

One of the most common clinical applications of IVCM is in the diagnosis and monitoring of microbial keratitis.^{6, 7, 28, 29} Numerous studies have reported visualising the hyphae of filamentous fungi and possibly even *Candida albicans* pseudofilaments.³⁰ The regression of fungal hyphae with treatment has also been reported.^{31, 32} Images of Acanthamoeba cysts have been published, sometimes with a double-walled appearance without which they may be difficult to differentiate from inflammatory cells.²⁸ It may also be possible to see trophozoites and swollen corneal nerves, but this is not as widely accepted.^{6, 33} There have also been reports of IVCM showing sub-epithelial infiltrates in epidemic keratoconjunctivitis, alteration in the sub-basal nerve plexus in herpes simplex virus infection and needle-like deposits in infectious crystalline keratopathy.³⁴⁻³⁶

IVCM has been reported to show good sensitivity and specificity in the diagnosis of acanthamoeba keratitis, but this was in the absence of masked grading.³⁷ Two prospective studies of patients presenting with a clinical diagnosis of infectious keratitis reported good sensitivities and specificities for acanthamoeba and fungal infections.³⁸ However, this was again in the absence of masked grading and little detail was presented on the protocol for taking the IVCM images or how standardised the protocols were. A more objective study using masked observers who selected a diagnosis of either acanthamoeba, fungal, *Microsporidia*, *Nocardia* or bacterial keratitis for culture-proven cases after viewing a representative IVCM scan.³⁹ With this more objective methodology the highest sensitivity and specificity values found were 56% and 84% respectively.

Ocular surface neoplasia

The use of IVCM as a diagnostic aid for possible ocular surface neoplasia is another in which IVCM could play an important clinical role. However, there have been relatively few studies in this area. Case reports have shown that abnormal cells and tissue in malignant lesions can apparently be clearly seen.⁴⁰⁻⁴⁶ A case series of ten patients with ocular surface squamous neoplasia found various characteristic cellular changes in high grade dysplasia.⁴⁷ A series of 28 pigmented tumours found that IVCM showed good sensitivity and specificity with histological analysis, although the observers were not masked to the clinical status.⁴⁸

Corneal degenerations, dystrophies and ectasia

There have been many reports into various corneal degenerations, dystrophies and ectasia including a reduction on keratocyte density in keratoconus and visualisation of guttae in Fuch's endothelial dystrophy.^{6, 7, 49}

Other ocular surface studies

IVCM studies in many other conditions have been reported including changes associated with contact lens wear, refractive and glaucoma surgery, topical medication, and also in numerous systemic diseases, especially corneal nerve changes in diabetic patients.^{3, 5-7, 49}

References

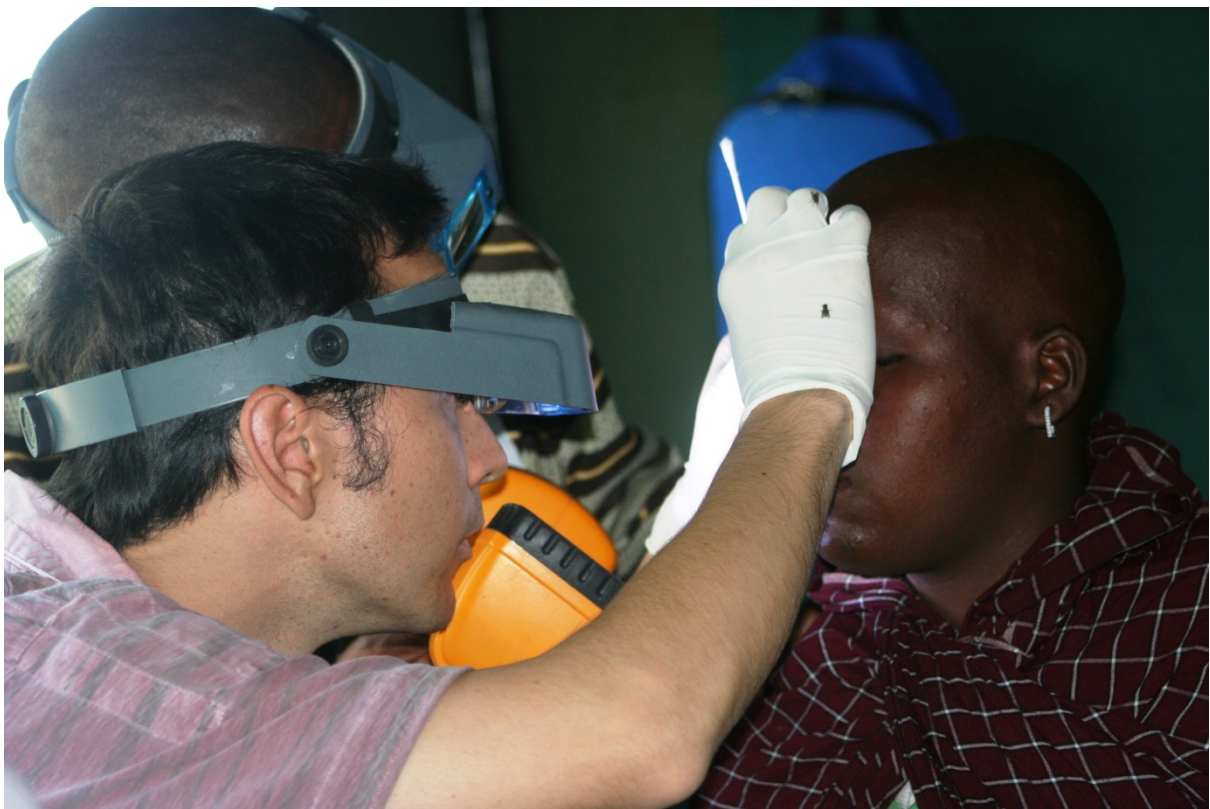1. Guthoff RF, Baudouin J, Stave J. Atlas of Confocal Laser Scanning In-vivo Microscopy in Ophthalmology. Berlin: Springer, 2006.
2. Scheuerle AF SE. Laser Scanning Ophthalmoscopy. Berlin: Springer, 2004.
3. Jalbert I, Stapleton F, Papas E, et al. In vivo confocal microscopy of the human cornea. Br J Ophthalmol 2003;87(2):225-36.
4. Erie JC, McLaren JW, Patel SV. Confocal microscopy in ophthalmology. Am J Ophthalmol 2009;148(5):639-46.
5. Guthoff RF, Zhivov A, Stachs O. In vivo confocal microscopy, an inner vision of the cornea - a major review. Clin Experiment Ophthalmol 2009;37(1):100-17.
6. Niederer RL, McGhee CN. Clinical in vivo confocal microscopy of the human cornea in health and disease. Prog Retin Eye Res 2010;29(1):30-58.
7. Patel DV, McGhee CN. Contemporary in vivo confocal microscopy of the living human cornea using white light and laser scanning techniques: a major review. Clin Experiment Ophthalmol 2007;35(1):71-88.
8. <http://www.nidektechnologies.it/ProductsCS4TechnicalReview.htm>. Accessed Oct 2011.
9. http://www.heidelbergengineering.com/international/wp-content/uploads/2011/07/RCM_Brochure_english.pdf. Accessed Oct 2011.
10. Zhivov A, Stachs O, Kraak R, et al. In vivo confocal microscopy of the ocular surface. Ocul Surf 2006;4(2):81-93.
11. Prydal JI, Dilly PN. In vivo confocal microscopy of the cornea and tear film. Scanning 1995;17(3):133-5.
12. Torens S, Berger E, Stave J, Guthoff R. [Imaging of the microarchitecture and dynamics of the break-up phenomena of the precocular tear film with the aid of laser scanning microscopy]. Ophthalmologie 2000;97(9):635-9.
13. Messmer EM, Mackert MJ, Zapp DM, Kampik A. In vivo confocal microscopy of normal conjunctiva and conjunctivitis. Cornea 2006;25(7):781-8.
14. Rath R, Stave J, Guthoff R, et al. [In vivo imaging of the conjunctival epithelium using confocal laser scanning microscopy]. Ophthalmologie 2006;103(5):401-5.
15. Efron N, Al-Dossari M, Pritchard N. In Vivo Confocal Microscopy of the Palpebral Conjunctiva and Tarsal Plate. Optom Vis Sci 2009.
16. Efron N, Al-Dossari M, Pritchard N. In vivo confocal microscopy of the bulbar conjunctiva. Clin Experiment Ophthalmol 2009;37(4):335-44.
17. Kobayashi A, Yoshita T, Sugiyama K. In vivo findings of the bulbar/palpebral conjunctiva and presumed meibomian glands by laser scanning confocal microscopy. Cornea 2005;24(8):985-8.
18. Zhu W, Hong J, Zheng T, et al. Age-related changes of human conjunctiva on in vivo confocal microscopy. Br J Ophthalmol 2010;94(11):1448-53.

19. Wei A, Hong J, Sun X, Xu J. Evaluation of age-related changes in human palpebral conjunctiva and meibomian glands by in vivo confocal microscopy. *Cornea* 2011;30(9):1007-12.
20. Villani E, Beretta S, Galimberti D, et al. In vivo confocal microscopy of conjunctival roundish bright objects: young, older, and Sjogren subjects. *Invest Ophthalmol Vis Sci* 2011;52(7):4829-32.
21. Jurgens C, Rath R, Giebel J, Tost FH. Laser scanning confocal microscopy for conjunctival epithelium imaging. *Dev Ophthalmol* 2010;45:71-82.
22. Hu Y, Adan ES, Matsumoto Y, et al. Conjunctival in vivo confocal scanning laser microscopy in patients with atopic keratoconjunctivitis. *Mol Vis* 2007;13:1379-89.
23. Wakamatsu TH, Okada N, Kojima T, et al. Evaluation of conjunctival inflammatory status by confocal scanning laser microscopy and conjunctival brush cytology in patients with atopic keratoconjunctivitis (AKC). *Mol Vis* 2009;15:1611-9.
24. Le Q, Hong J, Zhu W, et al. In vivo laser scanning confocal microscopy of vernal keratoconjunctivitis. *Clin Experiment Ophthalmol* 2011;39(1):53-60.
25. Wakamatsu TH, Sato EA, Matsumoto Y, et al. Conjunctival in vivo confocal scanning laser microscopy in patients with Sjogren syndrome. *Invest Ophthalmol Vis Sci* 2010;51(1):144-50.
26. Kojima T, Matsumoto Y, Dogru M, Tsubota K. The application of in vivo laser scanning confocal microscopy as a tool of conjunctival in vivo cytology in the diagnosis of dry eye ocular surface disease. *Mol Vis* 2010;16:2457-64.
27. Kojima T, Matsumoto Y, Ibrahim OM, et al. In vivo evaluation of superior limbic keratoconjunctivitis using laser scanning confocal microscopy and conjunctival impression cytology. *Invest Ophthalmol Vis Sci* 2010;51(8):3986-92.
28. Labbe A, Khammari C, Dupas B, et al. Contribution of in vivo confocal microscopy to the diagnosis and management of infectious keratitis. *Ocul Surf* 2009;7(1):41-52.
29. Kumar RL, Cruzat A, Hamrah P. Current state of in vivo confocal microscopy in management of microbial keratitis. *Semin Ophthalmol* 2010;25(5-6):166-70.
30. Brasnu E, Bourcier T, Dupas B, et al. In vivo confocal microscopy in fungal keratitis. *Br J Ophthalmol* 2007;91(5):588-91.
31. Winchester K, Mathers WD, Sutphin JE. Diagnosis of *Aspergillus* keratitis in vivo with confocal microscopy. *Cornea* 1997;16(1):27-31.
32. Shi W, Li S, Liu M, et al. Antifungal chemotherapy for fungal keratitis guided by in vivo confocal microscopy. *Graefes Arch Clin Exp Ophthalmol* 2008;246(4):581-6.
33. Matsumoto Y, Dogru M, Sato EA, et al. The application of in vivo confocal scanning laser microscopy in the management of *Acanthamoeba* keratitis. *Mol Vis* 2007;13:1319-26.
34. Dosso AA, Rungger-Brandle E. Clinical course of epidemic keratoconjunctivitis: evaluation by in vivo confocal microscopy. *Cornea* 2008;27(3):263-8.
35. Rosenberg ME, Tervo TM, Muller LJ, et al. In vivo confocal microscopy after herpes keratitis. *Cornea* 2002;21(3):265-9.
36. Sutphin JE, Kantor AL, Mathers WD, Mehaffey MG. Evaluation of infectious crystalline keratitis with confocal microscopy in a case series. *Cornea* 1997;16(1):21-6.
37. Tu EY, Joslin CE, Sugar J, et al. The relative value of confocal microscopy and superficial corneal scrapings in the diagnosis of *Acanthamoeba* keratitis. *Cornea* 2008;27(7):764-72.
38. Kanavi MR, Javadi M, Yazdani S, Mirdehghanm S. Sensitivity and specificity of confocal scan in the diagnosis of infectious keratitis. *Cornea* 2007;26(7):782-6.
39. Hau SC, Dart JK, Vesaluoma M, et al. Diagnostic accuracy of microbial keratitis with in vivo scanning laser confocal microscopy. *Br J Ophthalmol* 2010;94(8):982-7.
40. Balestrazzi A, Martone G, Pichierri P, et al. Corneal invasion of ocular surface squamous neoplasia after clear corneal phacoemulsification: in vivo confocal microscopy analysis. *J Cataract Refract Surg* 2008;34(6):1038-43.
41. Gentile CM, Burchakchi AI, Oscar CJ. In vivo confocal microscopy study of ocular surface neoplasia manifesting after radial keratotomy and laser in situ keratomileusis. *Cornea* 2009;28(3):357-9.
42. Hassani RT, Brasnu E, Amar N, et al. [Contribution of in vivo confocal microscopy to diagnosis of invasive ocular surface squamous neoplasia: a case report]. *J Fr Ophtalmol* 2010;33(3):163-8.

43. Duchateau N, Hugol D, D'Hermies F, et al. [Contribution of in vivo confocal microscopy to limbal tumor evaluation]. *J Fr Ophtalmol* 2005;28(8):810-6.
44. Pichierri P, Martone G, Loffredo A, et al. In vivo confocal microscopy in a patient with conjunctival lymphoma. *Clin Experiment Ophthalmol* 2008;36(1):67-9.
45. Gabison EE, Labbe A, Brignole-Baudouin F, et al. Confocal biomicroscopy of corneal intraepithelial neoplasia regression following interferon alpha 2b treatment. *Br J Ophthalmol* 2010;94(1):134-5.
46. Malandrini A, Martone G, Traversi C, Caporossi A. In vivo confocal microscopy in a patient with recurrent conjunctival intraepithelial neoplasia. *Acta Ophthalmol* 2008;86(6):690-1.
47. Parrozzani R, Lazzarini D, Dario A, Midena E. In vivo confocal microscopy of ocular surface squamous neoplasia. *Eye (Lond)* 2011;25(4):455-60.
48. Messmer EM, Mackert MJ, Zapp DM, Kampik A. In vivo confocal microscopy of pigmented conjunctival tumors. *Graefes Arch Clin Exp Ophthalmol* 2006;244(11):1437-45.
49. Chiou AG, Kaufman SC, Kaufman HE, Beuerman RW. Clinical corneal confocal microscopy. *Surv Ophthalmol* 2006;51(5):482-500.

Chapter 5

Clinical grading of trachomatous conjunctival scarring



Linking material summarising existing trachoma grading systems and describing a new grading system for trachomatous conjunctival scarring

Trachoma grading systems

It has generally been recognised that trachoma has two main stages: an initial active or inflammatory stage most commonly found in childhood, and a cicatricial stage usually found in adults. The various grading systems which have been developed over time generally show some reflection of these different phases.

In the late 19th century, on the basis of histological studies, Raehlmann described trachoma as consisting of Acute Trachoma with follicles present as part of an acute conjunctivitis, which then progressed to Chronic Trachoma consisting of three further stages.^{1 2} The first of the chronic stages was characterised by an increase in the size and number of follicles, the development of papillae and superior corneal pannus. The second chronic stage showed early tarsal scarring and the final chronic stage the development of entropion and trichiasis.

In 1908 MacCallan published his classification which was to become the world standard for over 60 years.³

Table 1: MacCallan's Classification of Trachoma³

Stage	Description
1	Small / immature follicles on the upper tarsal conjunctiva
2a	Large mature follicles
2b	Large mature follicles with papillary hypertrophy
3	Conjunctival scarring with some of the conjunctival signs described in stages 1 and 2
4	Advanced conjunctival scarring without any signs described in stages 1 and 2

However, this system does not include entropion or trichiasis or any mention of corneal disease. Those who have developed disease causing blindness, or who are at high risk of doing so, are therefore not recorded.

The World Health Organization has produced various grading systems for trachoma. One of the first of these, in 1966, included 20 signs which needed to be graded, and required the use of a slit lamp.⁴ This system was very difficult to use in the field and complex to analyse. In 1981, after various modifications, the grading was simplified to the "FPC" (follicles, papillae, cicatrices) system with five signs: upper tarsal follicles, upper tarsal papillary hypertrophy and diffuse infiltration, conjunctival scarring, trichiasis and/or entropion and

corneal scarring.⁵ The everted lid is divided into three zones, Figure 1, with the inner zones 2 and 3 only being used for grading.

Figure 1: Division of the upper lid for trachoma grading. Sketch of an everted upper eyelid showing the division into zones for the FPC system. The shaded area indicates the area to be examined for the simplified system (see below). Modified by Matthew Burton and reproduced with the permission of M. Burton and the World Health Organization.

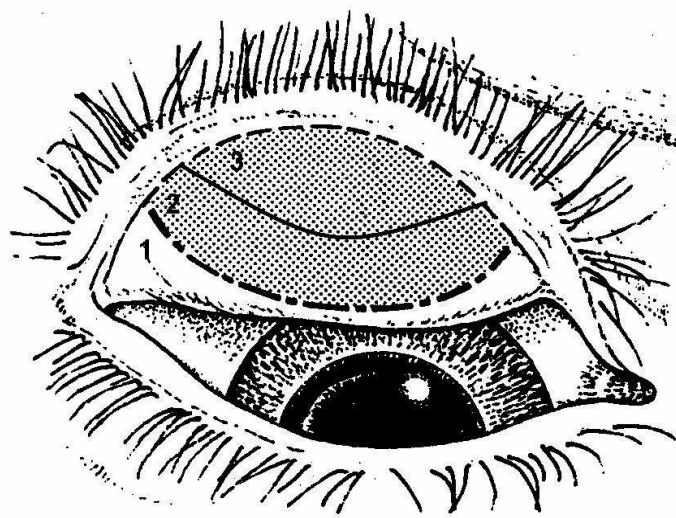


Table 2: WHO Trachoma Grading, 1981, FPC System⁵

Grade	Description
Upper Tarsal Follicles (F)	
F 0	No follicles.
F 1	Follicles present, but no more than 5 in zones 2 and 3 together.
F 2	More than 5 follicles in zones 2 and 3 together, but less than 5 in zone 3.
F 3	Five or more follicles in each of the three zones.
Upper tarsal papillary hypertrophy and diffuse inflammation (P)	
P 0	Absent: normal appearance
P 1	Minimal: individual vascular tufts (papillae) prominent, but deep subconjunctival vessels on the tarsus not obscured.
P 2	Moderate: more prominent papillae, and normal vessels appear hazy, even when seen by the naked eye.
P 3	Pronounced: conjunctiva thickened and opaque, normal vessels on the tarsus are hidden over more than half of the surface.

Conjunctival scarring (C)

- C 0 No scarring on the conjunctiva
- C 1 Mild: fine scattered scars on the upper tarsal conjunctiva, or scars on other parts of the conjunctiva.
- C 2 Moderate: more severe scarring but without shortening or distortion of the upper tarsus.
- C 3 Severe: scarring with distortion of the upper tarsus.
-

Trichiasis and/or entropion (T/E)

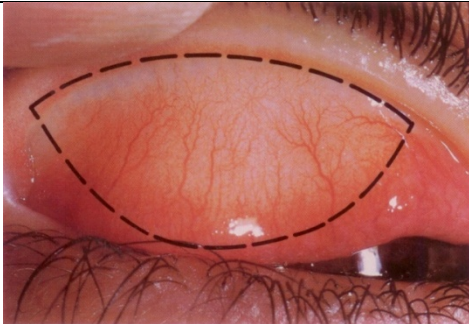
- T/E 0 No trichiasis and/or entropion.
- T/E 1 Lashes deviated towards the eye, but not touching the globe.
- T/E 2 Lashes touching the globe but not rubbing the cornea.
- T/E 3 Lashes constantly rubbing the cornea.
-

Corneal scarring (CC)

- CC 0 Absent
- CC 1 Minimal scarring or opacity but not involving the visual axis, and with clear central cornea.
- CC 2 Moderate scarring or opacity involving the visual axis, with the papillary margin visible through the opacity.
-

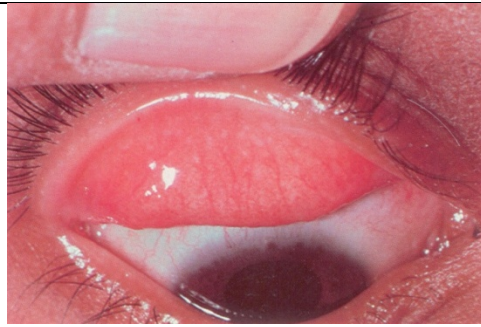This classification has been useful in the research setting but is still too complicated for programmatic work. The WHO simplified grading for trachoma was subsequently developed in 1987.⁶ In this system the same five signs which are graded in the FPC system are assessed, but the grader simply decides on the presence or absence of the sign rather than the severity. This simplified system can be quickly learnt by ophthalmic health care workers, is suitable for use in field studies and shows good agreement between clinical grading and grading from photographs.^{7, 8}

Table 3: WHO simplified grading for trachoma, 1987⁶

Grade and description	Example photograph
Normal tarsal conjunctiva The dotted lines indicate the area to be examined	

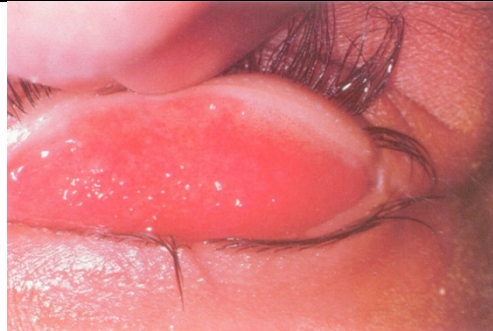Trachomatous Inflammation – Follicular (TF)

Description: The presence of 5 or more follicles (>0.5mm) in the upper tarsal conjunctiva



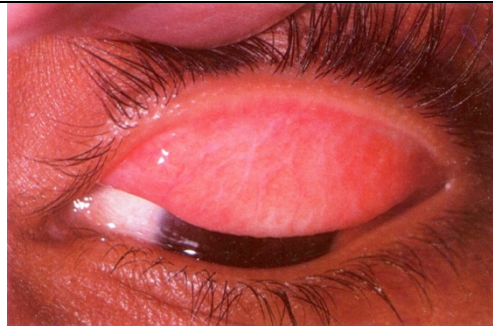Trachomatous Inflammation – Intense (TI)

Description: Pronounced inflammatory thickening of the tarsal conjunctiva that obscures more than half of the deep normal vessels



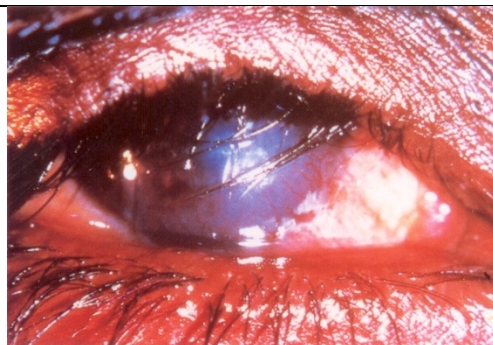
Trachomatous Scarring (TS)

Description: The presence of scarring in the tarsal conjunctiva



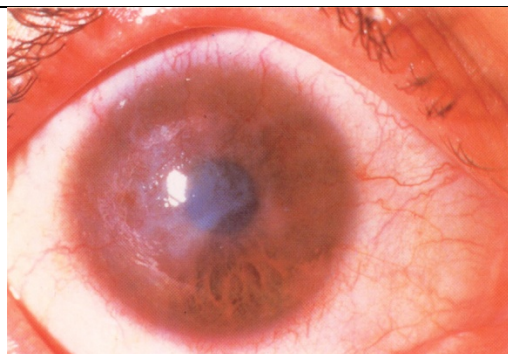Trachomatous Trichiasis (TT)

Description: At least one lash rubs on the eyeball



Corneal Opacity (CO)

Description: Easily visible corneal opacity over the pupil



The FPC system can be easily converted to the Simplified one using the table below, allowing comparison of results from different areas. Active disease is defined as having either TF (F2 or F3) and/or TI (P3).

Table 4: Conversion of WHO FPC System to Simplified System

Simplified System	FPC System	Implication
TI	P3	Severe intensity of inflammation
TF	F2 or F3	Presence of follicular trachoma
TS	C1, C2 or C3	Presence of cicatricial trachoma
TT	T/E 2 or T/E 3	Potentially disabling lesions
CO	CC 2 or CC 3	Visually disabling lesion

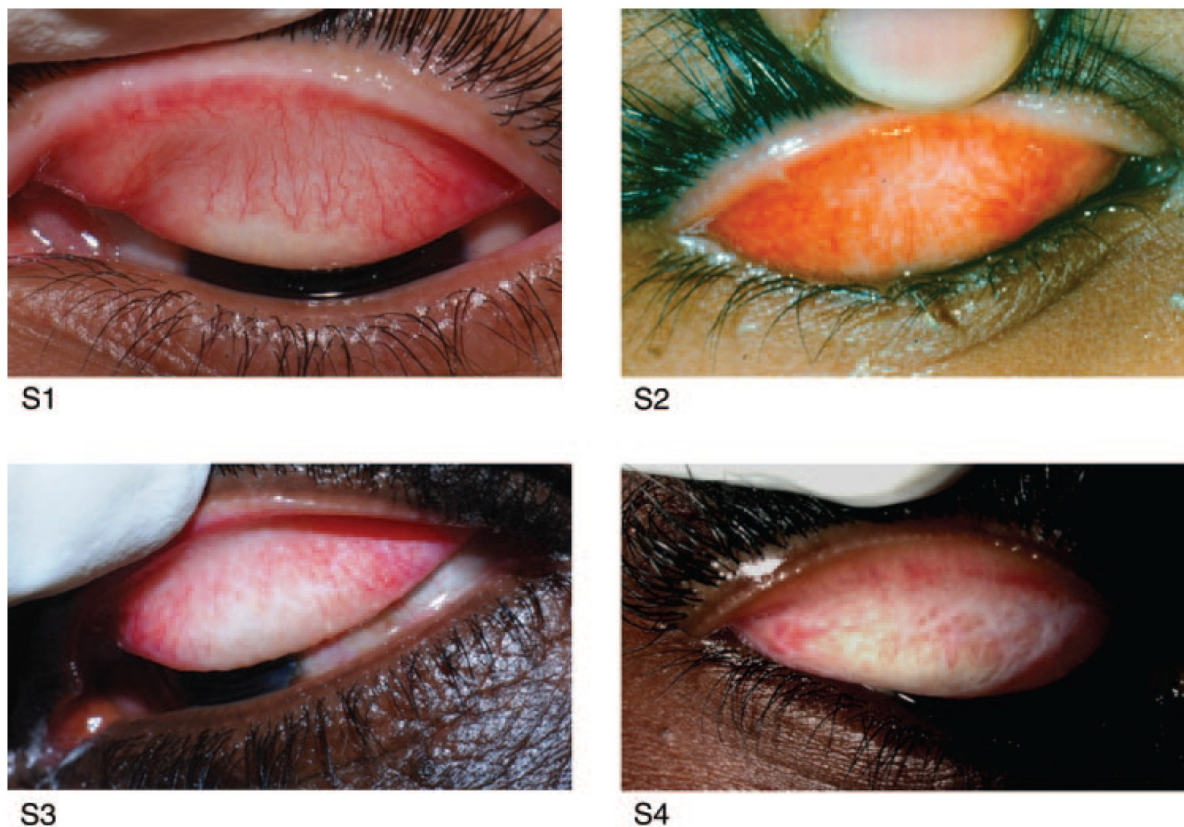
Alternative grading systems previously published

The WHO grading system for conjunctival scarring does not contain clear definitions of mild or moderate scarring and tarsal distortion is difficult to see on photographs. Alternative grading systems have therefore been used in two different studies^{9, 10} The first of these, published by Wolle et al, is shown in Table 5.

Table 5: Grading of trachomatous conjunctival scarring by Wolle et al.⁹

Grade	Definition
S1	A single line of scarring no more than 3mm in length and some stellate scars, but not as severe as S2.
S2	Multiple lines of scarring of more than 3mm in length with or without convergence that occupy approximately one eighth of the eyelid, but not as severe as S3.
S3	A linear pattern of scarring occupying at least one third of the upper lid with clear conjunctiva between, but not as severe as S4.
S4	More than 90% of the conjunctiva obliterated by scarring.

Figure 2: Reference images for trachomatous conjunctival scarring by Wolle et al⁹



Grading was performed using photographs taken with a digital camera (990, Nikon, Tokyo) at 5× magnification. Interobserver agreement on grading of a set of 84 images gave a kappa score (unweighted) of 0.74. This grading system uses a combination of length of scars and proportion of the upper lid involved in scarring. However, the grades do not appear to be completely contiguous. For example, it is not clear what the grade would be if the scarring involved between one eighth and one third of the upper lid.

Another scarring grading system has been published by Roper et al and shown in Table 6.¹⁰

Table 6: Grading of trachomatous conjunctival scarring by Roper et al.¹⁰

Grade	Definition
0	No visible scarring in the tarsal conjunctiva.
1	Small amount of early scarring apparent, but not clearly visible.
2	Moderate amount of early scarring apparent, but not clearly visible.
3	The presence of clearly visible scarring in the tarsal conjunctiva (equivalent to WHO simplified grading of TS).
4	Extensive clearly visible scarring involving most of the tarsal conjunctiva.

In this paper subjects were examined with 2.5× loupes and photographs were also taken with a digital camera (D40, Nikon, Tokyo). Between clinical and photographic grading of 1254 subjects the weighted kappa score was 0.67. Unfortunately, this grading system, like the 1981 WHO system, does not contain very clear definitions of the different grades.

A novel grading system for conjunctival scarring

In view of the shortcomings of previously published grading systems for conjunctival scarring we developed a new grading system, shown in Table 7 and Figure 3. In this system the surface area of the upper tarsal conjunctiva (zones 2 and 3) is divided into whether less than one third, between one and two thirds, or more than two thirds is covered with scarring, which correspond to grades S1, S2 and S3. If less than one third is covered with scarring (grade S1) there is a further sub-categorisation into S1a-S1c. This sub-categorisation of grade S1 was included as the TS (Trachomatous Scarring) study involved participants with mild-moderate scarring and therefore a finer grading at this end of the spectrum was desirable.

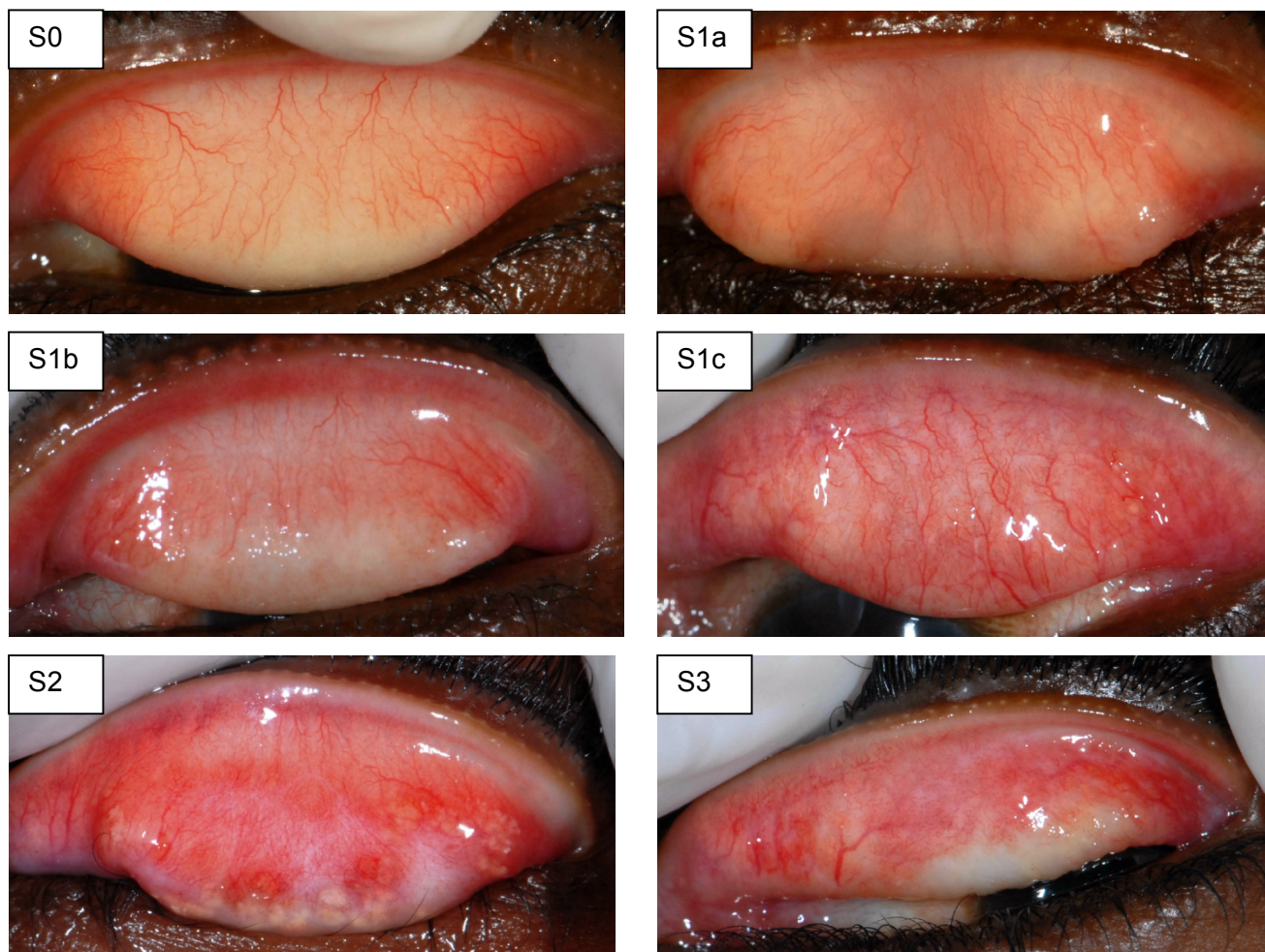
Table 7: New grading system for trachomatous conjunctival scarring¹¹

Grade	Definition*
S0	No visible scarring of the upper lid
S1	Scarring occupying $< \frac{1}{3}$ of the upper lid
S1a	One or more pinpoint scars and/or a single line of scarring less than 2mm in length [#]
S1b	Multiples lines of scarring less than 2mm in length
S1c	One or more lines/patches of scarring each 2mm or more in length/maximal dimension
S2	Scarring occupying $\geq \frac{1}{3}$ but $< \frac{2}{3}$ of the upper lid
S3	Scarring occupying $\geq \frac{2}{3}$ of the upper lid

* "upper lid" refers to zones 2 and 3 of the everted lid.

[#] 2mm was chosen as this is the approximate width of the lower lid margin, which is therefore readily available for comparison.

Figure 3: Example images for the new conjunctival scarring grading system



This novel grading system was used in both of the main case-control studies using 2.5× loupes and a bright torch for the field grading. Digital photographs were also taken (D200, Nikon, Tokyo).

To assess inter-observer variation of the novel grading system for trachomatous conjunctival scarring grading was performed on 51 subjects with a range of scarring. Photographs were graded at 5× magnification by two independent observers (VH and MB) masked to the clinical status. A kappa score of 0.68 (linear weighting, $p < 0.0001$) or 0.83 (quadratic weighting, $p < 0.0001$) was obtained.

Table 8: Interobserver variation for the new conjunctival scarring grading system

Grader	MB							Total
	Grade	0	S1a	S1b	S1c	S2	S3	
VH	0	7	0	1	0	0	0	8
	S1a	3	0	1	0	0	0	4
	S1b	1	1	3	1	1	0	7
	S1c	2	1	0	5	6	1	15
	S2	0	0	0	1	6	0	7
	S3	0	0	0	0	3	7	10
Total	13	2	5	7	16	8	51	

We have found this grading system straightforward to apply both in the field and for photographic grading of scarring. We have used it in both of the major case-control studies and plan to use it in futures studies. It has shown good correlation with *in vivo* confocal microscopy analysis of scarring and also been applied to the microbiological and gene expression analyses with good results.

References

1. E R. Pathologisch-anatomische Untersuchungen ueber die follikulaere Entzuendung der Bindehaut des Auges oder das Trachom. *Albrecht von Graefe's Archiv fur Ophthalmologie* 1883;73-166.
2. TaylorHR. *Trachoma: a blinding scourge from the Bronze Age to the twenty-first century*. Melbourne: Haddington Press; 2008.
3. AF M. Ophthalmic conditions in the government's schools in Egypt and their amelioration. *The Ophthalmoscope* 1908;856-863;947-852.
4. Fourth WHO Scientific Group on Trachoma Research. Report. *World Health Organ Tech Rep Ser* 1966;330:1-24.
5. Dawson CR JB, Tarizzo ML. Guide to trachoma control. Geneva: World Health Organization; 1981.
6. Thylefors B DC, Jones BR, West SK, Taylor HR. A simple system for the assessment of trachoma and its complications. *Bull World Health Organ*; 1987.
7. Taylor HR, West SK, Katala S, Foster A. Trachoma: evaluation of a new grading scheme in the United Republic of Tanzania. *Bull World Health Organ* 1987;65:485-488.
8. West SK, Taylor HR. Reliability of photographs for grading trachoma in field studies. *Br J Ophthalmol* 1990;74:12-13.

9. Wolle MA, Munoz B, Mkocha H, West SK. Age, sex, and cohort effects in a longitudinal study of trachomatous scarring. *Invest Ophthalmol Vis Sci* 2009;50:592-596.
10. Roper KG, Taylor HR. Comparison of clinical and photographic assessment of trachoma. *Br J Ophthalmol* 2009;93:811-814.
11. Hu VH, Massae P, Weiss HA, et al. Bacterial infection in scarring trachoma. *Invest Ophthalmol Vis Sci*.

Chapter 6

The problem, overall aims and study summaries



Linking material summarising a statement of the problem, the central research focus, specific objectives and hypotheses, and outlines of the main studies

Statement of the problem

A major challenge in the development and assessment of strategies to control blinding trachoma is that the progression from active trachoma in childhood to the development of scarring and blinding complications in later life occurs very slowly over many years. Therefore, prospective clinical trials and epidemiological studies conducted to investigate whether control measures prevent the development and progression of scarring and blindness would be prohibitively long. Moreover, it is important in the context of the worldwide effort to control blinding trachoma by the year 2020 to know as soon as possible whether progressive scarring disease can be prevented by the current control measures

It has been assumed that by controlling *Chlamydia trachomatis* infection through antibiotic distribution, face washing and environmental improvements that the progression to blinding disease will be halted. This assumption is likely to be correct for people who have not previously been infected by *C. trachomatis*, for example, children born after effective control measures were introduced. However, it is not known whether older children and adults who have previously been infected by *C. trachomatis* will be prevented from developing progressive scarring disease and blinding complications in future years. The answer to this question has major ophthalmic public health implications for blindness control programmes in trachoma endemic countries such as Tanzania.

There are also grounds for concern that the disease could still progress following a reduction in the prevalence of *C. trachomatis* infection. Firstly, clinically visible conjunctival inflammation is frequently found to persist in communities following the introduction of high coverage levels of mass antibiotic distribution.¹⁻⁴ This is likely to be much more pronounced in operational programmes where coverage levels may be disappointing. Such inflammation has been linked in long term epidemiological studies with scarring later in life.⁵⁻⁹ Secondly, in countries where the prevalence of *C. trachomatis* infection is thought to have been low for some time new cases of trichiasis and corneal blindness continue to develop.⁸ Relatively little is known about the pathogenesis of blinding trachoma. Whilst it is widely accepted that the process is initiated by recurrent chlamydial infection in childhood, it is probable that other poorly understood factors are important, which are not addressed by the current trachoma control strategies.

Central research focus

The main aim of this work was to identify the principal immuno-fibrogenic processes associated with trachomatous scarring. I set out to describe various correlates of trachomatous conjunctival scarring, including microbiological, immunological, fibrogenic and *in vivo* confocal microscopic. The purpose of this was improve our understanding of the pathogenesis of trachomatous scarring thereby aiding the development of future control strategies such as anti-scarring treatments and an anti-chlamydial vaccine, and also to help identify biomarkers for progressive scarring disease.

Specific objectives

1. To describe the microbiological, immunological, fibrogenic and confocal microscopic correlates of trachomatous conjunctival scarring, and how these differ from normal controls.
2. To describe in detail the histopathological appearance of conjunctival scarring in individuals with trachomatous trichiasis compared with normal control subjects, and relate this to the observations made with confocal microscopy.

Hypotheses

The following hypotheses were examined:

1. Clinically visible conjunctival inflammation and scarring in trachomatous subjects is correlated with differences seen using *in vivo* confocal microscopy, and this corresponds to the histological appearance.
2. Trachomatous scarring is driven by several factors, in addition to infection with *C. trachomatis*, such as non-chlamydial bacterial infection.
3. Trachomatous scarring is associated with a T_H2 cytokine response (particularly IL-13) and pro-fibrogenic mediators, such as MMP-9.
4. Trachomatous scarring is associated with evidence of innate immune responses.

Outline of the main studies

The data for this PhD are drawn from two main case-control studies. The first (TS) study is of trachomatous conjunctival scarring in which the cases had relatively mild scarring. Any participants which had progressed to trichiasis were excluded from this study. Chapters 8, 9, 11 and 12 utilise data from this TS study. The second (TT) study is of trachomatous conjunctival scarring in which the cases all had trichiasis and generally had severe scarring. Chapters 10 and 13 utilise data from this TT study.

References

1. Schachter J, West SK, Mabey D, et al. Azithromycin in control of trachoma. *Lancet* 1999;354:630-635.
2. Solomon AW, Holland MJ, Alexander ND, et al. Mass treatment with single-dose azithromycin for trachoma. *N Engl J Med* 2004;351:1962-1971.
3. Burton MJ, Holland MJ, Makalo P, et al. Re-emergence of Chlamydia trachomatis infection after mass antibiotic treatment of a trachoma-endemic Gambian community: a longitudinal study. *Lancet* 2005;365:1321-1328.
4. Keenan JD, Lakew T, Alemayehu W, et al. Slow resolution of clinically active trachoma following successful mass antibiotic treatments. *Arch Ophthalmol* 129:512-513.
5. West SK, Munoz B, Mkocha H, Hsieh YH, Lynch MC. Progression of active trachoma to scarring in a cohort of Tanzanian children. *Ophthalmic Epidemiol* 2001;8:137-144.
6. Dawson CR MR, Daghfous R, Juster R, Schachter J. What clinical signs are critical in evaluating the impact of intervention in trachoma? Chlamydia Infections. *Proceedings of the Seventh International Symposium on Human Chlamydial Infections*. London: Cambridge University Press; 1990:271-275.
7. Munoz B, Bobo L, Mkocha H, Lynch M, Hsieh YH, West S. Incidence of trichiasis in a cohort of women with and without scarring. *Int J Epidemiol* 1999;28:1167-1171.
8. Burton MJ, Bowman RJ, Faal H, et al. The long-term natural history of trachomatous trichiasis in the Gambia. *Invest Ophthalmol Vis Sci* 2006;47:847-852.
9. Wolle MA, Munoz BE, Mkocha H, West SK. Constant ocular infection with Chlamydia trachomatis predicts risk of scarring in children in Tanzania. *Ophthalmology* 2009;116:243-247.

Chapter 7

Survey of trachomatous scarring



Linking material describing an enumeration and screening operation in the Kilimanjaro region to identify cases for the Trachomatous Scarring (TS) case-control study

Introduction

For the TS (Trachomatous Scarring) case-control study we planned to recruit around 400 cases with trachomatous conjunctival scarring (without trichiasis) and 400 control subjects (without clinically visible scarring). A trachoma-endemic area was therefore identified. Assistance for this was provided by Paul Courtright at the Kilimanjaro Centre for Community Ophthalmology which had performed trachoma surveys in the Kilimanjaro Region of northern Tanzania. In order to identify suitable participants we conducted an enumeration and screening survey in the chosen area.

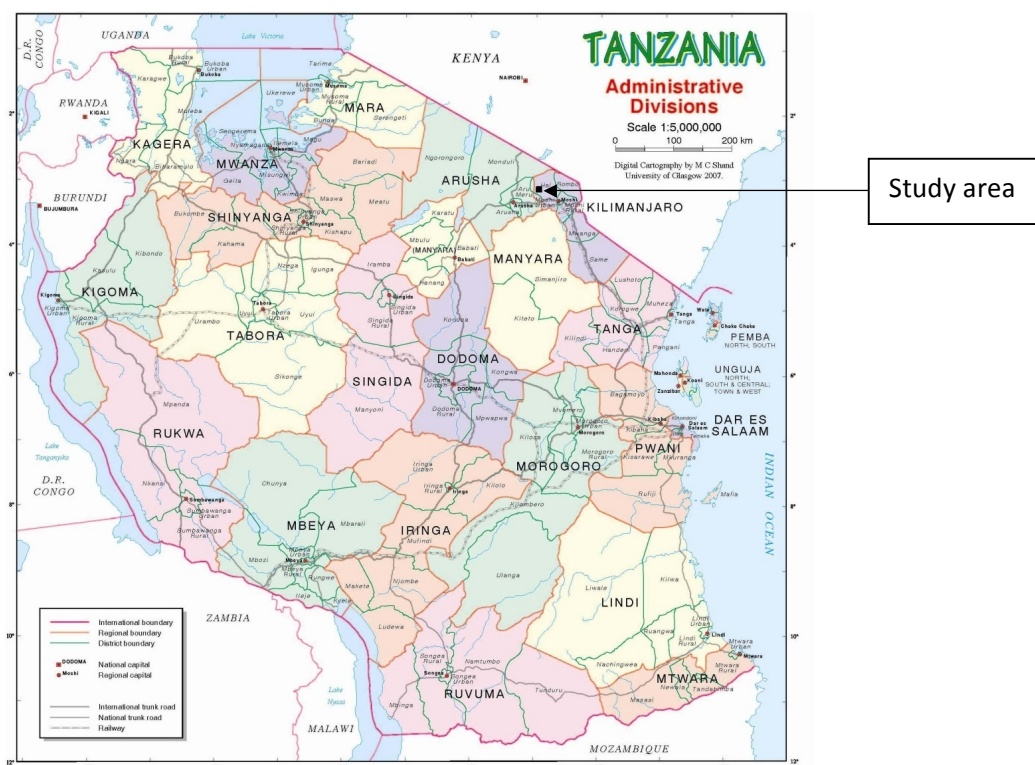
Methods

The enumeration and screening programme was carried out in three villages in Siha district: Mwasiliano, Magadini and Wiri. Adults (18 years or older) were enumerated with the assistance of the village leaders and balozi (leaders in charge of 10-20 families). House to house visits were made and available adults were examined by an ophthalmologist (VH) and a senior trachoma grader (Patrick Massase) using $\times 2.5$ loupes after obtaining verbal consent. Conjunctival scarring was recorded as being present if any of grades C1-C3 of the 1981 WHO Trachoma Grading system were present, Table 1¹ Demographic information was also recorded, including name, age and sex. A repeat visit was also made in an attempt to examine those initially absent. These three villages historically and geographically form a single unit, having been sub-divided for administrative purposes only two years before the study started.

Table 1: 1981 WHO Trachoma Grading system for conjunctival scarring¹

Grade	Description
C 0	No scarring on the conjunctiva
C 1	Mild: fine scattered scars on the upper tarsal conjunctiva, or scars on other parts of the conjunctiva.
C 2	Moderate: more severe scarring but without shortening or distortion of the upper tarsus.
C 3	Severe: scarring with distortion of the upper tarsus.

Figure 1: Map of Tanzania showing the study area



Results

Adults in the three villages of Mawasiliano, Magadini and Wiri were screened for trachomatous conjunctival scarring in December 2008 and January 2009. The total population of the three villages was 3626 people at the time of the census. Of these, 2418 (67%) were examined. Of the 1208 individuals not seen: 711 (59%) were absent at the time of the census, despite 2 visits to their homes; 347 (29%) were temporarily resident elsewhere; and 150 (12%) refused examination.

Of those examined, 983 (41%) were found to have conjunctival scarring. The distribution of TS by age and sex is shown Table 2. The prevalence of scarring increased with age for both males and females. The age-specific prevalence of scarring between the sexes was broadly similar. The proportion of people found to have scarring is high, this is at least partly because people were included as cases if they had any scarring, even if this scarring was minimal. Also, a bright torch under standard lighting conditions was used for the clinical examination.

Table 2: Proportion of trachomatous conjunctival scarring in the study area by age and sex

Age (years)	TS present		Males with TS present		Females with TS	
	n/N	(%)	n/N	(%)	n/N	(%)
18 - 25	134 / 572	(23.4)	35 / 176	(19.9)	99 / 396	(25.0)
25 - 35	188 / 578	(32.5)	69 / 194	(35.6)	119 / 384	(31.0)
35 - 45	205 / 506	(40.5)	82 / 207	(39.6)	123 / 299	(41.1)
45 - 55	166 / 315	(52.7)	63 / 125	(50.4)	103 / 190	(54.2)
55 - 65	118 / 188	(62.8)	49 / 79	(62.0)	69 / 109	(63.3)
> 65	170 / 252	(67.5)	80 / 125	(64.0)	89 / 126	(70.6)
Total	981 / 2411*	(40.1)	378 / 906	(41.7)	602 / 1504	(40.0)

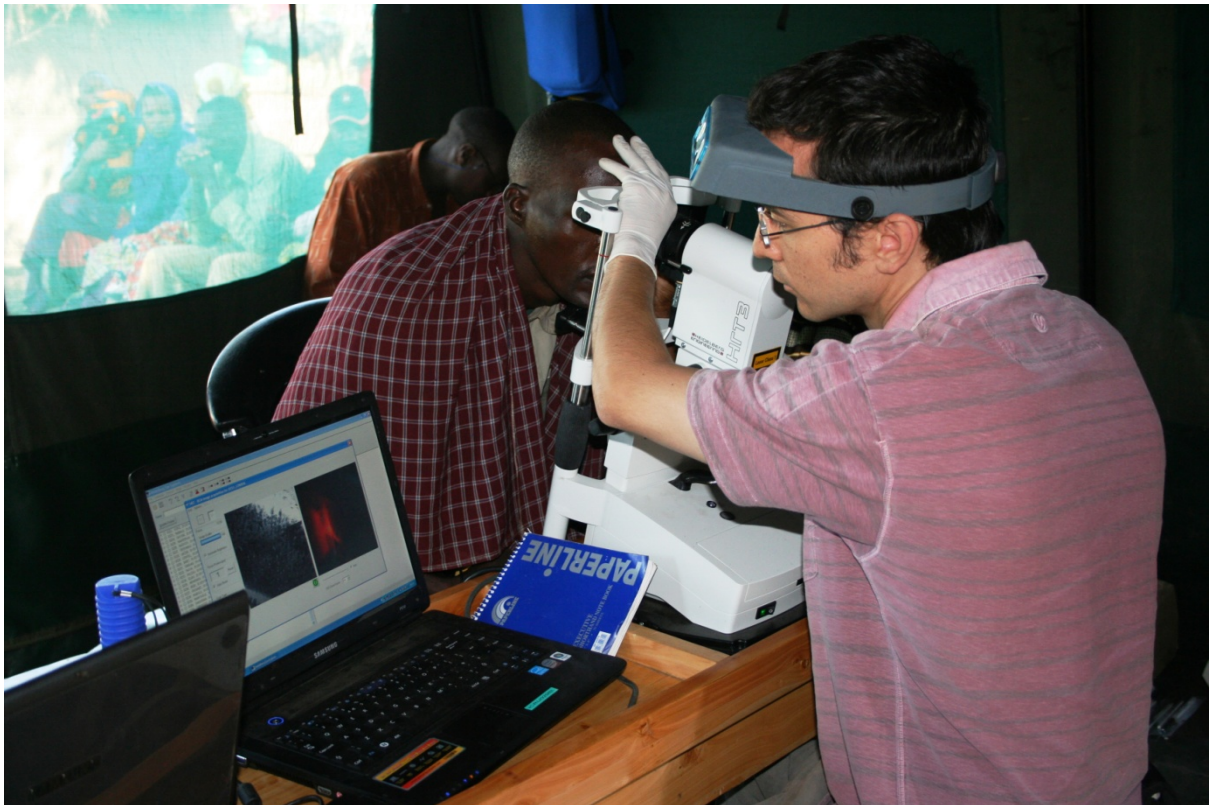*Some data points missing leading to reduced overall number for inclusion in the table

References

1. Dawson CR JB, Tarizzo ML. Guide to trachoma control. Geneva: World Health Organization; 1981.

Chapter 8

***In vivo* confocal microscopy of trachoma in relation to normal tarsal conjunctiva**



Research paper comparing *in vivo* confocal microscopy findings in trachomatous cases with controls and a description of grading systems for confocal analysis

Cover sheet for each ‘research/review paper’ included in a research thesis

1. For a ‘research/review paper’ already published

1.1. Where was the work published? **Ophthalmology**

1.2. When was the work published? **April 2011**

1.3. Was the work subject to academic peer review? **Yes**

1.4. Have you retained the copyright for the work? **No**

If yes, attach evidence of retention

If no, or if the work is being included in its published format, attach evidence of permission from copyright holder (publisher or other author) to include work

See Appendix 7c

2. For multi-authored work, give full details of your role in the research included in the paper and in the preparation of the paper. (Attach a further sheet if necessary)

I coordinated and actively led the field work for this paper. I identified the participants, carried out the clinical examinations and performed the confocal microscopy examinations over several months. Field supervision was provided by Matthew Burton over 4-5 days. I also analysed the confocal microscopy images and performed the statistical analysis, with some guidance from Helen Weiss. I wrote and submitted the paper with consideration of comments from co-authors.

Candidate’s signature.....

A handwritten signature in black ink, appearing to read 'J. Barton', is written on a light-colored rectangular background.

Supervisor or senior author’s signature to confirm role as stated in (2).....

In Vivo Confocal Microscopy of Trachoma in Relation to Normal Tarsal Conjunctiva

Victor H. Hu, MB, BCh, MRCOphth,^{1,2} Patrick Massae, DCEH,² Helen A. Weiss, PhD,³
Ian A. Cree, PhD, FRCPath,⁴ Paul Courtright, DrPh,² David C. W. Mabey, DM, FRCP,⁵
Robin L. Bailey, FRCP, PhD,⁵ Matthew J. Burton, FRCOphth, PhD^{1,2}

Objective: To describe the in vivo confocal microscopy (IVCM) appearances of the tarsal conjunctiva in trachoma compared with the appearance of healthy conjunctiva and to develop grading systems for IVCM examination of the tarsal conjunctiva for use in future studies on trachoma and other conjunctival diseases.

Design: Prospective observational study.

Participants: In vivo confocal microscopy examination was performed on 302 clinically normal adults, 16 clinically normal children, 750 adults with trichomatous conjunctival scarring, and 25 children with active trachoma.

Methods: Clinical evaluation was performed with $\times 2.5$ loupes, and IVCM examination of the upper tarsal conjunctiva was carried out with a Heidelberg Retina Tomograph 3 with the Rostock Cornea Module (Heidelberg Engineering GmbH, Dossenheim, Germany).

Main Outcome Measures: In vivo confocal microscopy images were analyzed for cellular and tissue changes associated with trichomatous inflammation and scarring compared with healthy subjects.

Results: Trichomatous subjects with follicular and papillary inflammation had an increased inflammatory cellular infiltrate, including dendritiform cells, discrete follicular and papillary structures, and cystic lacunae suggestive of tissue edema. Trichomatous conjunctival scarring was seen with IVCM as organization of the subepithelial connective tissue into bands/sheets. Grading systems for inflammatory changes and scarring were developed, with the system for scarring showing good interobserver agreement with an intraclass coefficient of 0.88.

Conclusions: In vivo confocal microscopy provides a powerful tool for examining the ocular surface. Numerous cellular and tissue changes were observed in subjects with trachoma, the first time IVCM has been applied to this disease. These changes both complement and add to previous histologic analyses. In vivo confocal microscopy promises to provide new insights into the pathogenesis of trachoma and other conjunctival diseases.

Financial Disclosure(s): The author(s) have no proprietary or commercial interest in any materials discussed in this article. *Ophthalmology* 2011;118:747–754 © 2011 by the American Academy of Ophthalmology.



Trachoma is caused by recurrent infection with *Chlamydia trachomatis*. The infection is most commonly found in children who develop a chronic follicular conjunctivitis with papillary hypertrophy, referred to as “active trachoma.” Later in life, such individuals are at risk of developing conjunctival scarring, entropion, trichiasis, and eventually blinding corneal opacification. Trachoma is an ancient disease that was previously endemic in Europe and North America but is now largely found in poor rural communities in the developing world. Trachoma remains the most common infectious cause of blindness globally with more than 1.3 million people blind from the disease, 8.2 million with trichiasis, and 40 million with active disease.^{1,2}

In vivo confocal microscopy (IVCM) is a noninvasive means of obtaining high-resolution tissue images down to the cellular level. The illumination and observation systems are focused on the same focal point, giving rise to the term

“confocal,” so that any light originating from outside the focal plane is highly suppressed. This allows a magnification of up to $800\times$ with an optical resolution of 1 to $2\ \mu\text{m}$. This relatively new technique has shown promise in the study of ocular surface disease, including corneal dystrophies, changes after refractive surgery, drug toxicity, and dendritic cell changes in inflammatory disease.^{3–5} The technique’s application to the study of ocular infections has shown that it is able to differentiate among bacterial, fungal, and protozoan agents.⁶ Although much of the work done so far has been concentrated on the cornea, several studies have reported interesting results on the conjunctiva, including changes in atopic keratoconjunctivitis, filtration blebs after glaucoma surgery, and inflammatory changes in response to bacterial lipopolysaccharide.^{3,7–11}

In vivo confocal microscopy has several advantages over alternative methods of studying cellular events in the conjunctiva. Histopathology of biopsy specimens, the “gold

standard," allows exceptional detail to be seen, but it is an invasive procedure in which usually only a small amount of tissue can be investigated and sequential examination over time is not feasible. In addition, there can be artefact changes in the tissue introduced during processing. Impression cytology can be useful; however, cells are probably collected from only the most superficial layers of the epithelium, and no information about the structure of the tissue is provided. In vivo confocal microscopy has not been associated with any adverse events, can be used repeatedly all over the ocular surface, and provides high-resolution images.

The pathogenesis of trachoma is poorly understood. The infection itself is believed to be limited to a small minority of the superficial conjunctival epithelial cells. It is generally accepted that much of the tissue damage in this disease is the result of a pathologic immune response.^{12–17} A limited serovar-specific protective immunity probably develops. However, it remains unclear why some individuals develop blinding sequelae and others do not (with a similar infection exposure), and what factors are important in the progression of scarring. In vivo confocal microscopy has the potential to provide useful insights into this disease process at the tissue level. Specifically, IVCN can reveal the morphology and distribution of fibrotic tissue within the palpebral conjunctiva. In addition, inflammatory cell infiltrates can be examined and related to the clinical phenotype.

This article presents descriptive findings from IVCN of the different clinical stages of trachoma and compares these with normal tarsal conjunctiva. We also propose a grading system for IVCN findings in subjects with trachoma to facilitate formal image analysis in ongoing studies. It is anticipated that this grading system will also have relevance for other immuno-fibrogenic diseases of the conjunctiva, such as mucous membrane pemphigoid and atopic keratoconjunctivitis.

Patients and Methods

Ethical Permission

The observations presented were made during the course of studies approved jointly by the London School of Hygiene and Tropical Medicine Ethics Committee, the Kilimanjaro Christian Medical Centre Ethics Committee, and the National Ethics Committee of the Tanzanian National Institute of Medical Research. Informed consent was obtained before enrollment of each subject.

Clinical Assessment

These studies were conducted in trachoma endemic communities in Siha District, Kilimanjaro Region, Northern Tanzania. Subjects were examined in a dark room or tent with $\times 2.5$ loupes and a bright torch. Signs of trachoma were graded using the 1981 detailed World Health Organization grading system, which assesses the upper palpebral conjunctiva for follicles, papillae, and scarring, and grades entropion/trichiasis and corneal opacity.¹⁸ A portable slit lamp was used if a more magnified view was needed, particularly to rule out subtle conjunctival scarring in normal controls. High-resolution digital photographs were taken of the upper tarsal conjunctiva.

The protocols for the ongoing related studies involved the recruitment of 800 adults with trachomatous conjunctival scarring and 360 adults without scarring. We attempted IVCN examinations on all consenting individuals. In a previously untreated village that was about to receive mass drug administration with azithromycin for trachoma control, we also performed IVCN examinations on children who could comfortably tolerate the procedure.

Confocal Microscopy Assessment

In vivo confocal microscopy was performed using the Heidelberg Retina Tomograph 3 (HRT3) in combination with the Rostock Cornea Module (RCM) (Heidelberg Engineering GmbH, Dossenheim, Germany). This uses a 670-nm diode laser as a light source with a $\times 63$ water-contact objective (Olympus Europa GmbH, Hamburg, Germany) covered with a sterile single-use polymethylmethacrylate (PMMA) cap (Tomocap, Heidelberg Engineering). A small amount of carbomer gel (GelTears, Chauvin Pharmaceuticals Ltd., Surrey, UK) was used as a coupling agent between the RCM lens and the cap. The device scans an area of $400 \times 400 \mu\text{m}$ with a magnification of $\times 800$ and a lateral resolution of $1 \mu\text{m}$.

The related study protocols required confocal examination of the upper tarsal conjunctiva in the left eye in adults and the right eye in children. Topical anesthesia was applied to the conjunctival sac (proxymetacaine 0.5%, Chauvin Pharmaceuticals Ltd., Surrey, UK), and the upper eyelid was everted. Additional coupling gel was not needed for the examination of the conjunctiva. The position of the HRT3/RCM unit was adjusted to bring the surface of the device into contact with the tarsal portion of the palpebral conjunctiva, with the assistance of a live-view side video camera. Scans were taken using the "volume" setting in which 40 coronal images are taken in rapid succession at $2.1\text{-}\mu\text{m}$ intervals from superficial to deep. Scans started at the conjunctival epithelial surface, and the final scan was at a depth of $85 \mu\text{m}$. It was generally found that the quality of the image became impaired beyond $85 \mu\text{m}$ with little structural detail visible. The brightness control was set on automatic. Ten volume scans were taken per patient from random locations across the tarsal conjunctiva. The total examination time was approximately 5 minutes. In selected patients, scans of the marginal portion of the palpebral conjunctiva were also obtained in a manner similar to those of the tarsal conjunctiva. None of the IVCN images shown in this article have had any adjustments made (e.g., in contrast or brightness) after being exported from the HRT3/RCM unit.

Results

Study Subjects

All IVCN examinations were performed as part of studies performed in a trachoma endemic area in Siha District of northern Tanzania. The descriptions of normal and diseased conjunctiva and the proposed grading systems are based on experience gained from IVCN examinations of 302 clinically normal adults (≥ 18 years), 16 clinically normal children (mean age 9.4 years, range 5–15 years), 750 adults with a wide range of trachomatous conjunctival scarring, and 25 children with active trachoma (mean 6.8 years, range 3–17 years).

Normal Palpebral Conjunctiva

In the tarsal portion of the healthy palpebral conjunctiva, round grey bodies can be seen at the surface, which probably represent epithelial cell nuclei (Fig 1A; further images of normal conjunctiva

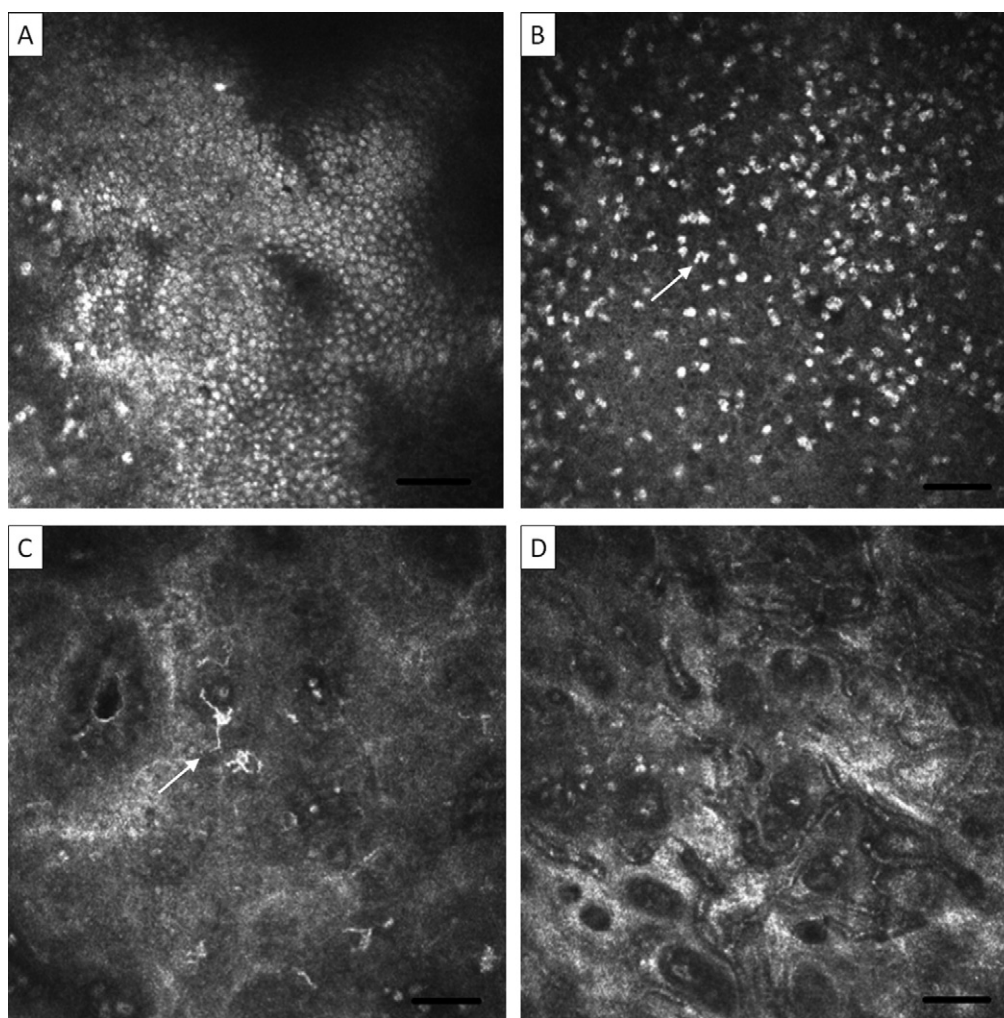


Figure 1. Normal tarsal conjunctiva. Images are $400 \times 400 \mu\text{m}$ with the bar representing $50 \mu\text{m}$. **A**, Superficial epithelial cell nuclei. **B**, Inflammatory cell nuclei; note heterogeneity in size and shape (arrow). **C**, Dendritic cells (arrow). **D**, Superficial blood vessels.

can also be seen in Fig 2, available at <http://aaojournal.org>). These are not always readily seen, and it is difficult to determine how many layers there are with IVCM. Scattered among the epithelial cells and extending beneath them are bright bodies (Fig 1B), which have been described as inflammatory cell nuclei. These are heterogeneous in size and shape, with some being circular and others multi-lobulated. These scattered presumed inflammatory cells are present to a depth of approximately $20 \mu\text{m}$. Dendritiform cells (DCs) are sometimes seen near the surface of the conjunctiva (Fig 1C). These appear as bright structures with cell bodies and multiple processes. In clinically normal conjunctiva, these processes are relatively short and there is usually no interdigitation with those of other DCs.

Round black spaces are often seen in the superficial conjunctiva, previously described as “microcysts” (Fig 2F, available at <http://aaojournal.org>). Sequential scanning shows these to be tubular in shape. The spaces contain highly reflective material, often in the form of discrete, round particles or cells. There is also often a bright reflection around their edge, suggestive of encapsulation. Approximately 20 to $30 \mu\text{m}$ below the surface, a fine network of small blood vessels is usually seen (Fig 1D). These are surrounded by brightly reflective fibrous material that is probably supportive connective tissue. Beneath the small blood vessels, there is loose

connective tissue within which few, if any, cells are seen (see Conjunctival Scarring section below). Deep blood vessels, which are much broader than the more superficial network, can be seen at variable depths with blood flowing inside (Fig 2H, available at <http://aaojournal.org>). Sometimes an oblique view is obtained (as opposed to the usual *en face*), as a result of unequal apposition of the PMMA cap on the conjunctival surface, which gives some appreciation of the various strata in the tissue (Fig 2I, available at <http://aaojournal.org>).

If confocal microscopy is performed on the marginal portion of the palpebral conjunctiva, next to the lid margin, then adenoid structures can be seen, which probably represent meibomian gland ducts or acinar units (Fig 2J, available at <http://aaojournal.org>). The IVCM appearance of palpebral conjunctiva in children and young adults is similar to that of older adults. One feature observed in the conjunctiva of approximately 20% of children (both clinically normal and inflamed) was fine blood vessels seen in cross-section (Fig 2K, available at <http://aaojournal.org>). Unlike the other small vessels mentioned above, which are parallel to the conjunctival surface, these vessels are perpendicular. They extended from a very superficial level to around the level of the usual vascular network at $20 \mu\text{m}$ and were surrounded with highly reflective connective tissue.

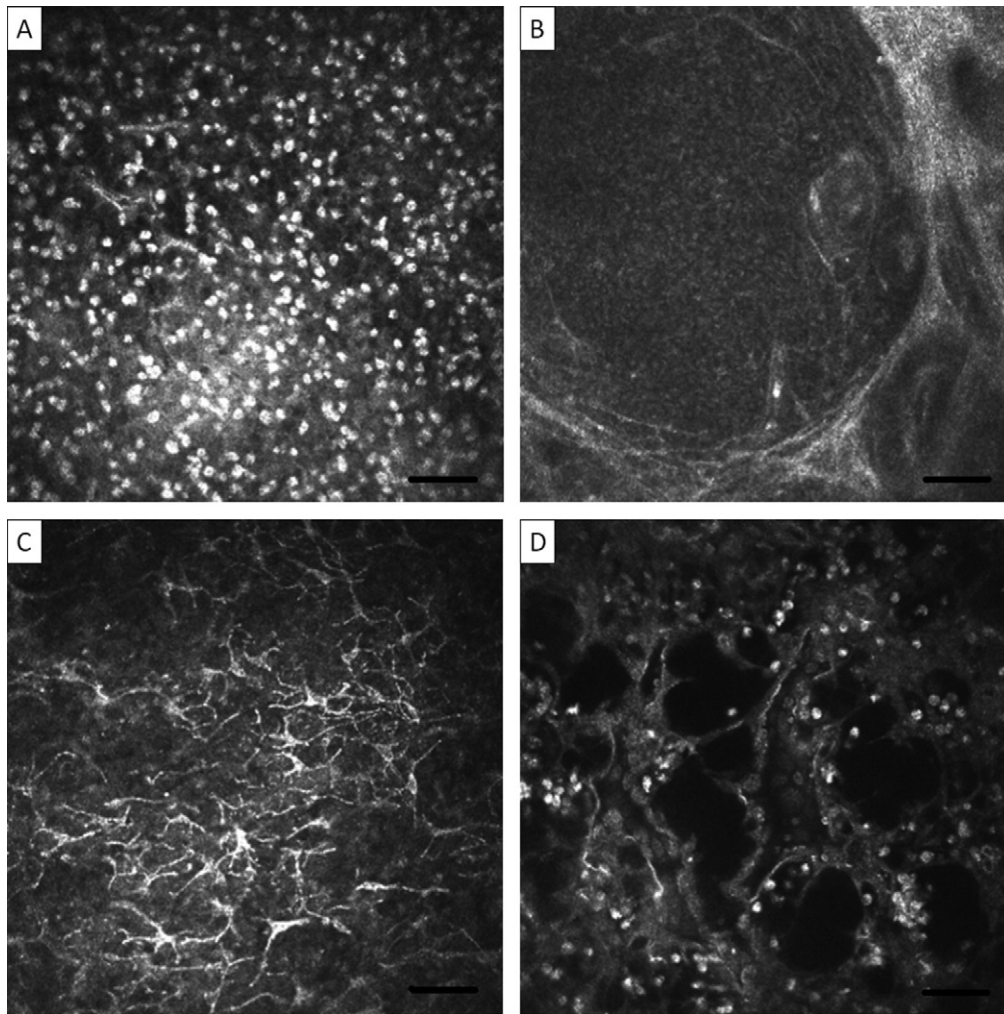


Figure 4. Active disease in adults with conjunctival scarring. Images are $400\times 400\mu\text{m}$ with the bar representing $50\mu\text{m}$. **A**, Increased inflammatory cell infiltrate. **B**, Follicular structure. **C**, Activated DCs. **D**, Cystic lacunae. DC = dendritiform cells.

Active Trachoma in Children

All of the children with active trachoma examined by IVCN were grade F2 or P2 on the World Health Organization grading system (i.e., having a significant number of follicles or papillary inflammation). Follicular structures occasionally were found (Fig 3A, available at <http://aaojournal.org>), which were formed of discrete collections of moderate to highly reflective round cell nuclei. They began at approximately $10\mu\text{m}$ below the surface and were roughly spherical with an estimated maximum diameter of approximately 0.5 to 1 mm.

Approximately half of the children with active disease had black, “cystic” spaces or lacunae near the conjunctival surface, which may reflect areas of tissue edema (Fig 3B, available at <http://aaojournal.org>; corresponding image from an adult is shown in Fig 4D). These lacunae were generally larger and more irregular in outline than the microcystic spaces seen in normal conjunctiva, and they did not have the surrounding bright edge, suggestive of encapsulation. These spaces were largely acellular with no flow seen, which suggests that they are not blood vessels. Approximately half of the children also had a network or honeycomb of interconnecting bands (Fig 3C, available at <http://aaojournal.org>). This network was seen near the surface and extended into the tissue for a variable distance. Small vessels were often seen near

the surface in the central areas of this network, and it is likely that this appearance represents tiny papillae. Dendritiform cells were seen more frequently in children with active disease and, when present, were more numerous and had longer dendritic processes that often interdigitated (Fig 3D, available at <http://aaojournal.org>).

Trachomatous Inflammation in Adults with Conjunctival Scarring

Clinical inflammation is often seen in adults with trachomatous scarring. In adults with clinical inflammation and scarring, IVCN often reveals an increase in the inflammatory cell infiltrate that was more marked than in children with active disease (Fig 4A; further images of conjunctiva from adults with inflammation and scarring can also be seen in Fig 5, available at <http://aaojournal.org>). This increased cellularity is most prominent in the superficial conjunctiva, rarely extending beyond $20\mu\text{m}$. Papilliform structures, composed of discrete conjunctival elevations with central vessels were seen with IVCN (Fig 5B, available at <http://aaojournal.org>). Follicular structures ($<0.5\text{ mm}$) were also observed in some subjects (Fig 4B), although follicles were rarely seen clinically. Cystic lacunae and DCs were also seen in adults (Fig 4C, D). The honeycomb of interconnecting bands was rarely seen.

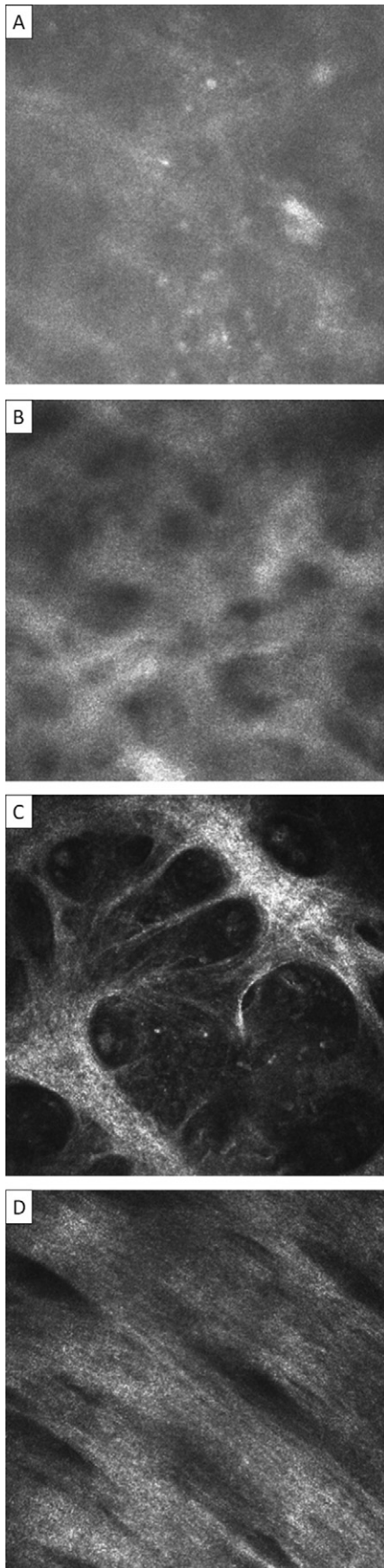


Table 1. Conjunctival Inflammation Grading System for In Vivo Confocal Microscopy

Feature	Grading Description
Inflammatory infiltrate	Mean inflammatory cell density of 3 randomly selected volume scans*
DCs	Present or absent: to be present, the mean number of DCs per volume scan needs to be ≥ 1 [†]
Tissue edema	Present or absent: present if seen in any volume scan
Papillae	Present or absent: present if seen in any volume scan

DC = dendritiform cells.

*Cell density is measured with the RCM software, for which it is suggested that a minimum of 50 cells is counted per field. See text for explanation of why 3 scans are selected. The individual scan with the largest density of cells from within the volume scan is used to calculate the density.

[†]The largest number of DCs in any individual scan in a particular volume scan is used.

For the evaluation of markers of inflammatory activity, we propose the grading scheme shown in Table 1. There was some variation in the inflammatory cell count density between images taken from different areas of the same conjunctival surface. For 30 subjects, we measured the cell count in the full 10 volume scans taken for each subject. From the variation in these estimates from the same lid, we found that the average cell count score of 3 random images provided sufficient precision.

Conjunctival Scarring

The appearance of the subepithelial connective tissue (starting at $\sim 30 \mu\text{m}$ from the surface) in individuals with clinically visible trachomatous conjunctival scarring varied widely. At the mild end of the spectrum, the appearance was similar to that seen in normal controls: mostly moderately reflective, amorphous tissue with a few fine, wispy strands randomly arranged. With increasing severity of clinically visible scarring, increasingly marked changes were found in the deeper subepithelial connective tissue. In the more severe cases, we observed broad bands of highly reflective connective tissue that were often arranged in parallel, with a striated “texture.” We interpret this appearance as organized bands of scar tissue. By reviewing these images, we developed a 4-point grading system for the degree of subepithelial connective tissue organization/scarring: normal to grade 3. Definitions and characteristic examples are provided in Figures 6 and 7 (available at <http://aaojournal.org>).

An overall IVCN connective tissue organization/scarring grade can be calculated with this grading system. Each volume scan is given a score of 0 (normal), 1 (grade 1), 2 (grade 2), or 3 (grade 3). If the grade varies between the individual images of the volume

Figure 6. Conjunctival connective tissue organization/scarring grading system for IVCN. Images are $400 \times 400 \mu\text{m}$. **A**, Normal: homogenous, amorphous appearance with occasional fine, wispy strand. **B**, Grade 1: Heterogeneous appearance with poorly defined clumps or bands present. **C**, Grade 2: clearly defined bands of tissue that constitute $< 50\%$ of the area of the scan. **D**, Grade 3: clearly defined bands or sheets of tissue that constitute $\geq 50\%$ of the area of the scan and in which striations are visible. If different grades of scarring are seen within a particular volume scan, then the highest grade is recorded. The connective tissue that is graded needs to be separate from that associated with the vascular tissue; if this is not possible then the scan is considered ungradable. IVCN = in vivo confocal microscopy.

scan, then the highest grade is used. The mean score for that patient is then calculated by dividing the sum of the volume scan scores by the number of volume scans read. At least 3 gradable volume scans need to be available to generate a mean score. The minimum score possible is therefore 0 and the maximum is 3 (if each volume scan score was 0 or 3, respectively).

Interobserver agreement was assessed by calculating the intraclass correlation coefficient on the mean scores of 50 patients. These were graded independently by VH and MB, who were also masked to the clinical appearance. The intraclass correlation coefficient showed a high agreement of 0.88, that is, 88% of the total variance was due to between individual variation (rather than between observer variation).

As described in the methodology, up to 10 sets of volume scans were taken from each subject. We found that the scarring grade generally showed little variation between the multiple images taken from different areas of the same tarsal conjunctiva. Analysis of the image grading of 50 randomly selected subjects with conjunctival scarring showed that all the separate volume scans of 74% of individuals had a difference of ≤ 1 (i.e., all scores were within 1 grade of each other). Only 1 individual had a range of 3.

Meibomian glands were not systematically imaged as part of the study protocols. However, acinar units at the marginal epithelium were seen in a few subjects with trachomatous scarring. In a limited number of scans, the lumen of these acinar units was seen to contain low reflectivity material, possibly scar tissue (Fig 8A, available at <http://aaojournal.org>). The walls of the units were also poorly defined, in contrast with those from normal subjects. In subjects with more advanced scarring, concretions were also a frequent finding (Fig 8B, available at <http://aaojournal.org>).

Discussion

The pathogenesis of trachoma has been studied from various angles, but these have tended not to show what is happening at a tissue or cellular level.^{19–22} A number of studies have used histopathology and immunohistochemistry. However, these involve an invasive biopsy procedure and analysis is restricted to a tiny amount of tissue.²³ We have carried out a large number of IVCN examinations in both trachomatous and clinically non-scarred subjects to gain insights into the pathophysiology of progressive conjunctival scarring in trachoma. To the best of our knowledge, this is the first time IVCN has been reported from individuals with trachoma or from children.

Follicular and papillary inflammation are the key features of active trachoma. Follicular structures can be seen with IVCN in the subepithelial tissue, probably composed of the nuclei of inflammatory cells and corresponding to follicles seen clinically. Histologic analysis has shown these to be composed mainly of B cells with some macrophages and T cells.^{23,24} Follicles in adults may be seen on histology without being a prominent clinical feature, and these follicles seem to be morphologically distinct from those in children in that they lack germinal centers.²⁵

Papillae are composed of engorged blood vessels with an edematous/inflamed overlying epithelium that varies in size. Adults with inflammation commonly had papillae seen with IVCN. These have been noted in the palpebral conjunctiva of patients with atopic keratoconjunctivitis.¹⁰ These papillae were not commonly seen among children with active disease. Children did, however, often have structures corre-

sponding to tiny, or micro, papillae: (1) a honeycomb appearance of the tissue with small blood vessels within the cells of the honeycomb and (2) small, superficial vessels perpendicular to the conjunctival surface with prominent surrounding connective tissue. The latter were seen in children with and without clinically apparent inflammation. We suggest that these vessels formed during papillary inflammation and slowly recede once the inflammation has resolved. We would not, therefore, expect this appearance to be found in a population of children from a non-trachoma endemic area.

Another morphologic change seen in active trachoma is the appearance of what has been described as “inflammatory lacunae.”²⁶ A feature of active trachoma is thickening of the upper tarsal conjunctiva probably due to edema,²⁷ and this probably corresponds to the IVCN finding of these lacunar spaces. This edema has not been observed in histologic studies. However, the processing of histopathology specimens may cause disruption with loss of the spaces.

Changes in cell populations were seen in both children and adults with clinical inflammation. The brightly reflective nuclei seen within and below the epithelium probably belong to inflammatory cells, such as neutrophils or lymphocytes.^{7,10,11,28} This inflammatory infiltrate has been found to be elevated in patients with atopic keratoconjunctivitis compared with controls.²⁶ In addition, subconjunctival injection of lipopolysaccharide in rabbit eyes resulted in a significant increase in the infiltrate.¹¹ Histopathologic analysis shows a marked inflammatory infiltrate in trachoma of mixed cell types,^{23,25,29} and IVCN shows that this inflammatory infiltrate is generally limited to the superficial 20 μm .

Dendritiform cells have been found with ocular surface IVCN, and studies have been done on their density and distribution in the cornea.^{5,30} We found DCs to be increased in children and adults with inflammation and that they had longer dendritic processes that frequently interdigitated. In addition to being the only antigen-presenting cells that are able to induce primary immune responses, dendritic cells are also important in the regulation of the type of T-cell response and the development of immunologic tolerance.^{31,32} The type of immune response (e.g., a type 1 vs type 2 T-helper response) seems to be important in trachoma in determining whether infection is resolved rapidly or a chronic inflammatory reaction develops.^{20,33,34} The study of dendritic cells in trachoma is also important because their role is likely to be important in the design of any chlamydial vaccine.³⁵ However, although IVCN studies have generally labeled DCs as being Langerhans or dendritic cells, immunohistochemistry is needed because other cell types may also have a dendritic morphology.

We are aware of 2 previously published IVCN images of conjunctival scarring. The first of these was from patients with atopic keratoconjunctivitis with an appearance similar to that found in trachoma with organized bands of connective tissue.¹⁰ The second report shows an unusual honeycomb type appearance that we have not observed elsewhere.⁸ The subepithelial tissue of nonfunctioning blebs shows dense connective tissue with few or no clear spaces, similar to that observed in scarred subjects. Histologic stud-

ies of trachomatous scarring have shown the conjunctival stroma to be replaced with compact, largely avascular scar tissue.^{36,37} The tissue organization that we observed with IVCM probably shows collagen fibrils that, in keeping with the histology, may be haphazardly arranged or, in more advanced cases, parallel to each other.

In addition to studying subjects with trachoma, we also examined the palpebral conjunctiva of a larger number of healthy subjects than has previously been done. The appearance of the tarsal conjunctiva in healthy children is largely similar to that of adults. Images of epithelial cells of the tarsal conjunctiva in an oblique view have been published, which are similar to those we found.⁷ It has been reported, using IVCM, that the palpebral conjunctival epithelium is organized in 6 to 7 cell layers.²⁸ However, this was also based on an oblique view that may have overestimated the number of layers, which was significantly more than we or previous histologic studies found.³⁸ Another published image of the palpebral conjunctival epithelium probably shows images from the marginal portion of the palpebral conjunctiva,³⁹ shown from one of our study subjects in Figure 9 (available at <http://aojournal.org>).

The “microcystic” spaces that we found in normal palpebral conjunctival epithelium have been observed by other investigators.^{8,39} It is only speculative whether these spaces are actually cystic because it is unknown whether they are lined by epithelium. It is also unknown what these spaces and the debris seen within them represent. It has been suggested that they are occluded goblet cells,³⁹ although they seem too large for this and to extend too deep into the tissue. They may represent mucous crypts, which are tubular structures consisting of clusters of goblet cells arranged around a central lumen with an overall diameter of 50 μm .³⁸ Kessing⁴⁰ states that there may be stagnation of mucin in these crypts leading to the formation of cysts. Goblet cells are not visible perhaps because they are of a similar reflectivity to the surrounding tissue in the palpebral conjunctiva and the HRT3/RCM is unable to differentiate them.

In vivo confocal microscopy offers a unique opportunity of studying tissue morphology and cellular activity in normal and diseased states. It is not invasive or harmful and can be used repeatedly. A high level of resolution is gained, almost comparable to histologic analysis. Once proficiency with the HRT3/RCM is achieved, images can be obtained within a few minutes, and we have found the machine to be robust and portable. There are, however, some limitations with the technique. The RCM requires contact with the tissue surface, which is not always well tolerated despite topical anesthesia. It can be difficult to satisfactorily position the everted upper lid, especially if the subject has limited mobility. The PMMA cap is currently relatively large and can impede good positioning on the conjunctival surface. The combination of the large cap and very small image area precludes identification of the exact location being imaged. The exact same area cannot, therefore, be imaged sequentially to observe temporal changes. In vivo confocal microscopy in its current state cannot be used in conjunction with tissue/cellular staining, an integral part of histologic-immunohistochemical analysis that yields much valuable information. In vivo confocal microscopy is a

relatively new technique, and histologic confirmation of these appearances is needed. We are currently in the process of conducting a case-control study of subjects with trachomatous trichiasis who are undergoing conjunctival biopsies at the time of trichiasis surgery. This will enable a systematic comparison of IVCM and histologic findings.

In conclusion, this article presents descriptive IVCM findings gained from examining a large number of subjects with trachoma compared with healthy control subjects, including children. We also present grading systems for analyzing conjunctival images. We are currently applying this grading system to a large case-control study of trachomatous scarring in which we are correlating confocal microscopy findings with clinical grading. We hope the descriptions presented will be of help in the interpretation of images from patients with a range of conjunctival diseases and further our understanding of trachomatous inflammation, scarring, and blindness.

References

1. Resnikoff S, Pascolini D, Etya'ale D, et al. Global data on visual impairment in the year 2002. *Bull World Health Organ* 2004;82:844–51.
2. Mariotti SP, Pascolini D, Rose-Nussbaumer J. Trachoma: global magnitude of a preventable cause of blindness. *Br J Ophthalmol* 2009;93:563–8.
3. Guthoff RF, Baudouin C, Stave J. Atlas of Confocal Laser Scanning In-vivo Microscopy in Ophthalmology. Berlin: Springer; 2006:89–90.
4. Chiou AG, Kaufman SC, Kaufman HE, Beuerman RW. Clinical corneal confocal microscopy. *Surv Ophthalmol* 2006;51:482–500.
5. Mastropasqua L, Nubile M, Lanzini M, et al. Epithelial dendritic cell distribution in normal and inflamed human cornea: in vivo confocal microscopy study. *Am J Ophthalmol* 2006; 142:736–44.
6. Guthoff RF, Zhivov A, Stachs O. In vivo confocal microscopy, an inner vision of the cornea—a major review. *Clin Experiment Ophthalmol* 2009;37:100–17.
7. Kobayashi A, Yoshita T, Sugiyama K. In vivo findings of the bulbar/palpebral conjunctiva and presumed meibomian glands by laser scanning confocal microscopy. *Cornea* 2005;24:985–8.
8. Messmer EM, Mackert MJ, Zapp DM, Kampik A. In vivo confocal microscopy of normal conjunctiva and conjunctivitis. *Cornea* 2006;25:781–8.
9. Messmer EM, Zapp DM, Mackert MJ, et al. In vivo confocal microscopy of filtering blebs after trabeculectomy. *Arch Ophthalmol* 2006;124:1095–103.
10. Hu Y, Adan ES, Matsumoto Y, et al. Conjunctival in vivo confocal scanning laser microscopy in patients with atopic keratoconjunctivitis. *Mol Vis* [serial online] 2007;13:1379–89. Available at: <http://www.molvis.org/molvis/v13/a152/>. Accessed July 25, 2010.
11. Liang H, Baudouin C, Labbe A, et al. In vivo confocal microscopy and ex vivo flow cytometry: new tools for assessing ocular inflammation applied to rabbit lipopolysaccharide-induced conjunctivitis. *Mol Vis* [serial online] 2006;12:1392–402. Available at: <http://www.molvis.org/molvis/v12/a157/>. Accessed July 25, 2010.
12. Jawetz E, Rose L, Hanna L, Thygeson P. Experimental inclusion conjunctivitis in man: measurements of infectivity and resistance. *JAMA* 1965;194:620–32.

13. Tarizzo ML, Nataf R, Nabli B. Experimental inoculation of thirteen volunteers with agent isolated from inclusion conjunctivitis. *Am J Ophthalmol* 1967;63(suppl):1120–8.
14. Bailey R, Duong T, Carpenter R, et al. The duration of human ocular *Chlamydia trachomatis* infection is age dependent. *Epidemiol Infect* 1999;123:479–86.
15. Brunham RC, Peeling RW. *Chlamydia trachomatis* antigens: role in immunity and pathogenesis. *Infect Agents Dis* 1994; 3:218–33.
16. Taylor HR. *Trachoma: a Blinding Scourge from the Bronze Age to the Twenty-First Century*. East Melbourne, Australia: Center for Eye Research Australia/Haddington Press; 2008:145–62.
17. Silverstein AM. The immunologic modulation of infectious disease pathogenesis. *Friedenwald Lecture, 1973. Invest Ophthalmol* 1974;13:560–74.
18. Dawson CR, Jones BR, Tarizzo ML. *Guide to Trachoma Control in programmes for the prevention of blindness*. Geneva: World Health Organization; 1981:12–18. Available at: <http://whqlibdoc.who.int/publications/1981/9241541571.pdf>. Accessed July 25, 2010.
19. Natividad A, Wilson J, Koch O, et al. Risk of trachomatous scarring and trichiasis in Gambians varies with SNP haplotypes at the interferon-gamma and interleukin-10 loci. *Genes Immun* 2005;6:332–40.
20. Holland MJ, Bailey RL, Conway DJ, et al. T helper type-1 (Th1)/Th2 profiles of peripheral blood mononuclear cells (PBMC): responses to antigens of *Chlamydia trachomatis* in subjects with severe trachomatous scarring. *Clin Exp Immunol* 1996;105:429–35.
21. Burton MJ, Bailey RL, Jeffries D, et al. Cytokine and fibrogenic gene expression in the conjunctivas of subjects from a Gambian community where trachoma is endemic. *Infect Immun* 2004;72:7352–6.
22. Blodi BA, Byrne KA, Tabbara KF. Goblet cell population among patients with inactive trachoma. *Int Ophthalmol* 1988; 12:41–5.
23. el-Asrar AM, Van den Oord JJ, Geboes K, et al. Immunopathology of trachomatous conjunctivitis. *Br J Ophthalmol* 1989;73:276–82.
24. Abu el-Asrar AM, Geboes K, Tabbara KF, et al. Immunopathogenesis of conjunctival scarring in trachoma. *Eye (Lond)* 1998;12:453–60.
25. Reacher MH, Pe'er J, Rapoza PA, et al. T cells and trachoma: their role in cicatricial disease. *Ophthalmology* 1991;98: 334–41.
26. Wakamatsu TH, Okada N, Kojima T, et al. Evaluation of conjunctival inflammatory status by confocal scanning laser microscopy and conjunctival brush cytology in patients with atopic keratoconjunctivitis (AKC). [serial online] *Mol Vis* 2009;15:1611–9. Available at: <http://www.molvis.org/molvis/v15/a172/>. Accessed July 25, 2010.
27. Thylefors B, Dawson CR, Jones BR, et al. A simple system for the assessment of trachoma and its complications. *Bull World Health Organ* 1987;65:477–83.
28. Zhivov A, Stachs O, Kraak R, et al. In vivo confocal microscopy of the ocular surface. *Ocul Surf* 2006;4:81–93.
29. Abrahams C, Ballard RC, Sutter EE. The pathology of trachoma in a black South African population: light microscopical, histochemical and electron microscopical findings. *S Afr Med J* 1979;55:1115–8.
30. Zhivov A, Stave J, Vollmar B, Guthoff R. In vivo confocal microscopic evaluation of Langerhans cell density and distribution in the corneal epithelium of healthy volunteers and contact lens wearers. *Cornea* 2007;26:47–54.
31. Sato K, Fujita S. Dendritic cells: nature and classification. *Allergol Int* 2007;56:183–91.
32. Banchereau J, Briere F, Caux C, et al. Immunobiology of dendritic cells. *Annu Rev Immunol* 2000;18:767–811.
33. Debattista J, Timms P, Allan J, Allan J. Immunopathogenesis of *Chlamydia trachomatis* infections in women. *Fertil Steril* 2003;79:1273–87.
34. Holland MJ, Bailey RL, Hayes LJ, et al. Conjunctival scarring in trachoma is associated with depressed cell-mediated immune responses to chlamydial antigens. *J Infect Dis* 1993;168: 1528–31.
35. Brunham RC, Rey-Ladino J. Immunology of *Chlamydia* infection: implications for a *Chlamydia trachomatis* vaccine. *Nat Rev Immunol* 2005;5:149–61.
36. Guzey M, Ozardali I, Basar E, et al. A survey of trachoma: the histopathology and the mechanism of progressive cicatrization of eyelid tissues. *Ophthalmologica* 2000;214:277–84.
37. al-Rajhi AA, Hidayat A, Nasr A, al-Faran M. The histopathology and the mechanism of entropion in patients with trachoma. *Ophthalmology* 1993;100:1293–6.
38. Bron AJ, Tripathi RC, Tripathi BJ. *Wolff's Anatomy of the Eye and Orbit*. 8th ed. London: Chapman and Hall Medical; 1997:51–70.
39. Efron N, Al-Dossari M, Pritchard N. In vivo confocal microscopy of the palpebral conjunctiva and tarsal plate. *Optom Vis Sci* 2009;86:E1303–8.
40. Kessing SV. Mucous gland system of the conjunctiva: a quantitative mucosal anatomical study. *Acta Ophthalmol (Copenh)* 1968;46(suppl 95):1–131.

Footnotes and Financial Disclosures

Originally received: April 3, 2010.

Final revision: August 16, 2010.

Accepted: August 17, 2010.

Available online: November 5, 2010. Manuscript no. 2010-492.

¹ International Centre for Eye Health, Department of Infectious and Tropical Diseases, London School of Hygiene and Tropical Medicine, London, United Kingdom.

² Kilimanjaro Centre for Community Ophthalmology, Moshi, Tanzania.

³ MRC Tropical Epidemiology Group, London School of Hygiene and Tropical Medicine, London, United Kingdom.

⁴ Department of Pathology, Institute of Ophthalmology, University College London, United Kingdom.

⁵ Clinical Research Unit, Department of Infectious and Tropical Diseases, London School of Hygiene and Tropical Medicine, London, United Kingdom.

Financial Disclosure(s):

The author(s) have no proprietary or commercial interest in any materials discussed in this article.

This study was funded by a fellowship grant to MJB from the Wellcome Trust (080741/Z/06/Z). VHH is supported by a fellowship grant from the British Council for the Prevention of Blindness (Barrie Jones Fellowship). The funders had no part in the study design; in the collection, analysis, and interpretation of data; in the writing of the report; and in the decision to submit the paper for publication.

Correspondence:

Victor Hu, MB, BCh, MRCPH, International Centre for Eye Health, London School of Hygiene and Tropical Medicine, Keppel Street, London, WC1E 7HT, United Kingdom. E-mail: victor.hu@lshtm.ac.uk.

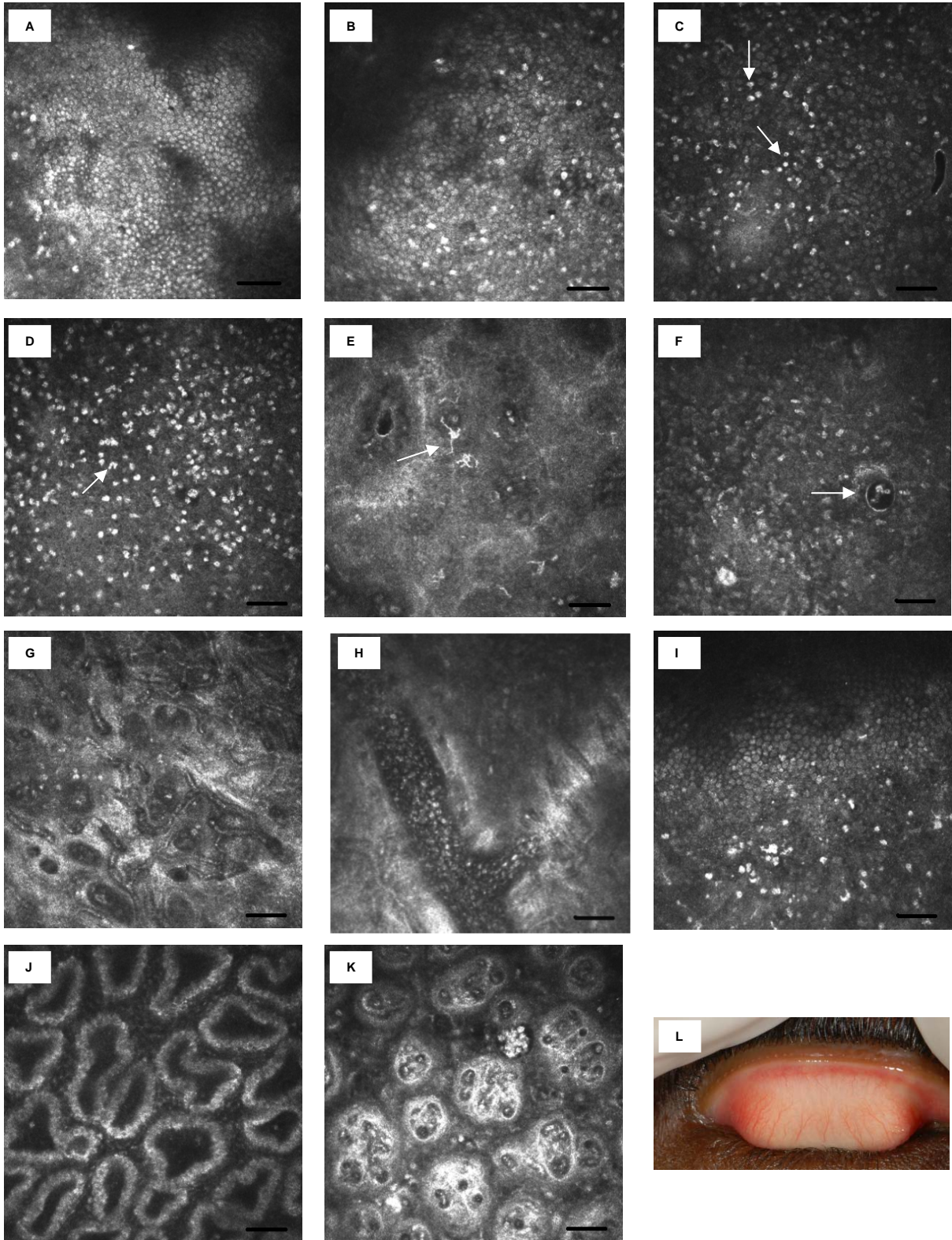


Figure 2. Normal tarsal conjunctiva. Images are 400×400µm with the bar representing 50µm. **A-B**, Superficial epithelial cell nuclei. **C**, Deep epithelial cell nuclei with some brightly reflective inflammatory cell nuclei also visible (arrows). **D**, Inflammatory cell nuclei, note heterogeneity in size and shape (arrow). **E**, Dendritic cells (arrow). **F**, Microcyst (arrow). **G**,

Superficial blood vessels. **H**, Deep blood vessel. **I**, Oblique view. **J**, Meibomian gland acinar units. **K**, Superficial blood vessels perpendicular to the surface with brightly reflective surrounding connective tissue. **L**, Clinical photograph of normal palpebral conjunctiva.

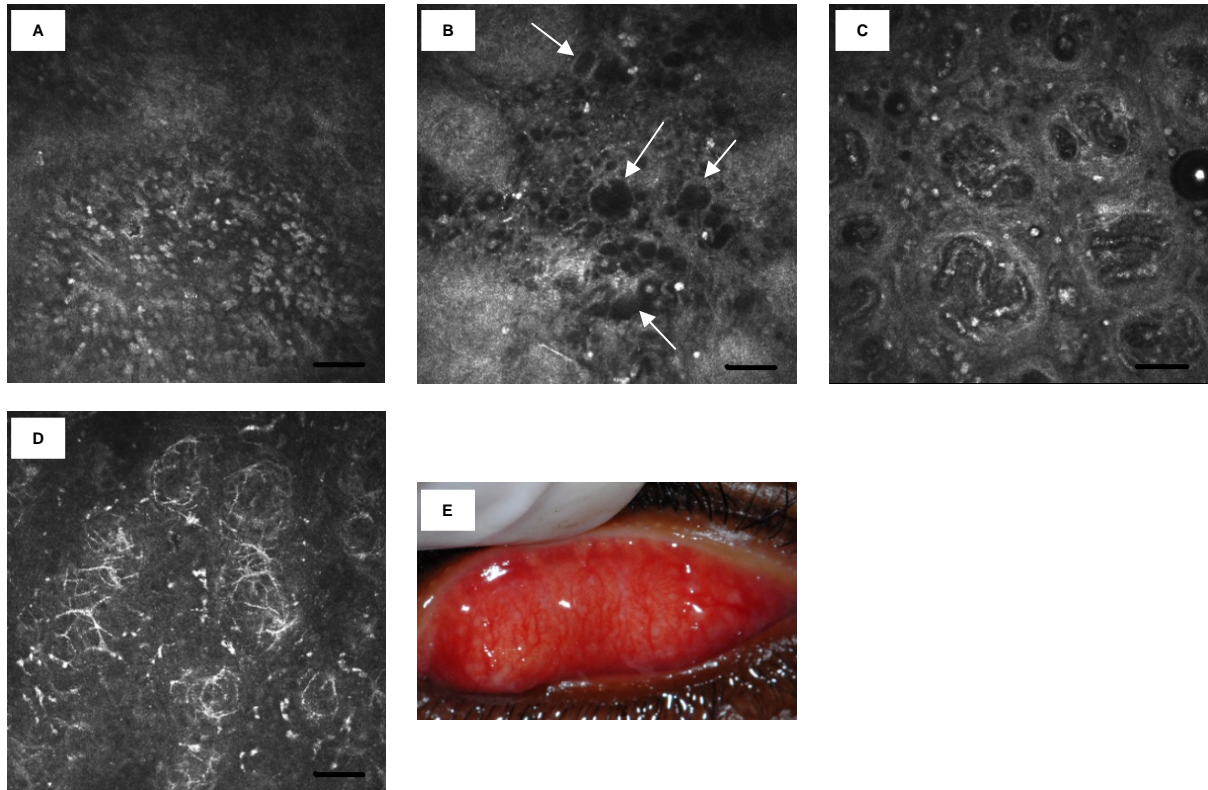


Figure 3. Active disease in children. Images are 400×400µm with the bar representing 50µm. **A**, Follicle at a depth of 20µm. **B**, Cystic lacunae (arrows). The tissue at the edges of this image has some resemblance to early lymphocyte cell aggregates, but no cellularity is seen on further sections at different depths. **C**, Honeycomb with central blood vessels. **D**, Numerous, inter-digitating dendritiform cells. **E**, Clinical photograph of the subject shown in A, note numerous follicles.

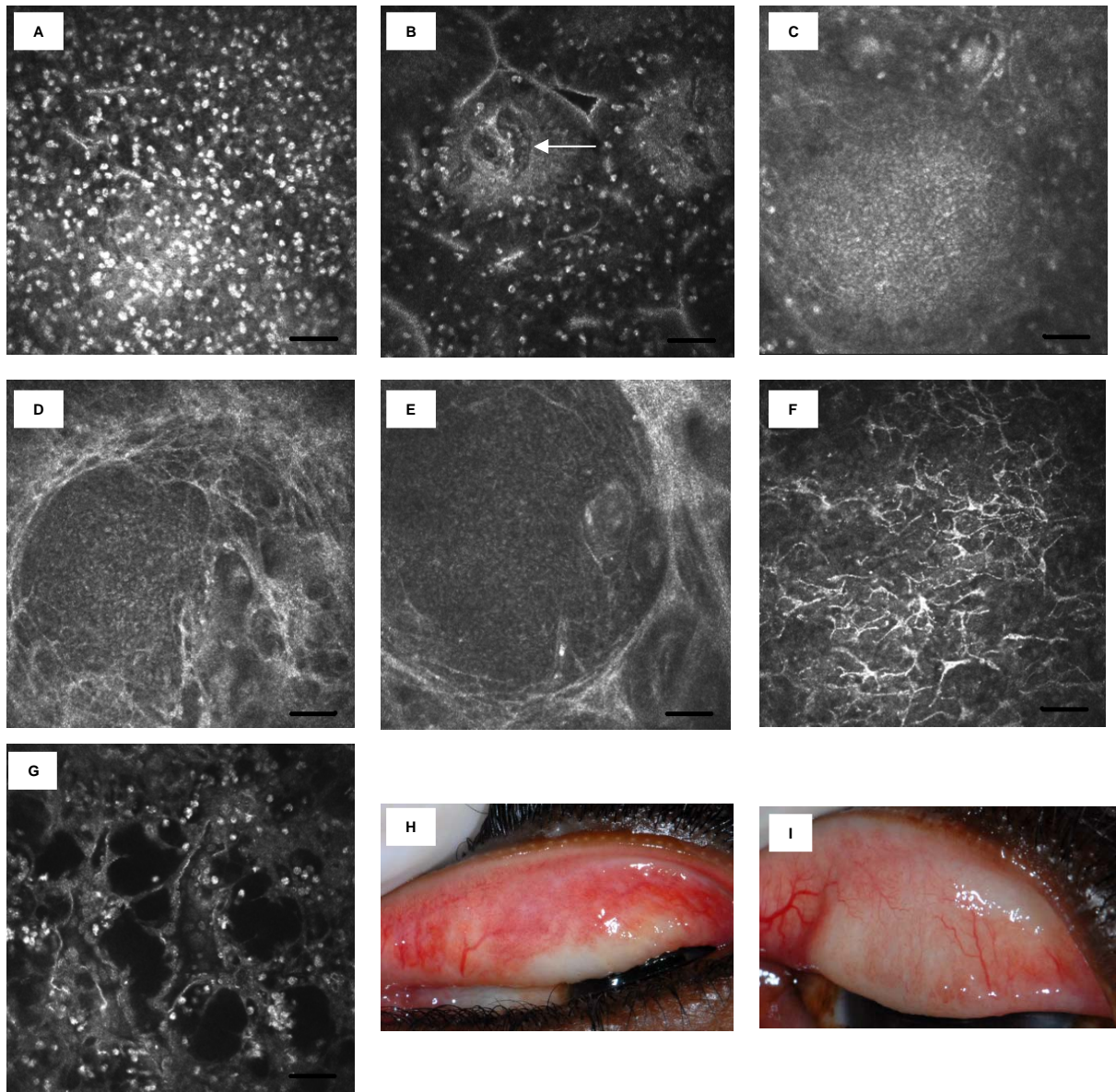




Figure 5. Active disease in adults with conjunctival scarring. Images are 400×400µm with the bar representing 50µm. **A**, Increased inflammatory cell infiltrate. **B**, Papillae with central vessels (arrow). **C-E**, Follicles at various depths. **F**, activated dendritiform cells. **G**, Cystic lacunae. **H**, Clinical photograph of the subject shown in A, note bands of scarring and papillary inflammation with obscuration of deep vessels. **I**, clinical photograph of the subject shown in C, note bands of scarring but lack of prominent follicles.

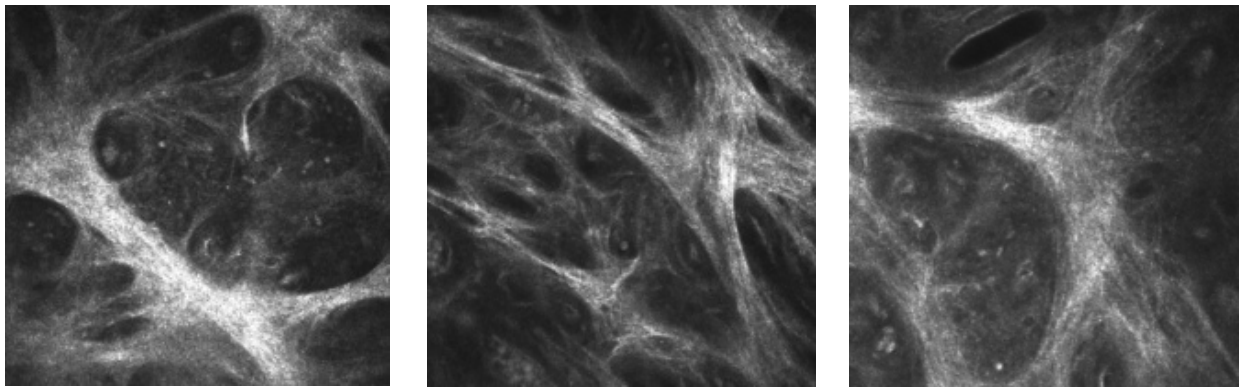
Normal: Homogeneous, amorphous appearance, with occasional fine, wispy strands.



Grade 1: Heterogeneous appearance with poorly defined clumps or bands present.



Grade 2: Clearly defined bands of tissue which constitute less than 50% of the area of the scan.



Grade 3: Clearly defined bands or sheets of tissue which constitute 50% or more of the area of the scan and in which striations are visible.




Figure 7. Conjunctival connective tissue organization/scarring grading system for *in vivo* confocal microscopy. Images are 400×400µm. If different grades of scarring are seen within a particular volume scan then the highest grade is recorded. The connective tissue which is graded needs to be separate from that associated with the vascular tissue, if this is not possible then the scan is considered ungradable.

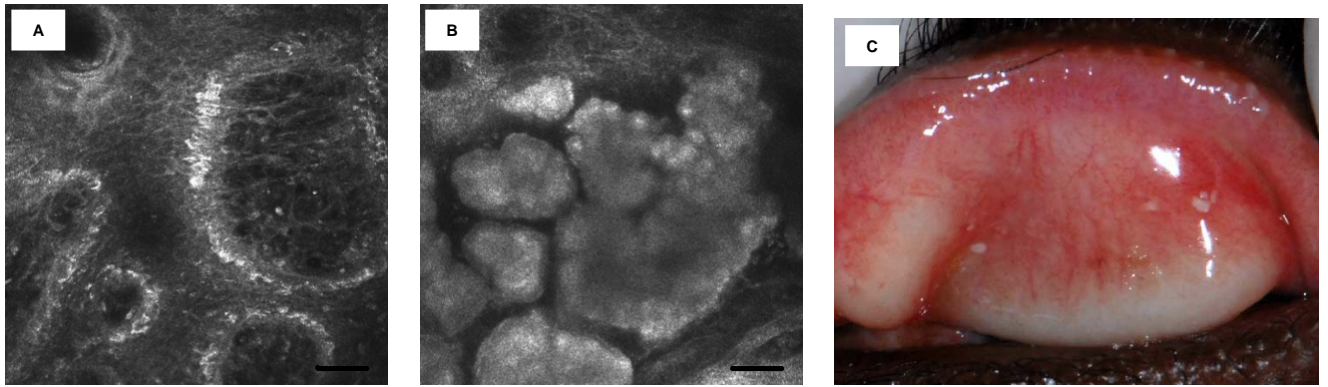


Figure 8. Meibomian gland scarring and concretions in trachoma. Images are 400×400µm with the bar representing 50µm. **A**, Scar tissue in the lumen of meibomian gland acinar units. **B**, concretions. **C**, clinical photograph of the subject shown in B, note concretions.

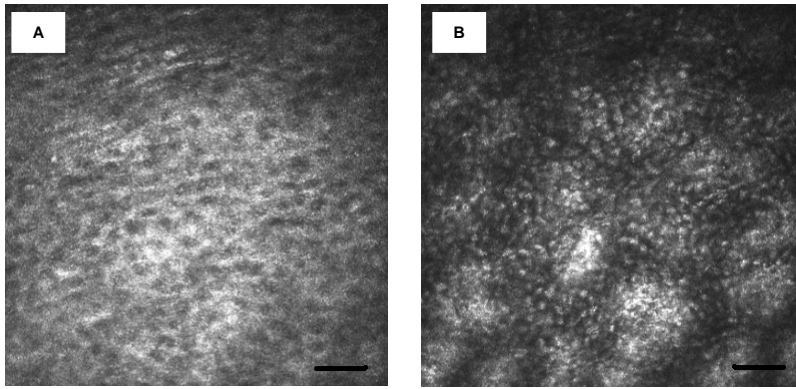


Figure 9. Lid margin epithelium. Images are 400×400µm with the bar representing 50µm. **A**, superficial epithelium. **B**, deeper epithelium.

Chapter 9

***In vivo* confocal microscopy in scarring trachoma**



Research paper looking at the results of *in vivo* confocal microscopy analysis in cases with trachomatous scarring compared to controls

Cover sheet for each ‘research/review paper’ included in a research thesis

1. For a ‘research/review paper’ already published

- 1.1. Where was the work published? **Ophthalmology**
- 1.2. When was the work published? **September 2011 (Epub ahead of print)**
- 1.3. Was the work subject to academic peer review? **Yes**
- 1.4. Have you retained the copyright for the work? **No**

If no, or if the work is being included in its published format, attach evidence of permission from copyright holder (publisher or other author) to include work

See Appendix 7d

2. For multi-authored work, give full details of your role in the research included in the paper and in the preparation of the paper. (Attach a further sheet if necessary)

I coordinated and actively led the field work for this paper. I identified the participants, carried out the clinical examinations and performed the confocal microscopy examinations over several months. Field supervision was provided by Matthew Burton over 4-5 days. I also analysed the confocal microscopy images and performed the statistical analysis, with some guidance from Helen Weiss. I wrote and submitted the paper with consideration of comments from co-authors.

Candidate’s signature.....

A handwritten signature in black ink that reads "M. Burton." The signature is written in a cursive style with a large initial 'M' and a period at the end.

Supervisor or senior author’s signature to confirm role as stated in (2).....

In Vivo Confocal Microscopy in Scarring Trachoma

Victor H. Hu, MBBCh, MRCPophth,^{1,2} Helen A. Weiss, PhD,³ Patrick Massae, DCEH,²
 AQ:1-2 Paul Courtright, DrPH,² William Makupa, MMED David C. W. Mabey, DM, FRCP,⁴
 Robin L. Bailey, PhD, FRCP,⁴ Matthew J. Burton, PhD, FRCOphth^{1,2}

Objective: To characterize the tissue and cellular changes found in trachomatous scarring (TS) and inflammation using in vivo confocal microscopy (IVCM).

Design: Two complimentary case-control studies.

Participants: The first study included 363 cases with TS (without trichiasis), of whom 328 had IVCM assessment, and 363 control subjects, of whom 319 had IVCM assessment. The second study included 34 cases with trachomatous trichiasis (TT), of whom 28 had IVCM assessment, and 33 control subjects, of whom 26 had IVCM assessment.

Methods: All participants were examined with $\times 2.5$ loupes. The IVCM examination of the upper tarsal conjunctiva was carried out with a Heidelberg Retina Tomograph 3 with the Rostock Cornea Module (Heidelberg Engineering GmbH, Dossenheim, Germany).

Main Outcome Measures: The IVCM images were graded in a masked manner using a previously published grading system evaluating the inflammatory infiltrate density; the presence or absence of dendritiform cells (DCs), tissue edema, and papillae; and the level of subepithelial connective tissue organization.

Results: Subjects with clinical scarring had a characteristic appearance on IVCM of well-defined bands and sheets of scar tissue visible. Similar changes were also seen in some clinically normal subjects consistent with subclinical scarring. Scarred subjects had more DCs and an elevated inflammatory infiltrate, even after adjusting for other factors, including the level of clinical inflammation. Cellular activity was usually seen only in or just below the epithelium, rarely being seen deeper than 30 μm from the surface. The presence of tissue edema was strongly associated with the level of clinical inflammation.

Conclusions: In vivo confocal microscopy can be quantitatively used to study inflammatory and scarring changes in the conjunctiva. Dendritic cells seem to be closely associated with the scarring process in trachoma and are likely to be an important target in antifibrotic therapies or the development of a chlamydial vaccine. The increased number of inflammatory cells seen in scarred subjects is consistent with the immunopathologic nature of the disease. The localization of cellular activity close to the conjunctival surface supports the view that the epithelium plays a central role in the pathogenesis of trachoma.

Financial Disclosure(s): The author(s) have no proprietary or commercial interest in any materials discussed in this article. *Ophthalmology* 2011;xx:xxx © 2011 by the American Academy of Ophthalmology.



Trachoma is a chronic, cicatrizing keratoconjunctivitis and is the most common infectious cause of blindness globally.¹ Trachoma is caused by infection with *Chlamydia trachomatis*, serovars A–C. In endemic regions, chlamydial infection is most frequently found in children, who develop a follicular and papillary conjunctivitis and sometimes corneal pannus (vascular infiltration). After repeated episodes of infection and inflammation, the scarring complications of trachoma develop: conjunctival scarring, entropion, trichiasis, and corneal opacity. Although there has been an encouraging downward trend in the number of people with active trachoma over the last 3 decades, this disease remains a significant public health problem in >50 countries.²

Despite numerous studies on the pathogenesis of scarring trachoma, the factors driving the late-stage scarring process and the immunofibrogenic responses involved remain to be

elucidated.³ In vivo confocal microscopy (IVCM) is a new technique that provides high-resolution images of the ocular surface down to the cellular level. It has been used to study a wide range of infectious, inflammatory, and metabolic disease processes affecting the ocular surface.^{4–9} We have previously reported a description of the main features of trachoma seen with IVCM and a new grading system for the quantitative assessment of these images.¹⁰ With the use of IVCM, one can assess the type and density of inflammatory cell infiltrates and the morphology and distribution of fibrotic tissue within the tarsal conjunctiva. In vivo confocal microscopy is noninvasive, has no adverse effects, and can be repeated in the same individual.

To better understand the disease process in scarring trachoma, we conducted a case-control study comparing the IVCM findings in individuals with trachomatous scarring

(TS) and normal controls. It is anticipated that this technology can be used to support the detailed assessment of progressive scarring in the study of both current and future interventions in trachoma control.

Patients and Methods

Ethical Permission and Subject Recruitment

This study was approved by ethics committees in Tanzania and the United Kingdom; written, informed consent was obtained from each subject. The first study, on TS, was conducted in the Siha District of the Kilimanjaro Region of Northern Tanzania, in what was historically a single village. Two years before the study, this village was subdivided into 3 administrative units that form a single continuous geographic entity. Previous surveys of children in this village found a moderate level of active trachoma (18% follicular trachoma in children aged 1–9 years). After an initial census, adults with conjunctival scarring (grade S1b or worse, see below) were recruited as cases. An equal number of control subjects without scarring, frequency matched by ethnicity, were recruited. Individuals with trichiasis or previous eyelid surgery were excluded from this study.

Most of the cases in the TS study had relatively mild conjunctival scarring. Therefore, to characterize the full range of the scarring phenotype, a second case-control study was conducted in which all the cases were individuals with trachomatous trichiasis (TT), who generally had more severe conjunctival scarring. The cases in the TT study were recruited from patients undergoing trichiasis surgery in the Kilimanjaro Region. Control subjects were recruited from patients undergoing cataract or retinal detachment surgery at Kilimanjaro Christian Medical Centre.

Clinical Assessment

All subjects were examined by an ophthalmologist (VH) using $\times 2.5$ loupes and a bright torch. Examinations were carried out in a darkened tent or room. The 1981 World Health Organization (FPC) trachoma grading system was used to grade conjunctival follicles and papillae, entropion, trichiasis, and corneal opacity.¹¹ We developed a more detailed grading system for conjunctival scarring (Table 1 and Fig 1, available at <http://aaojournal.org>). A slit lamp was used to rule out subtle conjunctival scarring in normal controls.

Confocal Microscopy Assessment

The IVCN examination of the upper tarsal conjunctiva was performed using the Heidelberg Retina Tomograph 3 in combination with the Rostock Corneal Module (Heidelberg Engineering GmbH, Dossenheim, Germany) using a previously described protocol.¹⁰ For the TS study, all IVCN assessments were done on the left eye, whereas for the TT study a mixture of right and left eyes were examined. Ten “volume” scans were taken from random locations across the tarsal conjunctiva, each of which consisted of 40 coronal scans taken in rapid succession at 2.1- μm intervals, starting at the conjunctival surface, moving from superficial to deep.

The IVCN images were graded for inflammatory features (Fig F2) and the degree of subepithelial connective tissue organization (Fig F3).¹⁰ All IVCN grading was performed by a single observer (VH) who was masked to the clinical status of the patient, with the exception of the cell counts for the inflammatory infiltrate in the

TS study, which was done by a single trained observer. For every subject, each volume scan was assessed and scored: 0 (normal), 1 (grade 1), 2 (grade 2), or 3 (grade 3) for the connective tissue organization grading. The overall connective tissue organization score for that subject was calculated by dividing the sum of these separate volume scan scores by the number of volume scans graded. Individuals with fewer than 3 gradable volume scans were excluded from the analysis. We have previously reported good interobserver agreement (intraclass coefficient of 0.88).¹⁰

Sample Size and Data Analysis

These studies are part of a series of related studies on the pathogenesis of TS with the sample size calculated to encompass these other components. For example, the sample of 363 cases and 363 controls has >85% power to detect an association of a factor with an odds ratio (OR) of 2 when the factor is present in 10% of control subjects.

Data were entered into Access 2007 (Microsoft Corp, Redmond, WA) and analyzed using STATA 11.0 (StataCorp LP, College Station, TX). Logistic regression models were developed for clinical scarring to estimate ORs and 95% confidence intervals (CIs) for association with demographic and categorical IVCN characteristics. In view of the differences in ages between cases and controls in the TS study and the known association of TS with age, all ORs were age-adjusted. Linear regression (age-adjusted for the TS study) was used to estimate the strength of associations between clinical scarring and continuous IVCN variables (inflammatory infiltrate and connective tissue organization score). The TS study had a larger number of participants, so a more detailed analysis is also presented for this study. Multivariable logistic regression models (for categorical outcomes) and multivariable linear regression models (for continuous outcomes) were fitted to assess whether IVCN characteristics were independently associated with the presence of scarring, the level of scarring, and the level of clinical inflammation after adjusting for potential confounding factors. Likelihood ratio tests were used to assess the strength of association of factors with scarring. Tests for nonlinearity were conducted to assess whether fitting factors on a linear scale provided an adequate fit to the data. Tests for trend were used to examine the association of IVCN parameters with the ordered categories of clinical scarring and inflammation severity using the Wald test.

Results

Study Participants

The TS study village had an adult population of 3626, of whom 2418 (67%) were seen. Of the 1208 individuals not seen, the majority (58.9%) were absent during the census, despite 2 visits; 9.6% were temporarily resident elsewhere; and 4.1% refused examination. Of the 2418 participants seen, we excluded 36 (1.5%) because of the presence of trichiasis, previous eyelid surgery, or inability to give informed consent. Of the remaining 2382 participants, 862 (36.2%) had clinically apparent TS and 1520 (63.8%) did not have visible scarring. We recruited 363 TS cases and 363 controls. Demographic and clinical characteristics are shown in Table 2. Cases were significantly older than controls ($P < 0.001$), so subsequent analyses were adjusted for age. The majority of cases and controls were of Maasai ethnicity (77% of both groups) followed by Chagga ethnicity (11% of both groups).

We recruited 34 TT cases and 33 controls for the TT study (Table 3). There was no significant difference between the ages of

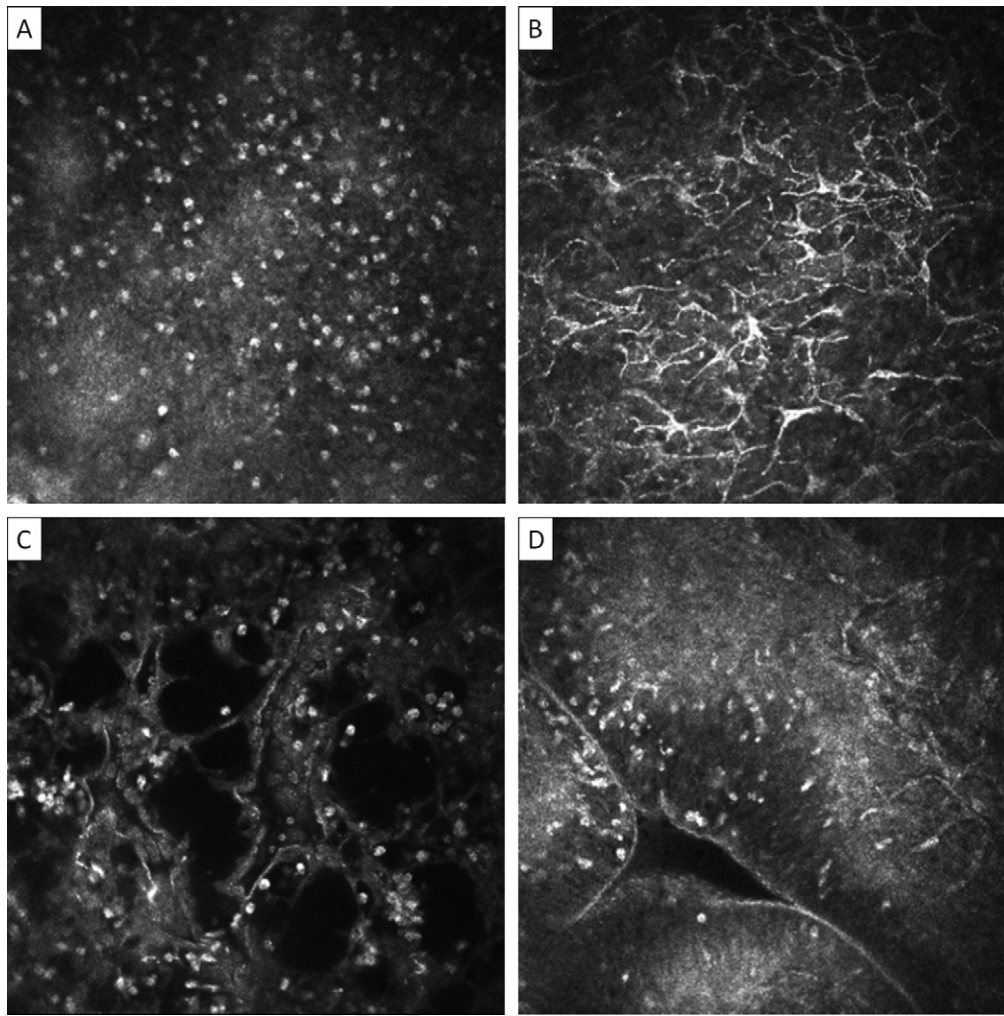


Figure 2. In vivo confocal microscopy grading system of inflammatory features. Images are $400 \times 400 \mu\text{m}$. **A**, Inflammatory infiltrate: seen as multiple bright white nuclei. The mean inflammatory cell density of 3 randomly selected volume scans is calculated. The individual scan with the highest density of cells from within the volume scan is used. **B**, Dendritiform cells: graded as present or absent. To be present, the mean number of DCs per volume scan needs to be ≥ 1 . The largest number of DCs in any individual scan in a volume scan is used for measurement. A mean number of ≥ 1 is used to differentiate occasional DCs seen in scans of otherwise normal subjects. **C**, Tissue edema: seen as multiple black empty spaces. Graded as present or absent in any volume scan. **D**, Papillae: seen as elevations with a central vascular network. Graded as present or absent in any volume scan.

TT cases and controls. The majority of the cases (85%) were Maasai, whereas the controls were more evenly divided between different ethnic groups (the largest groups were Chagga, 42%, and Pare, 24%).

Analysis Based on Case-Control Status

The clinical scarring was mostly mild to moderate in the TS study and severe in the TT study (Tables 2 and 3). Most of the cases were clinically inflamed; in contrast, most controls were not. In the TT study most cases had severe clinical scarring (70% with S3), in contrast with the TS study (3.6% with S3).

In all participants, most of the cellularity detected by IVCM was found within the most superficial 20–30 μm of the conjunctiva, with cells not usually seen below this level. There were more inflammatory cells in cases than controls, significantly so in the larger TS study (Table 4). Cases were also more

likely than controls to have dendritiform cells (DCs) and tissue edema present, but there was no association with the presence of papillae (Table 4).

The mean IVCM connective tissue organization score was higher in cases than in controls in both studies, but particularly in the TT study in which the cases had more severe clinical scarring (TT cases 2.29 vs. controls 0.59; $P < 0.001$; Table 4). The tissue organization score was similar in the control groups of both studies (TT study controls 0.59 vs. TS study controls 0.77). The IVCM connective tissue organization score was categorized into 3 groups (0–1, >1–2, and >2–3). In both studies, the majority of controls had a score of ≤ 1 (79% in the TS study and 92% in the TT study), compared with the cases (26% in the TS study and 8% in the TT study). Most of the cases in the TS study (63/81; 78%) with an IVCM score in the lowest 0–1 category had the mildest degree of clinical scarring, S1b. There were no controls in either study with the

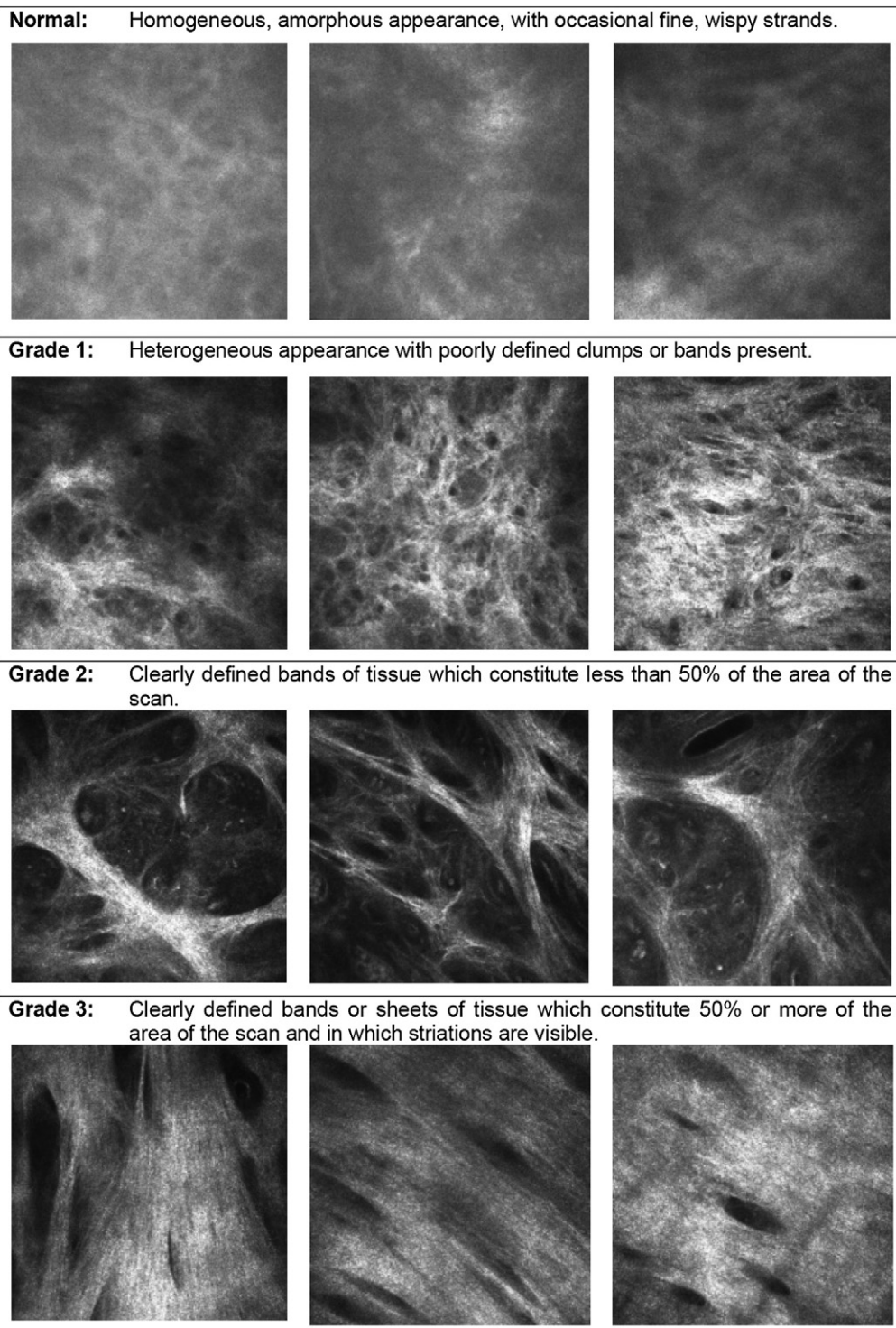


Figure 3. In vivo confocal microscopy grading system for conjunctival connective tissue organization. Images are $400 \times 400 \mu\text{m}$. If different grades of scarring are seen within a particular volume scan, then the highest grade is recorded. The connective tissue that is graded needs to be separate from that associated with the vascular tissue; if this is not possible, then the scan is considered ungradable.

highest IVCM connective tissue organization category (2–3), which is characterized by clearly defined bands or sheets of tissue.

A multivariable logistic regression model of the TS study showed that after controlling for age and clinical inflammation,

clinical scarring remained associated with the presence of DCs (OR 4.27, 95% CI, 1.39–13.09, $P=0.008$, Table 5, available at <http://aaojournal.org>). The corresponding adjusted association is even stronger for the TT study (OR 25.36, 95% CI, 1.69–380.00, $P = 0.02$). Tissue edema was not significantly associ-

Table 2. Demographic and Clinical Characteristics of the Trachomatous Scarring Study Participants and Age-Adjusted Associations with Conjunctival Scarring

Parameter	Cases N = 363		Controls N = 363		Age-Adjusted Association with Scarring		
	n	(%)	n	(%)	OR	95% CI	P Value
<i>Demographic Characteristics</i>							
Sex							
Female	222	(61.2)	242	(66.7)	1.00	–	
Male	141	(38.8)	121	(33.3)	1.19	0.83–1.71	0.34
Age (year groups)							
18–25	29	(8.0)	117	(32.2)	2.20*	1.94–2.50	<0.001
25–35	53	(14.6)	114	(31.4)			
35–45	65	(17.9)	87	(24.0)			
45–55	81	(22.3)	28	(7.7)			
55–65	58	(16.0)	9	(2.5)			
> 65	77	(21.2)	8	(2.2)			
Age (yrs) [median, IQR]	49.7	36.7–62.7	29.2	22.2–39.2			
Formal education [†]							
None	250	(69.4)	166	(46.1)	1.00	–	0.001
1–7 yrs	106	(29.4)	177	(49.2)	0.57	0.40–0.81	
> 7 yrs	4	(1.1)	17	(4.7)	0.25	0.07–0.88	
BMI [‡]							
Underweight	55	(15.3)	30	(8.4)	1.39	0.79–2.44	0.48
Normal	259	(72.0)	287	(80.2)	1.00	–	
Overweight/obese	46	(12.8)	41	(11.5)	1.14	0.68–1.92	
<i>Clinical Characteristics</i>							
Scarring grade [§]							
S0	–	–	363	(100)			
S1a	0	0	–	–			
S1b	188	(51.8)	–	–			
S1c	128	(35.3)	–	–			
S2	34	(9.4)	–	–			
S3	13	(3.6)	–	–			
Papillary inflammation grade							
P0	81	(22.3)	346	(95.3)			
P1	189	(52.1)	17	(4.7)			
P2	85	(23.4)	0	(0.0)			
P3	8	(2.2)	0	(0.0)			
Follicles grade							
F0	358	(98.6)	358	(99.7)			
F1	2	(0.6)	1	(0.3)			
F2	1	(0.3)	0	(0.0)			
F3	2	(0.6)	0	(0.0)			

BMI = body mass index; CI = confidence interval; IQR = interquartile range; OR = odds ratio.

*The result shown is the increase in the OR with each increase in age group category.

[†]Primary schooling in Tanzania is completed after 7 years.

[‡]Categories from the National Institutes of Health.

[§]All of the controls had no scarring (grade 0), and all of the cases had scarring grade \geq S1b.

ated with scarring after adjusting for age and clinical inflammation.

Analysis Based on Clinical Scarring Grade (TS Study Only)

The IVCM inflammatory infiltrate, connective tissue organization score, presence of DCs, and presence of tissue edema all increased with the clinical scarring grade (Table 6, available at <http://aao-journal.org>). Regression models were used to analyze the association of each of these factors adjusting for age, sex, and the clinical inflammation grade. For modeling purposes, clinical scarring

grades S2 and S3 were combined, because there were few individuals in clinical scarring grade S3 in the TS study. For each unit increase in the clinical scarring grade, there was an independent increase of 87 cells/mm² in the inflammatory infiltrate (95% CI, 45–130; $P < 0.001$) and of 0.36 in the organization score (95% CI, 0.29–0.43; $P < 0.001$). Similarly, the OR for the presence of DCs increased by 1.68 (95% CI, 1.14–2.47, $P = 0.008$) for each increase in clinical scarring grade. The presence of tissue edema was not significantly associated with increasing clinical scarring grade (OR = 0.83, 95% CI, 0.43–1.61).

For reference, the mean connective tissue organization score for clinical scarring grade S3 in the TT study was 2.65 (95% CI,

Table 3. Demographic and Clinical Characteristics of the Trachomatous Trichiasis Study Participants and Associations with Conjunctival Scarring

Parameter	Cases N = 34		Controls N = 33		Association with Scarring		
	n	(%)	n	(%)	OR	95% CI	P Value
<i>Demographic Characteristics</i>							
Sex							
Female	23	(67.7)	15	(45.5)	1.00	–	
Male	11	(32.3)	18	(54.5)	2.61	0.93–7.34	0.06
Age (year groups)							
18–25	0	(0.0)	0	(0.0)	1.62*	0.90–2.95	0.11
25–35	0	(0.0)	0	(0.0)			
35–45	1	(6.9)	2	(6.1)			
45–55	1	(20.7)	7	(21.2)			
55–65	10	(20.7)	6	(18.2)			
> 65	22	(51.7)	18	(54.6)			
Age (yrs) [median, IQR]	68.5	61.0–80.0	70.0	53.1–78.1			
Formal education [†]							
None	28	(87.5)	4	(13.3)	1.00	–	<0.001
1–7 yrs	4	(12.5)	18	(60.0)	0.02	0.00–0.12	–
>7 yrs	0	(0.0)	8	(26.7)	0.02	0.00–0.18	
BMI							
	Data not collected						
<i>Clinical Characteristics</i>							
Scarring grade [‡]							
S0	–	–	33	(100)			
S1a	0	0	–	–			
S1b	0	0	–	–			
S1c	6	(17.7)	–	–			
S2	4	(11.8)	–	–			
S3	24	(70.6)	–	–			
Papillary inflammation grade							
P0	4	(11.8)	31	(93.9)			
P1	5	(14.7)	1	(3.0)			
P2	17	(50.0)	1	(3.0)			
P3	8	(23.5)	0	(0.0)			
Follicles grade							
F0	34	(100.0)	33	(100.0)			
F1	0	(0.0)	0	(0.0)			
F2	0	(0.0)	0	(0.0)			
F3	0	(0.0)	0	(0.0)			

BMI = body mass index; CI = confidence interval; IQR = interquartile range; OR = odds ratio.

*The result shown is the increase in the OR with each increase in age group category.

[†]Primary schooling in Tanzania is completed after 7 years.

[‡]All of the controls had no scarring (grade 0), and all of the cases had scarring grade \geq S1c.

2.36–2.94). Of these severely scarred cases, 13 of 16 (81%) were in the highest IVCN organization grade 2–3, and 3 of 16 (19%) were in the intermediate grade >1–2.

Analysis Based on Clinical Inflammation Grade (TS Study Only)

The IVCN inflammatory infiltrate, connective tissue organization score, presence of DCs, and presence of tissue edema all tended to increase with the clinical inflammation grade (Table 7, available at <http://aaojournal.org>). Regression models were used to analyze the association of each of these factors, adjusting for age, sex, and clinical scarring grade, in a similar manner to that above. For each unit increase in the clinical inflammation grade, there was a small increase in the inflammatory infiltrate, but this was of only borderline statistical significance ($P = 0.06$). After adjusting for the other factors, the organization score no longer remained significantly associated with the level of clinical inflammation. The presence of DCs did remain associated with the level of clinical

inflammation ($P=0.03$), especially for the highest grade of inflammation (OR 12.1, 95% CI, 2.1–69.2). With each increase in clinical inflammation grade, there was an increase of 5.12 in the OR for the presence of tissue edema (95% CI, 2.69–9.76, $P<0.001$).

Discussion

In this study, IVCN was used to examine tissue changes in a large number of people with trachomatous conjunctival scarring and compared with controls. Previously developed grading systems were used to formally evaluate tissue morphology and cellular appearances.

Previous studies have shown that the cellular infiltrate is probably composed of inflammatory cells, such as neutrophils or lymphocytes, and is increased in patients with atopic keratoconjunctivitis.^{8,12–15} In vivo confocal micros-

Table 4. In Vivo Confocal Microscopy Findings from the Trachomatous Scarring and Trachomatous Trichiasis Studies and Associations with Conjunctival Scarring

Parameter	Cases		Controls		Association with Scarring [†]		
	n	(%)	n	(%)	OR	95% CI	P Value
	N = 328*		N = 319*				
<i>TS Study</i>							
Mean inflammatory infiltrate (cells/mm ²) [mean, 95% CI]	875	832–919	674	640–707	154 [‡]	90–217	<0.001
DCs present	50	(15.2)	7	(2.2)	4.10	1.71–9.85	0.002
Tissue edema present	22	(6.7)	9	(2.8)	3.77	1.53–9.26	0.004
Papillae present	110	(33.5)	129	(40.4)	1.14	0.78–1.66	0.49
	N = 314		N = 302				
<i>Connective tissue organization grade</i>							
0–1	81	(25.8)	238	(78.8)	1.00	–	<0.001
1–2	178	(56.7)	64	(21.2)	6.2	4.1–9.4	
2–3	55	(17.5)	0	(0.0)	107.4 [§]	14.2–813.7	
Mean connective tissue organization score (mean, 95% CI)	1.48	1.41–1.56	0.77	0.71–0.82	0.59 [‡]	0.48–0.69	<0.001
<i>TT Study</i>							
	N = 28		N = 26				
Mean inflammatory infiltrate (cells/mm ²) [mean, 95% CI]	1572	1174–1972	1252	1037–1467			0.11
DCs present	16	(61.5)	1	(3.6)	43.20	5.05–369.6	0.001
Tissue edema present	10	(38.5)	0	(0.0)	16.9 [‡]	1.97–144.4	0.01
Papillae present	0	(0.0)	3	(10.7)	0.33 [‡]	0.03–3.43	0.36
	N = 26		N = 25				
<i>Connective tissue organization grade</i>							
0–1	2	(8.0)	24	(92.3)	1.00	–	<0.001
1–2	6	(24.0)	2	(7.7)	72.0	5.6–933.0	
2–3	17	(68.0)	0	(0.0)	204.0 [§]	17.1–2434.9	
Mean connective tissue organization score (mean, 95% CI)	2.29	1.94–2.64	0.59	0.41–0.77			<0.001

CI = confidence interval; OR = odds ratio; TS = trachomatous scarring; TT = trachomatous trichiasis.

*There are different numbers because not all subjects had images that could be graded.

[†]Age-adjusted for the TS study.

[‡]Age-adjusted difference between cases and controls.

[§]If a cell contained 0, then a participant was moved up a category to be able to generate a representative OR.

copy assessment of the inflammatory cell density also has shown good correlation with assessment by brush cytology.¹⁵ Some attempt can be made to differentiate these cells on the basis of nuclear detail, for example, segmentation suggesting polymorphs, but definitive identification would require biopsy. We found that the inflammatory cell density increased with increasing clinical scores for both conjunctival inflammation and scarring. The association with scarring was greater than with inflammation and remained strongly significant even after adjusting for the level of clinical inflammation. This suggests that the increased cellularity may be more closely related to the scarring process than clinically visible “inflammation,” which is characterized by erythema and edema.

Dendritiform cells were found to be independently associated with TS. These cells have invariably been labeled as dendritic cells in previous studies of the ocular surface using IVCM, although there has not been definitive histologic confirmation of this finding.^{7,16} Dendritic cells play a central role in determining the type of immune response that develops to response to infection, which is of particular relevance in trachoma because the tissue damage is immune

mediated.^{17–21} The view that dendritic cells are likely to play an important role in the design of any chlamydial vaccine gains some support from our study.²²

Of note, most of the cells seen in these adults with TS were within the superficial 30 μ m of the surface. This distribution suggests close interaction between these cells and the epithelium and lends support to the cellular paradigm of chlamydia pathogenesis. The cellular paradigm suggests that non-immune host cells, particularly epithelial cells, release proinflammatory cytokines and chemokines in response to chlamydial and other bacterial infection, which induces an inflammatory response leading to tissue damage.^{3,23,24} This is in contrast with the immunologic paradigm, which argues that the damage is primarily driven by an acquired cell-mediated immune response that is important for defense against infection but also leads to collateral tissue damage.²²

Some attempt has been made at grading the density of conjunctival subepithelial connective tissue in relation to blebs after trabeculectomy surgery.²⁵ However, no clear definitions were provided for this grading system, nor was there any evaluation of interobserver variation. In this arti-

423 cle, we have applied the use of a grading system that has
424 clear definitions and good interobserver agreement with the
425 graders masked to the clinical findings.¹⁰ This study showed
426 that scarring of the conjunctiva has a characteristic appear-
427 ance on IVCM with well-defined bands or sheets of scarring
428 seen. These probably represent collagen fibers. The IVCM
429 organization score tended to show an increase with the
430 clinical scarring grade. Most of the cases in the TT study
431 had severe scarring, and most were also scored as being in
432 the highest IVCM connective tissue organization grade,
433 showing good agreement between clinical and IVCM as-
434 sessment. Not all cases had an IVCM appearance suggestive
435 of scarring, with some having a homogenous appearance
436 similar to control subjects. However, most of these had very
437 mild clinical scarring.

438 Some control subjects also had a more organized appear-
439 ance of the connective tissue. This may represent limitations
440 in the grading system or the quality of the images gained by
441 the microscope. However, we have also performed tarsal
442 conjunctival IVCM with a similar protocol on 30 healthy
443 volunteer subjects from a variety of non-trachoma endemic
444 areas (mean age 36.7 years, range 22–85 years). These
445 scans were graded in a masked manner (mixed with scans
446 from cases with scarring so that the grader, VH, did not
447 know the clinical status), and the mean IVCM connective
448 tissue organization score was 0.40 (95% CI, 0.27–0.54)
449 with all individuals graded as being in the lowest IVCM
450 organization grade. Although this may reflect differences
451 based on ethnicity, an alternative explanation is that the
452 confocal microscope is able to detect subclinical scarring.
453 Many of the control subjects in both case-control studies
454 presented were probably exposed to chlamydial infection as
455 children. There is likely to be a spectrum of scarring sever-
456 ity seen in the population, some of which may not be visible
457 clinically but can be detected with the confocal microscope.
458 This may be represented by the 20% of clinically normal
459 subjects in the TS study with an intermediate grade of
460 IVCM organization. This is supported by the observation
461 that in people from non-trachoma endemic areas, the mean
462 IVCM organization score was lower than that of the con-
463 trols in both case-control studies, and that the entire group
464 had only the lowest grade of IVCM organization.

465 Study Limitations

466 There are a number of limitations to these studies. In the TS
467 study, cases tended to be older than controls. However, we
468 adjusted for this in the analysis. The age distribution was
469 similar between cases and controls in the TT study. Also,
470 not all potential study participants were able to tolerate
471 confocal microscopy. However, we think it is unlikely that
472 any systematic bias was introduced that would have affected
473 the results. We are currently comparing IVCM findings with
474 paired histology specimens to further validate the interpre-
475 tation of these observations. These studies were conducted
476 in a district previously found to be endemic for trachoma,
477 and results may differ in other areas/countries, for example,
478 where levels of infection are hyperendemic. Although the
479 cases and controls in the TS study were recruited from the

423 same community, the controls in the TT study were from a
424 mixture of urban and rural areas.

425 In conclusion, these studies have used IVCM to ex-
426 plore the cellular and tissue changes occurring in tracho-
427 matous conjunctival scarring and inflammation. A robust
428 grading system has been used, and new insights have
429 been gained into the pathologic mechanisms at work. We
430 hope the grading system may be of relevance in the study
431 of other immunofibrogenic diseases of the conjunctiva,
432 such as mucous membrane pemphigoid and atopic
433 keratoconjunctivitis.

434 References

- 435 1. Resnikoff S, Pascolini D, Etya'ale D, et al. Global data on
436 visual impairment in the year 2002. *Bull World Health Organ*
437 2004;82:844–51.
- 438 2. Mariotti SP, Pascolini D, Rose-Nussbaumer J. Trachoma:
439 global magnitude of a preventable cause of blindness. *Br J*
440 *Ophthalmol* 2009;93:563–8.
- 441 3. Stephens RS. The cellular paradigm of chlamydial pathogen-
442 esis. *Trends Microbiol* 2003;11:44–51.
- 443 4. Guthoff RF, Zhivov A, Stachs O. In vivo confocal micros-
444 copy, an inner vision of the cornea—a major review. *Clin*
445 *Experiment Ophthalmol* 2009;37:100–17.
- 446 5. Guthoff RF, Baudouin J, Stave J. *Atlas of Confocal Laser*
447 *Scanning In-vivo Microscopy in Ophthalmology*. Berlin:
448 Springer; 2006.
- 449 6. Chiou AG, Kaufman SC, Kaufman HE, Beuerman RW. Clin-
450 ical corneal confocal microscopy. *Surv Ophthalmol* 2006;51:
451 482–500.
- 452 7. Mastropasqua L, Nubile M, Lanzini M, et al. Epithelial den-
453 dritic cell distribution in normal and inflamed human cornea:
454 in vivo confocal microscopy study. *Am J Ophthalmol* 2006;
455 142:736–44.
- 456 8. Hu Y, Adan ES, Matsumoto Y, et al. Conjunctival in vivo
457 confocal scanning laser microscopy in patients with atopic
458 keratoconjunctivitis. *Mol Vis* [serial online] 2007;13:1379–
459 89. Available at: <http://www.molvis.org/molvis/v13/a152/>.
460 Accessed April 6, 2011.
- 461 9. Jalbert I, Stapleton F, Papas E, et al. In vivo confocal micros-
462 copy of the human cornea. *Br J Ophthalmol* 2003;87:225–36.
- 463 10. Hu VH, Massae P, Weiss HA, et al. In vivo confocal micros-
464 copy of trachoma in relation to normal tarsal conjunctiva.
465 *Ophthalmology* 2011;118:747–54.
- 466 11. Dawson CR, Jones BR, Tarizzo ML. *Guide To Trachoma*
467 *Control*. Geneva: World Health Organization; 1981:xx–xx
468
- 469 12. Zhivov A, Stachs O, Kraak R, et al. In vivo confocal micros-
470 copy of the ocular surface. *Ocul Surf* 2006;4:81–93.
- 471 13. Kobayashi A, Yoshita T, Sugiyama K. In vivo findings of the
472 bulbar/palpebral conjunctiva and presumed meibomian glands
473 by laser scanning confocal microscopy. *Cornea* 2005;24:
474 985–8.
- 475 14. Liang H, Baudouin C, Labbe A, et al. In vivo confocal
476 microscopy and ex vivo flow cytometry: new tools for assess-
477 ing ocular inflammation applied to rabbit lipopolysaccharide-
478 induced conjunctivitis. *Mol Vis* [serial online] 2006;12:1392–
479 402. Available at: <http://www.molvis.org/molvis/v12/a157/>.
480 Accessed April 6, 2011.
- 481 15. Wakamatsu TH, Okada N, Kojima T, et al. Evaluation of
482 conjunctival inflammatory status by confocal scanning laser
483 microscopy and conjunctival brush cytology in patients
484 with atopic keratoconjunctivitis (AKC). *Mol Vis* [serial

online] 2009;15:1611–9. Available at: <http://www.molvis.org/molvis/v15/a172/>. Accessed April 6, 2011.

16. Zhivov A, Stave J, Vollmar B, Guthoff R. In vivo confocal microscopic evaluation of Langerhans cell density and distribution in the corneal epithelium of healthy volunteers and contact lens wearers. *Cornea* 2007;26:47–54.
17. Sato K, Fujita S. Dendritic cells: nature and classification. *Allergol Int* 2007;56:183–91.
18. Banchereau J, Briere F, Caux C, et al. Immunobiology of dendritic cells. *Annu Rev Immunol* 2000;18:767–811.
19. Debattista J, Timms P, Allan J. Immunopathogenesis of *Chlamydia trachomatis* infections in women. *Fertil Steril* 2003;79:1273–87.
20. Holland MJ, Bailey RL, Hayes LJ, et al. Conjunctival scarring in trachoma is associated with depressed cell-mediated immune responses to chlamydial antigens. *J Infect Dis* 1993;168:1528–31.

21. Holland MJ, Bailey RL, Conway DJ, et al. T helper type-1 (Th1)/Th2 profiles of peripheral blood mononuclear cells (PBMC): responses to antigens of *Chlamydia trachomatis* in subjects with severe trachomatous scarring. *Clin Exp Immunol* 1996;105:429–35.
22. Brunham RC, Rey-Ladino J. Immunology of *Chlamydia* infection: implications for a *Chlamydia trachomatis* vaccine. *Nat Rev Immunol* 2005;5:149–61.
23. Darville T, Hiltke TJ. Pathogenesis of genital tract disease due to *Chlamydia trachomatis*. *J Infect Dis* 2010;201(Suppl):S114–25.
24. Burton MJ, Bailey R, Jeffries D, et al. Conjunctival expression of matrix metalloproteinase and proinflammatory cytokine genes following trichiasis surgery. *Invest Ophthalmol Vis Sci* 2010;51:3583–90.
25. Labbe A, Dupas B, Hamard P, Baudouin C. In vivo confocal microscopy study of blebs after filtering surgery. *Ophthalmology* 2005;112:1979–86.

Footnotes and Financial Disclosures

Originally received: November 23, 2010.

Final revision: March 2, 2011.

Accepted: April 11, 2011.

Available online: ●●●.

Manuscript no. 2010-1620.

¹ International Centre for Eye Health, Faculty of Infectious and Tropical Diseases, London School of Hygiene and Tropical Medicine, London, United Kingdom.

² Kilimanjaro Centre for Community Ophthalmology, Moshi, Tanzania.

³ MRC Tropical Epidemiology Group, London School of Hygiene and Tropical Medicine, London, United Kingdom.

⁴ Clinical Research Department, Faculty of Infectious and Tropical Diseases, London School of Hygiene and Tropical Medicine, London, United Kingdom.

Financial Disclosure(s):

The author(s) have no proprietary or commercial interest in any materials discussed in this article.

This study was funded by a fellowship grant to MJB from the Wellcome Trust (080741/Z/06/Z). VHH is supported by a fellowship grant from the British Council for the Prevention of Blindness (Barrie Jones Fellowship). The funders had no part in the study design; in the collection, analysis, and interpretation of data; in the writing of the report; or in the decision to submit the manuscript for publication.

Correspondence:

Victor H. Hu, MBBCh, MRCOphth, International Centre for Eye Health, London School of Hygiene and Tropical Medicine, Keppel Street, London, WC1E 7HT, UK. E-mail: victor.hu@lshtm.ac.uk.

Table 1: Clinical Scarring Grading System for the tarsal conjunctiva.

Grade	Definition*
S1	Scarring occupying $< \frac{1}{3}$ of the upper lid
S1a	One or more pinpoint scars and/or a single line of scarring less than 2mm in length [†]
S1b	Multiples lines of scarring less than 2mm in length
S1c	One or more lines/patches of scarring each 2mm or more in length/maximal dimension
S2	Patches of scarring occupying in surface area $\geq \frac{1}{3}$ but $< \frac{2}{3}$ of the upper lid
S3	Patches of scarring occupying in surface area $\geq \frac{2}{3}$ of the upper lid

* "upper lid" refers to zones 2 and 3 of the everted lid.²⁹

[†] 2mm was chosen as this is the approximate width of the lower lid margin, which is readily available for comparison.

Table 5: Multivariable logistic regression model for the presence of conjunctival scarring (Trachomatous Scarring Study subjects only)

Risk factor	Odds Ratio	95% CI	p-value
Age group*	2.26	1.86-2.75	<0.001
Presence of any clinical inflammation	72.45	38-138	<0.001
Dendritiform cells present	4.27	1.39-13.04	0.008

* The result shows the increase in the OR with each increasing age group (10 year) category.

CI = Confidence intervals

Table 6: *In vivo* confocal microscopy parameters by Clinical Scarring Grade (Trachomatous Scarring study subjects only).

Parameter	Clinical Scarring Grade				Test for trend*	
	S0	S1b	S1c	S2		
Mean inflammatory infiltrate (cells/mm ²)	674 (640-707)	783 (730-835)	964 (898-1031)	1028 (902-1155)	1045 (844-1245)	<0.001
[mean (95%CI)]						
Mean connective tissue organization score	0.77 (0.72-0.82)	1.30 (1.21-1.39)	1.60 (1.47-1.73)	2.06 (1.83-2.29)	1.54 (1.21-1.88)	<0.001
[mean (95%CI)]						
Dendritiform cells present [n (%)]	7 (2.19)	18 (10.34)	20 (18.35)	6 (18.75)	6 (46.15)	0.008
Tissue edema present [n (%)]	9 (2.82)	6 (3.45)	12 (11.01)	2 (6.25)	2 (15.38)	0.58

* Adjusted for age, sex and Clinical Inflammation Grade

CI = Confidence interval

Table 7: *In vivo* confocal microscopy parameters by Clinical Inflammation Grade (Trachomatous Scarring Study subjects only).

Parameter	Clinical Inflammation Grade			Test for trend*	
	P0	P1	P2		
IVCM inflammatory infiltrate score (cells/mm ²) [mean (95%CI)]	693 (657-730)	850 (799-902)	983 (902-1063)	974 (724-1224)	0.06
IVCM connective tissue organization score [mean (95%CI)]	0.91 (0.85-0.97)	1.42 (1.33-1.52)	1.51 (1.36-1.66)	1.48 (0.97-1.98)	0.23
Dendritiform cells present [n (%)]	18 (4.8)	20 (10.9)	14 (17.8)	5 (62.5)	0.03
Tissue edema present [n (%)]	9 (2.4)	4 (2.2)	13 (16.7)	5 (62.5)	<0.001

* Adjusted for age, sex and Clinical Scarring Grade

CI = Confidence interval

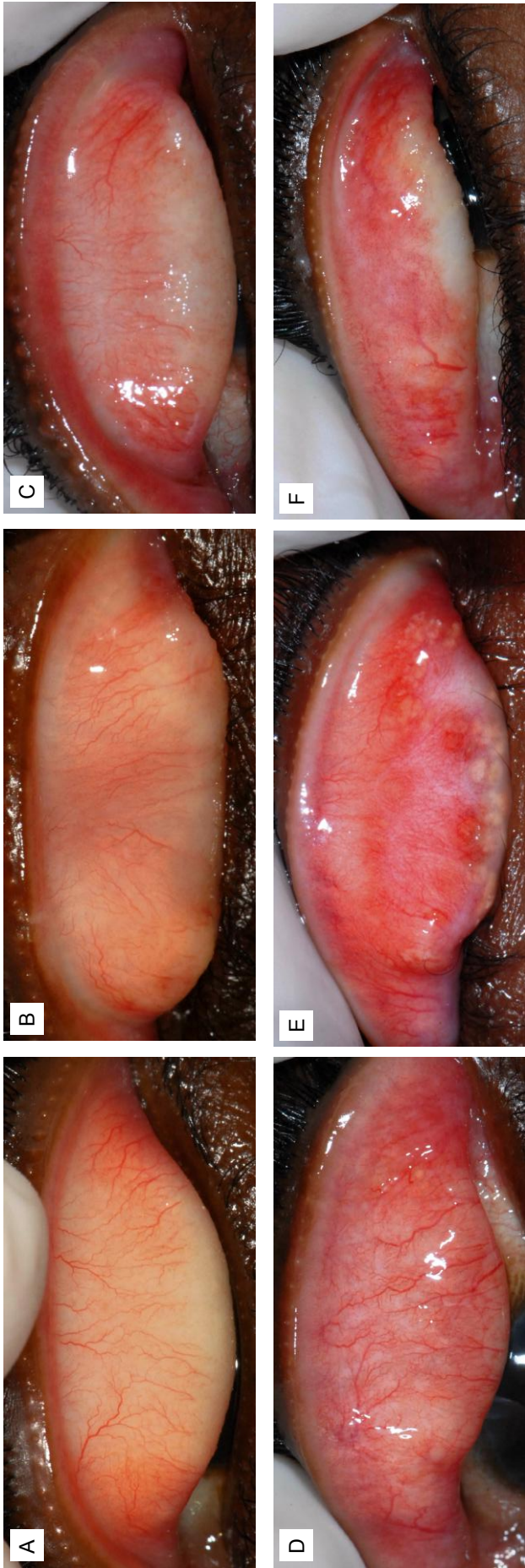
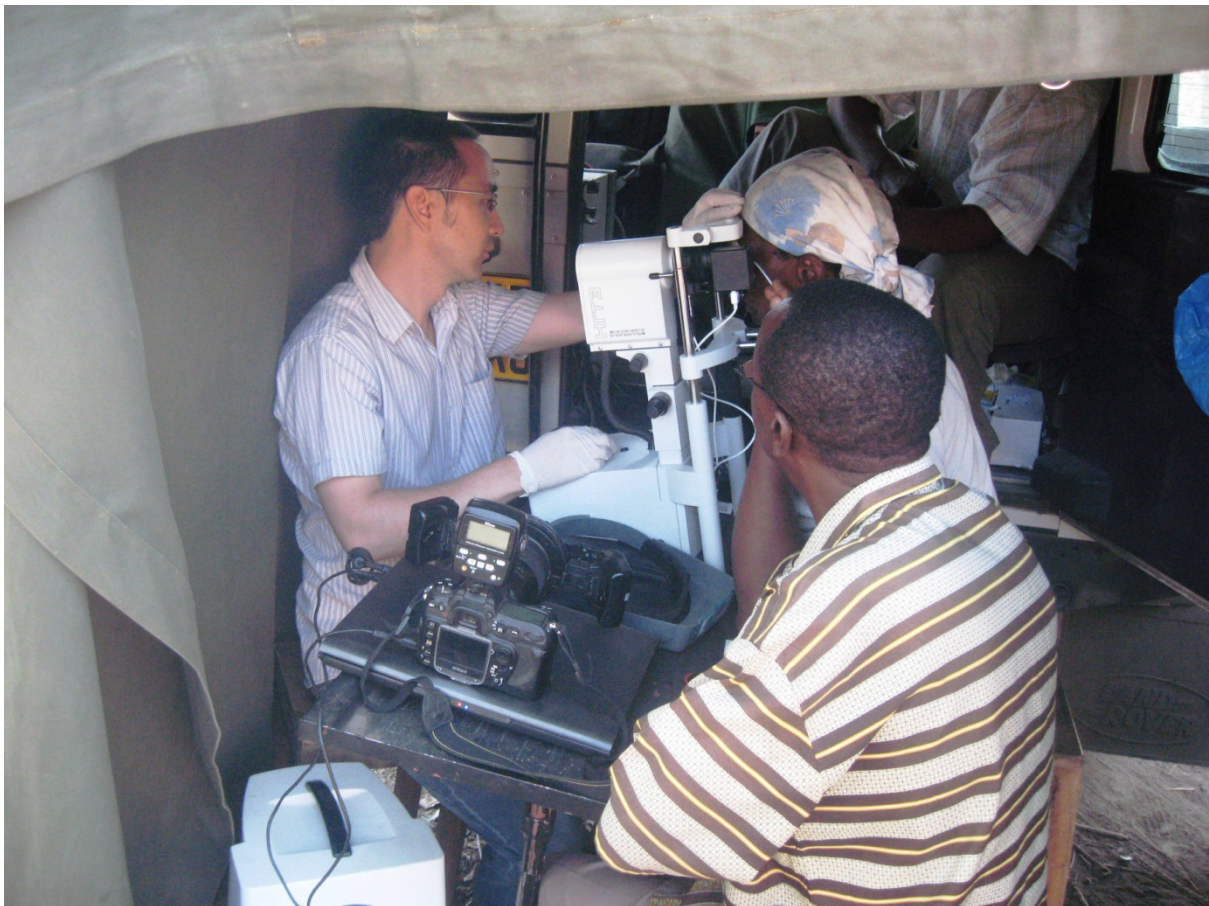

Figure 1. Clinical grading system for trachomatous conjunctival scarring. **A**, Normal. **B**, Grade S1a. **C**, Grade S1c. **D**, Grade S2. **E**, Grade S2. **F**, Grade S3.

Chapter 10

***In vivo* confocal microscopy and histopathology of the conjunctiva in healthy and trachomatous conjunctiva: a systematic comparison**



Research paper comparing *in vivo* confocal microscopy and immunohistological analyses of tarsal conjunctiva in trachomatous scarring and control subjects

Cover sheet for each ‘research/review paper’ included in a research thesis

1. For a ‘research/review paper’ prepared for publication but not yet published

1.1. Where is the work intended to be published? **Ophthalmology**

1.2. List the paper’s authors in the intended authorship order

**Victor H. Hu, Martin J. Holland, Ian A. Cree, James Pullin, Helen A. Weiss,
Patrick Massae, William Makupa, David C. W. Mabey, Robin L. Bailey, Matthew
J. Burton Phil Luthert,**

1.3. Stage of publication **Not yet submitted**

2. For multi-authored work, give full details of your role in the research included in the paper and in the preparation of the paper. (Attach a further sheet if necessary)

I conducted the field work for this study including organising and running surgical camps providing trichiasis surgery in the community. I liaised with the Kilimanjaro Eye Care Coordinator with regards to these. I also identified and recruited suitable control participants. I performed all the clinical examinations and took the swab samples. I supervised the trichiasis surgery including the biopsy sampling and took the biopsy samples from control participants myself. The histological and immunohistochemical processing was performed at the Institute of Ophthalmology, University College London. I spent several days at the Institute discussing and observing this work with the histotechnicians and Phil Luthert. The histological and immunohistochemical grading was performed by Phil Luther and Ian Cree. I sat with Phil Luthert on a multi-viewer microscope while we worked through the grading systems and observed all of the grading performed by him. I liaised with Ian Cree about the grading performed by him. I performed the data analysis with some guidance from Helen Weiss. I wrote the paper with consideration of comments from co-authors.

Candidate’s signature.....



Supervisor or senior author’s signature to confirm role as stated in (2).....

Title Page

Title:

In vivo confocal microscopy and histopathology of the conjunctiva in healthy and trachomatous conjunctiva: a systematic comparison

Authors & Affiliations:

Victor H. Hu^{1,2}, Martin J. Holland³, Ian A. Cree⁴, James Pullin⁴, Helen A. Weiss⁵, Patrick Massae², William Makupa², David C. W. Mabey³, Robin L. Bailey³, Matthew J. Burton^{1,2} and Phil Luthert⁴.

¹ International Centre for Eye Health, Department of Clinical Research, Faculty of Infectious and Tropical Diseases, London School of Hygiene and Tropical Medicine, London, UK

² Kilimanjaro Centre for Community Ophthalmology, Moshi, Tanzania

³ Department of Clinical Research, Faculty of Infectious and Tropical Diseases, London School of Hygiene and Tropical Medicine, London, UK

⁴ Institute of Ophthalmology, University College London, UK

⁵ Department of Infectious Disease Epidemiology, Faculty of Epidemiology and Population Health, London School of Hygiene and Tropical Medicine, London, UK

Corresponding author details:

Victor Hu
International Centre for Eye Health,
London School of Hygiene and Tropical Medicine,
Keppel Street,
London, WC1E 7HT, UK
Telephone number: +255 76 258 2948
Email: victor.hu@lshtm.ac.uk

Financial support:

This study was funded by grants from the Wellcome Trust (080741/Z/06/Z and 079246/Z/06/Z) and by a grant for the British Council for the Prevention of Blindness.

VHH is supported by a fellowship grant from the British Council for the Prevention of Blindness (Barrie Jones Fellowship). The funders had no part in the study design; in the collection, analysis, and interpretation of data; in the writing of the report; and in the decision to submit the paper for publication.

Conflict of interest:

None of the authors have had, or will receive, any financial support or other benefit which may be viewed as creating a potential conflict of interest.

Running head

In vivo confocal microscopy in scarring trachoma

Address for reprints

International Centre for Eye Health,
London School of Hygiene and Tropical Medicine,
Keppel Street,
London, WC1E 7HT, UK

Key words:

Trachoma; *in vivo* confocal microscopy; histology; conjunctiva; Chlamydia trachomatis; scarring; case-control

Abstract:

Objective: To compare the *in vivo* confocal microscopy (IVCM) analysis of tissue and cellular changes with corresponding immunohistological analysis in normal and diseased conjunctiva.

Design: Comparative study of IVCM and immunohistological analyses of tarsal conjunctiva.

Participants: A total of 67 participants, 34 of whom had severe trichomatous conjunctival scarring and were undergoing trichiasis surgery, and 33 of whom were normal controls undergoing cataract or retinal detachment surgery. Many of the scarred cases also had significant clinical inflammation.

Methods: Participants underwent a clinical examination and IVCM of the tarsal conjunctiva was performed using the Heidelberg Retina Tomograph 3 with the Rostock Cornea Module. At the time of surgery a 3mm conjunctival biopsy was taken which was initially placed in buffered formalin, then embedded into paraffin wax and subsequently stained with hematoxylin and eosin and other tinctorial stains, and by immunohistochemistry for CD45 and CD83.

Main outcome measures: IVCM connective tissue scarring, inflammatory cell density and presence of dendritiform cells were quantitatively assessed using established protocols and masked grading. Immunohistological assessment for comparative analysis including the masked grading of: scarring using cross polarised light to visualise collagen fibres; the inflammatory cell infiltrate seen with hematoxylin and eosin staining; and the presence of CD83+ cells, and CD45+ cells with a dendritic morphology, as markers of mature dendritic cells.

Results: The IVCM connective tissue scarring score was closely correlated with the histological grading of scarring ($p < 0.001$). There was a moderate association of the IVCM inflammatory cell infiltrate and the histological inflammatory cell grade ($p = 0.05$). We did not find any evidence that dendritiform cells seen with IVCM are mature, conventional dendritic cells.

Conclusions: The IVCM analysis of scarring in the tarsal conjunctiva is able to show good agreement with histological grading. The inflammatory cell infiltrate on IVCM has a weaker agreement with histological assessment. The discordance between IVCM dendritiform cells and immunohistochemical dendritic cells may be result of study limitations or may be because these dendritiform structures represent fibroblasts rather than dendritic cells.

Introduction

In vivo confocal microscopy (IVCM) provides high-resolution tissue images of living subjects in a non-invasive manner. It relies on the optical principle of confocality of the illumination and observation systems, i.e., the two systems are focused on the same focal points.^{1, 2} Light outside of the focal plane is highly suppressed, thereby markedly increasing the resolution. This is in contrast to light biomicroscopy, for example with a slit lamp, where there is a large amount of scattered light that limits the maximum resolution which can be attained. The confocal field of view is very small and so the microscope rapidly scans the focal point across the tissue and reconstructs an image. The image obtained is parallel to the surface being examined.

IVCM is increasingly being used in several medical disciplines, including dermatology and gastroenterology, where it has been used to examine for malignant changes.^{3, 4} In ophthalmology there has been a stream of reports on IVCM as a research tool for examining the ocular surface and it is being used increasingly in clinical practice. Uses include the diagnosis and monitoring of microbial keratitis, where it may help to identify acanthamoeba cysts and filamentary fungi; assessment of potentially malignant lesions; and examination of the ocular surface after glaucoma and other forms of surgery.⁵⁻⁸

Trachoma is a chronic, scarring keratoconjunctivitis initiated by recurrent infection with *Chlamydia trachomatis* in childhood.⁹ The scarring complications of the disease, usually seen in adulthood, include tarsal conjunctival scarring, entropion and corneal opacity. We have previously used IVCM to quantify both inflammatory and scarring changes in the tarsal conjunctiva in cicatricial trachoma.^{10, 11} However, interpreting IVCM images can be challenging. In this relatively new field of imaging the structures and morphology observed need to be carefully evaluated to prevent misinterpretation. This is especially true for IVCM of the conjunctiva, underlying tarsal/bulbar tissue and lid margin. This part of the ocular

surface contains a highly specialised mucosal surface, which in contrast to the cornea, is vascular and contains many different structures and cell types including goblet cells, meibomian glands, lymphoid tissue and pseudoglands of Henle.

To validate the interpretation of IVCM images of the tarsal conjunctiva, including those from our previous studies on trachomatous scarring, we conducted a case-control study to systematically compare IVCM with the histological / immunohistological appearance of the tarsal conjunctival surface. Histological analysis of biopsy samples permits greater cellular phenotypic resolution and sub-cellular structures to be identified. Participants with trachomatous conjunctival scarring (many of whom also had a marked inflammation) and controls with healthy conjunctiva were compared. We examined the hypotheses that the IVCM scarring score and inflammatory cell count would show significant agreement with the grading of corresponding immunohistological parameters, and that the presence of IVCM dendritiform cells would be associated with the immunohistological presence of dendritic cells. There have been limited attempts previously to compare IVCM and histological findings, which have been purely descriptive and employed only impression cytology specimens.^{12, 13}

Patients and Methods

Ethical permission & Subject recruitment

This study adhered to the tenets of the Declaration of Helsinki. It was approved by the Tanzanian National Institute of Medical Research Ethics Committee, the Kilimanjaro Christian Medical Centre Ethics Committee and the London School of Hygiene and Tropical Medicine Ethics Committee. The study was explained to potential study subjects and informed consent was obtained before enrolment and recorded. Individuals with trichomatous trichiasis (TT) were recruited from those undergoing trichiasis surgery in the Kilimanjaro Region. Control participants were recruited from patients undergoing cataract or retinal detachment surgery at Kilimanjaro Christian Medical Centre who had healthy tarsal conjunctiva.

Clinical assessment

All subjects were examined by an ophthalmologist using ×2.5 loupes and a bright torch. The 1981 World Health Organization (FPC) trachoma grading system was used to grade conjunctival follicles and papillae, entropion, trichiasis and corneal opacity.¹⁴ A more detailed grading system was used for conjunctival scarring as previously described.^{11, 15}

Confocal microscopy assessment

IVCM examination of the upper tarsal conjunctiva was performed using the Heidelberg Retina Tomograph 3 (HRT3) in combination with the Rostock Corneal Module (RCM) (Heidelberg Engineering GmbH, Dossenheim, Germany) using previously described examination and image grading protocols.^{10, 11} IVCM images were graded for inflammatory features including the inflammatory cell density and the presence of dendritiform cells (DFC), and also for sub-epithelial connective tissue organisation/scarring (Figures 1 and 2).

Biopsy samples and staining

The eyelid was anaesthetized with an injection of 2% lignocaine (Vital Healthcare, India) and the eye cleaned with 5% povidone iodine. A biopsy sample was taken using a 3mm trephine from the tarsal conjunctiva, 2mm from the lid margin, at the junction of the medial $\frac{2}{3}$ and lateral $\frac{1}{3}$ of the everted lid. Samples were immediately placed in 10% neutral buffered formalin and subsequently embedded in paraffin wax. Sections, 4 μ m thick, were cut perpendicular to the conjunctival surface and stained with hematoxylin and eosin (H&E) and stained by immunohistochemistry for CD45 as a marker of nucleated hematopoietic cells (mouse monoclonal antibody, Dako, UK, Clones 2B11+PD7/26, 1:800) and for CD83 as a marker of mature dendritic cells (mouse monoclonal antibody, AbD Serotec, UK, Clone HB1e, 1:75). Prior to immunohistochemical staining sections were dewaxed and pressure-cooked for 4 minutes in de-ionized water with antigen retrieval solution (Vector Lab, UK). After incubation at room temperature for 30 minutes with the primary antibody, sections were incubated with a biotinylated secondary antibody, followed by streptavidin-conjugated horseradish peroxidase (Dako, UK), and finally 3,3'-diaminobenzidine (Dako, UK) was used as the chromogen. Endogenous peroxidase was inhibited using Real Endogenous Peroxidase Block (Dako, UK). The slides were counterstained with Harris hematoxylin. All staining procedures were performed using the Dako autostainer (Dako, UK). Positive control samples were provided by human tonsil sections and omission of primary antibody controls were used throughout.

Microscopic examination of biopsy samples

Grading was performed by ocular pathologists who were masked to the clinical status of the patients. The grading was performed on the sub-epithelial tissue (lamina propria and stroma unless stated otherwise) using the parameters shown below. These were chosen to enable comparison with the IVCM scarring score, inflammatory infiltrate and presence of DFC.

- The degree of scarring was assessed using cross polarised light for both the subepithelium and the tarsus. Initial comparison of the examination of picosirus red

and other tinctorial stains under cross polarised light showed that the organization of collagen bundles was apparent with a variety of staining methods. For assessment purposes we used elastin/Van Gieson stained preparations as these sections contained all of the samples available.. In healthy subepithelial tissue short connective tissue fibres running parallel to the surface in an ordered manner could be seen. In healthy tarsus long connective tissue fibres passing between the meibomian glands could be seen, perpendicular to the surface, which terminated in shorter fibres running parallel to the surface, giving rise to a “T” appearance, Figure 4. Tissue appearing healthy was graded as 0 and grades 1-3 used for progressive disorder of the normal appearance Figures 3-4.

- The inflammatory cell density was assessed using the H&E stained slides using an ordinal scale of 0-3 where 0=scattered cells; 1=few cells; 2=moderate cells; 3=abundant/confluent cells, Figure 5
- Cellular staining with the CD83 antibody as an indicator of dendritic cells (DC). An ordinal scale of 0-3 was used where 0=no/very few cells; 1=occasional cells; 2=moderate cells; 3=abundant/confluent cells, Figure 6.
- To further characterize the presence of DC we counted the number CD45+ cells with dendritic morphology, where the dendritic processes \geq twice the width of the nucleus (in order to exclude CD45+ cells which are not DC), Figure 7. The field with the greatest density of cells using $\times 400$ magnification was used for counting, and cells were counted in the epithelium and subepithelium.

Data analysis

Data were entered into Access 2007 (Microsoft) and analysed using STATA 11.0 (StataCorp LP, TX). The Kruskal-Wallis one-way analysis of variance was used to compare the respective scarring and inflammatory cell measurements gained by IVCN and histology. The Wilcoxon rank sum test was used to compare the IVCN inflammatory cell infiltrate by a binary histological inflammatory cell score (grades 0 and 1 combined vs. grades 2 and 3

combined). A non-parametric test for trend was used to look at the IVCM scarring score by the histological tarsal connective tissue scarring grade. Fisher's exact tests were used to determine the strength of association between IVCM DFC and immunohistochemical CD83 staining. The Wilcoxon rank sum test was used to test for a difference in the number of CD45+ cells with a dendritic morphology on immunohistochemistry according to the presence of IVCM DFC.

Results

Study participants, IVCM and immunohistological findings

Demographic and clinical characteristics of the participants are shown in Table 1. A little over half of the participants were female, ages ranged from 35 to 91 years and the most common ethnic group was Maasai followed by Chagga. There were 34 patients with trachomatous trichiasis and marked conjunctival scarring and 33 control participants without scarring. Demographic, clinical and IVCM characteristics according to the presence of trachomatous scarring has been previously presented.¹¹ The overall IVCM and immunohistological findings are shown in Tables 2 and 3 respectively.

Table 1: Demographic and clinical characteristics

	n (%)
	N=67
<i>Demographic characteristics</i>	
Female	37 (55.2)
Age (years)	
34-45	3 (4.5)
45-55	8 (11.9)
55-65	16 (23.9)
65-75	18 (26.9)
75-85	16 (23.9)
85-95	6 (9.0)
Ethnic group	
Maasai	28 (41.8)
Chagga	18 (26.9)
Pare	8 (11.9)
Other	13 (19.4)
<i>Clinical characteristics</i>	
Trichiasis present*	34 (50.7)
Scarring grade	
S0	33 (49.3)
S1a	0 (0.0)
S1b	0 (0.0)
S1c	6 (9.0)
S2	5 (7.4)
S3	23 (34.3)
Papillary inflammation grade	
P0	35 (52.2)
P1	6 (9.0)
P2	19 (28.4)
P3	7 (10.4)

* Either one or more lashes constantly touching the globe or evidence of recent epilation with a suggestive history.

Table 2: *In vivo* confocal microscopy findings

Mean connective tissue scarring score (95%CI)]	N=51*
	1.41 (1.11-1.71)
Connective tissue scarring grade [n (%)]	N=51*
0-1	26 (51.0)
>1-2	9 (17.6)
>2-3	16 (31.4)
Mean inflammatory cell infiltrate(95%CI)]	N=50*
	1390 (1194-1586)
Dendritiform cells present [n (%)]	N=54*
	17 (31.5)

* It was possible to perform *in vivo* confocal microscopy on 54 out of the 67 participants, and a small number of these scans were not suitable for connective tissue scarring grading or inflammatory cell counting.

CI=confidence interval

Table 3: Immunohistological findings

Subepithelial connective tissue	N=60*
scarring grade [n (%)]	
0	29 (48.3)
1	18 (30.0)
2	12 (20.0)
3	1 (1.7)
Tarsal connective tissue scarring	N=45*
grade [n (%)]	
0	31 (68.9)
1	5 (11.1)
2	7 (15.6)
3	2 (4.4)
Inflammatory cell infiltrate on	N=65*
H&E stain [n (%)]	
0	16 (24.6)
1	29 (44.6)
2	11 (16.9)
3	9 (13.9)
Cellular CD83 staining	N=65*
[n (%)]	
0	14 (21.5)
1	32 (49.2)
2	18 (27.7)
3	1 (1.5)
Mean number of CD45+ cells with	N=67*
dendritic morphology (95%CI)	6.72 (5.15-8.28)

* Some samples did not yield gradable sections and several sections did not have adequate tarsal tissue for grading of the connective tissue scarring.

H&E = Hematoxylin & eosin

Comparison of histological and IVCM connective tissue scarring assessments

The mean IVCM connective tissue scarring score according to the histological subepithelial and tarsal connective tissue scarring grades are shown in Table 4. It can be seen that the higher histological scarring grades are associated with greater IVCM scarring scores. A clear pattern is especially apparent for IVCM scarring score by tarsal histological scarring grade, Figure 5 (non-parametric test for trend <0.001).

Table 4: Comparison of histological and *in vivo* confocal microscopy connective tissue scarring assessments

Mean IVCM scarring score by histological subepithelial scarring grade

Histological scarring grade	Mean IVCM scarring score (95%CI)	N	p-value*
0	0.74 (0.362-1.11)	21	0.0008
1	2.01 (1.56-2.46)	15	
2	2.29 (1.63-2.94)	7	
3	2.00 (-)	1	

Mean IVCM scarring score by histological tarsal scarring grade

Histological scarring grade	Mean IVCM scarring score (95%CI)	N	p-value*
0	0.59 (0.35-0.83)	26	0.0024
1	1.63 (0.93-2.32)	3	
2	1.99 (1.45-2.53)	5	
3	2.5 (1.64-3.53)	2	

IVCM = *in vivo* confocal microscopy

* Kruskal-Wallis analysis of variance.

Comparison of histological and IVCM inflammatory cell density assessments

The mean IVCM inflammatory cell density according to the histological inflammatory cell grade on H&E staining is shown in Table 5. There is some evidence of a difference between the histological grades, but no clear pattern is apparent. However, if the power is increased by combining the bottom two and the top two histological grades, then the top two combined grades have significantly more IVCM inflammatory cells than the bottom two combined grades (mean 1834 [95%CI 1420-2248] vs 1245 [95%CI 1027-1465] cells/mm², p=0.01 with the Wilcoxon rank sum test).

Table 5: Comparison of histological and *in vivo* confocal microscopy inflammatory cell density assessments

Histological inflammatory infiltrate grade	Mean IVCM inflammatory cell density, cells/mm ² (95%CI)	N	p-value*
0	1342 (999-1684)	15	0.05
1	1181 (898-1463)	22	
2	1958 (1487-2570)	7	
3	1660 (1097-2180)	5	

* Kruskal-Wallis analysis of variance

IVCM = *in vivo* confocal microscopy

Comparison of immunohistological dendritic cell parameters and IVCM dendritiform cells

The presence of IVCM DFC showed no significant association with the presence of CD83+ cells (Table 7). The mean number of CD45+ cells which had a dendritic morphology per field was higher if IVCM DFC had been identified, but this was not statistically significant (Table 6).

Table 6: Comparison of immunohistological dendritic cell parameters and the presence of *in vivo* confocal microscopy dendritiform cells

	DFC present	DFC absent	p-value
Cellular CD83 staining [n (%)]	N=17	N=35	0.50*
0	3 (17.7)	7 (20.0)	
1	11 (64.7)	17 (48.6)	
2	3 (17.7)	11 (31.4)	
3	0 (0.0)	0 (0.0)	
Mean number of CD45+ cells with dendritic morphology per field (95%CI)	N=17 9.5 (6.3-12.7)	N=37 5.8 (3.7-8.0)	0.32 [†]

* Chi-squared test

[†] Wilcoxon rank sum test

DFC = dendritiform cells on IVCM

CI = Confidence interval

Discussion

In this study we have used defined grading systems to systematically compare IVCM of the tarsal conjunctival surface with immunohistological findings in order to validate our interpretation of confocal microscopy. The IVCM connective tissue scarring score was strongly correlated with the histological assessment of scarring. The histological quantification of scarring has not been well-defined, particularly in the tarsal conjunctival surface. We developed a novel system for grading the amount of scarring present using polarised light to directly visualise connective tissue fibres. This grading also shows a very close association with the presence of clinical scarring (paper in preparation). We have previously shown the IVCM scarring assessment to also be strongly associated with clinical scarring.¹¹ Overall, these studies suggest that scarring can be reliably assessed with IVCM. Previous descriptions of conjunctival scarring using IVCM have been very limited.¹⁶⁻¹⁸

The presence of small, round, hyper-reflective bodies has been widely reported in IVCM studies of the conjunctival surface and these are generally accepted as representing the nuclei of inflammatory cells. We did find some evidence of an association between this apparent IVCM cell infiltrate and inflammatory cells seen histologically. Leucocytes are the most likely explanation as the cell type responsible for these hyper-reflective bodies seen on IVCM with few plausible alternative explanations. Previous studies have found a similar IVCM appearance to be associated with clinical inflammation in vernal keratoconjunctivitis and to show a rapid increase in rabbit conjunctiva after the injection of lipopolysaccharide.¹⁹

20

We found no association between the presence of IVCM DFC and the histological identification of DC. This may be a result of limitations of this study. To maximise the number of histological sections available they were cut perpendicular to the conjunctival surface. This may limit the detection of DC as the dendritic processes appear to spread out parallel to the surface and so may be more easily identified by IVCM where the image obtained is

parallel to the surface. Multiple IVCM images were obtained from all over the tarsal conjunctiva for analysis which were compared to a single biopsy specimen. Additionally, dendritic cell immunophenotyping is complex and requires a combination of staining intensity coupled with positive and negative markers in order to confidently identify different types.²¹⁻²³ We had insufficient tissue to exhaustively type this cell population and selected markers which we expected would best indicate a number of cell types including DC. The IVCM grading identified DFC with well developed dendritic processes, suggesting mature DC, which would usually stain with CD83.^{24, 25} The use of cellular CD45 staining and dendritic morphology should also have identified mature DC.

An alternative explanation for the discordance between the IVCM and histology is that the DFC seen on IVCM are not actually DCs. One possibility is that these dendritiform structures are fibroblasts, which can have marked dendritic extensions.^{26, 27} IVCM studies have shown similar DFC to be increased in microbial infection, vernal keratoconjunctivitis, contact lens wear, immune-mediated inflammation and pterygium.^{20, 28-31} Many of these conditions are associated with scarring and fibroblasts would be expected to be present. The cornea contains numerous keratocytes and these can transform into activated corneal fibroblasts in response to injury.^{32, 33} The comprehensive identification of these conjunctival DFCs requires further study.

We chose to use an ordinal scale for the immunohistological grading of inflammatory cells and cellular CD83 staining, with the observer masked to the clinical status. Alternative forms of analysis include cell counts on representative fields. However, this is open to bias unless the fields selected are chosen at random which is difficult if the infiltrate is not evenly distributed within the tissue, and it also restricts the amount of tissue used for the assessment.

This is the first time that IVCM analysis has been objectively and quantitatively compared to immunohistological findings. The comparison was performed using masked observers and defined grading systems on a large number of participants thereby allowing significance testing to be performed. We have shown found that the grading of scarring in the tarsal conjunctiva with IVCM can show very good correlation with histological grading of scarring. However, we found only a moderate association between the amount of presumed inflammatory cell infiltrate on IVCM and that reported with histology. We did not find evidence to support the interpretation that DFC seen with IVCM are mature, conventional, immune DC. This may be a result of study limitations, but may also indicate that these dendritiform structures represent something else, such as fibroblasts.

Acknowledgements

We would like to acknowledge the help of Heidi Barnes and Caroline Thaug at the Institute of Ophthalmology for help with processing the biopsy samples and with using the microscope camera. We would also like to thank Anthony Hall and the theatre staff at the Eye Department of the Kilimanjaro Christian Medical Centre for their help with recruiting control participants.

References

1. Jalbert I, Stapleton F, Papas E, et al. In vivo confocal microscopy of the human cornea. *Br J Ophthalmol* 2003;87(2):225-36.
2. Guthoff RF, Zhivov A, Stachs O. In vivo confocal microscopy, an inner vision of the cornea - a major review. *Clin Experiment Ophthalmol* 2009;37(1):100-17.
3. Rito C, Pineiro-Maceira J. [Reflectance confocal microscopy in the diagnosis of cutaneous melanoma]. *An Bras Dermatol* 2009;84(6):636-42.
4. Li WB, Zuo XL, Li CQ, et al. Diagnostic value of confocal laser endomicroscopy for gastric superficial cancerous lesions. *Gut* 2011;60(3):299-306.
5. Patel DV, McGhee CN. In vivo confocal microscopy of human corneal nerves in health, in ocular and systemic disease, and following corneal surgery: a review. *Br J Ophthalmol* 2009;93(7):853-60.
6. Niederer RL, McGhee CN. Clinical in vivo confocal microscopy of the human cornea in health and disease. *Prog Retin Eye Res* 2010;29(1):30-58.
7. Kumar RL, Cruzat A, Hamrah P. Current state of in vivo confocal microscopy in management of microbial keratitis. *Semin Ophthalmol* 2010;25(5-6):166-70.

8. Messmer EM, Mackert MJ, Zapp DM, Kampik A. In vivo confocal microscopy of pigmented conjunctival tumors. *Graefes Arch Clin Exp Ophthalmol* 2006;244(11):1437-45.
9. Hu VH, Harding-Esch EM, Burton MJ, et al. Epidemiology and control of trachoma: systematic review. *Trop Med Int Health* 2010;15(6):673-91.
10. Hu VH, Massae P, Weiss HA, et al. In vivo confocal microscopy of trachoma in relation to normal tarsal conjunctiva. *Ophthalmology* 2011;118(4):747-54.
11. Hu VH, Weiss HA, Massae P, et al. In Vivo Confocal Microscopy in Scarring Trachoma. *Ophthalmology* 2011.
12. Meltendorf C, Buhren J, Bug R, et al. Correlation between clinical in vivo confocal microscopic and ex vivo histopathologic findings of Salzmann nodular degeneration. *Cornea* 2006;25(6):734-8.
13. De Nicola R, Labbe A, Amar N, et al. [In vivo confocal microscopy and ocular surface diseases: anatomical-clinical correlations]. *J Fr Ophtalmol* 2005;28(7):691-8.
14. Dawson C, Jones B, Tarizzo M. Guide to trachoma control in programmes for the prevention of blindness. Geneva: World Health Organization, 1981.
15. Hu VH, Massae P, Weiss HA, et al. Bacterial infection in scarring trachoma. *Invest Ophthalmol Vis Sci* 2011;52(5):2181-6.
16. Messmer EM, Mackert MJ, Zapp DM, Kampik A. In vivo confocal microscopy of normal conjunctiva and conjunctivitis. *Cornea* 2006;25(7):781-8.
17. Hu Y, Adan ES, Matsumoto Y, et al. Conjunctival in vivo confocal scanning laser microscopy in patients with atopic keratoconjunctivitis. *Mol Vis* 2007;13:1379-89.
18. Labbe A, Dupas B, Hamard P, Baudouin C. In vivo confocal microscopy study of blebs after filtering surgery. *Ophthalmology* 2005;112(11):1979.
19. Liang H, Baudouin C, Labbe A, et al. In vivo confocal microscopy and ex vivo flow cytometry: new tools for assessing ocular inflammation applied to rabbit lipopolysaccharide-induced conjunctivitis. *Mol Vis* 2006;12:1392-402.
20. Le Q, Hong J, Zhu W, et al. In vivo laser scanning confocal microscopy of vernal keratoconjunctivitis. *Clin Experiment Ophthalmol* 2011;39(1):53-60.
21. Baudouin C, Brignole F, Pisella PJ, et al. Immunophenotyping of human dendriform cells from the conjunctival epithelium. *Curr Eye Res* 1997;16(5):475-81.
22. Adams S, O'Neill DW, Bhardwaj N. Recent advances in dendritic cell biology. *J Clin Immunol* 2005;25(3):177-88.
23. Merad M, Ginhoux F, Collin M. Origin, homeostasis and function of Langerhans cells and other langerin-expressing dendritic cells. *Nat Rev Immunol* 2008;8(12):935-47.
24. Prazma CM, Tedder TF. Dendritic cell CD83: a therapeutic target or innocent bystander? *Immunol Lett* 2008;115(1):1-8.
25. Breloer M, Fleischer B. CD83 regulates lymphocyte maturation, activation and homeostasis. *Trends Immunol* 2008;29(4):186-94.
26. Rhee S, Grinnell F. P21-activated kinase 1: convergence point in PDGF- and LPA-stimulated collagen matrix contraction by human fibroblasts. *J Cell Biol* 2006;172(3):423-32.
27. Abe M, Ho CH, Kamm KE, Grinnell F. Different molecular motors mediate platelet-derived growth factor and lysophosphatidic acid-stimulated floating collagen matrix contraction. *J Biol Chem* 2003;278(48):47707-12.
28. Cruzat A, Witkin D, Baniasadi N, et al. Inflammation and the nervous system: the connection in the cornea in patients with infectious keratitis. *Invest Ophthalmol Vis Sci* 2011;52(8):5136-43.
29. Zhivov A, Stave J, Vollmar B, Guthoff R. In vivo confocal microscopic evaluation of langerhans cell density and distribution in the corneal epithelium of healthy volunteers and contact lens wearers. *Cornea* 2007;26(1):47-54.
30. Mastropasqua L, Nubile M, Lanzini M, et al. Epithelial dendritic cell distribution in normal and inflamed human cornea: in vivo confocal microscopy study. *Am J Ophthalmol* 2006;142(5):736-44.

31. Wang Y, Zhao F, Zhu W, et al. In vivo confocal microscopic evaluation of morphologic changes and dendritic cell distribution in pterygium. *Am J Ophthalmol* 2010;150(5):650-5 e1.
32. Fini ME. Keratocyte and fibroblast phenotypes in the repairing cornea. *Prog Retin Eye Res* 1999;18(4):529-51.
33. West-Mays JA, Dwivedi DJ. The keratocyte: corneal stromal cell with variable repair phenotypes. *Int J Biochem Cell Biol* 2006;38(10):1625-31.

Figure 1: *In vivo* confocal microscopy grading system of inflammatory features. Images are 400×400µm. **A, Inflammatory infiltrate:** seen as multiple bright white nuclei. The mean inflammatory cell density of 3 randomly selected volume scans is calculated. The individual scan with the highest density of cells from within the volume scan is used. **B, Dendritiform cells:** graded as present or absent. To be present, the mean number of DCs per volume scan needs to be ≥1. The largest number of dendritiform cells in any individual scan in a volume scan is used for measurement. A mean number of ≥1 is used to differentiate occasional dendritiform cells seen in scans of otherwise normal subjects. **C, Tissue edema:** seen as multiple black empty spaces. Graded as present or absent in any volume scan. **D, Papillae:** seen as elevations with a central vascular network. Graded as present or absent in any volume scan.

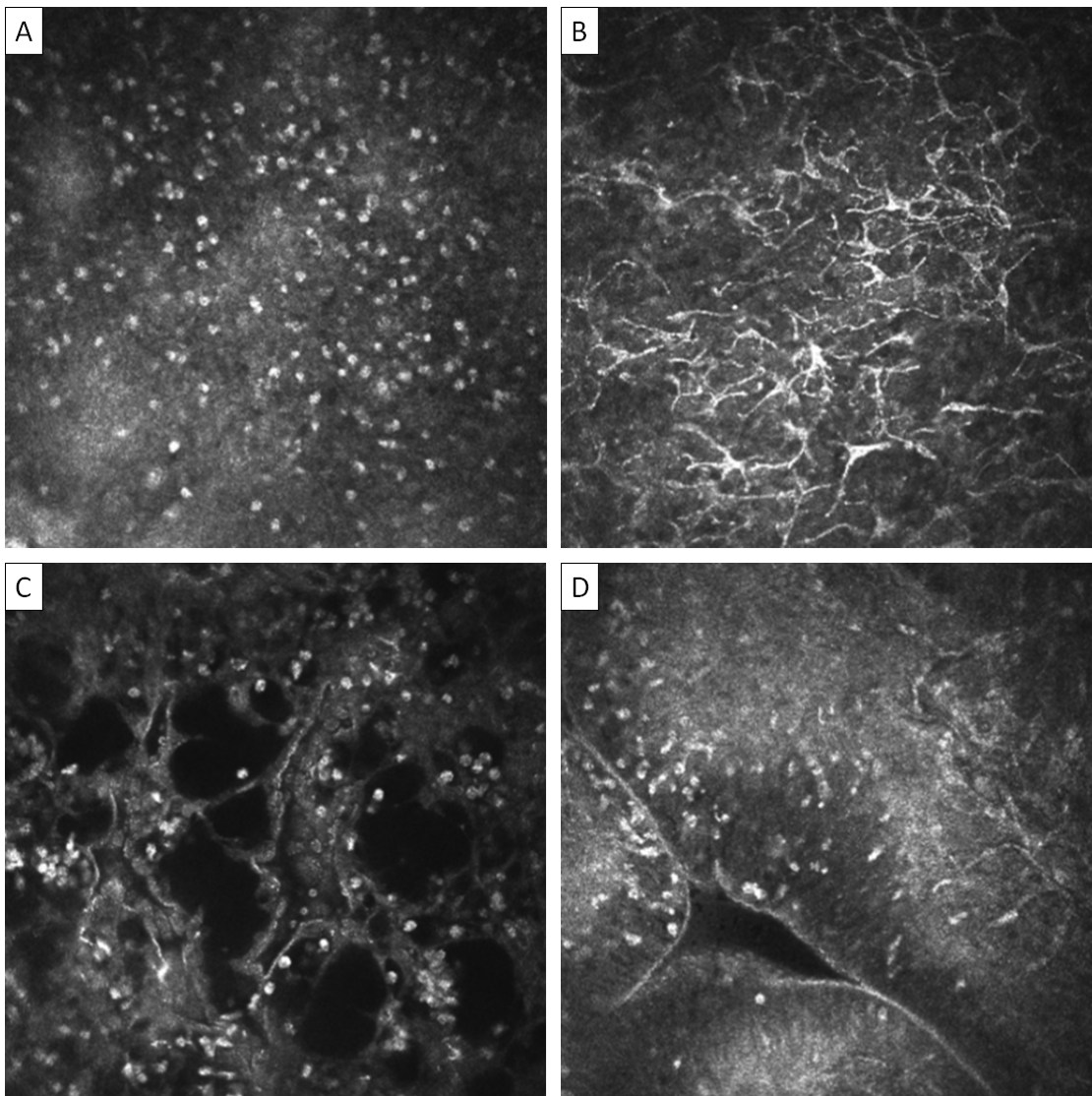


Figure 2: *In vivo* confocal microscopy grading system for conjunctival connective tissue organization. Images are 400×400µm. (A) Normal: homogenous, amorphous appearance, with occasional, fine, wispy strands. (B) Grade 1: heterogenous appearance with poorly defined clumps or bands present. (C) Grade 2: clearly defined bands of tissue which constitute less than 50% of the area of the scan. (D) Grade 3: clearly defined bands or sheets of tissue which constitute 50% or more of the area of the scan and in which striations are present. If different grades of scarring are seen within a particular volume scan then the highest grade is recorded. The connective tissue which is graded needs to be separate from that associated with the vascular tissue, if this is not possible then the scan is considered ungradable.

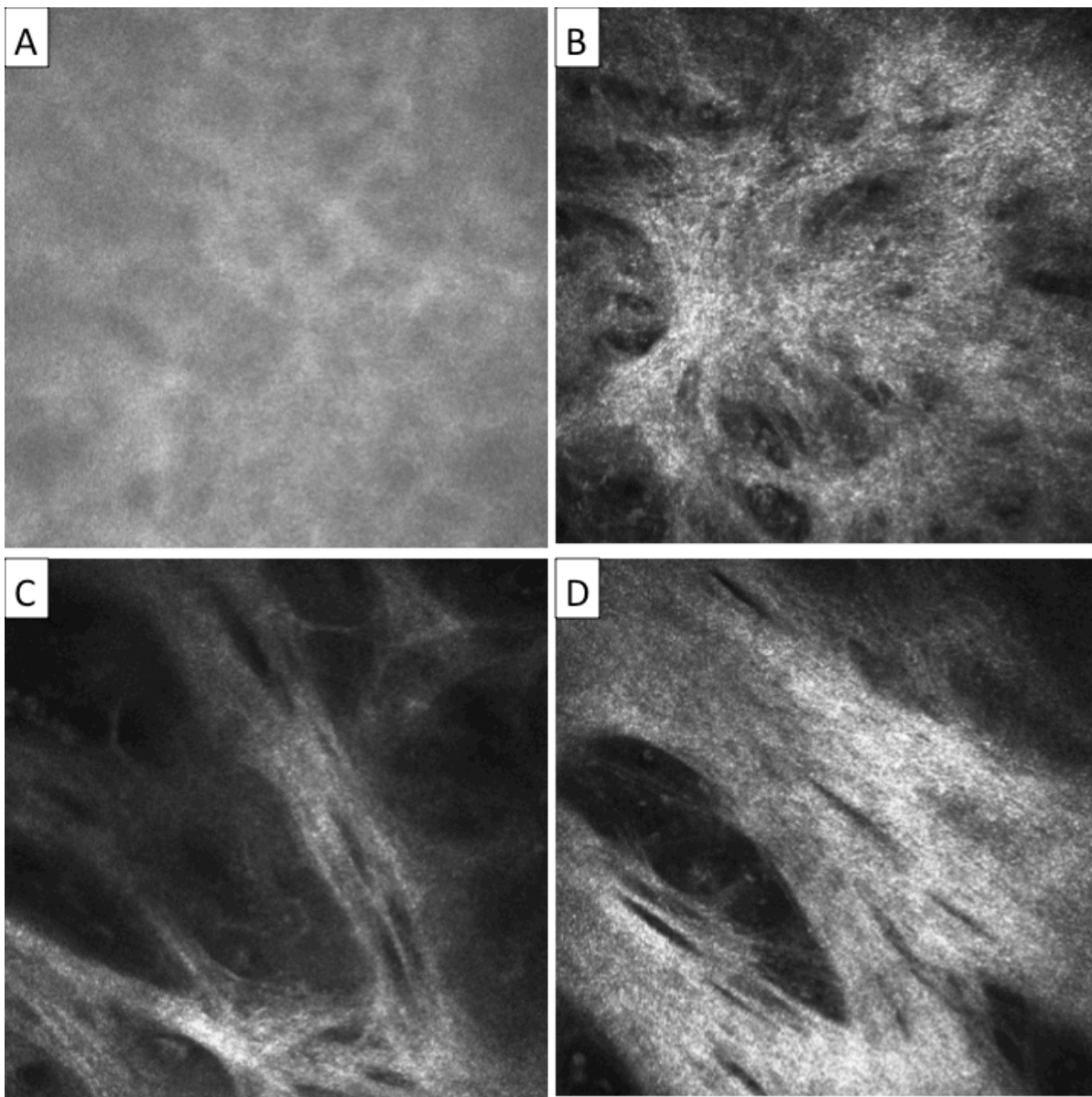


Figure 3: Example grading photos for the histological grading of connective tissue scarring in the conjunctival subepithelial tissue using cross polarized light. The top images shows collagen fibres parallel with the surface found in normal tissue (arrows) and is graded 0. Subsequent images show progressive disorganisation of this appearance, grades 1-3. Original magnification $\times 100$.




Figure 4: Example grading photos for the histological grading of connective tissue scarring in the tarsal tissue using cross polarized light. The top image shows long collagen fibres between the meibomian glands which join shorter fibres next to the stroma forming a “T” sign in normal tissue (arrow), which is graded 0. Subsequent images show progressive disorganisation of this appearance, grades 1-3. Original magnification $\times 100$.

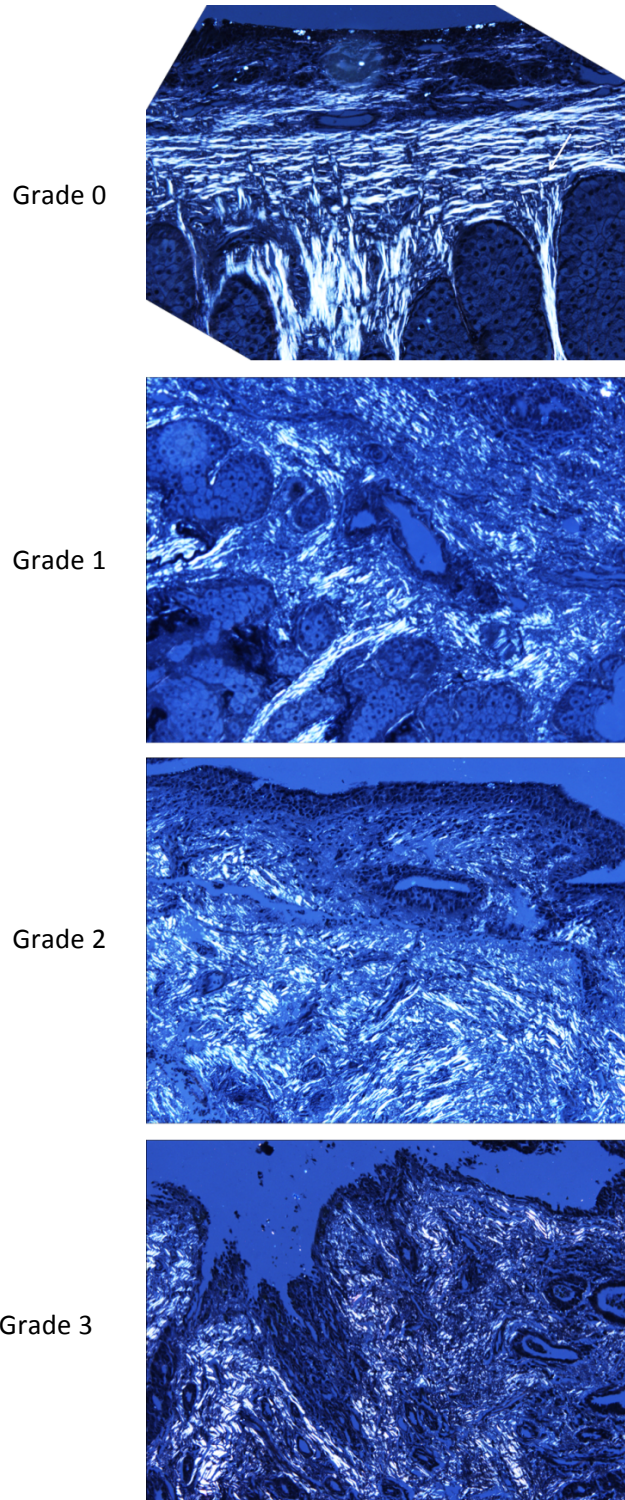
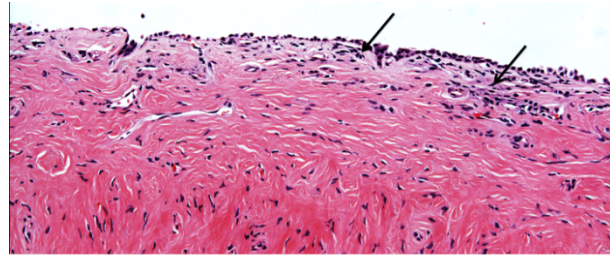
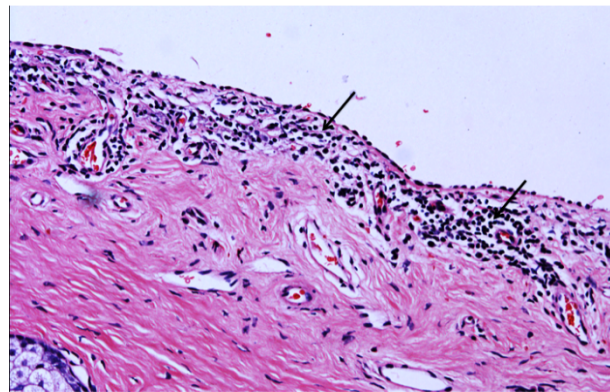


Figure 5: Example grading photos for the inflammatory cell infiltrate on the hematoxylin and eosin stain in the sub-epithelium (arrows). Original magnification $\times 200$.

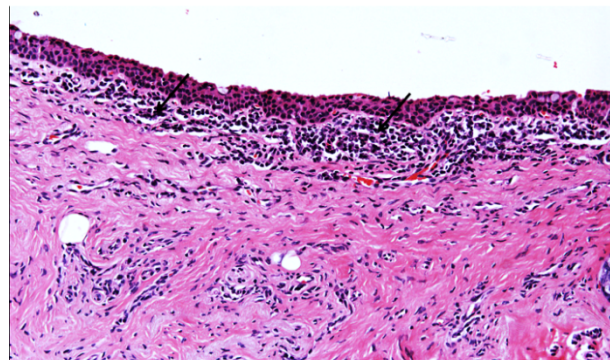
Grade 0



Grade 1



Grade 2



Grade 3

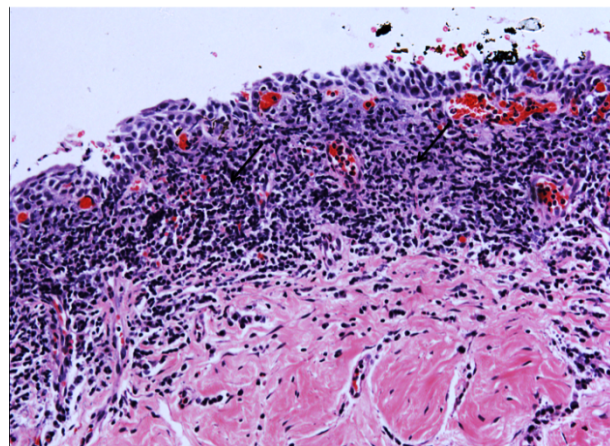
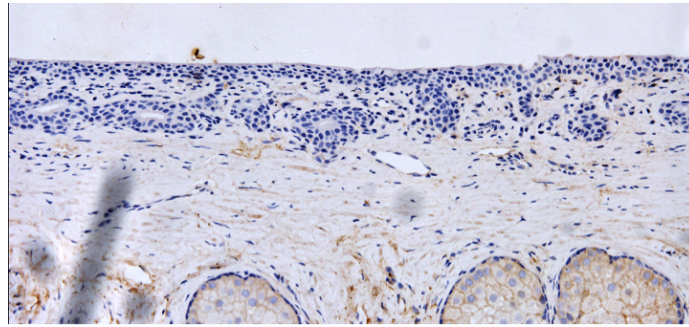
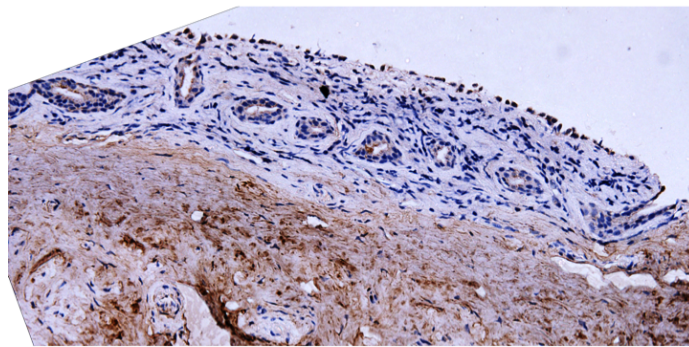


Figure 6: Example grading photos for the CD83+ cells in the sub-epithelium (stained brown).
Original magnification $\times 200$.

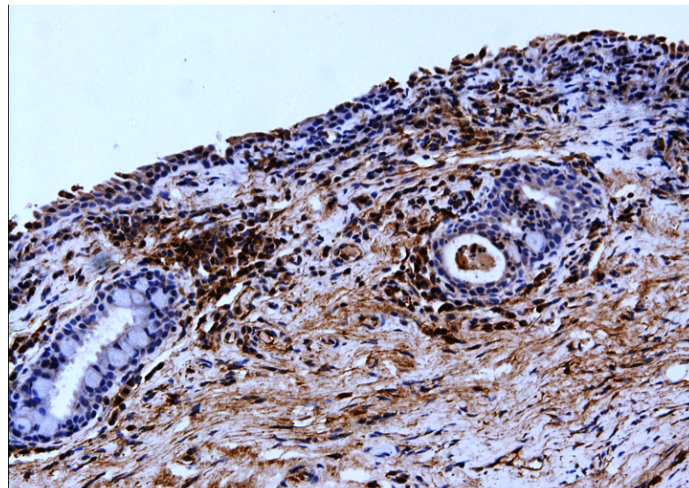
Grade 0



Grade 1



Grade 2



Grade 3



Figure 7: CD45+ cells with a dendritic morphology (stained brown, arrows). Original magnification $\times 400$.

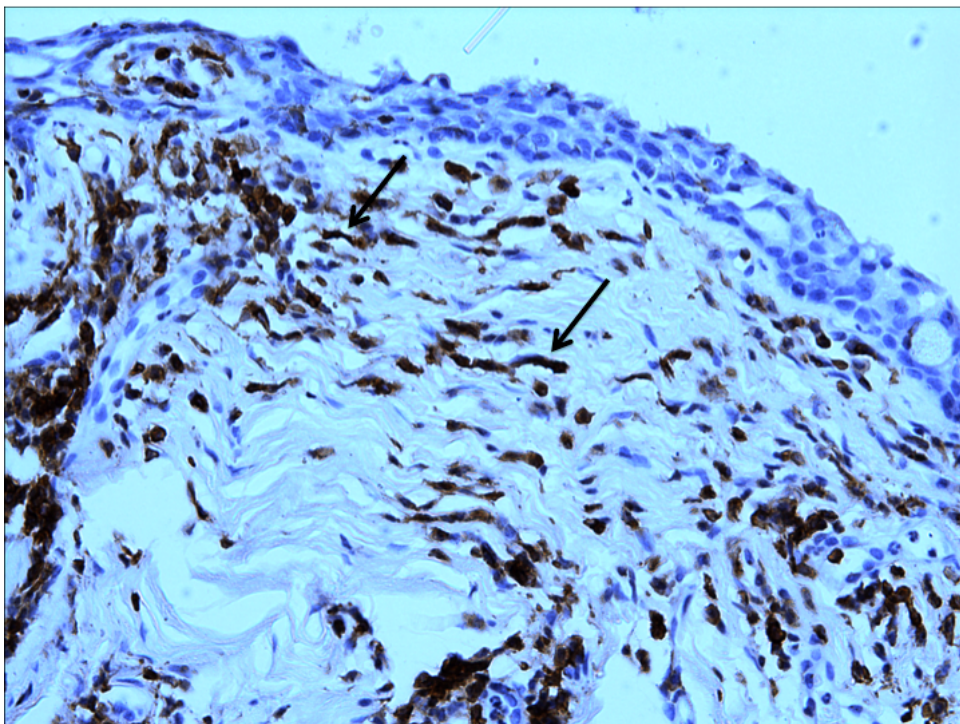
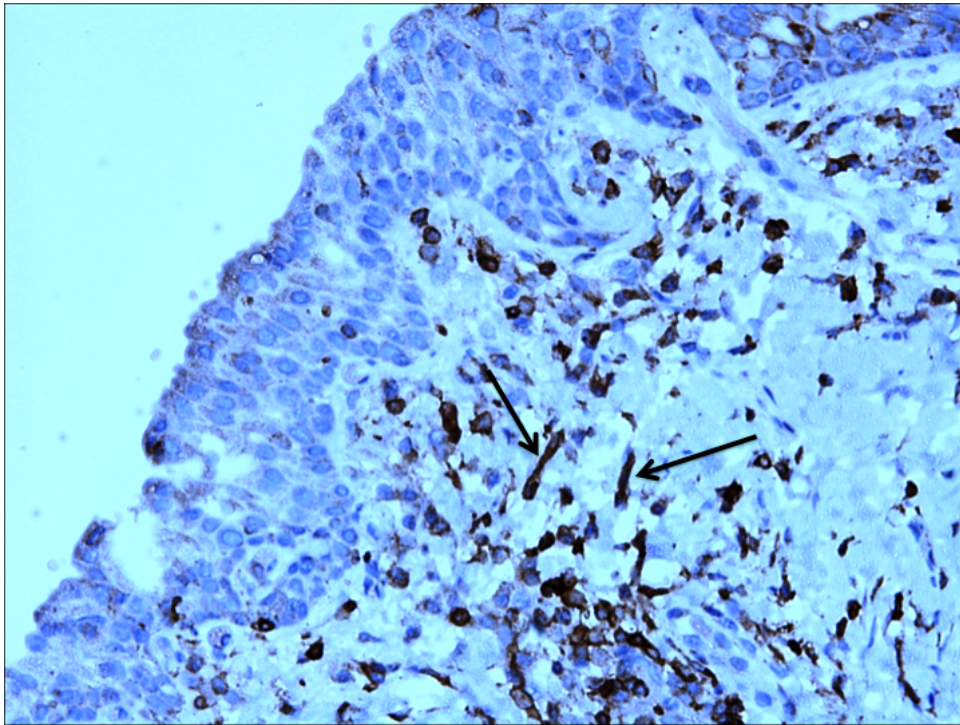
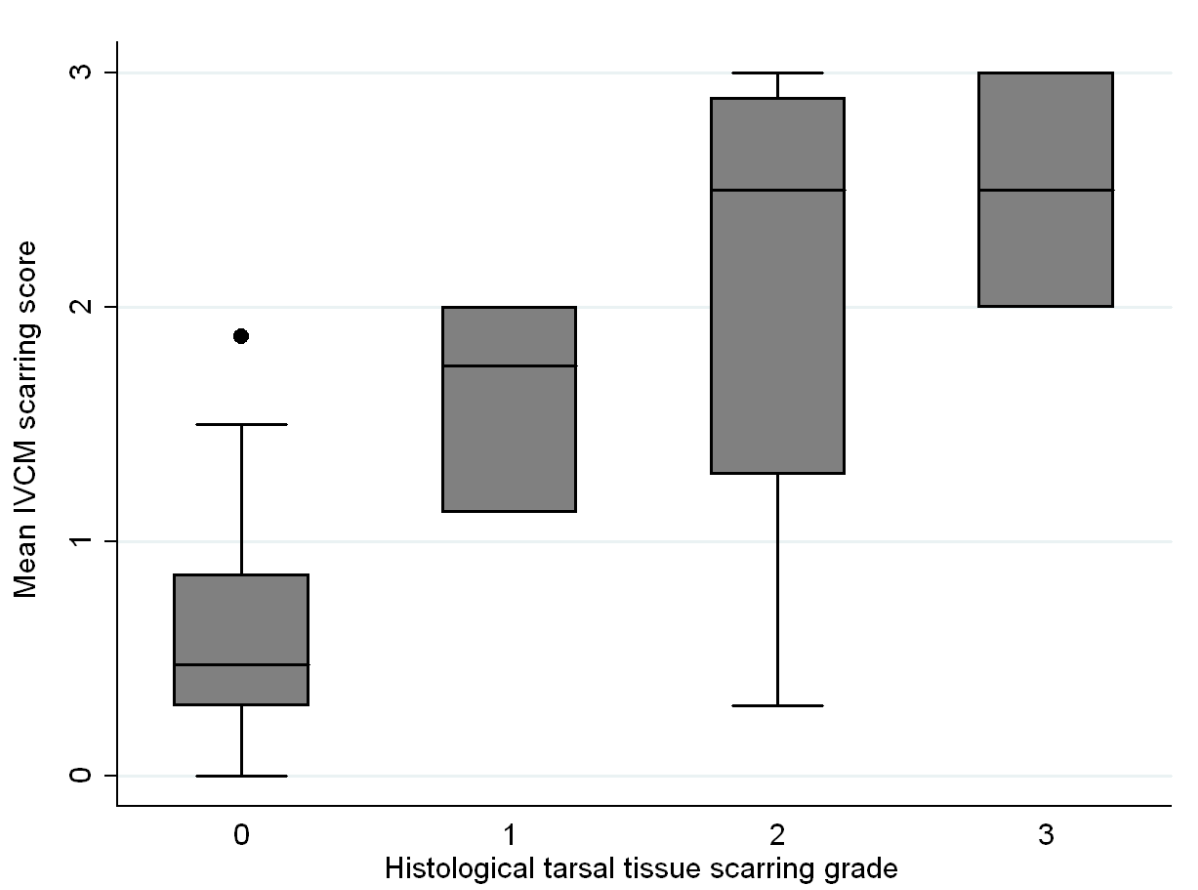


Figure 8: Mean IVCM connective tissue scarring score by histological tarsal connective tissue scarring grade



Chapter 11

Bacterial Infection in Scarring Trachoma



Research paper comparing the frequency of bacterial infection in cases with trichomatous scarring and controls

Cover sheet for each ‘research/review paper’ included in a research thesis

1. For a ‘research/review paper’ already published

1.1. Where was the work published? ***Investigative Ophthalmology and Visual Science***

1.2. When was the work published? ***April 2011***

1.3. Was the work subject to academic peer review? ***Yes***

1.4. Have you retained the copyright for the work? ***No***

If no, or if the work is being included in its published format, attach evidence of permission from copyright holder (publisher or other author) to include work

See Appendix 7e

2. For multi-authored work, give full details of your role in the research included in the paper and in the preparation of the paper. (Attach a further sheet if necessary)

I conducted the field work for this study including performing the clinical examination and taking the swab samples. I analysed the data, with some guidance from Helen Weiss and Matthew Burton. I wrote the paper with consideration of comments from co-authors. The microbiological culture was performed by the Duke University group at the Kilimanjaro Biotechnology Laboratory, with whom I liaised.

Candidate’s signature.....

A handwritten signature in black ink, appearing to read 'M. Burton', is shown within a light gray rectangular box.

Supervisor or senior author’s signature to confirm role as stated in (2).....

Bacterial Infection in Scarring Trachoma

Victor H. Hu,^{1,2} Patrick Massae,² Helen A. Weiss,³ Caroline Chevallier,^{4,5}
Jecinta J. Onyango,⁵ Isaac A. Afwamba,⁵ David C. W. Mabey,⁶ Robin L. Bailey,⁶
and Matthew J. Burton^{1,2}

PURPOSE. To assess whether non-chlamydial bacterial infection is associated with trichomatous scarring in adults.

METHODS. This was a case-control study of 360 cases with trichomatous scarring but without trichiasis, and 360 controls without scarring. All participants underwent clinical examination, and a swab was taken from the inferior conjunctival fornix. Samples were inoculated onto blood and chocolate agar later that day.

RESULTS. Bacterial isolates were identified in 54.0% of cases compared with 34.6% of controls ($P < 0.001$). A multivariate logistic regression model adjusted for age and lack of education showed that scarring was associated with the presence of commensal organisms (odds ratio [OR], 1.46; 95% confidence interval [CI], 1.01–2.09) and was strongly associated with the presence of pathogenic organisms (OR, 4.08; 95% CI, 1.59–10.45). There was an increasing prevalence of all bacterial isolates with increasing severity of scarring ($P_{\text{trend}} < 0.001$).

CONCLUSIONS. Trichomatous scarring is strongly associated with non-chlamydial bacterial infection compared with controls. The role of such infection with regard to scarring progression should be investigated and may have important implications for trachoma control strategies and prevention of blindness. (*Invest Ophthalmol Vis Sci.* 2011;52:2181–2186) DOI: 10.1167/iovs.10-5829

Trachoma is the leading infectious cause of blindness worldwide. It is caused by infection with *Chlamydia trachomatis* and is characterized by inflammatory changes in the conjunctiva in children with subsequent conjunctival scarring, trichiasis, and blinding corneal opacity in adults. It is estimated that more than 1.3 million people are blind from the disease,

8.2 million have trichiasis, and 40 million have active disease.^{1,2}

Over the past 30 years, because of improved living standards and the implementation of trachoma control strategies, there has been an encouraging downward trend in the global prevalence of people with active trachoma.^{2–5} However, trachoma is still a public health problem in more than 50 countries with high levels of active disease where children are at future risk of scarring and blindness.⁵ The number of people estimated to have trichiasis has shown little decline since 1991, suggesting that progressive conjunctival scarring can occur even when there has been a marked reduction in active disease and *C. trachomatis* infection and that those who already have conjunctival scarring are at risk of going on to blinding corneal opacity caused by trachoma.

While nearly all children in hyperendemic areas suffer repeated infection with *C. trachomatis*, it is unclear which factors drive the scarring process in the conjunctiva, why only a proportion of scarred subjects subsequently have trichiasis, and why only a proportion of these become blind. Severe inflammation and prolonged chlamydial infection appear to put children at increased risk of future scarring.^{6,7} However, infection with *Chlamydia trachomatis* is only rarely found in adults, suggesting that this is not necessarily the only factor driving progressive scarring.^{8–11} While the onset of trichiasis may be associated with chlamydial infection,¹² incident trichiasis has also been found to develop in a significant proportion of eyes in a cohort where the chlamydial infection rate was 1%.^{12,13}

Chronic conjunctival inflammation is probably a key factor in the development of blinding trachoma.^{6,7,13–15} An important element in maintaining this inflammatory state may be non-chlamydial bacterial infection. Previous studies have shown that (non-chlamydial) bacterial infection is found more frequently in patients with trichiasis and is associated with trichiasis recurrence after surgery.^{8,10,15} Patients with trichomatous conjunctival scarring without trichiasis were also found to have an increased frequency of bacterial infection compared with controls, although this was not statistically significant, probably due to a limited sample size.¹⁰ A recent study examining trichiasis patients 1 year after surgery found that, after adjustment for other factors, bacterial infection was significantly associated with elevated levels of interleukin-1 β , matrix metalloproteinase-9, and the ratio of matrix metalloproteinase-1/tissue inhibitor metalloproteinase-1.¹⁶ This finding suggests that bacterial infection may promote a proinflammatory and tissue remodelling response in the conjunctiva, possibly through innate immune mechanisms, which may be an important factor in the pathogenesis of trichomatous scarring and blindness.

The purpose of this study was to compare the frequency and type of non-chlamydial bacterial conjunctival infection between subjects with trichomatous scarring and controls. A strengthened understanding of the pathophysiology of trichomatous scarring and its progression will help in the assessment

From the ¹International Centre for Eye Health and the ⁶Clinical Research Unit, Department of Infectious and Tropical Diseases, and the ³MRC Tropical Epidemiology Group, London School of Hygiene and Tropical Medicine, London, United Kingdom; the ²Kilimanjaro Centre for Community Ophthalmology, Moshi, Tanzania; the ⁴Duke Global Health Institute, Duke University, Durham, North Carolina; and the ⁵Biotechnology Laboratory, Kilimanjaro Christian Medical Centre, Moshi, Tanzania.

Supported by a fellowship grant to MJB from the Wellcome Trust (080741/Z/06/Z). VHH is supported by a fellowship grant from the British Council for the Prevention of Blindness (Barrie Jones Fellowship). The funders had no part in the study design; in the collection, analysis, and interpretation of data; in the writing of the report; and in the decision to submit the paper for publication.

Submitted for publication May 4, 2010; revised August 19 and October 14, 2010; accepted October 17, 2010.

Disclosure: V.H. Hu, None; P. Massae, None; H.A. Weiss, None; C. Chevallier, None; J.J. Onyango, None; I.A. Afwamba, None; D.C.W. Mabey, None; R.L. Bailey, None; M.J. Burton, None

Corresponding author: Victor H. Hu, International Centre for Eye Health, London School of Hygiene and Tropical Medicine, Keppel Street, London, WC1E 7HT, UK; victor.hu@lshtm.ac.uk.

of current blindness prevention strategies and assist in the development of new interventions.

METHODS

Ethical Approval

This study adhered to the tenets of the Declaration of Helsinki. It was approved by the Tanzanian National Institute of Medical Research Ethics Committee, the Kilimanjaro Christian Medical Centre Ethics Committee and the London School of Hygiene and Tropical Medicine Ethics Committee. The study was explained to potential study subjects and written, informed consent was obtained before enrollment.

Subject Recruitment

This study was conducted in the Siha district of the Kilimanjaro region of northern Tanzania, in what was historically a single village. Two years before the study the area was divided into three administrative units, but these still form a single continuous geographic entity. Previous surveys of children in this village showed a moderate level of active trachoma. A survey conducted 6 months before the start of this study found a follicular trachoma (TF) prevalence rate of 18% among 1- to 9-year-olds. However, no children of the 43 randomly selected individuals from this village were positive for chlamydia infection by PCR (Amplicor; Roche Molecular Diagnostics, Mannheim, Germany) (Courtright P, personal communication, October 2010). A two-stage process was undertaken to identify suitable candidates for a case-control study. Initially, a census was made of the resident adult population (18 years or older). At the time of the enumeration, door-to-door visits were conducted, and available adults were screened for the presence of trachomatous conjunctival scarring. After participants with trichiasis or previous eyelid surgery were excluded, individuals with scarring were invited to join a related cohort study. Only those with more than minimal scarring (grade S1b or worse, see below) were included in the analysis of this case-control study. An equal number of village residents without scarring were invited to join as control subjects, frequency matched by ethnicity.

Clinical Examination

All subjects were examined by an ophthalmologist (VH) using $\times 2.5$ loupes and a bright torch. Examinations were performed in a dark tent, ensuring standard conditions. The 1981 World Health Organization trachoma grading system³ was used with some modification. The WHO system for grading conjunctival scarring does not have very objective definitions for "mild" or "moderate" scarring. Therefore, we developed a modified system for classifying tarsal conjunctival scarring (Table 1; example photographs shown in Supplementary Fig. S1, <http://www.iovs.org/lookup/suppl/doi:10.1167/iovs.10-5829/-/DCSupplemental>).

TABLE 1. Tarsal Conjunctival Scarring Grading System

Grade	Definition*
S1	Scarring occupying $<1/3$ of the upper lid
S1a	One or more pinpoint scars and/or a single line of scarring less than 2 mm in length†
S1b	Multiples lines of scarring less than 2 mm in length
S1c	One or more lines/patches of scarring each 2 mm or more in length/maximal dimension
S2	Patches of scarring occupying in surface area $\geq 1/3$ but $< 2/3$ of the upper lid
3	Patches of scarring occupying in surface area $\geq 2/3$ of the upper lid

* Upper lid, zones 2 and 3 of the everted upper lid.³

† 2 mm was chosen, as this is the approximate width of the lower lid margin, which is readily available for comparison.

Microbiology Samples and Analysis

The conjunctiva was anesthetized with preservative-free proxymetacaine 0.5% eye drops (Minims; Chauvin Pharmaceuticals, Montpellier, France). A rayon-tipped swab sample was collected from the inferior fornix and placed immediately into Amies charcoal transport medium (Sterilin, Caerphilly, UK) and kept at ambient temperature. Samples were inoculated onto blood and chocolate agar later the same day (rarely >6 hours, usually <5 hours from collection time) and incubated at 37°C for 48 hours. Culture isolates were identified by standard microbiologic techniques.

Sample Size and Data Analysis

This study was part of a larger series of related studies on the pathogenesis of trachomatous scarring with the sample size calculated to encompass these other components. The sample of 360 cases and 360 controls has $>90\%$ power to detect an association with non-chlamydial bacterial infection with an odds ratio of 2.5 when such infection is present in 6%¹⁰ of control subjects.

Data were entered into a database (Access 2007; Microsoft, Redmond, WA) and analyzed (Stata 10.0; StataCorp LP, College Station, TX). The χ^2 test was used to determine strength of association for individual bacterial isolates or groups of isolates (commensal or pathogenic organisms) according to case-control status. A nonparametric test for trend was used to look at prevalence of bacterial culture by the ordered categories of scarring severity. Given the known association of trachomatous scarring with age, logistic regression models were used to estimate single-factor, age-adjusted, odds ratios (ORs) and 95% confidence intervals (CIs) for factors associated with the presence of scarring and inflammation. A multivariable logistic regression model was fitted, including age as an a priori factor, and other factors, if they were associated with scarring in the age-adjusted analysis and independently associated in the multivariable model ($P < 0.1$). Likelihood ratio tests were used to assess the strength of association of each factor with the outcome, and tests for nonlinearity were conducted to assess whether fitting age as a continuous variable provided an adequate fit to the data.

RESULTS

This village had an adult population of 3626 people at the time of the census, of whom 2418 (67%) were seen. Of those not seen, 711 (19.6%) were absent at the time of the census, despite two visits; 347 (9.6%) were temporarily resident elsewhere; and 150 (4.1%) refused examination. We excluded 36 (1.0%) due to the presence of trichiasis, previous eyelid surgery, or an inability to give informed consent. Of the remaining, 862 (23.8%) had trachomatous conjunctival scarring, and 1520 (41.9%) did not have scarring.

We recruited 360 cases with trachomatous conjunctival scarring and 360 control subjects without scarring. Baseline demographic characteristics are shown in Table 2. The majority of cases and controls were of Maasai ethnicity (77% of both groups) followed by Chagga ethnicity (11% of both groups). The controls were younger than the entire census population (mean age, 31.9 vs. 37.4 years; $P < 0.001$), which may cause an overestimation of the association of scarring with age in the study population. Odds of trachomatous scarring increased twofold with each 10-year increase in age ($P < 0.001$). After adjustment for age, lack of education was strongly associated with scarring.

Clinical findings are shown in Table 2. The scarring was mostly mild to moderate. Conjunctival inflammation (grades P2 and P3) was present in 25.5% of cases and in none of the controls. Follicles were found very infrequently in both cases (1.5%) and controls (0.3%).

Bacterial isolates were identified in 54% of cases, compared with 34% of controls ($P < 0.001$; Table 3). Coagulase negative

TABLE 2. Demographic and Clinical Characteristics of the Study Participants and Age-Adjusted Associations with Scarring

Parameter	Cases (n = 360)		Controls (n = 360)		Age-Adjusted Association with Scarring		
	n	(%)	n	(%)	OR	95% CI	P
Age groups, y							<0.001
18-25	29	(8.1)	117	(32.5)	1		
25-35	53	(14.7)	113	(31.4)	1.88	1.11-3.16	
35-45	65	(18.1)	85	(23.6)	3.13	1.87-5.26	
45-55	80	(22.2)	28	(7.8)	11.53	6.38-20.84	
55-65	57	(15.8)	9	(2.5)	28.75	12.36-66.87	
>65	76	(21.1)	8	(2.2)	34.07	15.28-75.95	
Age in years, mean (95% CI)	50.2	(48.3-2.0)	31.9	(30.7-3.1)	Trend 2.19*	(1.92-2.49)	<0.001
Sex							0.40
Female	219	(60.8)	241	(66.9)	1.00	—	
Male	141	(39.2)	119	(33.1)	1.17	0.81-1.68	
Formal education†							<0.001
None	250	(69.4)	166	(46.1)	1.00	—	
1-7 y	106	(29.4)	177	(49.2)	0.61	0.42-0.87	
>7 y	4	(1.1)	17	(4.7)	0.24	0.06-0.86	
BMI‡							0.55
Underweight	55	(15.4)	30	(8.5)	1.35	0.77-2.39	
Normal	257	(72.0)	284	(80.0)	1.00	—	
Overweight/obese	45	(12.6)	41	(11.6)	1.12	0.66-1.89	
Scarring grade§							
0	—	—	360	(100)			
1a	0	(0.0)	—	—			
1b	187	(51.9)	—	—			
1c	127	(35.3)	—	—			
2	33	(9.2)	—	—			
3	13	(3.6)	—	—			
Papillary inflammation grade							
P0	80	(22.2)	343	(95.3)			
P1	188	(52.2)	17	(4.7)			
P2	84	(23.3)	0	(0.0)			
P3	8	(2.2)	0	(0.0)			
Follicles							
F0	355	(98.6)	359	(99.7)			
F1	2	(0.6)	1	(0.3)			
F2	1	(0.3)	0	(0.0)			
F3	2	(0.6)	0	(0.0)			

* The result shown is the increase in the OR with each increase in age group category.

† Primary schooling in Tanzania is completed after 7 years.

‡ Categories from the National Institutes of Health.

§ All controls had no scarring (grade 0), and all cases had scarring grade 1b or higher.

staphylococci (CNS), *Corynebacterium* spp., *Streptococcus viridans*, and *Bacillus* spp. were designated as commensal organisms for the purposes of this analysis. Both pathogenic and commensal organisms were more prevalent in cases versus controls (pathogenic: 6.7% vs. 1.9%; OR, 4.90; 95% CI, 2.06-11.65; $P < 0.001$; commensal: 47.4% vs. 32.6%; OR, 2.09; 95% CI, 1.54-2.84; $P < 0.001$). There was an increasing prevalence of bacterial isolates (both commensal and pathogenic), with increasing severity of scarring ($P_{\text{trend}} < 0.001$, Table 4).

To assess the association between papillary inflammation and bacterial isolates among those with scarring, the cases were subdivided into either inflamed (P2 or P3) or noninflamed (P0 or P1). There were 92 (25.6%) inflamed cases and 268 (74.4%) noninflamed cases. A bacterial isolate (commensal or pathogenic) was cultured in 60 (65.2%) of the inflamed cases compared with 135 (50.4%) of the noninflamed cases (OR, 1.86; 95% CI, 1.14-3.04; $P = 0.01$). Commensal organisms were not significantly associated with inflammation, being found in 45 (48.9%) of the inflamed cases and 126 (47.0%) of the noninflamed ones (OR, 1.48; 95% CI, 0.89-2.48; $P = 0.13$). There was no evidence that individual commensal organisms were associated with inflammation. The presence of pathogenic organisms, however, was strongly associated with inflammation. They were detected in 15 (16.3%) of 92 of in-

flamed cases and 9 (3.4%) of 268 of the noninflamed (OR, 6.93; 95% CI, 2.79-17.24; $P < 0.001$).

Multivariable analyses showed that trachomatous scarring was independently associated with increasing age and lack of education (Table 5). Scarring was also associated with the presence of commensal organisms (adjusted OR, 1.47; 95% CI, 1.03-2.12) and was strongly associated with pathogenic organisms (adjusted OR, 4.08; 95% CI, 1.60-10.43).

DISCUSSION

This study showed, for the first time, that trachomatous scarring without trichiasis is strongly associated with non-chlamydial bacterial infection in cases compared with controls. Chlamydial infection itself is only rarely found in adults with scarring, and repeated infectious episodes with other bacteria may contribute to progressive scarring.

Several studies from The Gambia have examined the role of bacterial infection and inflammation in cicatricial trachoma, although most of these have been in patients with trichiasis. Bacterial infection was found before surgery in 30% of patients undergoing trichiasis surgery. Recurrent trichiasis at 12 months was associated with conjunctival inflammation and bacterial

TABLE 3. Bacterial Culture Results by Case-Control Status

	Cases (n = 360)		Controls (n = 360)		χ^2 test
	n	(%)	n	(%)	
Any isolate cultured	195	(54.2)	124	(34.4)	<0.001
Number of organisms cultured					
0	165	(45.8)	236	(65.6)	—
1	125	(34.7)	96	(26.7)	<0.001
2	66	(18.3)	24	(6.7)	<0.001
3	4	(1.1)	4	(1.1)	0.62
Type of isolate cultured*					
None	165	(45.8)	236	(65.6)	—
Commensal only	171	(47.5)	117	(32.5)	<0.001
Pathogenic +/- commensal	24	(6.7)	7	(1.9)	<0.001
Organisms					
CNS	110	(30.6)	69	(19.2)	<0.001
<i>Corynebacterium</i> spp.	89	(24.7)	42	(11.7)	<0.001
<i>Viridans</i> group streptococci	35	(9.7)	32	(8.9)	0.70
<i>Bacillus</i> spp.	8	(2.2)	8	(2.2)	1.0
<i>Haemophilus influenzae</i> , B	9	(2.5)	0	(0.0)	0.003
<i>Streptococcus pneumoniae</i>	7	(1.9)	1	(0.3)	0.03
<i>Escherichia coli</i>	3	(0.8)	0	(0.0)	0.08
<i>Neisseria</i> spp.	3	(0.8)	0	(0.0)	0.08
<i>Staphylococcus aureus</i>	2	(0.6)	0	(0.0)	0.16
<i>Aeromonas hydrophila</i>	0	(0.0)	2	(0.6)	0.16
Fungus, mould	0	(0.0)	2	(0.6)	0.16
Gram negative rods (other)	1	(0.3)	1	(0.3)	1.0
<i>Actinomyces</i>	1	(0.3)	0	(0.0)	0.32
<i>Enterobacter cloacae</i>	1	(0.3)	0	(0.0)	0.32
Gram-negative rods, non-Lactose fermenting	1	(0.3)	0	(0.0)	0.32
<i>Klebsiella</i> spp.	0	(0.0)	1	(0.3)	0.32

* Commensal organisms include CNS, *Corynebacterium* spp., and *Viridans* group streptococci.

infection at 12 months.⁸ Postoperative bacterial infection and conjunctival inflammation were also associated with recurrent trichiasis in another study in which examined patients were examined 3.5 years after surgery.^{8,15} Bacterial infection and inflammation were found to be associated with major trichiasis (five or more lashes touching the globe) in a cohort study of Gambian patients with trichiasis who declined surgery; however, neither was significantly associated with progression in trichiasis after adjustment for other factors.¹³ Finally, the first of two related case-control studies found that patients with trichiasis had an increased bacterial infection rate compared with controls and that infection was more common with increasing trichiasis severity.¹⁰ In the second case-control study, while there was an increased infection rate in those with trachomatous scarring without trichiasis, this did not reach statistical significance (OR, 2.2; 95% CI 0.79–6.33; $P = 0.144$), probably because of a limited sample size. The current study, which has greater power, showed that scarring is associated with bacterial infection. Several clinical trials have investigated the effect of single-dose oral azithromycin after trichiasis sur-

gery on TT recurrence. These have reported variable impact on the subsequent recurrence rate. It is plausible that at least part of the benefit of this intervention is attributable to the effect of this antibiotic on Gram-positive infection rather than on chlamydial infection alone.^{8,17,18}

The results of studies on patients with trichiasis cannot necessarily be extrapolated to those with scarring alone, as the two groups are notably different. Trichiasis denotes lashes rubbing against the globe, causing mechanical damage and a persistent foreign body on the ocular surface. This effect provides a nidus for infection that may itself lead to an increased risk of infection and inflammation rather than the other way around. In this study we found that scarring without trichiasis is also associated with bacterial infection and inflammation. While cause and effect cannot be established with this study, we are currently observing a cohort of scarred subjects who are being assessed at regular intervals for infection and scarring progression.

Earlier studies have also examined bacterial culture rates in active trachoma, especially in relation to seasonal epidemics of

TABLE 4. Bacterial Culture Rates by Scarring Grade

	Conjunctival Scarring Grade										Test for Trend P
	0 (n = 360)		1b (n = 187)		1c (n = 127)		2 (n = 33)		3 (n = 13)		
	n	(%)	n	(%)	n	(%)	n	(%)	n	(%)	
Any isolate cultured	124	(34.4)	84	(44.9)	78	(61.4)	23	(69.7)	10	(76.9)	<0.001
Type of isolate cultured											
None	236	(65.6)	103	(55.1)	49	(38.6)	10	(30.3)	3	(23.1)	
Commensal only	117	(32.5)	76	(40.6)	68	(53.5)	18	(54.6)	9	(69.2)	<0.001
Pathogenic +/- commensal	7	(1.9)	8	(4.3)	10	(7.9)	5	(15.2)	1	(7.7)	<0.001

TABLE 5. Multivariable Logistic Regression Model for Conjunctival Scarring

Risk Factor	OR	95% CI	P
Age group*	2.10	1.84-2.39	<0.001
Education			0.007
None	1.00	—	
≤7 years of education	0.61	0.43-0.88	
>7 years of education	0.29	0.08-1.07	
Type of bacterial organism cultured			0.002
None	1.00	—	
Commensal only	1.47	1.02-2.12	
Pathogenic +/- commensal	4.08	1.60-10.43	

* The result shows the increase in the OR with increasing age group category.

bacterial conjunctivitis.¹⁹⁻²⁵ However, most of these studies were in children without cicatricial stages of trachoma, did not contain control groups, and used older trachoma grading systems that are difficult to compare with those currently used. The two studies that did compare groups with and without trachoma showed little difference in the bacterial isolation rates between the two groups; however, these findings relate only to children with active disease.^{24,25}

Monkey models of trachoma have also sought to elucidate the relationship between trachoma and bacterial infection. These have shown that bacterial co-infection in active disease did not result in more severe disease.²⁶ However, when bacteria were introduced into eyes with conjunctival scarring, a more marked and prolonged inflammatory reaction was produced compared with control animals.²⁶

Another interesting question that our study raises is the role and definition of commensal organisms. Such organisms can act as part of the defensive mechanism of the ocular surface by preventing colonization and infection by more pathogenic bacteria.²⁷ However, deciding which organisms to categorize as a commensal can be a moot point. Previous studies have gone some way toward identifying organisms commonly found on the ocular surface of healthy eyes which generally behave in a non-pathogenic manner. These include CNS and *Corynebacteria*.²⁸⁻³² However, findings depend on various factors. Polymerase chain reaction with DNA sequencing, for example, detects a much broader range and higher frequency of organisms than does conventional bacterial culture.³¹ The population being sampled is important, as many studies performed so far have been on subjects from developed areas. A recent survey from Sierra Leone of healthy eyes found a much higher proportion of isolates of bacteria usually thought of as pathogenic than previous studies, as well as fungi, the significance of which remains unknown.³²

We found that one third of our control subjects had an organism cultured. This is on the lower end of the range compared with results of previous studies on the conjunctival flora, which showed culture rates of between 34% and 100%.²⁸⁻³² This discrepancy may be partly because our study was conducted in a remote, rural community and there was a short delay in getting the samples to the laboratory. However, the sample handling was identical between cases and controls, and we do not believe that any systematic bias resulted. We considered any increase in detection rates that may be achieved with plating the swabs directly onto culture media in the field would have been outweighed by higher contamination rates.

We included *Streptococcus viridans* and *Bacillus* as commensal organisms as well as CNS and *Corynebacteria*. *S. viridans* is a common oral commensal which is also frequently found in the ocular flora in trachoma endemic areas and does

not appear to act in a pathogenic manner.^{20,23,24} Poor dental hygiene in these areas may facilitate spread of the organism from the oral cavity to the eye, which are joined by a continuous mucosal surface. *Bacillus* was also included as a commensal organism, as a number of factors indicated that it was acting in a nonpathogenic manner. It was found equally in cases and controls; on all the occasions on which it was cultured, there was only mild growth and there was usually co-culture with other organisms; and it did not cause any clinically significant inflammation.

In our study, pathogens were significantly associated with inflammation while commensals (both individually and overall) were not. This result suggests that the scarred surface is more easily colonized by commensal organisms with little adverse effect, although a subclinical effect cannot be ruled out. The scarred surface also appears to be more prone to infection with pathogens that do cause inflammation and, perhaps, scarring progression.

Our study benefited from a prospective approach with standard clinical grading. There was minimal delay between taking the swabs and inoculating samples onto the culture medium. We also identified and adjusted for potential confounding factors. A potential confounder was the difference in age between cases and controls; however, bacterial infection remained significantly associated with scarring even after adjustment for age in a logistic regression model. Limitations of the study include not having a specific culture for fungi, which may have led to underestimation of their role. This study was conducted in an area mesoendemic for trachoma, and the level of scarring in the cases reflected this, being relatively mild, with most of the cases having less than one third of the upper lid scarred. This study, therefore, is applicable to the many other areas with a moderate level of trachoma. We found that the infection rate tended to increase with the level of scarring, suggesting that more bacterial infection would be found in communities with more severe scarring.

Chlamydial infection data are not available for this group of subjects. However, in this setting, we would expect the prevalence of infection with *C. trachomatis* in adults to be low, previous studies having suggested it would probably be between 0% and 10%.⁸⁻¹³

In summary, trachomatous conjunctival scarring is associated with increased bacterial infection, the role of which warrants further investigation, especially with regard to scarring progression and the risk of blindness.

Acknowledgments

The authors thank Christopher Odhiambo Onguny for help with the laboratory work.

References

- Resnikoff S, Pascolini D, Etya'ale D, et al. Global data on visual impairment in the year 2002. *Bull World Health Organ*. 2004; 82(11):844-851.
- Mariotti SP, Pascolini D, Rose-Nussbaumer J. Trachoma: global magnitude of a preventable cause of blindness. *Br J Ophthalmol*. 2009;93(5):563-568.
- Dawson CR, Jones BR, Tarizzo ML. *Guide to Trachoma Control*. Geneva: World Health Organization; 1981.
- Thylefors B, Negrel AD, Pararajasegaram R. Epidemiological surveillance of trachoma: evaluation and perspective (in French). *Rev Int Trach Pathol Ocul Trop Subtrop Sante Publique*. 1992;69: 107-114.
- Organization WH. *Report of the 2nd Global Scientific Meeting on Trachoma*. Geneva: World Health Organization; 2003.
- West SK, Munoz B, Mkocha H, Hsieh YH, Lynch MC. Progression of active trachoma to scarring in a cohort of Tanzanian children. *Ophthalmic Epidemiol*. 2001;8:137-144.

7. Wolle MA, Munoz BE, Mkocho H, West SK. Constant ocular infection with Chlamydia trachomatis predicts risk of scarring in children in Tanzania. *Ophthalmology*. 2009;116:243-247.
8. Burton MJ, Kinteh F, Jallow O, et al. A randomised controlled trial of azithromycin following surgery for trachomatous trichiasis in the Gambia. *Br J Ophthalmol*. 2005;89(10):1282-1288.
9. Solomon AW, Holland MJ, Burton MJ, et al. Strategies for control of trachoma: observational study with quantitative PCR. *Lancet*. 2003;362(9379):198-204.
10. Burton MJ, Adegbola RA, Kinteh F, et al. Bacterial infection and trachoma in The Gambia: a case control study. *Invest Ophthalmol Vis Sci*. 2007;48(10):4440-4444.
11. West ES, Mkocho H, Munoz B, et al. Risk factors for postsurgical trichiasis recurrence in a trachoma-endemic area. *Invest Ophthalmol Vis Sci*. 2005;46(2):447-453.
12. Munoz B, Bobo L, Mkocho H, Lynch M, Hsieh YH, West S. Incidence of trichiasis in a cohort of women with and without scarring. *Int J Epidemiol*. 1999;28(6):1167-1171.
13. Burton MJ, Bowman RJ, Faal H, et al. The long-term natural history of trachomatous trichiasis in the Gambia. *Invest Ophthalmol Vis Sci*. 2006;47(3):847-852.
14. Bowman RJ, Faal H, Myatt M, et al. Longitudinal study of trachomatous trichiasis in the Gambia. *Br J Ophthalmol*. 2002;86(3):339-343.
15. Burton MJ, Bowman RJ, Faal H, Aryee EA, Ikumapayi UN, Alexander ND, et al. Long term outcome of trichiasis surgery in the Gambia. *Br J Ophthalmol*. 2005;89(5):575-579.
16. Burton MJ, Bailey RL, Jeffries D, et al. Conjunctival expression of matrix metalloproteinase and proinflammatory cytokine genes after trichiasis surgery. *Invest Ophthalmol Vis Sci*. 2010;51:3583-3590.
17. West SK, West ES, Alemayehu W, et al. Single-dose azithromycin prevents trichiasis recurrence following surgery: randomized trial in Ethiopia. *Arch Ophthalmol*. 2006;124(3):309-314.
18. Zhang H, Kandel RP, Atakari HK, Dean D. Impact of oral azithromycin on recurrence of trachomatous trichiasis in Nepal over 1 year. *Br J Ophthalmol*. 2006;90(8):943-948.
19. Reinhardt J, Weber A, Nizetic B, Kupka K, Maxwell-Lyons F. Studies in the epidemiology and control of seasonal conjunctivitis and trachoma in southern Morocco. *Bull World Health Organ*. 1968;39(4):497-545.
20. Vastine DW, Dawson CR, Daghfous T, Yoneda C, et al. Severe endemic trachoma in Tunisia, I: effect of topical chemotherapy on conjunctivitis and ocular bacteria. *Br J Ophthalmol*. 1974;58(10):833-842.
21. Nabli B. Bacteriology of the trachomatous eye (in French). *Rev Int Trach*. 1974;51(4):93-102.
22. Aouchiche M, Bonnardot R, Chibane S, et al. Trachoma and associated flora: theoretical study and practical deductions in trachoma control in Algeria—new health survey in the region of Guerrara (in French). *Rev Int Trach*. 1969;46(2):157-167.
23. Nema HV, Bal A, Nath K, Shukla BR. Bacterial flora of the trachomatous conjunctiva. *Br J Ophthalmol*. 1964;48:690-691.
24. Wood TR, Dawson CR. Bacteriologic studies of a trachomatous population. *Am J Ophthalmol*. 1967;63(5 suppl):1298-1301.
25. Woolridge RL, Gillmore JD. Bacteriological studies on trachomatous and normal persons from three areas in Taiwan: *Bull World Health Organ*. 1962;26:789-795.
26. Taylor HR, Kolarczyk RA, Johnson SL, Schachter J, Prendergast RA. Effect of bacterial secondary infection in an animal model of trachoma. *Infect Immun*. 1984;44(3):614-616.
27. Chandler JW, Gillette TE. Immunologic defense mechanisms of the ocular surface. *Ophthalmology*. 1983;90(6):585-591.
28. Gritz DC, Scott TJ, Sedo SF, Cevallos AV, Margolis TP, Whitcher JP. Ocular flora of patients with AIDS compared with those of HIV-negative patients. *Cornea*. 1997;16(4):400-405.
29. Martins EN, Alvarenga LS, Hoffling-Lima AL, et al. Aerobic bacterial conjunctival flora in diabetic patients. *Cornea*. 2004;23(2):136-142.
30. Iskeleli G, Bahar H, Eroglu E, Torun MM, Ozkan S. Microbial changes in conjunctival flora with 30-day continuous-wear silicone hydrogel contact lenses. *Eye Contact Lens*. 2005;31(3):124-126.
31. Graham JE, Moore JE, Jiru X, et al. Ocular pathogen or commensal: a PCR-based study of surface bacterial flora in normal and dry eyes. *Invest Ophthalmol Vis Sci*. 2007;48(12):5616-5623.
32. Capriotti JA, Pelletier JS, Shah M, Caivano DM, Ritterband DC. Normal ocular flora in healthy eyes from a rural population in Sierra Leone. *Int Ophthalmol*. 2009;29(2):81-84.

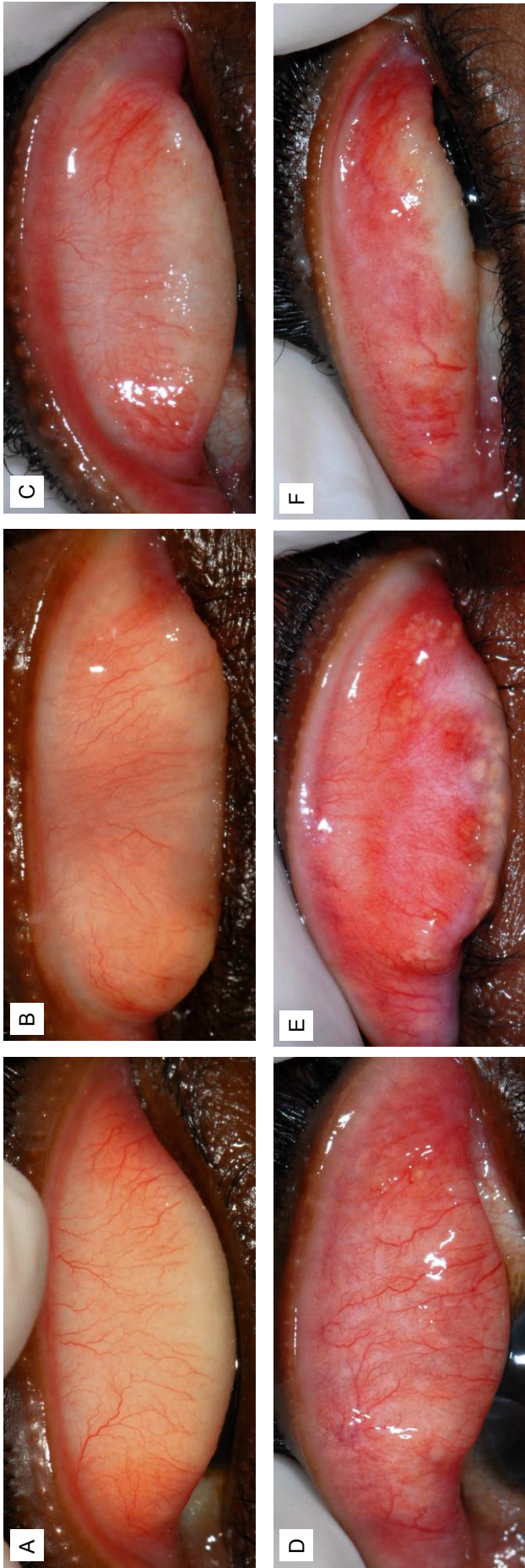


Figure 1. Clinical grading system for trachomatous conjunctival scarring. **A**, Normal. **B**, Grade S1a. **C**, Grade S1b. **D**, Grade S1c. **E**, Grade S2. **F**, Grade S3.

Chapter 12

**Innate immune responses and modified
extra-cellular matrix regulation
characterize bacterial infection and
cellular/connective tissue changes in
scarring trachoma**



**Research paper analysing gene expression changes in
relation to trachomatous scarring, infection status and *in vivo*
confocal microscopy changes**

Cover sheet for each ‘research/review paper’ included in a research thesis

1. For a ‘research/review paper’ already published

1.1. Where was the work published? ***Infection & Immunity***

1.2. When was the work published? ***November 2011 (Epub ahead of print)***

1.3. Was the work subject to academic peer review? ***Yes***

1.4. Have you retained the copyright for the work? ***Yes***

If no, or if the work is being included in its published format, attach evidence of permission from copyright holder (publisher or other author) to include work

See Appendix 7f

2. For multi-authored work, give full details of your role in the research included in the paper and in the preparation of the paper. (Attach a further sheet if necessary)

I conducted the field work for this study including performing the clinical examination and in vivo confocal microscopy examination and taking the swab samples. I performed the quantitative polymerase chain reaction (qPCR) with guidance from Matthew Burton and assistance from Athumani Ramadhani and Sonda Tolbert. The Amplicor testing was performed by Athumani Ramadhani. I performed the delta delta Ct qPCR analysis and graded the confocal images. I performed the overall analysis with guidance from Helen Weiss. I wrote the paper with consideration of comments from co-authors.

Candidate’s signature.....

A handwritten signature in black ink, appearing to read 'M. Burton', is written on a light-colored rectangular background.

Supervisor or senior author’s signature to confirm role as stated in (2).....

Title Page

Title:

Innate immune responses and modified extra-cellular matrix regulation characterize bacterial infection and cellular/connective tissue changes in scarring trachoma

Running title:

Immuno-fibrogenic correlates of trachomatous scarring

Authors and affiliations:

Victor H. Hu^{1,2*}, Helen A. Weiss³, Athumani M. Ramadhani⁴, Sonda B. Tolbert⁴, Patrick Massae², David C. W. Mabey¹, Martin J. Holland¹, Robin L. Bailey¹ and Matthew J. Burton^{1,2}

¹ Department of Clinical Research, Faculty of Infectious and Tropical Diseases, London School of Hygiene and Tropical Medicine, UK

² Kilimanjaro Centre for Community Ophthalmology, Moshi, Tanzania

³ Department of Infectious Disease Epidemiology, Faculty of Epidemiology and Population Health, London School of Hygiene and Tropical Medicine, London, UK

⁴ Biotechnology Laboratory, Kilimanjaro Christian Medical Centre, Moshi, Tanzania

Corresponding author details:

Victor H. Hu
International Centre for Eye Health,
London School of Hygiene and Tropical Medicine,
Keppel Street,
London, WC1E 7HT, UK
Telephone number: 07970 939445
Email: victor.hu@lshtm.ac.uk

Supplemental files:

Figure S1.

Financial support:

This study was funded by a fellowship grant to MJB from the Wellcome Trust (080741/Z/06/Z). VHH is supported by a fellowship grant from the British Council for the Prevention of Blindness (Barrie Jones Fellowship). The funders had no part in the study

design; in the collection, analysis, and interpretation of data; in the writing of the report; and in the decision to submit the paper for publication.

Conflict of interest:

No authors have any financial/conflicting interests to disclose.

Word count: 3380

Key words:

Trachoma; conjunctiva; *Chlamydia trachomatis*; scarring; gene expression; *in vivo* confocal microscopy; quantitative multiplex PCR; microbiology

Abstract

Trachoma is the most common infectious cause of blindness and a major public health problem in many developing countries. It is caused by recurrent ocular infection with *Chlamydia trachomatis* in childhood, with conjunctival scarring seen later in life. The pathogenesis of trachomatous scarring, however, is poorly understood and this study was carried out to investigate the immuno-fibrogenic correlates of trachomatous conjunctival scarring. A case-control study of 363 cases with conjunctival scarring and 363 control participants was conducted. Investigations included *in vivo* confocal microscopy (IVCM) assessment, quantitative real-time PCR gene expression, *C. trachomatis* detection and non-chlamydial bacterial culture. Trachomatous scarring was found to be strongly associated with a pro-inflammatory, innate immune response with increased expression of: psoriasin; interleukin-1 β ; tumour necrosis factor- α ; defensin- β 4A; chemokine (CXC) ligand 5; and serum amyloid A1. There was also differential expression of various modifiers of the extracellular matrix including: metalloproteinases 7, 9, 10 and 12; tissue inhibitor of matrix metalloproteinase 1; and secreted protein acidic cystein-rich-like 1. The expression of many of these genes was also significantly associated with the presence of non-chlamydial bacterial infection. These infections had a marked effect on conjunctival immune processes including an increased inflammatory infiltrate and edema seen with IVCM. This study supports the possibility that the immuno-fibrogenic response in scarring trachoma is partly stimulated by non-chlamydial bacterial infection which is characterised by the expression of innate factors.

Trachoma is a major cause of blindness, especially in developing countries. Children suffer recurrent episodes of ocular infection with *Chlamydia trachomatis* which stimulate a follicular and papillary conjunctivitis. These children are subsequently at risk of developing conjunctival scarring which can progress to entropion (in-turning of the eyelid) and trichiasis (eyelashes rubbing against the eyeball). Corneal opacity and blindness can result, as well as severe and persistent discomfort. Trachoma is the most common infectious cause of blindness, with at least 1.3 million people estimated to be blind from the disease, 8.2 million to have trichiasis and 40 million to have active disease. (40, 52)

The pathogenesis of trachoma, and especially of the scarring process, is poorly understood. Histological studies of conjunctival biopsies from scarred individuals show a chronic inflammatory cell infiltrate, especially in the substantia propria, with large numbers of lymphocytes. (1, 4, 25, 51) T cells, both CD4+ and CD8+, tend to outnumber B cells. The conjunctival stroma is replaced by thick, mostly avascular scar tissue. Earlier studies examining lymphoproliferative responses to chlamydial antigens in trachomatous subjects were consistent with findings from animal models of infection, which suggested that a strong Th1 response with production of IFN γ was important in clearing chlamydial infection and may be protective against the development of scarring. (5, 27, 28) These studies also provided limited evidence that Th2 responses were associated with conjunctival fibrosis, which may have parallels with other infectious disease, such as schistosomiasis. (59) However, recent studies using microarray analysis of conjunctival swab samples from subjects with trachomatous trichiasis have not found evidence of Th1/Th2 polarisation. Instead, pro-inflammatory mediators, particularly suggestive of innate immune responses and factors affecting extra-cellular matrix (ECM) remodelling, were prominent. (14, 29) A number of studies have also provided compelling evidence supporting the importance of conjunctival inflammation in the development of scarring and blinding complications. (11, 18, 43, 55, 57)

Two models have been proposed to account for the pathogenesis of *C. trachomatis* induced scarring in the eye or genital tract: the “immunological” and the “cellular” paradigms, which are not necessarily mutually exclusive.(7, 16, 53) The immunological paradigm argues that cellular immune responses, especially those involving T-cells, against specific chlamydial antigens are important in causing disease. The cellular paradigm proposes that host epithelial cells act as a key innate responder cell and are central in driving tissue damage.

In this case-control study we investigated the pathophysiology of trachomatous conjunctival scarring by measuring conjunctival gene expression. We examined the hypotheses that conjunctival scarring is associated with: (1) a predominantly Th2 (IL-13 mediated) rather than Th1 response, (2) various pro-fibrotic mediators such as matrix metalloproteinases, and (3) markers of innate immunity. In addition, we investigate the relationship between the expression of these various factors and both *C. trachomatis* and other bacterial infections. Finally, we relate the gene expression profile to the microscopic tissue morphology changes and inflammatory cell infiltrate observed by *in vivo* confocal microscopy (IVCM). IVCM is a relatively new technique to examine the ocular surface, which provides high-resolution images down to the cellular level.(31, 32)

MATERIAL AND METHODS

Ethical approval

This study adhered to the tenets of the Declaration of Helsinki. It was approved by the ethics committees of the Tanzanian National Institute for Medical Research, the Kilimanjaro Christian Medical Centre and the London School of Hygiene and Tropical Medicine. The study was explained to potential study subjects and written, informed consent was obtained before enrolment.

Participant recruitment

The recruitment of participants into this population-based study has been previously described.(30, 32) Briefly, adults with trachomatous conjunctival scarring, but without trichiasis, were recruited from a trachoma endemic area in Siha district of northern Tanzania. Control subjects without scarring from the same community, frequency matched for ethnicity, were also recruited.

Clinical examination and sample collection

All participants were examined clinically, as previously described, using the 1981 World Health Organization trachoma grading system with some modifications including a more detailed grading for conjunctival scarring.(17, 30, 32) The left conjunctiva was anaesthetised with preservative-free proxymetacaine 0.5% eye drops (Minims®, Chauvin Pharmaceuticals) and a swab collected for microbiological analysis from the inferior fornix. Two upper tarsal conjunctival swabs were also collected (Dacron polyester-tipped, Hardwood Products Company, Guildford, ME). The first was for RNA isolation (described later) and was placed directly into a tube containing 0.2 ml RNA stabilizer (RNA^{later}, Life technologies, UK). The second was for *C. trachomatis* detection and put into a dry tube. Samples were kept on ice packs until frozen later the same day at -80°C.

Confocal microscopy assessment

IVCM examination of the upper tarsal conjunctiva was performed using the Heidelberg Retina Tomograph 3 (HRT3) in combination with the Rostock Corneal Module (RCM) (Heidelberg Engineering GmbH, Dossenheim, Germany) using previously described examination and image grading protocols.(31) IVCM images were graded for inflammatory features sub-epithelial connective tissue organisation/scarring (Figures 1 and 2).

Quantitative RT-PCR

Twenty-three different gene transcripts were selected for quantitation by real time RT-PCR including interferon gamma (*IFNG*); indoleamine-2,3-dioxygenase (*INDO*); tumour necrosis factor, alpha (*TNF α*); interleukin 1, beta (*IL1B*); interleukin 10 (*IL10*); interleukin 12, beta (*IL12B*); interleukin 13 (*IL13*); interleukin 13 receptor, alpha 2 (*IL13RA2*); S100 calcium binding protein A7 (*S100A7*); defensin, beta 4A (*DEFB4A*); chemokine (C-X-C motif) ligand 5 (*CXCL5*); serum amyloid A1 (*SAA1*); arginase, liver (*ARG1*); nitric oxide synthase 2, inducible (*NOS2*); matrix metalloproteinase 1 (*MMP1*); matrix metalloproteinase 7 (*MMP7*); matrix metalloproteinase 9 (*MMP9*); matrix metalloproteinase 10 (*MMP10*); matrix metalloproteinase 12 (*MMP12*); TIMP (tissue inhibitor of matrix metalloproteinase) matrix metalloproteinase inhibitor 1 (*TIMP1*); SPARC (secreted protein, acidic, cystein-rich)-like 1 (hevin) (*SPARCL1*); complement factor H (*CFH*); and CD83 molecule (*CD83*).

Genes were chosen to investigate the specific hypotheses outlined above. Specifically, *IFNG*, *IL12B*, *IL13* and *IL13RA2* expression to investigate a Th1/Th2 predominance; the expression of matrix metalloproteinases, *TIMP1* and *SPARCL1* as potentially important regulators of extra-cellular matrix; and *IL1B*, *TNFA*, *S100A7*, *DEFB4A*, *CXCL5* and *SAA1* expression as evidence of a pro-inflammatory and/or innate immune response. We were also interested in examining evidence of differential macrophage activity (*ARG1* and *NOS2*), mature dendritic cells (*CD83*) and complement regulation (*CFH*). The selection of these genes was informed by previous studies including a conjunctival microarray transcriptome analysis.(6, 9, 14, 15, 22, 27, 28, 42, 45, 47-49) The microarray data have been deposited in NCBI's Gene Expression Omnibus under accession numbers GSE23705 (Ethiopia) and GSE24383 (Tanzania).

Total RNA was extracted from the swab sample using RNeasy Micro Kit (Qiagen, Hilden, Germany) and reverse transcribed to cDNA using the QuantiTect Reverse Transcription Kit (Qiagen) according to the manufacturer's instructions. Multiplex real-time quantitative PCR

was performed on a Rotor-Gene 6000 (Corbett Research, Cambridge, UK) using the QuantiTect Multiplex NoROX Kit (Qiagen) according to the manufacturer's instructions. Probes and primers for multiplex assays, which included up to four separate targets (including HPRT-1, which was used as a reference gene), were designed and synthesised by Sigma Life Science (www.sigma.com/designmyprobe, available on request). The samples were tested in duplicate, in a total reaction volume of 25 μ l, which contained 2 μ l of sample or standard. The thermal cycle protocol used the following conditions: 95°C for 15 minutes, followed by 45 - 50 cycles of (1) denaturation at 94°C for 30 seconds, (2) annealing and extension at 60°C for 30 seconds. Fluorescence data was acquired at the end of each cycle. The relative efficiency of the component reactions was assessed using standards containing all targets in a sequence of tenfold serial dilutions.

Microbiology samples and analysis

C. trachomatis DNA was detected using a PCR-based assay (Amplicor CT/NG Test; Roche) with previously described modifications.(12) Samples for culture were inoculated onto blood and chocolate agar later on the day of collection (rarely more than 6 hours) and incubated at 37°C for 48 hours. Culture isolates were identified by standard microbiological techniques.

Data analysis

Data were entered into Access 2007 (Microsoft) and analysed using STATA 11.0 (StataCorp LP, TX). The transcript abundances for the genes of interest were standardised relative to that of *HPRT1* in the same reaction using the $\Delta\Delta C_T$ method and were normalised by log₁₀ transformation.(37) Linear regression models were used to estimate fold changes (age and sex adjusted) in the level of gene expression in those with clinically visible scarring compared to controls, subdivided into those with no/minimal inflammation - TS (inflammation grades P0 and P1); and those with inflammation - TSI (inflammation grades P2 and P3), where P0=no inflammation; P1=minimal inflammation with individual papillae prominent; P2=moderate inflammation in which normal vessels appear hazy; P3=pronounced

inflammation in which normal vessels on the tarsus are hidden over more than half the surface).(17) Similar fold changes were estimated for the presence of clinically significant inflammation (P2 or P3), adjusted for the level of clinical scarring as well as age and sex. Age and sex adjusted fold changes in gene expression by grade of IVCM connective tissue organization/scarring, and for the presence of dendritiform cells were also estimated. Correlation coefficients were estimated between the increase in gene expression (\log_{10} transformed) and the IVCM inflammatory infiltrate, with the significance tested using age/sex adjusted linear regression models. Likelihood ratio tests were used to assess the strength of association of each factor with gene expression fold change. P-values for all associations are shown in the results section. For reference, the P-values for the critical significance thresholds determined by a Bonferroni correction for multiple comparisons are shown in table footnotes. However, the choice of targets for gene expression were not selected at random, as is assumed by the Bonferroni method, but contain related groups of genes which might be expected to act in a similar manner. In addition, using such a conservative correction increases the likelihood of a Type 2 error.

RESULTS

Study participants

We recruited 363 cases with trachomatous conjunctival scarring and 363 control participants without scarring. The demographic, clinical, IVCM and non-chlamydial bacterial infection data have previously been reported in detail.(30, 32) In summary, controls were younger than the cases (mean 31.9 vs 50.3 years, $p < 0.001$) and all analyses were age and sex adjusted. Conjunctival scarring in the cases was mostly mild to moderate and cases had significantly more clinical inflammation than controls. IVCM analysis showed that cases had more inflammatory cells and a higher connective tissue scarring score. Non-chlamydial pathogenic organisms were cultured more frequently from cases (25 [6.9%]) than controls (7 [1.9%], p -value 0.002). The most frequently cultured pathogenic organisms were

Haemphilus influenzae type b and *Streptococcus pneumoniae* while Coagulase negative staphylococci, *Corynebacterium spp.*, *Streptococcus viridans* and *Bacillus spp.* were designated as commensal organisms in this analysis. Five (1.4%) of the cases and none of the controls had *C. trachomatis* infection detected.

Conjunctival gene expression

Quantitative, real-time RT-PCR was performed for 23 gene expression targets for all 363 cases and 363 controls. There was inadequate sample for detection in 4 samples (3 cases and 1 control) and amplification failed in a number of experiments for technical reasons related to laboratory power supply problems. The number of samples successfully detected for each target ranged from 313 to 359 for cases and 316 to 362 for controls.

Gene expression levels in relation to clinical findings

Cases with scarring had enriched gene expression compared to controls for the majority of transcripts measured, even after adjusting for age and sex (Table 1). This tended to be more marked in those cases with inflammation (increased: *INDO*, *TNFA*, *IL1B*, *S100A7*, *DEFB4A*, *CXCL5*, *SAA1*, *ARG*, *NOS2*, *MMP7*, *MMP9*, *MMP12*, *TIMP1* and *CD83*; decreased: *MMP10*, *CFH* and *SPARCL1*). There was also some evidence, but with less robust P-values, that the expression of *INFG* and *IL13RA2* were increased in cases with scarring.

After adjusting for age, sex and the level of clinical scarring a number of genes were also differentially expressed in those with clinical inflammation compared to those without inflammation (increased: *INDO*, *IL1B*, *DEFB4A*, *CXCL5*, *MMP7*, *MMP9*, *MMP12* and *CD83*; decreased: *MMP10*, *SPARCL1* and *CFH*).

TABLE 1. Conjunctival gene expression in relation to clinical phenotype.

Gene	TSI vs C ^a		TS vs C ^a		Inflamed vs non-inflamed ^b	
	FC	p ^c	FC	p ^c	FC	p ^c
<i>S100A7</i>	5.54	<0.0001	3.2	<0.0001	1.3	0.11
<i>SAA1</i>	4.99	<0.0001	2.11	<0.0001	1.6	0.04
<i>DEFB4A</i>	4.72	<0.0001	1.42	0.01	2.46	<0.0001
<i>CXCL5</i>	3.89	<0.0001	1.18	0.43	3.4	<0.0001
<i>MMP12</i>	3.55	<0.0001	1.74	<0.0001	1.62	0.0002
<i>INDO</i>	3.29	<0.0001	1.5	<0.0001	1.96	<0.0001
<i>MMP9</i>	3.06	<0.0001	1.76	<0.0001	1.67	<0.0001
<i>IL1B</i>	2.57	<0.0001	1.59	<0.0001	1.48	0.0003
<i>NOS2</i>	2.16	<0.0001	1.27	0.005	1.38	0.007
<i>MMP7</i>	2.14	<0.0001	1.23	0.003	1.51	<0.0001
<i>CD83</i>	1.9	<0.0001	1.4	<0.0001	1.31	0.0004
<i>IL13RA2</i>	1.62	0.006	1.38	0.008	1.08	0.65
<i>IL12B</i>	1.52	0.02	1.29	0.04	1.22	0.23
<i>TNFA</i>	1.47	<0.0001	1.14	0.008	1.23	0.003
<i>IL10</i>	1.46	0.2	0.64	0.03	1.27	0.42
<i>TIMP1</i>	1.46	<0.0001	1.4	<0.0001	0.93	0.3
<i>IFNG</i>	1.42	0.001	1.06	0.4	1.41	0.002
<i>ARG1</i>	1.3	0.01	1.25	0.0003	1.04	0.64
<i>IL13</i>	1.22	0.3	1.17	0.19	1.09	0.64
<i>CFH</i>	0.75	<0.0001	1.13	0.005	0.68	<0.0001
<i>MMP1</i>	0.58	0.009	1.28	0.05	0.63	0.02
<i>MMP10</i>	0.38	<0.0001	0.86	0.02	0.54	<0.0001
<i>SPARCL1</i>	0.06	<0.0001	0.51	<0.0001	0.19	<0.0001

^a Adjusted for age and sex

^b Adjusted for age, sex and level of clinical scarring

^c Using a Bonferroni correction for 69 comparisons then a P-value of <0.0007 would be considered significant, see text for discussion.

TSI = trachomatous scarring with inflammation; TS = trachomatous scarring without inflammation; FC = fold change; *S100A7* = S100 calcium binding protein A7; *SAA1* = serum amyloid A1; *DEFB4A* = defensin, beta 4A; *CXCL5* = chemokine (C-X-C motif) ligand 5; *MMP12* = matrix metalloproteinase 12; *INDO* = indoleamine-2,3-dioxygenase; *MMP9* =

matrix metalloproteinase 9; *IL1B* = interleukin 1; *NOS2* = nitric oxide synthase 2, inducible; *MMP7* = matrix metalloproteinase 7; *CD83* = CD83 molecule; *IL13RA2* = interleukin 13 receptor, alpha 2; *IL12B* = interleukin 12, beta; *TNF α* = tumour necrosis factor, alpha; beta; *IL10* = interleukin 10; *TIMP1* = TIMP (tissue inhibitor of matrix metalloproteinase) matrix metalloproteinase inhibitor 1; *IFNG* = interferon gamma; *ARG1* = arginase, liver; *IL13* = interleukin 13; *CFH* = complement factor H; *MMP1* = matrix metalloproteinase 1; *MMP10* = matrix metalloproteinase 10; *SPARCL1* = SPARC (secreted protein, acidic, cystein-rich)-like 1 (hevin).

Gene expression in relation to IVCM findings

The relationship between the gene expression results and the IVCM findings are presented in Table 2. Increasing IVCM connective tissue grade was associated with increased expression of *S100A7*, which also had the largest fold changes, *TIMP1* and *CFH*; and with decreased expression of *SPARCL1*. There was also some evidence, but with less robust P-values, that the connective tissue grade was associated with increased levels of *INDO*, *IL1B*, *SAA1*, *ARG1*, *MMP12* and *CD83*.

The expression of a number of genes were correlated with the IVCM inflammatory infiltrate density: the correlation coefficient for *IL1B*, *S100A7* and *DEFB4* was greater than +0.40 (Figure 3); for *SAA1*, *MMP9*, and *MMP12* it was between +0.25 and +0.35; and for *MMP10* and *SPARCL1* it was between -0.20 and -0.30. The presence of DFCs was associated with increased expression of *INDO* and *S100A7*; and with decreased expression of *SPARCL1*.

TABLE 2. Gene expression levels in relation to *in vivo* confocal microscopy findings

Gene	Fold change in gene expression with increasing connective tissue grade ^a			IVCM infiltrate		Fold change in gene expression if dendritiform cells present ^a	
	Grade	FC	p-value ^b	correlation coefficient	p-value ^{ab}	FC	p ^b
<i>S100A7</i>	1	1.00	<0.0001	0.43	<0.0001	2.03	0.0004
	2	1.64					
	3	3.76					
<i>SAA1</i>	1	1.00	0.002	0.28	<0.0001	1.80	0.03
	2	1.18					
	3	2.74					
<i>DEFB4A</i>	1	1.00	0.01	0.42	<0.0001	1.74	0.01
	2	0.84					
	3	1.60					
<i>CXCL5</i>	1	1.00	0.50	0.08	0.01	1.51	0.22
	2	1.25					
	3	1.40					
<i>MMP12</i>	1	1.00	0.004	0.31	<0.0001	1.36	0.05
	2	1.23					
	3	1.69					
<i>INDO</i>	1	1.00	0.004	0.16	<0.0001	1.71	0.0001
	2	1.17					
	3	1.60					
<i>MMP9</i>	1	1.00	0.01	0.28	<0.0001	1.19	0.19
	2	1.26					
	3	1.33					
<i>IL1B</i>	1	1.00	0.008	0.49	<0.0001	1.15	0.27
	2	1.18					
	3	1.45					
<i>NOS2</i>	1	1.00	0.14	0.15	0.02	1.28	0.07
	2	1.01					
	3	1.33					
<i>MMP7</i>	1	1.00	0.65	0.08	0.14	1.06	0.62
	2	1.02					
	3	1.12					
<i>CD83</i>	1	1.00	0.003	0.10	0.03	1.11	0.25
	2	1.21					
	3	1.13					
<i>IL13RA2</i>	1	1.00	0.79	0.14	0.005	0.92	0.65
	2	0.98					
	3	1.11					
<i>IL12B</i>	1	1.00	0.87	-0.09	0.01	0.90	0.59
	2	1.06					
	3	1.07					
<i>TNFA</i>	1	1.00	0.39	0.12	0.009	1.05	0.54
	2	1.07					
	3	1.04					
<i>IL10</i>	1	1.00	0.15	0.13	0.0003	1.11	0.77
	2	0.86					
	3	0.49					

<i>TIMP1</i>	1	1.00	<0.0001	0.19	0.0005	1.09	0.27
	2	1.18					
	3	1.46					
<i>IFNG</i>	1	1.00	0.43	-0.12	0.0003	1.05	0.71
	2	0.91					
	3	0.89					
<i>ARG</i>	1	1.00	0.003	0.14	0.002	1.09	0.42
	2	1.24					
	3	1.17					
<i>IL13</i>	1	1.00	0.13	0.001	0.98	0.92	0.27
	2	1.24					
	3	0.94					
<i>CFH</i>	1	1.00	0.0004	-0.09	0.004	0.93	0.30
	2	1.15					
	3	1.24					
<i>MMP1</i>	1	1.00	0.32	0.02	0.88	0.97	0.87
	2	1.06					
	3	1.40					
<i>MMP10</i>	1	1.00	0.02	-0.22	<0.0001	0.76	0.01
	2	1.14					
	3	0.85					
<i>SPARCL1</i>	1	1.00	<0.0001	-0.27	<0.0001	0.30	<0.0001
	2	0.87					
	3	0.67					

^a Adjusted for age and sex.

^b Using a Bonferroni correction for 69 comparisons then a P-value of <0.0007 would be considered significant, see text for discussion.

IVCM = *in vivo* confocal microscopy. FC = fold change. See Table 1 for gene abbreviations.

Gene expression levels in relation to microbiology findings

Infection with *C. trachomatis* was associated with up-regulated *IFNG*, *INDO* and *NOS2*; and with down-regulated *MMP10* and *SPARCL1*, Table 3 (note that only 5 participants had detectable *C. trachomatis* DNA). There was also some evidence, but with less robust P-values, that *C. trachomatis* infection was associated with increased *IL12B*, *MMP1*, *MMP7* and *MMP10*. Non-chlamydial bacterial infection was associated with increased expression of *INDO*, *S100A7*, *DEFB4A* and *MMP12* and with decreased expression of *MMP10*, *SPARCL1* and *CFH* (Table 3). There was also some evidence that non-chlamydial bacterial infection was associated with increased *IL1B*, *IL10*, *CXCL5*, *SAA1*, *MMP7* and *MMP9*.

TABLE 3. Gene expression in relation to microbiological infection status

Gene	Chlamydial infection ^a		Non-chlamydial bacterial infection ^a	
	FC	p	FC ^b	p
<i>S100A7</i>	4.21	0.04	2.59	0.0006
<i>SAA1</i>	8.06	0.01	2.47	0.008
<i>DEFB4A</i>	4.82	0.02	3.56	<0.0001
<i>CXCL5</i>	8.2	0.07	4.15	0.002
<i>MMP12</i>	1.84	0.21	2.21	<0.0001
<i>INDO</i>	6.78	<0.0001	2.74	<0.0001
<i>MMP9</i>	1.57	0.28	1.73	0.002
<i>IL1B</i>	1.49	0.32	1.72	0.001
<i>NOS2</i>	4.5	0.0003	1.40	0.06
<i>MMP7</i>	3.01	0.002	1.52	0.003
<i>CD83</i>	1.30	0.34	1.27	0.05
<i>IL13RA2</i>	0.81	0.72	0.98	0.94
<i>IL12B</i>	3.10	0.05	1.16	0.56
<i>TNFA</i>	1.60	0.06	1.14	0.20
<i>IL10</i>	1.29	0.81	3.30	0.005
<i>TIMP1</i>	0.98	0.94	1.09	0.36
<i>IFNG</i>	4.2	<0.0001	1.12	0.46
<i>ARG</i>	0.71	0.27	0.92	0.56
<i>IL13</i>	0.26	0.02	0.66	0.13
<i>CFH</i>	0.64	0.03	0.67	<0.0001
<i>MMP1</i>	0.14	0.004	0.59	0.06
<i>MMP10</i>	0.34	0.002	0.46	<0.0001
<i>SPARCL1</i>	0.02	<0.0001	0.09	<0.0001

^a Adjusted for age and sex. Using a Bonferroni correction for 46 comparisons then a P-value of <0.001 would be considered significant, see text for further discussion.

^b Compared to no organism cultured.

FC = fold change. See Table 1 for gene abbreviations.

IVCM findings in relation to non-chlamydial bacterial infection status

A new combined analysis of previously published IVCM and microbiology data found that pathogenic organisms were associated with significantly more inflammatory cells ($P < 0.0006$) and with the presence of tissue edema ($P = 0.02$), Table 4.(30, 32)

TABLE 4. *In vivo* confocal microscopy parameters by non-chlamydial bacterial infection status

IVCM parameter	No organism		Pathogenic organism		Adjusted increase ^a	p-value
	Mean	95% CI	Mean	95% CI		
Inflammatory infiltrate (cells/mm ²)	731	(694-769)	972	(841-1102)	230	0.0006
Connective tissue organization score	1.04	(0.97-1.11)	1.31	(1.06-1.56)	0.12	0.40
	n	%	n	%	Adjusted OR ^a	p-value
Dendritiform cells present	22	(6.0)	4	(14.3)	1.89	0.33
Tissue edema present	13	(3.6)	3	(10.7)	5.4	0.02

^a Compared to no growth and adjusted for age and sex.

CI = Confidence intervals; OR = Odds ratio.

DISCUSSION

Previous studies have used gene expression measurement of conjunctival swab samples to study the pathogenesis of trachoma.(6, 9, 14, 21, 22, 29, 46) However, this is the first study to systematically compare a large number of cases with trichomatous scarring and control subjects in which the scarring had not yet progressed to trichiasis. Cases with trichiasis are quite distinct from cases with scarring alone as they have a persistent foreign body abrading the globe stimulating inflammation and facilitating secondary infection.(13) In this study we have shown that scarring without trichiasis is associated with large fold changes in gene expression of various cytokines, chemokines and other immuno-fibrogenic mediators, even though the scarring was generally mild-moderate.

We found that mild to moderate trichomatous scarring is strongly associated with a pro-inflammatory, innate immune response which has marked anti-microbial properties, with increased expression of *S100A7*, *DEFB4A*, *CXCL5*, *IL1B*, *TNFA* and *SAA1*. This is consistent with a transcriptome microarray study of end-stage scarring trachoma with trichiasis from Ethiopia.(14) In both studies the expression of *S100A7* (psoriasin) showed the greatest fold increase between cases and controls. Psoriasin was initially identified as being upregulated in epithelial cells from psoriatic lesions.(38) It is an antimicrobial peptide (AMP) and therefore an important component of innate immune defence.(56) Psoriasin is chemotactic for neutrophils and regulates neutrophil function by inducing the production of several cytokines, chemokines and reactive oxygen species.(34, 61) It has been shown to reduce *Escherichia coli* survival, the mechanism of which may be either through zinc sequestration or direct adherence with the bacteria.(24, 36) It has more recently been shown to be upregulated at the ocular surface in response to *Staphylococcus aureus* and *Haemophilis influenzae*.(23) Binding of *E. Coli* flagellin by the Toll-like receptor 5 on keratinocytes is important in psoriasin induction, supporting its role as an innate immune molecule.(2) The defensins are another group of AMPs found at the ocular surface with β -defensins released by leucocytes and epithelial cells.(26, 41) *CXCL5* is a potent chemotaxin

involved in neutrophil activation which is produced by epithelial cells.(33, 56) TNF α and IL1 β are pro-inflammatory mediators which play a central role in mediating an innate immune response and have previously been found to be associated with active and scarring trachoma.(3, 6, 9, 15, 22, 47). Serum amyloid A, of which SAA1 is a main isoform, is an acute phase protein which is raised in inflammatory diseases and has been shown to have anti-bacterial effects.(19, 39)

The upregulation of these various pro-inflammatory, chemotactic and antimicrobial mediators suggests an important role for the innate immune response in trachomatous scarring. This is consistent with the cellular paradigm of *Chlamydia trachomatis* pathogenesis. While there was some evidence of Th1 response in scarring (increased *IFNG* and *INDO* expression), there was no significant difference in *IL13* expression, which might have suggested a Th2 response. There was some evidence that the expression of *IL13RA2*, which appears to act as a decoy receptor for IL13 and oppose its function, was increased in cases compared to controls.(60)

Many of the measured transcripts were upregulated in the presence of clinical inflammation. When scarred cases were compared to controls without scarring, the additional presence of inflammation in the cases tended to lead to more marked increases in gene expression. These observations are consistent with the hypothesis that episodes of inflammation are important in the pathogenesis of scarring and blindness. It is also interesting to note that a number of genes, for example, *S100A7*, *IL1B*, *SAA1* and *MMP12* showed large fold changes in gene expression even in relatively non-inflamed cases with scarring compared to controls. These genes also showed a clearly progressive increase in expression with increasing IVCM connective tissue organization grade.

We found infection with *C. trachomatis* to be infrequent in these adults with conjunctival scarring, with a similar detection rate to previous studies of trachomatous trichiasis.(8, 11,

13) While caution is needed in interpreting these data because of the small numbers, individuals infected with *C. trachomatis* had gene expression profiles characteristic of *C. trachomatis* infection in children.(9, 46) There was a typical Th1 dominated response with upregulated *IFNG* and *IL12B* ($p=0.05$) and also *INDO* and *NOS2* (both IFN γ -regulated) and some acute phase reactants. Infection with other bacteria was more frequent, and many of the above genes involved in innate immunity showed moderate-large increases in expression if a pathogenic organism was present. A previous study found that the presence of bacterial infection was associated with increased expression of *IL1B*, *TNF α* , *MMP1*, *MMP9* and *TIMP2* after trichiasis surgery.(10) In the current study bacterial infection was also found to be associated with an increased inflammatory infiltrate and tissue edema. Overall, these studies support the hypothesis that non-chlamydial bacterial infection is important in driving the scarring process.

Matrix metalloproteinases are capable of degrading the protein components of the ECM and also have wide-ranging effects on inflammatory and immune responses.(58) (50) Previous studies have implicated MMPs in the pathogenesis of trachomatous scarring and this was further confirmed in this study in a separate population.(9, 10, 14, 20, 29, 44) *MMP7*, *9*, *12* and *TIMP1* were upregulated in scarring and inflammation, while *MMP10* and *SPARCL1* were downregulated. *SPARCL1* is a matricellular protein which regulates the synthesis and turnover of the ECM.(35, 54) The gene expression levels by clinical scarring grade were broadly consistent with the levels by IVCM connective tissue grade, and the expression levels by clinical inflammation were consistent with the IVCM inflammatory infiltrate correlation. The differential gene expression of these ECM modifiers was closely related to bacterial infection status as discussed above.

Strengths of this population-based study were that we studied a large number of cases with early scarring trachoma to analyse gene expression changes in relation to clinical, IVCM and microbiological status. There are, however, a number of limitations. Gene expression levels

do not necessarily reflect the level of functional protein, exemplified by TFG β , which has significant post-transcriptional regulation. Conjunctival swabs obtain material from the tissue surface and so have a tendency to limit the observations to events in or near the epithelium. To address these two issues we are currently comparing gene expression with immunohistochemical analysis of conjunctival biopsy tissue.

This study showed that mild-moderate trachomatous scarring is strongly associated with a pro-inflammatory, innate immune response, and with differential expression of various modifiers of the ECM. We found no evidence for an active role for IL-13 / Th2 responses at this stage of the disease. This is consistent with the findings from a microarray transcriptome study from Ethiopia on advanced trachomatous scarring.(14) We were also able to use IVCM to show differential transcript levels according to connective tissue morphology and inflammatory cell infiltrate. A key determinant in the expression of many of these genes appears to be the presence of non-chlamydial bacterial infection which, as well as causing inflammation, may contribute to the scarring process.

Acknowledgements

We thank all of the participants for their involvement. This study was funded by a fellowship grant to MJB from the Wellcome Trust (080741/Z/06/Z). VHH is supported by a fellowship grant from the British Council for the Prevention of Blindness (Barrie Jones Fellowship). The funders had no part in the study design; in the collection, analysis, and interpretation of data; in the writing of the report; and in the decision to submit the paper for publication.

References

1. **Abrahams, C., R. C. Ballard, and E. E. Sutter.** 1979. The pathology of trachoma in a black South African population. Light microscopical, histochemical and electron microscopical findings. *S Afr Med J* **55**:1115-1118.
2. **Abtin, A., L. Eckhart, M. Mildner, F. Gruber, J. M. Schroder, and E. Tschachler.** 2008. Flagellin is the principal inducer of the antimicrobial peptide S100A7c (psoriasin) in human epidermal keratinocytes exposed to *Escherichia coli*. *FASEB J* **22**:2168-2176.
3. **Abu el-Asrar, A. M., K. Geboes, K. F. Tabbara, S. A. al-Kharashi, L. Missotten, and V. Desmet.** 1998. Immunopathogenesis of conjunctival scarring in trachoma. *Eye* **12 (Pt 3a)**:453-460.
4. **al-Rajhi, A. A., A. Hidayat, A. Nasr, and M. al-Faran.** 1993. The histopathology and the mechanism of entropion in patients with trachoma. *Ophthalmology* **100**:1293-1296.
5. **Bailey, R. L., M. J. Holland, H. C. Whittle, and D. C. Mabey.** 1995. Subjects recovering from human ocular chlamydial infection have enhanced lymphoproliferative responses to chlamydial antigens compared with those of persistently diseased controls. *Infect Immun* **63**:389-392.
6. **Bobo, L., N. Novak, H. Mkocha, S. Vitale, S. West, and T. C. Quinn.** 1996. Evidence for a predominant proinflammatory conjunctival cytokine response in individuals with trachoma. *Infect Immun* **64**:3273-3279.
7. **Brunham, R. C., and J. Rey-Ladino.** 2005. Immunology of Chlamydia infection: implications for a Chlamydia trachomatis vaccine. *Nat Rev Immunol* **5**:149-161.
8. **Burton, M. J., R. A. Adegbola, F. Kinteh, U. N. Ikumapayi, A. Foster, D. C. Mabey, and R. L. Bailey.** 2007. Bacterial infection and trachoma in the gambia: a case control study. *Invest Ophthalmol Vis Sci* **48**:4440-4444.
9. **Burton, M. J., R. L. Bailey, D. Jeffries, D. C. Mabey, and M. J. Holland.** 2004. Cytokine and fibrogenic gene expression in the conjunctivas of subjects from a Gambian community where trachoma is endemic. *Infect Immun* **72**:7352-7356.
10. **Burton, M. J., R. L. Bailey, D. Jeffries, S. N. Rajak, R. A. Adegbola, A. Sillah, D. C. Mabey, and M. J. Holland.** Conjunctival expression of matrix metalloproteinase and proinflammatory cytokine genes after trichiasis surgery. *Invest Ophthalmol Vis Sci* **51**:3583-3590.
11. **Burton, M. J., R. J. Bowman, H. Faal, E. A. Aryee, U. N. Ikumapayi, N. D. Alexander, R. A. Adegbola, D. C. Mabey, A. Foster, G. J. Johnson, and R. L. Bailey.** 2006. The long-term natural history of trachomatous trichiasis in the Gambia. *Invest Ophthalmol Vis Sci* **47**:847-852.
12. **Burton, M. J., M. J. Holland, N. Faal, E. A. Aryee, N. D. Alexander, M. Bah, H. Faal, S. K. West, A. Foster, G. J. Johnson, D. C. Mabey, and R. L. Bailey.** 2003. Which members of a community need antibiotics to control trachoma? Conjunctival Chlamydia trachomatis infection load in Gambian villages. *Invest Ophthalmol Vis Sci* **44**:4215-4222.
13. **Burton, M. J., F. Kinteh, O. Jallow, A. Sillah, M. Bah, M. Faye, E. A. Aryee, U. N. Ikumapayi, N. D. Alexander, R. A. Adegbola, H. Faal, D. C. Mabey, A. Foster, G. J. Johnson, and R. L. Bailey.** 2005. A randomised controlled trial of azithromycin following surgery for trachomatous trichiasis in the Gambia. *Br J Ophthalmol* **89**:1282-1288.
14. **Burton, M. J., S. N. Rajak, J. Bauer, H. A. Weiss, S. B. Tolbert, A. Shoo, E. Habtamu, A. Manjurano, P. M. Emerson, D. C. Mabey, M. J. Holland, and R. L. Bailey.** 2011. Conjunctival transcriptome in scarring trachoma. *Infect Immun* **79**:499-511.
15. **Conway, D. J., M. J. Holland, R. L. Bailey, A. E. Campbell, O. S. Mahdi, R. Jennings, E. Mbeni, and D. C. Mabey.** 1997. Scarring trachoma is associated with polymorphism in the tumor necrosis factor alpha (TNF-alpha) gene promoter and with elevated TNF-alpha levels in tear fluid. *Infect Immun* **65**:1003-1006.
16. **Darville, T., and T. J. Hiltke.** Pathogenesis of genital tract disease due to Chlamydia trachomatis. *J Infect Dis* **201 Suppl 2**:S114-125.

17. **Dawson, C. R., B. R. Jones, and M. L. Tarizzo.** 1981. Guide to Trachoma Control. World Health Organization.
18. **Dawson CR, M. R., Daghfous R, Juster R, Schachter J.** 1990. What clinical signs are critical in evaluating the impact of intervention in trachoma? *Chlamydia Infections*, p. 271-275. Proceedings of the Seventh International Symposium on Human Chlamydial Infections. Cambridge University Press, London.
19. **Eckhardt, E. R., J. Witta, J. Zhong, R. Arsenescu, V. Arsenescu, Y. Wang, S. Ghoshal, M. C. de Beer, F. C. de Beer, and W. J. de Villiers.** Intestinal epithelial serum amyloid A modulates bacterial growth in vitro and pro-inflammatory responses in mouse experimental colitis. *BMC Gastroenterol* **10**:133.
20. **El-Asrar, A. M., K. Geboes, S. A. Al-Kharashi, A. A. Al-Mosallam, L. Missotten, L. Paemen, and G. Opednakker.** 2000. Expression of gelatinase B in trachomatous conjunctivitis. *Br J Ophthalmol* **84**:85-91.
21. **Faal, N., R. L. Bailey, D. Jeffries, H. Joof, I. Sarr, M. Laye, D. C. Mabey, and M. J. Holland.** 2006. Conjunctival FOXP3 expression in trachoma: do regulatory T cells have a role in human ocular *Chlamydia trachomatis* infection? *PLoS Med* **3**:e266.
22. **Faal, N., R. L. Bailey, I. Sarr, H. Joof, D. C. Mabey, and M. J. Holland.** 2005. Temporal cytokine gene expression patterns in subjects with trachoma identify distinct conjunctival responses associated with infection. *Clin Exp Immunol* **142**:347-353.
23. **Garreis, F., M. Gottschalt, T. Schlorf, R. Glaser, J. Harder, D. Worlitzsch, and F. P. Paulsen.** 2011. Expression and regulation of antimicrobial peptide psoriasin (S100A7) at the ocular surface and in the lacrimal apparatus. *Invest Ophthalmol Vis Sci* **52**:4914-4922.
24. **Glaser, R., J. Harder, H. Lange, J. Bartels, E. Christophers, and J. M. Schroder.** 2005. Antimicrobial psoriasin (S100A7) protects human skin from *Escherichia coli* infection. *Nat Immunol* **6**:57-64.
25. **Guzey, M., I. Ozardali, E. Basar, G. Aslan, A. Satici, and S. Karadede.** 2000. A survey of trachoma: the histopathology and the mechanism of progressive cicatrization of eyelid tissues. *Ophthalmologica* **214**:277-284.
26. **Hazlett, L., and M. Wu.** Defensins in innate immunity. *Cell Tissue Res* **343**:175-188.
27. **Holland, M. J., R. L. Bailey, D. J. Conway, F. Culley, G. Miranpuri, G. I. Byrne, H. C. Whittle, and D. C. Mabey.** 1996. T helper type-1 (Th1)/Th2 profiles of peripheral blood mononuclear cells (PBMC); responses to antigens of *Chlamydia trachomatis* in subjects with severe trachomatous scarring. *Clin Exp Immunol* **105**:429-435.
28. **Holland, M. J., R. L. Bailey, L. J. Hayes, H. C. Whittle, and D. C. Mabey.** 1993. Conjunctival scarring in trachoma is associated with depressed cell-mediated immune responses to chlamydial antigens. *J Infect Dis* **168**:1528-1531.
29. **Holland, M. J., D. Jeffries, M. Pattison, G. Korr, A. Gall, H. Joof, A. Manjang, M. J. Burton, D. C. Mabey, and R. L. Bailey.** Pathway-focused arrays reveal increased matrix metalloproteinase-7 (matrilysin) transcription in trachomatous trichiasis. *Invest Ophthalmol Vis Sci* **51**:3893-3902.
30. **Hu, V. H., P. Massae, H. A. Weiss, C. Chevallier, J. J. Onyango, I. A. Afwamba, D. C. Mabey, R. L. Bailey, and M. J. Burton.** 2011. Bacterial infection in scarring trachoma. *Invest Ophthalmol Vis Sci* **52**:2181-2186.
31. **Hu, V. H., P. Massae, H. A. Weiss, I. A. Cree, P. Courtright, D. C. Mabey, R. L. Bailey, and M. J. Burton.** 2011. In vivo confocal microscopy of trachoma in relation to normal tarsal conjunctiva. *Ophthalmology* **118**:747-754.
32. **Hu, V. H., H. A. Weiss, P. Massae, P. Courtright, W. Makupa, D. C. Mabey, R. L. Bailey, and M. J. Burton.** 2011. In Vivo Confocal Microscopy in Scarring Trachoma. *Ophthalmology*.
33. **Jeyaseelan, S., R. Manzer, S. K. Young, M. Yamamoto, S. Akira, R. J. Mason, and G. S. Worthen.** 2005. Induction of CXCL5 during inflammation in the rodent lung involves activation of alveolar epithelium. *Am J Respir Cell Mol Biol* **32**:531-539.

34. **Jinquan, T., H. Vorum, C. G. Larsen, P. Madsen, H. H. Rasmussen, B. Gesser, M. Etzerodt, B. Honore, J. E. Celis, and K. Thestrup-Pedersen.** 1996. Psoriasin: a novel chemotactic protein. *J Invest Dermatol* **107**:5-10.
35. **Kang, M. H., D. J. Oh, and D. J. Rhee.** Effect of hevin deletion in mice and characterization in trabecular meshwork. *Invest Ophthalmol Vis Sci* **52**:2187-2193.
36. **Lee, K. C., and R. L. Eckert.** 2007. S100A7 (Psoriasin)--mechanism of antibacterial action in wounds. *J Invest Dermatol* **127**:945-957.
37. **Livak, K. J., and T. D. Schmittgen.** 2001. Analysis of relative gene expression data using real-time quantitative PCR and the 2(-Delta Delta C(T)) Method. *Methods* **25**:402-408.
38. **Madsen, P., H. H. Rasmussen, H. Leffers, B. Honore, K. Dejgaard, E. Olsen, J. Kiil, E. Walbum, A. H. Andersen, B. Basse, and et al.** 1991. Molecular cloning, occurrence, and expression of a novel partially secreted protein "psoriasin" that is highly up-regulated in psoriatic skin. *J Invest Dermatol* **97**:701-712.
39. **Malle, E., S. Sodin-Semrl, and A. Kovacevic.** 2009. Serum amyloid A: an acute-phase protein involved in tumour pathogenesis. *Cell Mol Life Sci* **66**:9-26.
40. **Mariotti, S. P., D. Pascolini, and J. Rose-Nussbaumer.** 2009. Trachoma: global magnitude of a preventable cause of blindness. *Br J Ophthalmol* **93**:563-568.
41. **McDermott, A. M.** 2009. The role of antimicrobial peptides at the ocular surface. *Ophthalmic Res* **41**:60-75.
42. **Mozzato-Chamay, N., O. S. Mahdi, O. Jallow, D. C. Mabey, R. L. Bailey, and D. J. Conway.** 2000. Polymorphisms in candidate genes and risk of scarring trachoma in a Chlamydia trachomatis--endemic population. *J Infect Dis* **182**:1545-1548.
43. **Munoz, B., L. Bobo, H. Mkocha, M. Lynch, Y. H. Hsieh, and S. West.** 1999. Incidence of trichiasis in a cohort of women with and without scarring. *Int J Epidemiol* **28**:1167-1171.
44. **Natividad, A., G. Cooke, M. J. Holland, M. J. Burton, H. M. Joof, K. Rockett, D. P. Kwiatkowski, D. C. Mabey, and R. L. Bailey.** 2006. A coding polymorphism in matrix metalloproteinase 9 reduces risk of scarring sequelae of ocular Chlamydia trachomatis infection. *BMC Med Genet* **7**:40.
45. **Natividad, A., T. C. Freeman, D. Jeffries, M. J. Burton, D. C. Mabey, R. L. Bailey, and M. J. Holland.** Human conjunctival transcriptome analysis reveals the prominence of innate defence in Chlamydia trachomatis infection. *Infect Immun*.
46. **Natividad, A., T. C. Freeman, D. Jeffries, M. J. Burton, D. C. Mabey, R. L. Bailey, and M. J. Holland.** 2010. Human conjunctival transcriptome analysis reveals the prominence of innate defense in Chlamydia trachomatis infection. *Infect Immun* **78**:4895-4911.
47. **Natividad, A., N. Hanchard, M. J. Holland, O. S. Mahdi, M. Diakite, K. Rockett, O. Jallow, H. M. Joof, D. P. Kwiatkowski, D. C. Mabey, and R. L. Bailey.** 2007. Genetic variation at the TNF locus and the risk of severe sequelae of ocular Chlamydia trachomatis infection in Gambians. *Genes Immun* **8**:288-295.
48. **Natividad, A., M. J. Holland, K. A. Rockett, J. Forton, N. Faal, H. M. Joof, D. C. Mabey, R. L. Bailey, and D. P. Kwiatkowski.** 2008. Susceptibility to sequelae of human ocular chlamydial infection associated with allelic variation in IL10 cis-regulation. *Hum Mol Genet* **17**:323-329.
49. **Natividad, A., J. Wilson, O. Koch, M. J. Holland, K. Rockett, N. Faal, O. Jallow, H. M. Joof, M. J. Burton, N. D. Alexander, D. P. Kwiatkowski, D. C. Mabey, and R. L. Bailey.** 2005. Risk of trachomatous scarring and trichiasis in Gambians varies with SNP haplotypes at the interferon-gamma and interleukin-10 loci. *Genes Immun* **6**:332-340.
50. **Parks, W. C., C. L. Wilson, and Y. S. Lopez-Boado.** 2004. Matrix metalloproteinases as modulators of inflammation and innate immunity. *Nat Rev Immunol* **4**:617-629.
51. **Reacher, M. H., J. Pe'er, P. A. Rapoza, J. A. Whittum-Hudson, and H. R. Taylor.** 1991. T cells and trachoma. Their role in cicatricial disease. *Ophthalmology* **98**:334-341.

52. **Resnikoff, S., D. Pascolini, D. Etya'ale, I. Kocur, R. Pararajasegaram, G. P. Pokharel, and S. P. Mariotti.** 2004. Global data on visual impairment in the year 2002. *Bull World Health Organ* **82**:844-851.
53. **Stephens, R. S.** 2003. The cellular paradigm of chlamydial pathogenesis. *Trends Microbiol* **11**:44-51.
54. **Sullivan, M. M., T. H. Barker, S. E. Funk, A. Karchin, N. S. Seo, M. Hook, J. Sanders, B. Starcher, T. N. Wight, P. Puolakkainen, and E. H. Sage.** 2006. Matricellular hevin regulates decorin production and collagen assembly. *J Biol Chem* **281**:27621-27632.
55. **West, S. K., B. Munoz, H. Mkocha, Y. H. Hsieh, and M. C. Lynch.** 2001. Progression of active trachoma to scarring in a cohort of Tanzanian children. *Ophthalmic Epidemiol* **8**:137-144.
56. **Wiesner, J., and A. Vilcinskas.** Antimicrobial peptides: the ancient arm of the human immune system. *Virulence* **1**:440-464.
57. **Wolle, M. A., B. E. Munoz, H. Mkocha, and S. K. West.** 2009. Constant ocular infection with *Chlamydia trachomatis* predicts risk of scarring in children in Tanzania. *Ophthalmology* **116**:243-247.
58. **Wynn, T. A.** 2008. Cellular and molecular mechanisms of fibrosis. *J Pathol* **214**:199-210.
59. **Wynn, T. A.** 2004. Fibrotic disease and the T(H)1/T(H)2 paradigm. *Nat Rev Immunol* **4**:583-594.
60. **Wynn, T. A.** 2003. IL-13 effector functions. *Annu Rev Immunol* **21**:425-456.
61. **Zheng, Y., F. Niyonsaba, H. Ushio, S. Ikeda, I. Nagaoka, K. Okumura, and H. Ogawa.** 2008. Microbicidal protein psoriasin is a multifunctional modulator of neutrophil activation. *Immunology* **124**:357-367.

Figure 1: *In vivo* confocal microscopy grading system of inflammatory features. Images are 400×400µm. **A, Inflammatory infiltrate:** seen as multiple bright white nuclei. The mean inflammatory cell density of 3 randomly selected volume scans is calculated. The individual scan with the highest density of cells from within the volume scan is used. **B, Dendritiform cells:** graded as present or absent. To be present, the mean number of DCs per volume scan needs to be ≥1. The largest number of dendritiform cells in any individual scan in a volume scan is used for measurement. A mean number of ≥1 is used to differentiate occasional dendritiform cells seen in scans of otherwise normal subjects. **C, Tissue edema:** seen as multiple black empty spaces. Graded as present or absent in any volume scan. **D, Papillae:** seen as elevations with a central vascular network. Graded as present or absent in any volume scan.

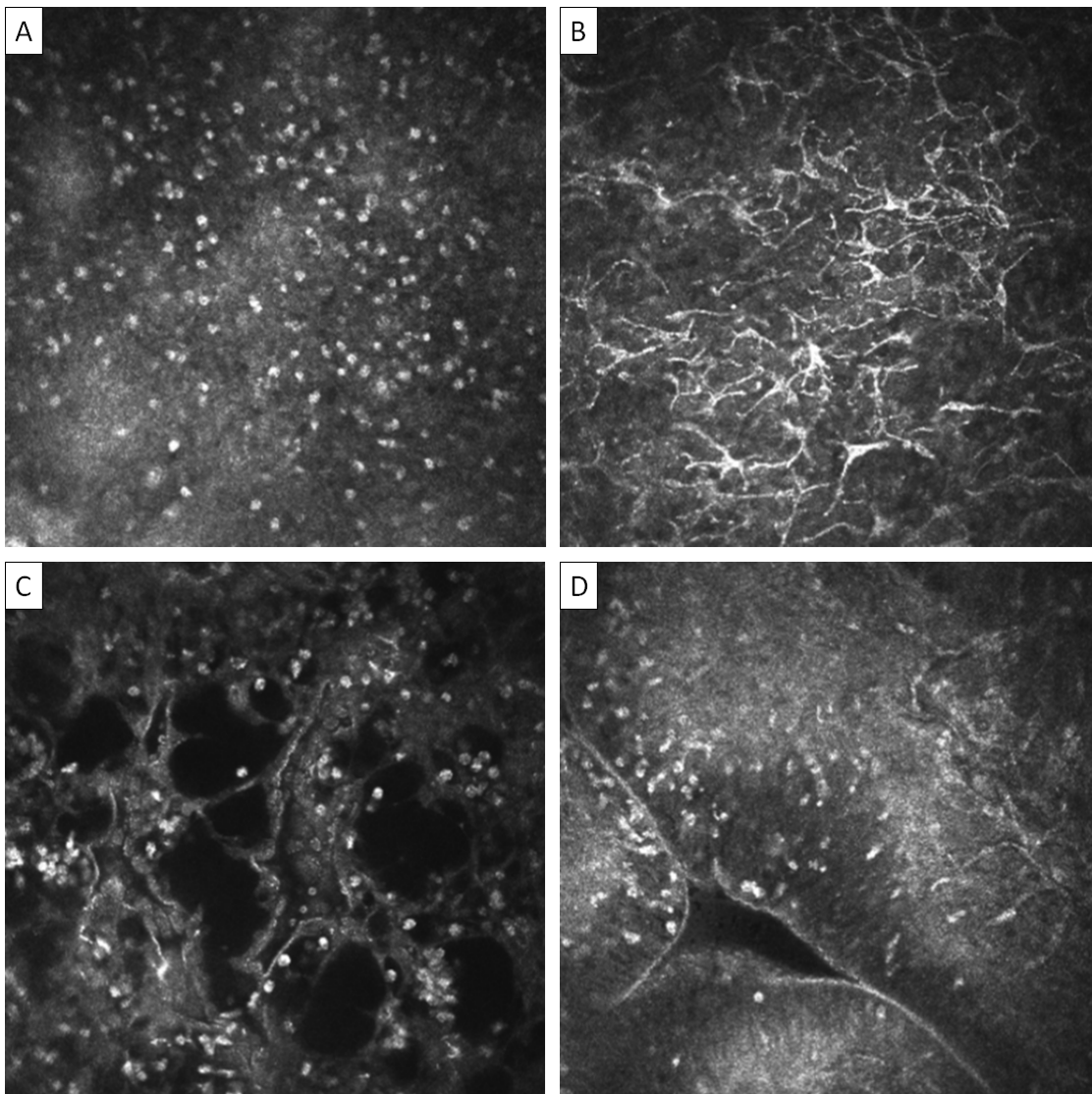


Figure 2: *In vivo* confocal microscopy grading system for conjunctival connective tissue organization. Images are 400×400µm. (A) Normal: homogenous, amorphous appearance, with occasional, fine, wispy strands. (B) Grade 1: heterogenous appearance with poorly defined clumps or bands present. (C) Grade 2: clearly defined bands of tissue which constitute less than 50% of the area of the scan. (D) Grade 3: clearly defined bands or sheets of tissue which constitute 50% or more of the area of the scan and in which striations are present. If different grades of scarring are seen within a particular volume scan then the highest grade is recorded. The connective tissue which is graded needs to be separate from that associated with the vascular tissue, if this is not possible then the scan is considered ungradable.

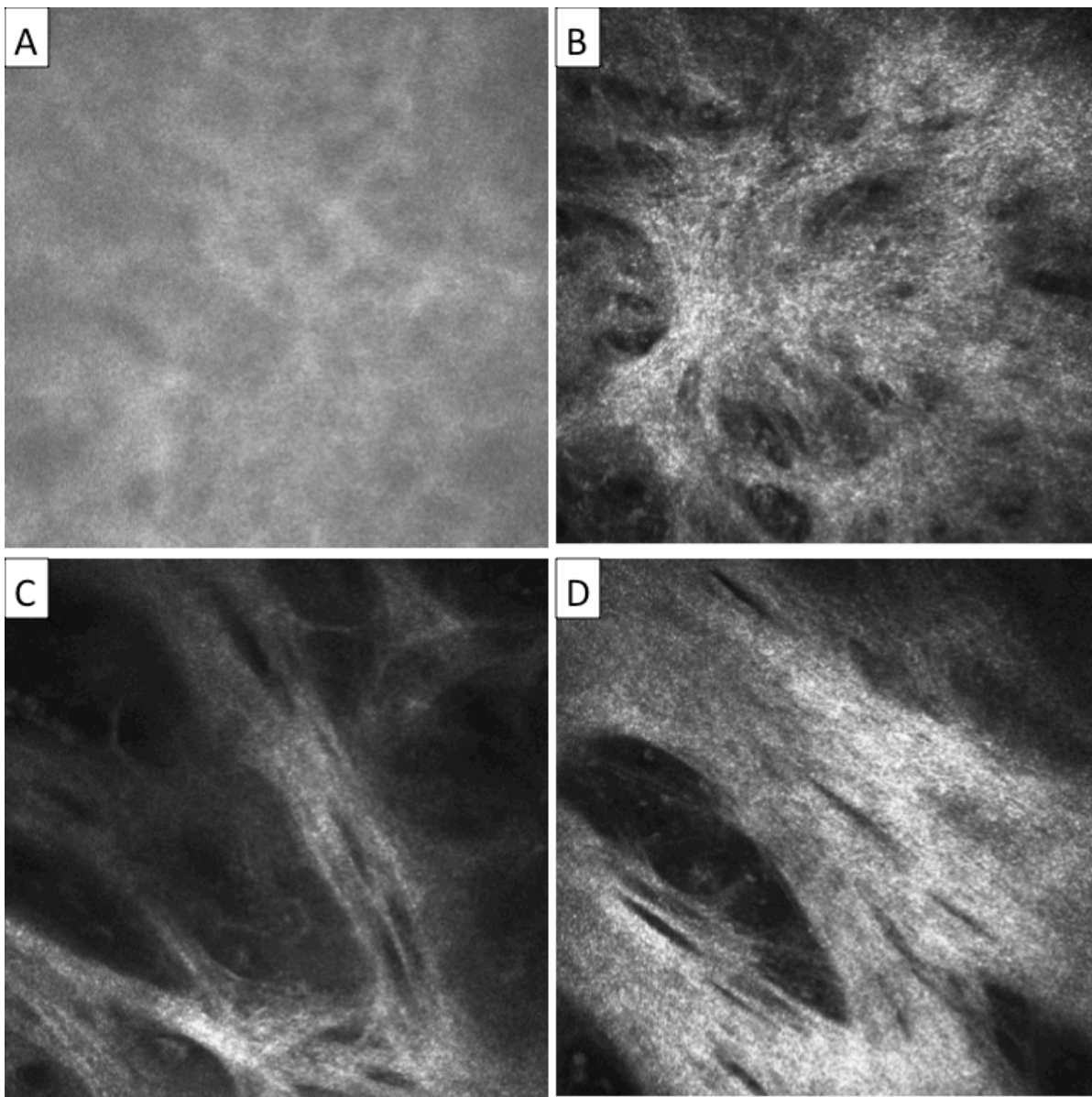
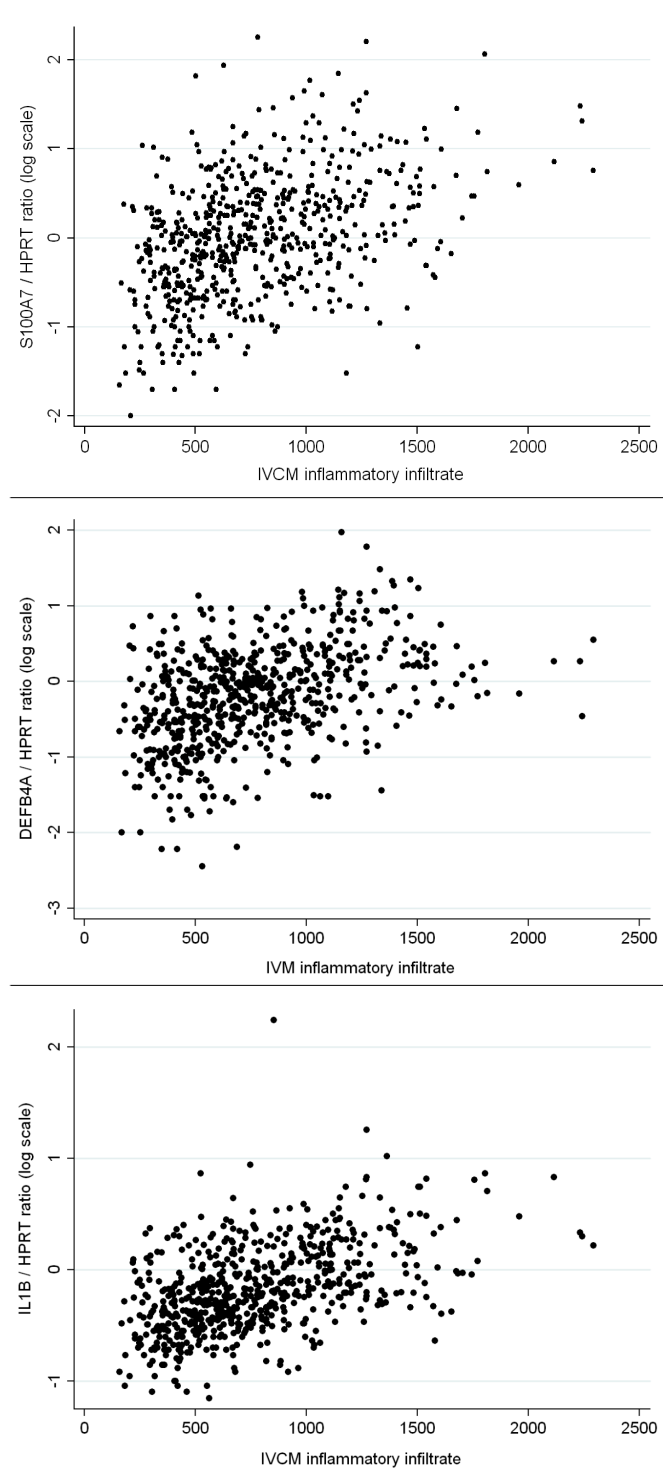


Figure 3. Gene expression levels relative to *HPRT1* of *S100A7*, *DEFB4A* and *IL1B* by *in vivo* confocal microscopy inflammatory cell infiltrate.



Chapter 13

Immunohistological analysis of trachomatous scarring reveals increased CD8+ cells and an infiltrate of CD45 negative inflammatory cells



Research paper using histological analysis and immunohistochemical staining to compare tissue and cellular changes in trachomatous scarring and control tissue

Cover sheet for each ‘research/review paper’ included in a research thesis

1. For a ‘research/review paper’ prepared for publication but not yet published
 - 1.1. Where is the work intended to be published? ***Investigative Ophthalmology and Visual Science***
 - 1.2. List the paper’s authors in the intended authorship order
Victor H. Hu, Phil Luthert, James Pullin, Ian A. Cree, Helen A. Weiss, Patrick Massae, William Makupa, David C. W. Mabey, Robin L. Bailey, Martin J. Holland, Matthew J. Burton
 - 1.3. Stage of publication ***Not yet submitted***

2. For multi-authored work, give full details of your role in the research included in the paper and in the preparation of the paper. (Attach a further sheet if necessary)

I conducted the field work for this study including organising and running surgical camps providing trichiasis surgery in the community. I liaised with the Kilimanjaro Eye Care Coordinator with regards to these. I also identified and recruited suitable control participants. I performed all the clinical examinations and took the swab samples. I supervised the trichiasis surgery including the biopsy sampling and took the biopsy samples from control participants myself. The histological and immunohistochemical processing was performed at the Institute of Ophthalmology, University College London. I spent several days at the Institute discussing and observing this work with the histotechnicians and Phil Luthert. The histological and immunohistochemical grading was performed by Phil Luther and Ian Cree. I sat with Phil Luthert on a multi-viewer microscope while we worked through the grading systems and observed all of the grading performed by him. I liaised with Ian Cree about the grading performed by him. I performed the data analysis with some guidance from Helen Weiss. I wrote the paper with consideration of comments from co-authors.

Candidate’s signature.....



Supervisor or senior author’s signature to confirm role as stated in (2).....

Title Page

Title:

Immunohistological analysis of trachomatous scarring reveals an infiltrate of Natural Killer cells and CD45 negative cells

Authors & Affiliations:

Victor H. Hu^{1,2}, Phil Luthert³, James Pullin³, Ian A. Cree³, Helen A. Weiss⁴, Patrick Massae², William Makupa², David C. W. Mabey⁵, Robin L. Bailey⁵, Martin J. Holland⁵, Matthew J. Burton^{1,2}

¹ International Centre for Eye Health, Department of Clinical Research, Faculty of Infectious and Tropical Diseases, London School of Hygiene and Tropical Medicine, London, UK

² Kilimanjaro Christian Medical Centre, Moshi, Tanzania

³ Institute of Ophthalmology, University College London, UK

⁴ Department of Infectious Disease Epidemiology, Faculty of Epidemiology and Population Health, London School of Hygiene and Tropical Medicine, London, UK

⁵ Department of Clinical Research Department, Faculty of Infectious and Tropical Diseases, London School of Hygiene and Tropical Medicine, London, UK

Corresponding author details:

Victor Hu

International Centre for Eye Health,

London School of Hygiene and Tropical Medicine,

Keppel Street,

London, WC1E 7HT, UK

Telephone number: +255 76 258 2948

Email: victor.hu@lshtm.ac.uk

Financial support:

This study was funded by grants from the Wellcome Trust (080741/Z/06/Z and 079246/Z/06/Z) and by a grant for the British Council for the Prevention of Blindness. VHH is supported by a fellowship grant from the British Council for the Prevention of Blindness (Barrie Jones Fellowship). The funders had no part in the study design; in the collection, analysis, and interpretation of data; in the writing of the report; and in the decision to submit the paper for publication.

Conflict of interest:

None of the authors have had, or will receive, any financial support or other benefit which may be viewed as creating a potential conflict of interest.

Running head

Infiltrates of Natural Killer cells and a population of CD45 negative cells are found in trachomatous scarring

Key words:

Trachoma; histology; immunohistochemistry; conjunctiva; Chlamydia trachomatis; scarring; case-control..

Abstract

Purpose. To assess the tissue morphology and cellular infiltrates found in trachomatous scarring.

Methods. Case-control study of 34 cases with severe trachomatous scarring undergoing trichiasis surgery and 33 control subjects without scarring undergoing cataract or retinal detachment surgery. Participants were examined clinically and conjunctival biopsy samples were taken which were fixed in buffered formalin and processed into paraffin wax. Hematoxylin and eosin (H&E) staining was performed for assessment of the inflammatory cell infiltrate. Immunohistochemical processing was performed to identify cells staining with CD3 (T-cells), CD4 (helper T-cells), CD8 (suppressor/cytotoxic T-cells and Natural Killer cells), CD20 (B-cells), CD45 (nucleated hematopoietic cells), CD56 (Natural Killer cells), CD68 (macrophages/monocytes) and CD83 (mature dendritic cells). The degree of scarring was assessed histologically using cross polarised light to visualise collagen fibres.

Results. Scarring was associated with increased inflammatory cell infiltrates on H&E and CD45 staining. Scarring was also associated with increased CD8+ and CD56+ cells, but not CD3+ cells, indicating a Natural Killer cell infiltrate. There was some increase of CD20+ cells, but no evidence for increased CD4+, CD68+ or CD83+ cells. Numerous CD45 negative cells were also seen in scarred conjunctiva. Clinically scarred conjunctiva was strongly associated with disorganization of the normal collagen architecture.

Conclusion. Scarred conjunctiva appears to be infiltrated with Natural Killer cells and further investigation is warranted on the role these cells may play in the pathogenesis of trachoma. Further work is also required on the identification of an unexpected infiltrate of CD45 negative cells in scarring.

Introduction

Trachoma starts in childhood with repeated conjunctival infection by the gram-negative bacterium *Chlamydia trachomatis*. The infection provokes a marked inflammatory response, which can lead to cicatricial sequelae in later life: conjunctival scarring, entropion, trichiasis, corneal opacity and, eventually, blindness. Trachoma is still a major problem world-wide; the World Health Organization (WHO) currently estimates that about 84 million people (mostly children) have active inflammatory trachoma, and about 8 million (mostly adults) are either blind or visually impaired.¹ There has been an encouraging reduction in the number of children with active disease over the last few decades, which is probably attributable to improved living standards and trachoma control programmes.² However, even in areas where the prevalence of *C. trachomatis* infection has been low for some time scarring complications still appear to develop and progress. Therefore, it is important to better understand the cicatricial disease process.

The pathophysiology of scarring complications of *C. trachomatis* infection, both in the eye and genital tract, remains unclear and various models have been proposed. The “immunological” paradigm suggests that disease is the result of a cell-mediated immune process, particularly involving T-cells responses, against specific *C. trachomatis* antigens.^{3, 4} The “cellular” paradigm argues that infected epithelial cells are central in causing tissue damage through the release of pro-inflammatory cytokines, chemokines and growth factors, although this may also subsequently involve adaptive responses.^{5, 6} Recent studies have supported the role of innate immunity in the development of scarring complications and the epithelium may be important in driving these innate processes.⁷⁻¹⁰

Histological examination of trachomatous tissue gives a valuable opportunity to study the disease. Several previous studies have examined the histopathology of conjunctival biopsy specimens from individuals with trachoma.¹¹⁻²¹ However, these studies have tended to have

relatively small sample sizes and either lacked or had very few control samples for comparison. In the present study we have analysed conjunctival biopsies from a sizeable number of patients with trichomatous trichiasis and control subjects recruited from the same region. We characterised in detail the morphological and cellular changes using masked observers and defined grading systems with robust analytical techniques. We examined the hypotheses that conjunctiva with trichomatous scarring is characterised by connective tissue changes that can be seen histologically and with an increased inflammatory cell infiltrate. We also wanted to examine the nature of the cellular infiltrate found in scarred trachoma.

Methods

Ethical permission & Subject recruitment

This study adhered to the tenets of the Declaration of Helsinki. It was approved by the Tanzanian National Institute of Medical Research Ethics Committee, the Kilimanjaro Christian Medical Centre Ethics Committee and the London School of Hygiene and Tropical Medicine Ethics Committee. The study was explained to potential study subjects and written, informed consent was obtained before enrolment.

Clinical assessment and swab sample collection

All subjects were examined by an ophthalmologist using $\times 2.5$ loupes and a bright torch. The 1981 World Health Organization (FPC) trachoma grading system was used to grade conjunctival follicles and papillae, entropion, trichiasis and corneal opacity.²² A more detailed grading system was used for conjunctival scarring as previously described.^{23, 24} The conjunctiva was anaesthetised with preservative-free proxymetacaine 0.5% eye drops (Minims®, Chauvin Pharmaceuticals). An upper tarsal conjunctival swab was collected (Dacron polyester-tipped, Hardwood Products Company, Guildford, ME) for *C. trachomatis* detection and put into a dry tube. Samples were kept on ice packs until frozen later the same day at -80°C .

Biopsy samples and staining

The eyelid was injected with 2% lignocaine (Vital Healthcare, India) and the eye cleaned with 5% povidone iodine. A biopsy sample was taken using a 3mm trephine from the tarsal conjunctiva, 2mm from the lid margin, at the junction of the medial $\frac{2}{3}$ and lateral $\frac{1}{3}$ of the everted lid. Samples were immediately placed in 10% neutral buffered formalin and subsequently embedded in paraffin wax. Sections, 4 μm thick, were cut perpendicular to the conjunctival surface and stained with hematoxylin and eosin (H&E) and for immunohistochemistry with the antibodies shown in Table 2. Prior to immunohistochemical

staining, sections were dewaxed and pressure-cooked for 4 minutes in de-ionized water with antigen retrieval solution (Vector Lab, UK). After incubation at room temperature with the primary antibody sections were incubated with a biotinylated secondary antibody, followed by streptavidin-conjugated horseradish peroxidase (Dako, UK), and finally 3,3'-diaminobenzidine (Dako, UK) was used as the chromogen. Endogenous peroxidase was inhibited using Real Endogenous Peroxidase Block (Dako, UK). The slides were counterstained with Harris hematoxylin. All staining procedures were performed using the Dako autostainer (Dako, UK). Positive control samples were provided by human tonsil sections and omission of primary antibody controls were used throughout.

Table 2: Summary of primary antibody targets

Antigen	Specificity	Dilution	Source and type
CD3	T-cells*	1:400	Dako. polyclonal, rabbit. Code no. A.0452.
CD4	Helper T-cells	1:50	Dako. Monoclonal, mouse. Clone 4B12.
CD8	Cytotoxic/suppressor T-cells*	1:100	Dako. Monoclonal, mouse. Clone C8/144B.
CD20	B-cells	1:600	Dako. Monoclonal, mouse. Clone L26.
CD45	Nucleated hematopoietic cells	1:800	Dako. Monoclonal, mouse. Clones 2B11+PD7/26.
CD56	Natural killer cells	1:100	Dako. Monoclonal, mouse. Clone 123C.
CD68	Macrophages/monocytes	1:100	Dako. Monoclonal, mouse. Clone KP1.
CD83	Mature dendritic cells	1:75	Serotec AbD. Monoclonal, mouse. Clone HB15e.

Incubation times were 30 minutes for all antibodies

* Natural killer cell lines can also be identified.

Microscopic examination of biopsy samples

Grading was performed by ophthalmic pathologists who were masked to the clinical status of the patients. The grading was performed on the subepithelial tissue (lamina propria and stroma unless otherwise stated), on the parameters below, with examples pictures shown in Figures 1-11 (see end of manuscript).

- The degree of scarring was assessed using cross polarised light for both the subepithelium and the tarsus. Initial comparison of the examination of picosirus red and other tinctorial stains under cross polarised light showed that the organization of collagen bundles was apparent with a variety of staining methods. For assessment purposes we used elastin/Van Gieson stained preparations as these sections contained all of the samples available. Tissue appearing healthy was graded as 0 and grades 1-3 used for progressive disorder of the normal appearance.
- The inflammatory cell density was assessed using the H&E stained slides using an ordinal scale of 0-3 where 0=scattered cells; 1=few cells; 2=moderate cells; 3=abundant/confluent cells.
- Cellular staining was performed with the antibodies listed in Table 1. The whole of the available section was examined and an ordinal scale of 0-3 was used where 0=no/very few cells; 1=few cells; 2=moderate cells; 3=abundant/confluent cells.

Data analysis

Data were entered into Access 2007 (Microsoft) and analysed using STATA 11.0 (StataCorp LP, TX). Fisher's exact tests were used to determine the strength of association for the parameters graded according to case-control status.

Results

Study participants

Demographic and clinical characteristics of the participants are shown in Table 3. All of the cases had trichiasis, defined as at least one lash rubbing against the globe or evidence of recent epilation with a suggestive history. The majority of the cases were of Maasai ethnicity, while the controls were more evenly divided between different ethnic groups. Clinically visible conjunctival inflammation was very strongly associated with the presence of scarring. Lymphoid follicles, which are the clinical hallmark of active disease in children, were not seen in any of the participants. Infection with *C. trachomatis* was not detected in any of the participants. Surgery was performed on the right eye of 14 (40%) of the cases and 19 (58%) of the controls.

Table 3: Demographic and clinical characteristics

Parameter	Cases	Controls	p-value*
	N = 34	N = 33	
<u><i>Demographic Characteristics</i></u>			
Female [n (%)]	22 (64.7)	15 (45.5)	0.09
Age in years [\bar{u} (95%CI)]	69.6 (65.6-73.6)	67.1 (62.1-72.1)	0.52
Ethnicity [n (%)]			<0.001
Maasai	28 (82.3)	0 (0.0)	
Chagga	4 (11.8)	14 (42.4)	
Pare	0 (0.0)	8 (24.2)	
Other	2 (5.9)	11 (33.3)	
Any education [n (%)]	4 (12.5)	26 (86.7)	<0.001
<u><i>Clinical Characteristics</i></u>			
Scarring grade [n (%)]			
S0	- -	33 (100)	
S1a	0 0	- -	
S1b	0 0	- -	
S1c	6 (17.7)	- -	
S2	5 (14.7)	- -	
S3	23 (68.6)	- -	
Papillary inflammation grade [n (%)]			<0.001
P0	4 (11.8)	31 (93.9)	
P1	5 (14.7)	1 (3.0)	
P2	18 (52.9)	1 (3.0)	
P3	7 (20.6)	0 (0.0)	

* Using the Fisher's exact test, and the Wilcoxon ranked sum test for age.

Histological scarring

In healthy subepithelial tissue there could be seen short connective fibres running parallel to the surface in an ordered manner. In healthy tarsal tissue long connective tissue fibres passing between the meibomian glands could be seen, perpendicular to the surface, which terminated in shorter fibres running parallel to the surface, giving rise to a “T” appearance. On examination with cross polarised light all of the samples from control participants except for one had the “T-sign” visible in the tarsal connective tissue while all of the cases had some disorganisation of this appearance (Table 4). A similar pattern, although with slightly less well marked differentiation between cases and controls, was seen in the subepithelial connective tissue.

Table 4: Connective tissue scarring grade using polarised light

Scarring grade	Cases	Controls	p-value*
	n (%)	n (%)	
Subepithelial tissue	N = 29	N = 31	<0.001
0	3 (10.3)	26 (83.9)	
1	13 (44.8)	5 (16.1)	
2	12 (41.4)	0 (0.0)	
3	1 (3.5)	0 (0.0)	
Tarsal tissue	N=13 [†]	N=32	<0.001
0	0 (0.0)	31	
1	5 (38.5)	0 (0.0)	
2	6 (46.1)	1 (3.1)	
3	2 (15.4)	0 (0.0)	

* Using Fishers' exact test.

[†] Insufficient tarsal tissue limited the number available for grading.

Inflammatory cells

Cases had significantly more inflammatory cells than controls, assessed both with the H&E and CD45 stains. Table 5. A number of sections were noted to have a marked inflammatory cell infiltrate in which a large proportion of the cells were CD45 negative, Figure 12. The inflammatory cell infiltrate was analysed in relation to the presence of clinical inflammation (with significant inflammation defined as grades P2/3 and non significant inflammation as grades P0/1). This was restricted to cases only, as clinical inflammation was very strongly associated with case-control status. There was no significant difference for the H&E infiltrate ($p=0.59$) or the CD45 infiltrate ($p=0.38$) in inflamed vs non-inflamed cases, although the number of non-inflamed cases was small ($n=9$). The inflammatory infiltrates were more severe in non-inflamed cases compared to non-inflamed controls, for both the H&E infiltrate ($p=0.005$) and CD45 infiltrate ($p=0.001$).

Table 5: Inflammatory cell infiltrates

Parameter	Cases		Controls		p-value*
	n	(%)	n	(%)	
H&E inflammatory infiltrate	N=32		N=33		<0.001
0	0	(0.0)	16	(48.5)	
1	15	(46.9)	14	(42.4)	
2	8	(25.0)	3	(9.1)	
3	9	(28.1)	0	(0.0)	
Cellular CD45 staining	N=34		N=33		<0.001
0	6	(17.7)	21	(63.6)	
1	11	(32.3)	11	(33.3)	
2	9	(26.5)	0	(0.0)	
3	8	(23.5)	1	(3.0)	

* Using Fisher's exact test.

Specific immunohistochemical cell staining

Cases had significantly more CD8+, CD56+ and CD20+ cells than controls (Table 6). More than half of the cases had grade 2 for CD8+ cells compared to very few of the controls ($p=0.001$, none of the sections graded as 3). Almost a third of the cases were grade 2 for CD56+ cells compared to none of the controls ($p=0.001$), none of the sections were grade 3). Almost half of the cases had grades 2 or 3 for CD20+ cells compared to very few of the controls ($p=0.03$). Of borderline statistical significance, cases had marginally more CD3+ cells than controls. There was a significant association between the presence of CD8+ and CD56+ cells (Table 6). Neutrophils (which are generally easily apparent on histological sections without specific immunohistochemical staining) were very infrequent in either cases or controls and therefore no formal grading was undertaken.

Table 6: Specific cellular stains

Cellular stain	Cases	Controls	p-value*
	n (%)	n (%)	
CD3	N=33	N=33	0.06
0	16 (48.5)	20 (60.6)	
1	12 (36.4)	13 (39.4)	
2	5 (15.1)	0 (0.0)	
3	0 (0.0)	0 (0.0)	
CD4	N=33	N=32	0.36
0	10 (30.3)	6 (18.8)	
1	19 (57.6)	24 (75.0)	
2	4 (12.1)	2 (6.2)	
3	0 (0.0)	0 (0.0)	
CD8	N=33	N=32	0.001
0	0 (0.0)	1 (3.1)	
1	14 (42.4)	27 (84.4)	
2	19 (57.6)	4 (12.5)	
3	0 (0.0)	0 (0.0)	
CD20	N=32	N=33	0.03
0	8 (25.0)	13 (39.4)	
1	10 (31.3)	16 (48.5)	
2	10 (31.3)	4 (12.1)	
3	4 (12.5)	0	
CD56	N=20 [†]	N=31	0.001
0	8 (40.0)	10 (32.3)	
1	6 (30.0)	21 (67.7)	
2	6 (30.0)	0 (0.0)	

3	1 (4.2)	2 (6.7)	
CD68	N=33	N=33	0.33
0	23 (69.7)	23 (69.7)	
1	10 (30.3)	8 (24.2)	
2	0 (0.0)	2 (6.1)	
3	0 (0.0)	1 (0.0)	
CD83	N=32	N=33	0.68
0	6 (18.8)	8 (24.2)	
1	16 (50.0)	16 (48.5)	
2	10 (31.2)	8 (24.2)	
3	0 (0.0)	1 (3.0)	

* Using Fisher's exact test.

† A number of the sections were no longer available for CD56 staining owing to limited sample.

Discussion

In this study we have characterised in detail the morphological and cellular changes found in trachomatous scarring. Scarring was found to be associated with marked infiltrates of CD8+ and CD56+ cells compared to controls. CD56 is a marker for natural killer (NK) cells, although usually in combination with other phenotypic markers of cell lineage.²⁵⁻²⁷ The CD8 antigen can be expressed by both T-cells and NK cells.²⁶ If the identified cells were CD8+ T-cells they would be expected to co-express CD3. However, there was a marked lack of CD3+ cells relative to CD8+ cells. This suggests that the increased CD8+ cells found in scarred conjunctiva may be NK cells. There was a significant association between CD8+ and CD56+ infiltrates, Table 7 ($p=0.03$ with Fisher's exact test). These results overall support the finding that scarred conjunctiva in trachoma contains a prominent NK cell infiltrate. The CD8 and CD56 stains were done on sections from different ends of the biopsy sample which might explain their association not being stronger.

Table 7: Comparison of CD8 and CD56 cellular grading

		CD56			Total
		0	1	2	
CD8	0	1	0	0	1
	1	12	20	1	33
	2	5	7	5	17
Total		18	27	6	51

Fisher's exact test = 0.03

NK cells represent around 10-15% of circulating lymphocytes and were historically identified as granular lymphocytes that can lyse target cells without previous sensitisation.^{25, 27} They are generally considered to be part of the innate immune response as they lack the fine antigen specificity of T and B-cells and respond rapidly to bacterial, viral and parasitic infections through a variety of pattern recognition receptors.²⁸ They can also have a regulatory role on both innate and adaptive immunity through the production of cytokines and pro-inflammatory mediators, notably interferon gamma (IFN γ). More recently, a form of NK cell adaptive memory to diverse antigens has been described.²⁹ NK cells lack a single defining genetic or phenotypic characteristic and share considerable overlap with cytotoxic CD8+ T-cells.²⁶ While NK cells are usually described as being CD3 negative, CD3 subunit chains may be identified with immunohistochemistry.

Until recently NK cells had received relatively little attention in trachoma research. However, a microarray study of active disease in children found extensive evidence for enrichment of genes in pathways that regulate NK cell activation and cytotoxicity.⁹ NK cells have been found to be a major source of IFN γ , a key cytokine in the immune response to *C. trachomatis* infection, in trachomatous patients.³⁰ Infection of epithelial cell lines with *C. trachomatis* render them susceptible to NK cell lysis and a murine model of *C. trachomatis* infection found NK cell depletion to exacerbate the course of infection.³¹⁻³³ While the results of the present study require confirmation they indicate that NK cells may be important in the development of scarring complications. Repeated *C. trachomatis* infection may cause a pathological NK cell response resulting in tissue damage either through a direct cytolytic effect or through the production of cytokines and related molecules. This would be consistent with recent studies pointing towards the importance of innate immune responses in the pathogenesis of trachoma and warrants further investigation into the role of NK cells.^{7, 9, 10}

Some of the findings in our study contrast with two previous immunohistological studies on biopsy samples from subjects with trachomatous scarring. Both found increased T-cell

populations in scarred tissue and suggested that in inflamed cases these were predominantly CD4+ T-cells and in non-inflamed cases predominantly CD8+ T-cells.^{12, 14} However, these studies had a number of methodological and analytical differences which may explain the discrepancy with our conclusions. The first study recruited only three control participants whose demographic details were not presented; the grading system used was not defined; only limited data was presented and no significance testing was performed.¹² The second study appears to have been performed in a non-trachoma endemic region; it also utilised only three control samples which were collected post-mortem after various causes of death; cases were divided into inflamed or non-inflamed on the basis of the number of immunohistochemically stained cells present in relation to control samples (rather than clinical status); and limited data was presented since statistical tests for significance were not presented and would not have been appropriate with such a limited sample size.¹⁴ Other studies looking at cell populations in trachomatous scarring have not included control tissue or presented quantitative data.^{11, 19}

We also found evidence that trachomatous scarring is associated with increased numbers of CD20+ B-cells. Anti-chlamydial antibodies have been found in tears and sera of both children with active disease and adults with scarring. Whether these are protective, or simply markers of previous infection, is not known.³⁴⁻³⁷ Animal models of genital tract infection have supported the role of humoral immunity in protection against re-infection.³⁸⁻⁴⁰

We found no evidence suggestive of increased T-helper cells (CD4+), macrophages (CD68+) or neutrophils in scarring. The presence of neutrophils tends to be short-lived, however, and it is possible that a significant neutrophil presence may not have been detected by our analysis. There was also no difference in the levels of cells expressing CD83+, a marker of mature dendritic cells. However, dendritic cell immunophenotyping is complex. This normally requires a combination of staining intensity coupled with positive and negative markers in order to confidently identify specific DC phenotypes. This was beyond

the scope of this study due to the limited amount of biopsy tissue and the total number of immunohistochemical markers used. A marked inflammatory cell infiltrate was seen in biopsies from individuals with scarring which could not be accounted for by the specific stains and increased numbers of CD8+, CD56+ and CD20+ cells. It was also notable that in a number of cases there were numerous CD45 negative inflammatory/immune cells present. We had not anticipated this finding based on previous studies as we had expected most or all of the inflammatory cells present to be positive for CD45 which is expressed on nearly all nucleated cells of hematopoietic origin.⁴¹ The identity of these CD45 negative cells infiltrating scarred tissue remains an enigma. However, one of several potential explanations might be the induction of follicular dendritic cells, which are non-hematopoietic in origin and associated with lymphoid follicle formation.^{42, 43}

Conjunctival inflammation is probably on the causal pathway to the development and progression of scarring complications in trachoma and we found the presence of scarring to be very strongly associated with clinical inflammation.⁴⁴⁻⁴⁸ Of interest, our data showed that cases with more clinical inflammation did not have increased histological cellular infiltrates compared to less inflamed cases. Non-inflamed cases did, however, have increased infiltrates compared to non-inflamed controls. While there were small numbers involved in these comparisons, they do suggest that the scarring itself is associated with inflammatory/immune cell infiltration, rather than simply being part of a general inflammatory response.

This study benefitted from including a sizeable number of control participants who were well matched for age. The socio-demographic background of the controls was probably different to the cases, as reflected in the different educational levels. However, many of the controls were identified through outreach programmes in rural areas where trachoma is typically found and most had had the cost of their surgery subsidised. Identifying control subjects with a completely identical background to scarred trachoma cases is challenging as often the

majority of older adults have some scarring in a trachoma-endemic area. The inclusion of control participants has allowed us to compare the normal pattern of conjunctival immune cells to that found in scarring trachoma. This comparison is essential for interpretation of diseased tissue, especially in the regions where trachoma is found as these tend to have a relatively high prevalence of conjunctival bacterial infection.^{23, 49} Studies of normal conjunctival cell populations have found various inflammatory/immune cells are normally present with T cells most commonly found, but also B-cells, macrophages, NK cells, neutrophils and dendritic cells.⁵⁰⁻⁵³ Varying proportions of CD4+:CD8+ cells have been found depending on the study and conjunctival location, but with overall roughly equal numbers, or a slight predominance of CD8+ cells, in the tarsal stroma.⁵⁰⁻⁵³ In this study we found a predominance of CD8+ cells over CD4+ cells in controls.

Quantification of tarsal conjunctival scarring is not straight-forward with a paucity of robust grading systems in the literature. In this study we developed a novel system for grading both the sup-epithelial and tarsal connective tissue using cross polarised light. This allowed us to directly visualise collagen fibres and the grading closely corresponded to the clinical status. The association was particularly strong for grading the tarsal connective tissue where the fibres were longer and could be more easily visualised.

We chose to use an ordinal scale for grading of the sections with the observer masked to the clinical status. A commonly employed alternative form of analysis involves cell counts on representative fields. However, the choice of fields is open to bias unless done in a random manner, and this method also restricts the amount of tissue analysed.

In conclusion, our study found evidence of a NK cell infiltrate in scarring trachoma and lends further support to studies implicating innate immune responses in the pathogenesis of trachoma. Scarred tissue was also infiltrated by large numbers of CD45 negative cells and further work is required to characterise these cells.

References

1. <http://www.who.int/blindness/causes/priority/en/>.
2. Hu VH, Harding-Esch EM, Burton MJ, Bailey RL, Kadimpeul J, Mabey DC. Epidemiology and control of trachoma: systematic review. *Trop Med Int Health* 2010;15:673-691.
3. Silverstein AM. The immunologic modulation of infectious disease pathogenesis. Friedenwald Lecture, 1973. *Invest Ophthalmol* 1974;13:560-574.
4. Brunham RC, Rey-Ladino J. Immunology of Chlamydia infection: implications for a Chlamydia trachomatis vaccine. *Nat Rev Immunol* 2005;5:149-161.
5. Stephens RS. The cellular paradigm of chlamydial pathogenesis. *Trends Microbiol* 2003;11:44-51.
6. Darville T, Hiltke TJ. Pathogenesis of genital tract disease due to Chlamydia trachomatis. *J Infect Dis* 201 Suppl 2:S114-125.
7. Lacy HM, Bowlin AK, Hennings L, Scurlock AM, Nagarajan UM, Rank RG. Essential role for neutrophils in pathogenesis and adaptive immunity in Chlamydia caviae ocular infections. *Infect Immun* 2011;79:1889-1897.
8. Darville T, O'Neill JM, Andrews CW, Jr., Nagarajan UM, Stahl L, Ojcius DM. Toll-like receptor-2, but not Toll-like receptor-4, is essential for development of oviduct pathology in chlamydial genital tract infection. *J Immunol* 2003;171:6187-6197.
9. Natividad A, Freeman TC, Jeffries D, et al. Human conjunctival transcriptome analysis reveals the prominence of innate defense in Chlamydia trachomatis infection. *Infect Immun* 2010;78:4895-4911.
10. Burton MJ, Rajak SN, Bauer J, et al. Conjunctival transcriptome in scarring trachoma. *Infect Immun* 2011;79:499-511.
11. Abrahams C, Ballard RC, Sutter EE. The pathology of trachoma in a black South African population. Light microscopical, histochemical and electron microscopical findings. *S Afr Med J* 1979;55:1115-1118.
12. Burd EM, Tabbara KF, Nasr AM, Taylor PB. Conjunctival lymphocyte subsets in trachoma. *Int Ophthalmol* 1988;12:53-57.
13. el-Asrar AM, Van den Oord JJ, Geboes K, Missotten L, Emarah MH, Desmet V. Immunopathology of trachomatous conjunctivitis. *Br J Ophthalmol* 1989;73:276-282.
14. Reacher MH, Pe'er J, Rapoza PA, Whittum-Hudson JA, Taylor HR. T cells and trachoma. Their role in cicatricial disease. *Ophthalmology* 1991;98:334-341.
15. al-Rajhi AA, Hidayat A, Nasr A, al-Faran M. The histopathology and the mechanism of entropion in patients with trachoma. *Ophthalmology* 1993;100:1293-1296.
16. Abu el-Asrar AM, Geboes K, Tabbara KF, al-Kharashi SA, Missotten L, Desmet V. Immunopathogenesis of conjunctival scarring in trachoma. *Eye* 1998;12 (Pt 3a):453-460.
17. Abu el-Asrar AM, Geboes K, al-Kharashi SA, Tabbara KF, Missotten L. Collagen content and types in trachomatous conjunctivitis. *Eye* 1998;12 (Pt 4):735-739.
18. Abu el-Asrar AM, Geboes K, al-Kharashi SA, et al. An immunohistochemical study of collagens in trachoma and vernal keratoconjunctivitis. *Eye* 1998;12 (Pt 6):1001-1006.
19. Guzey M, Ozardali I, Basar E, Aslan G, Satici A, Karadede S. A survey of trachoma: the histopathology and the mechanism of progressive cicatrization of eyelid tissues. *Ophthalmologica* 2000;214:277-284.
20. El-Asrar AM, Geboes K, Al-Kharashi SA, et al. Expression of gelatinase B in trachomatous conjunctivitis. *Br J Ophthalmol* 2000;84:85-91.
21. Abu El-Asrar AM, Al-Kharashi SA, Missotten L, Geboes K. Expression of growth factors in the conjunctiva from patients with active trachoma. *Eye* 2006;20:362-369.
22. Dawson C, Jones B, Tarizzo M. Guide to trachoma control in programmes for the prevention of blindness. Geneva: World Health Organization; 1981.
23. Hu VH, Massae P, Weiss HA, et al. Bacterial infection in scarring trachoma. *Invest Ophthalmol Vis Sci* 2011;52:2181-2186.

24. Hu VH, Weiss HA, Massae P, et al. In Vivo Confocal Microscopy in Scarring Trachoma. *Ophthalmology* 2011.
25. Freud AG, Caligiuri MA. Human natural killer cell development. *Immunol Rev* 2006;214:56-72.
26. Morice WG. The immunophenotypic attributes of NK cells and NK-cell lineage lymphoproliferative disorders. *Am J Clin Pathol* 2007;127:881-886.
27. Caligiuri MA. Human natural killer cells. *Blood* 2008;112:461-469.
28. Empson VG, McQueen FM, Dalbeth N. The natural killer cell: a further innate mediator of gouty inflammation? *Immunol Cell Biol* 2010;88:24-31.
29. Paust S, von Andrian UH. Natural killer cell memory. *Nat Immunol* 2011;12:500-508.
30. Gall A, Horowitz A, Joof H, et al. Systemic effector and regulatory immune responses to chlamydial antigens in trichomatous trichiasis. *Front Microbiol* 2011;2:10.
31. Tseng CT, Rank RG. Role of NK cells in early host response to chlamydial genital infection. *Infect Immun* 1998;66:5867-5875.
32. Hook CE, Telyatnikova N, Goodall JC, et al. Effects of Chlamydia trachomatis infection on the expression of natural killer (NK) cell ligands and susceptibility to NK cell lysis. *Clin Exp Immunol* 2004;138:54-60.
33. Hook CE, Matyszak MK, Gaston JS. Infection of epithelial and dendritic cells by Chlamydia trachomatis results in IL-18 and IL-12 production, leading to interferon-gamma production by human natural killer cells. *FEMS Immunol Med Microbiol* 2005;45:113-120.
34. Collier LH, Sowa J, Sowa S. The serum and conjunctival antibody response to trachoma in Gambian children. *J Hyg (Lond)* 1972;70:727-740.
35. Maythar B, Zakay-Rones Z. Local and humoral chlamydial antibodies in trachoma patients of different age groups. *Invest Ophthalmol* 1972;11:651-654.
36. Holland MJ, Bailey RL, Hayes LJ, Whittle HC, Mabey DC. Conjunctival scarring in trachoma is associated with depressed cell-mediated immune responses to chlamydial antigens. *J Infect Dis* 1993;168:1528-1531.
37. Bailey RL, Kajbaf M, Whittle HC, Ward ME, Mabey DC. The influence of local antichlamydial antibody on the acquisition and persistence of human ocular chlamydial infection: IgG antibodies are not protective. *Epidemiol Infect* 1993;111:315-324.
38. Morrison SG, Su H, Caldwell HD, Morrison RP. Immunity to murine Chlamydia trachomatis genital tract reinfection involves B cells and CD4(+) T cells but not CD8(+) T cells. *Infect Immun* 2000;68:6979-6987.
39. Morrison SG, Morrison RP. Resolution of secondary Chlamydia trachomatis genital tract infection in immune mice with depletion of both CD4+ and CD8+ T cells. *Infect Immun* 2001;69:2643-2649.
40. Morrison SG, Morrison RP. A predominant role for antibody in acquired immunity to chlamydial genital tract reinfection. *J Immunol* 2005;175:7536-7542.
41. Woodford-Thomas T, Thomas ML. The leukocyte common antigen, CD45 and other protein tyrosine phosphatases in hematopoietic cells. *Semin Cell Biol* 1993;4:409-418.
42. Aguzzi A, Krautler NJ. Characterizing follicular dendritic cells: A progress report. *Eur J Immunol* 2010;40:2134-2138.
43. Munoz-Fernandez R, Blanco FJ, Frecha C, et al. Follicular dendritic cells are related to bone marrow stromal cell progenitors and to myofibroblasts. *J Immunol* 2006;177:280-289.
44. West SK, Munoz B, Mkocha H, Hsieh YH, Lynch MC. Progression of active trachoma to scarring in a cohort of Tanzanian children. *Ophthalmic Epidemiol* 2001;8:137-144.
45. Dawson CR MR, Daghfous R, Juster R, Schachter J. What clinical signs are critical in evaluating the impact of intervention in trachoma? Chlamydia Infections. *Proceedings of the Seventh International Symposium on Human Chlamydial Infections*. London: Cambridge University Press; 1990:271-275.
46. Munoz B, Bobo L, Mkocha H, Lynch M, Hsieh YH, West S. Incidence of trichiasis in a cohort of women with and without scarring. *Int J Epidemiol* 1999;28:1167-1171.

47. Burton MJ, Bowman RJ, Faal H, et al. The long-term natural history of trachomatous trichiasis in the Gambia. *Invest Ophthalmol Vis Sci* 2006;47:847-852.
48. Wolle MA, Munoz BE, Mkocha H, West SK. Constant ocular infection with *Chlamydia trachomatis* predicts risk of scarring in children in Tanzania. *Ophthalmology* 2009;116:243-247.
49. Burton MJ, Kinteh F, Jallow O, et al. A randomised controlled trial of azithromycin following surgery for trachomatous trichiasis in the Gambia. *Br J Ophthalmol* 2005;89:1282-1288.
50. Sacks EH, Wieczorek R, Jakobiec FA, Knowles DM, 2nd. Lymphocytic subpopulations in the normal human conjunctiva. A monoclonal antibody study. *Ophthalmology* 1986;93:1276-1283.
51. Hingorani M, Metz D, Lightman SL. Characterisation of the normal conjunctival leukocyte population. *Exp Eye Res* 1997;64:905-912.
52. Bhan AK, Fujikawa LS, Foster CS. T-cell subsets and Langerhans cells in normal and diseased conjunctiva. *Am J Ophthalmol* 1982;94:205-212.
53. Soukiasian SH, Rice B, Foster CS, Lee SJ. The T cell receptor in normal and inflamed human conjunctiva. *Invest Ophthalmol Vis Sci* 1992;33:453-459.

Figure 1: Example grading photos for the histological grading of connective tissue scarring in the conjunctival subepithelial tissue using cross polarized light. The top images shows collagen fibres parallel with the surface found in normal tissue (arrows) and is graded 0. Subsequent images show progressive disorganisation of this appearance, grades 1-3. Original magnification $\times 100$.




Figure 2: Example grading photos for the histological grading of connective tissue scarring in the tarsal tissue using cross polarized light. The top image shows long collagen fibres between the meibomian glands which join shorter fibres next to the stroma forming a “T” sign in normal tissue (arrow), which is graded 0. Subsequent images show progressive disorganisation of this appearance, grades 1-3. Original magnification $\times 100$.

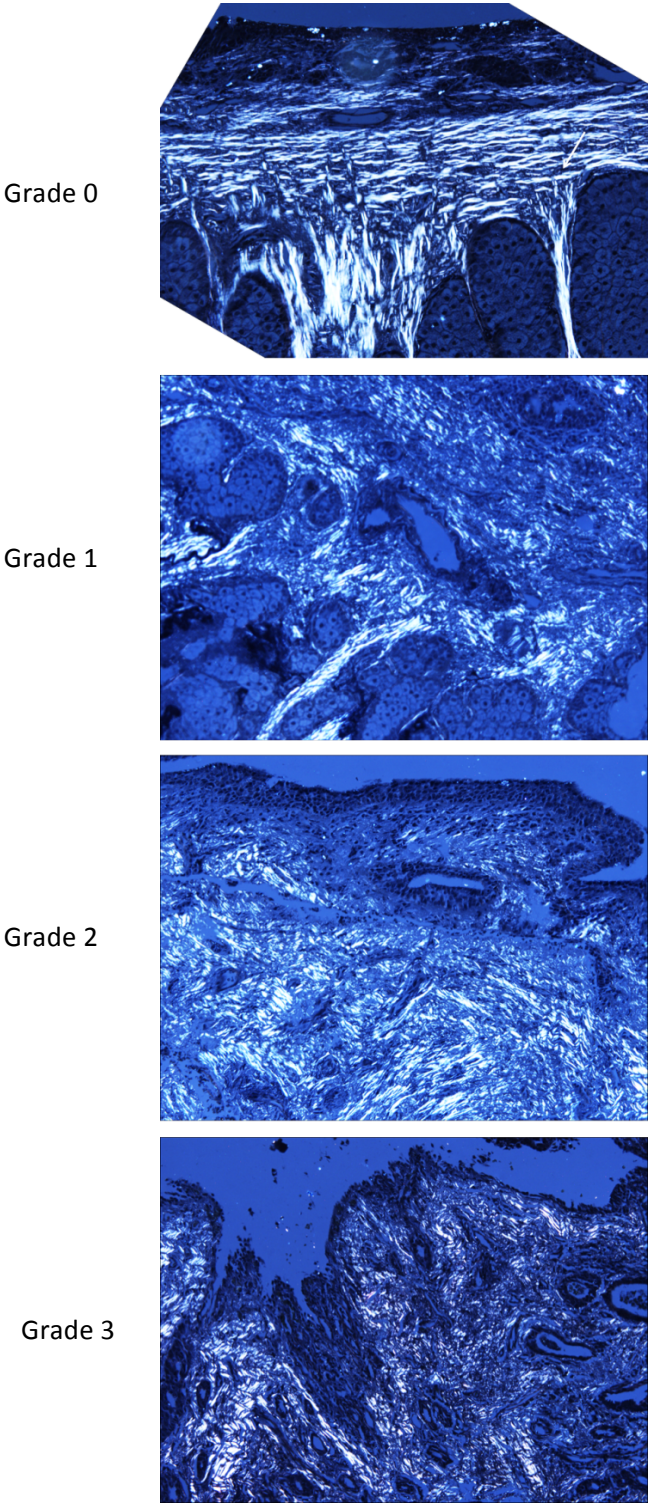
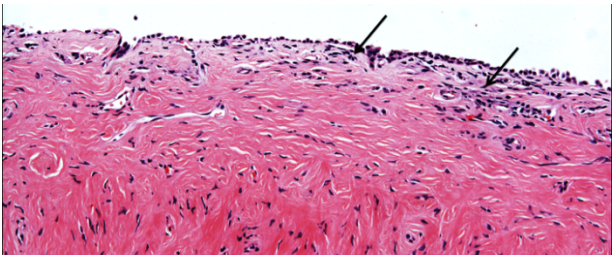
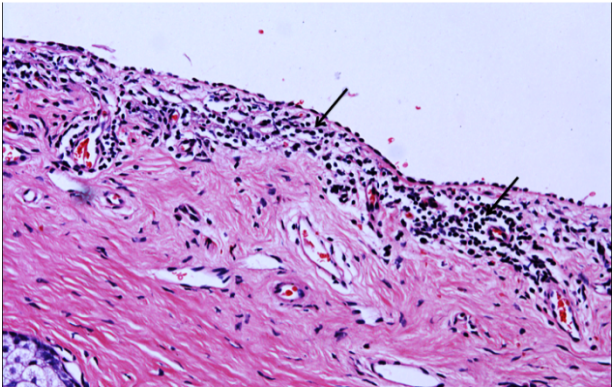


Figure 3: Example grading photos for the inflammatory cell infiltrate on the hematoxylin and eosin stain in the sub-epithelium (arrows). Original magnification $\times 200$.

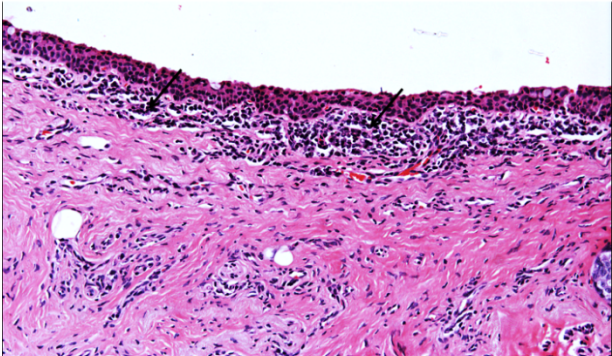
Grade 0



Grade 1



Grade 2



Grade 3

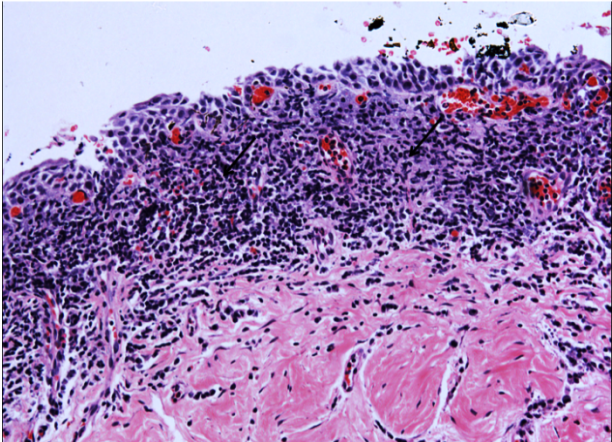
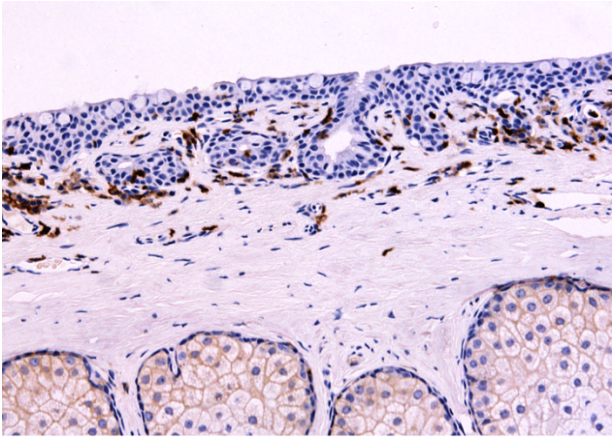
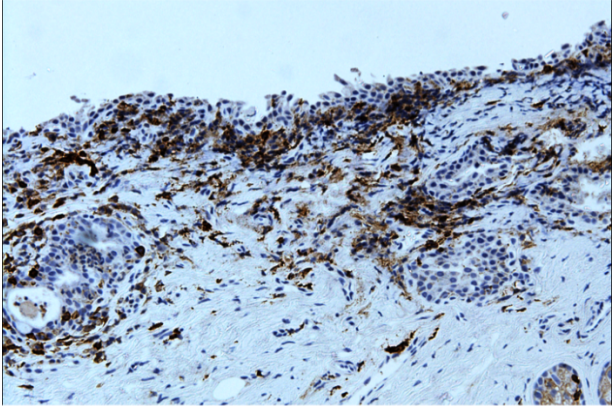


Figure 4: Example grading photos for CD45+ cells in the sub-epithelium (stained brown). Original magnification $\times 200$.

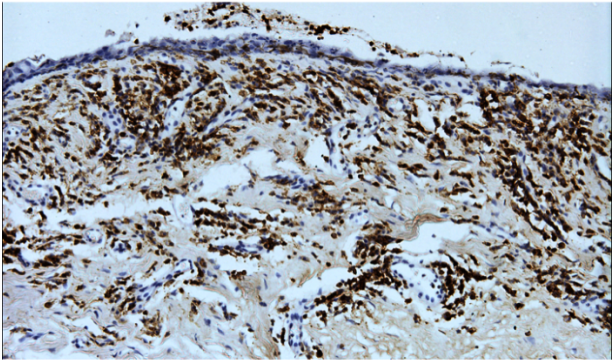
Grade 0



Grade 1



Grade 2



Grade 3

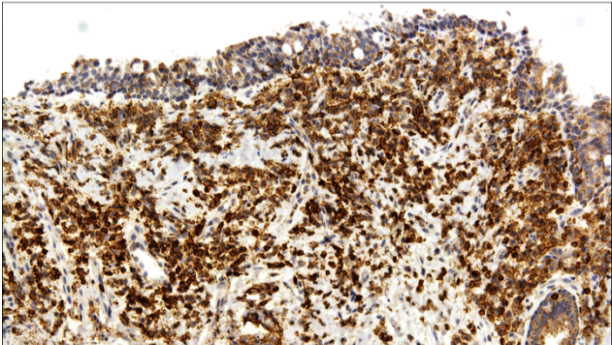
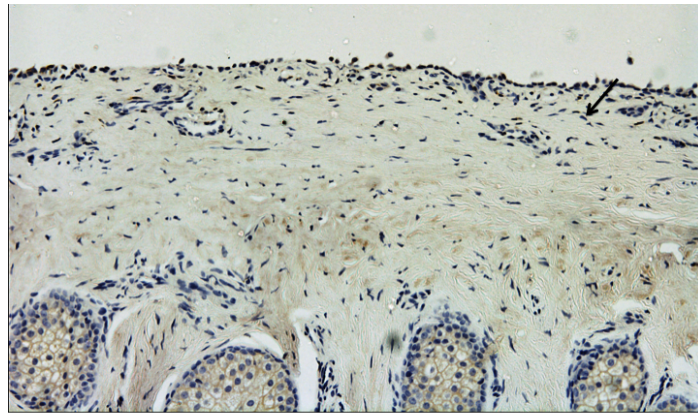
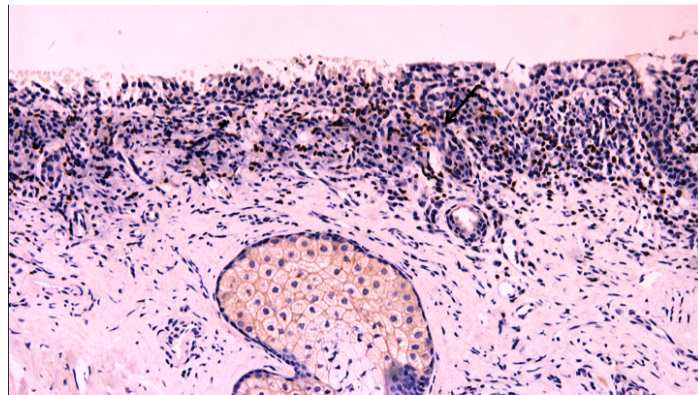


Figure 5: Example grading photos for the CD3+ cells in the sub-epithelium (stained brown). No section was given a grade 3. A proportion of the inflammatory/immune cells present are CD3 negative and do not stain with the brown chromagen (arrows). Original magnification $\times 200$.

Grade 0



Grade 1



Grade 2

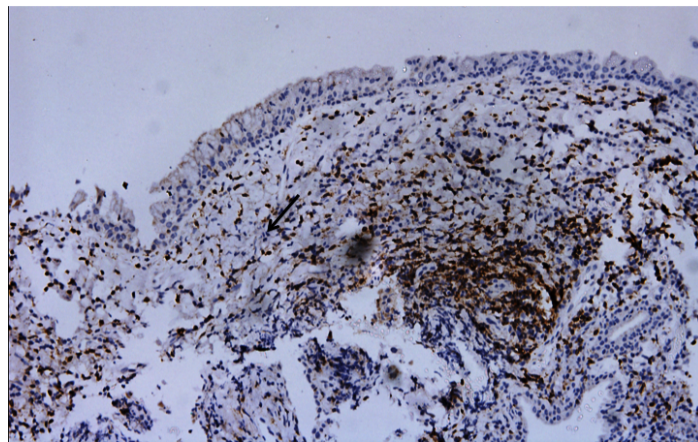
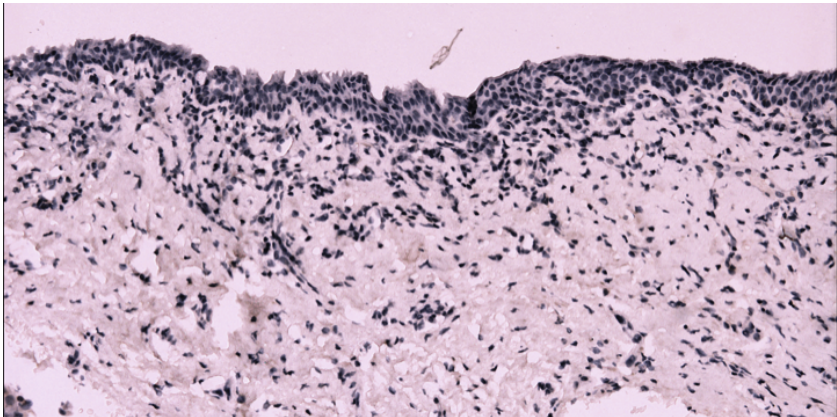
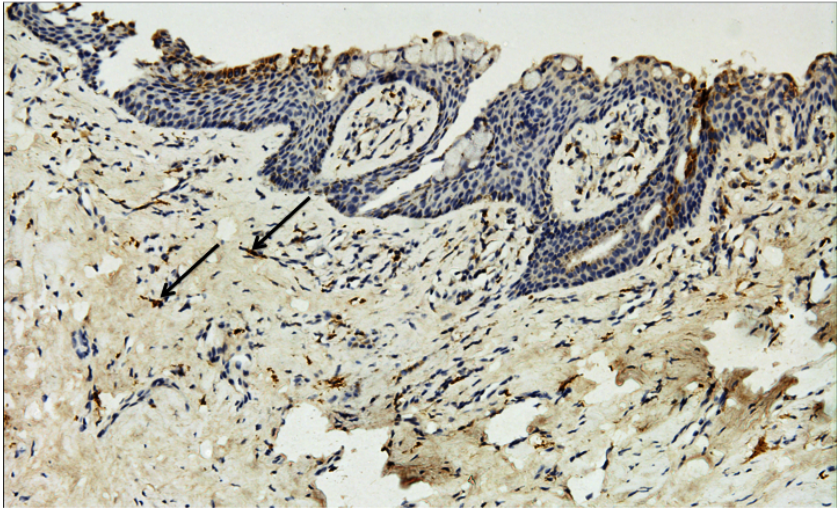


Figure 6: Example grading photos for the CD4+ cells in the sub-epithelium (stained brown, arrows). No section was given a grade 3. Original magnification $\times 200$.

Grade 0



Grade 1



Grade 2

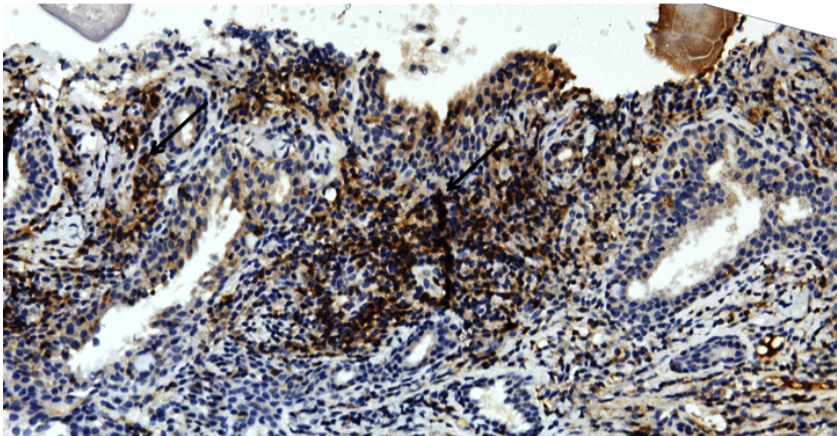
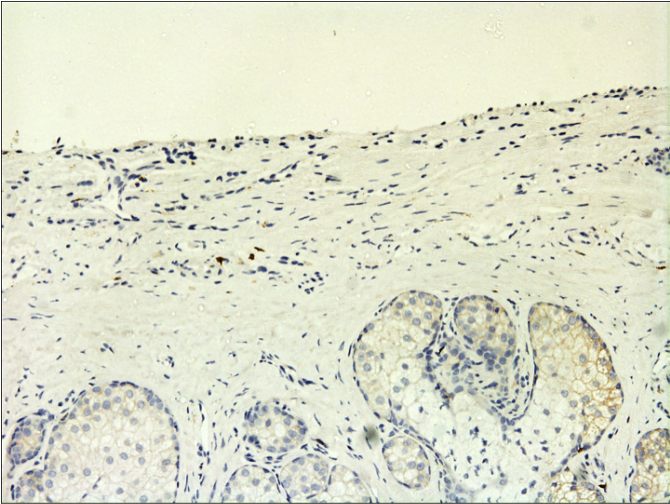
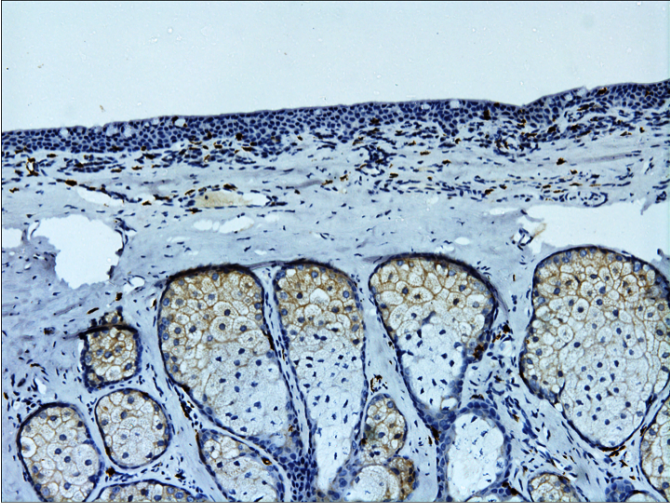


Figure 7: Example grading photos for the CD8+ cells in the sub-epithelium (stained brown). No section was given a grade 3. Original magnification $\times 200$.

Grade 0



Grade 1



Grade 2


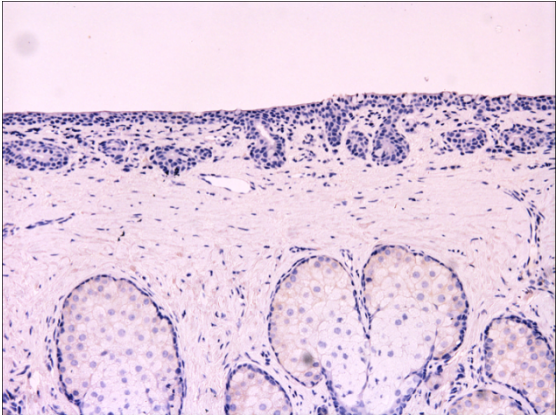
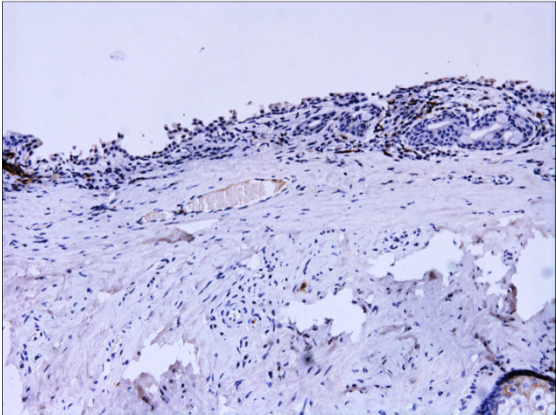


Figure 8: Example grading photos for the CD20+ cells in the sub-epithelium (stained brown). Original magnification $\times 200$.

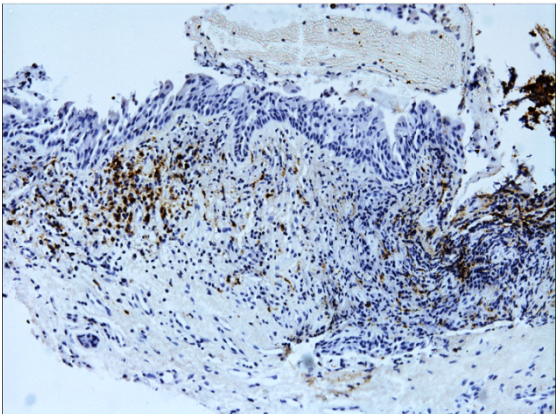
Grade 0



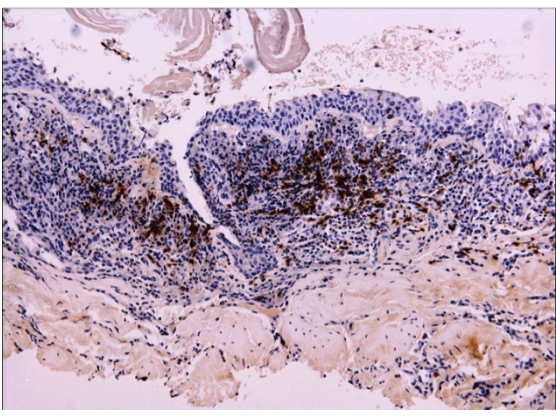
Grade 1



Grade 2



Grade 3



The sections stained for CD20+ cells also showed focal collections of cells. The below is an example of a focal collection of cells given a grade 3. Original magnification $\times 200$.

Grade 3 (focal)

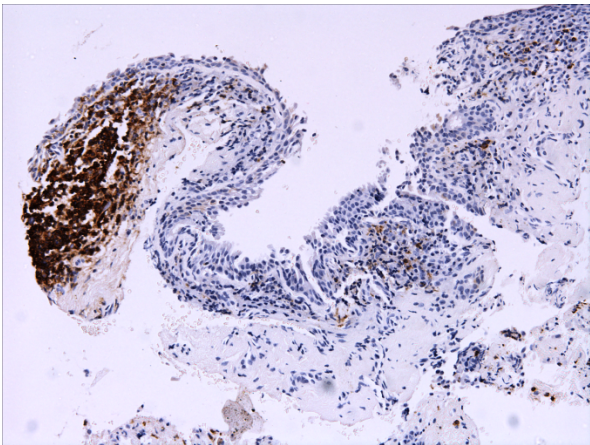
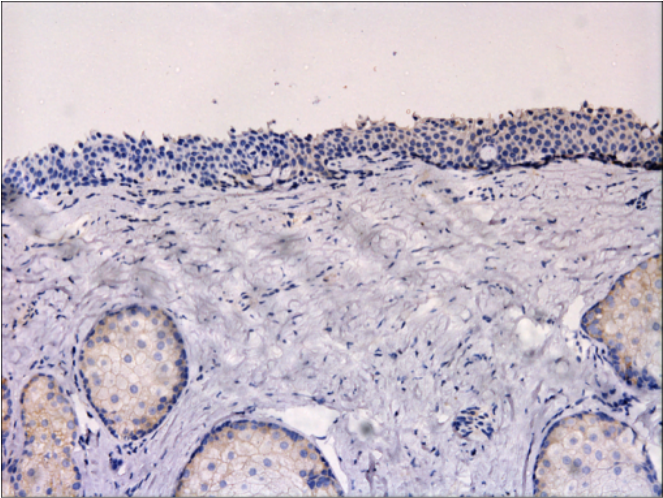
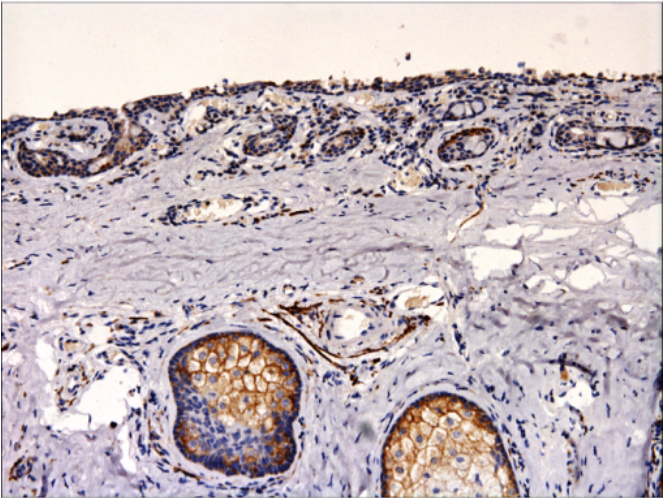


Figure 9: Example grading photos for the CD56+ cells in the sub-epithelium (stained brown). No section was given a grade 3. Original magnification $\times 200$.

Grade 0



Grade 1



Grade 2

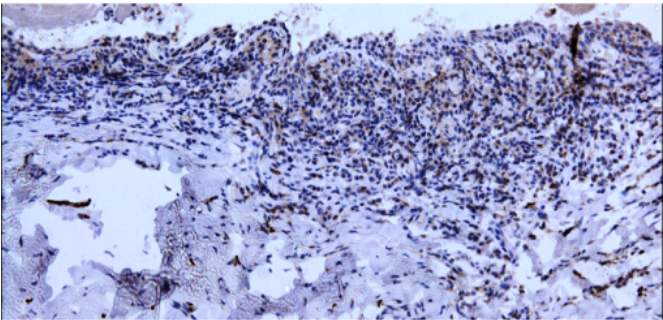
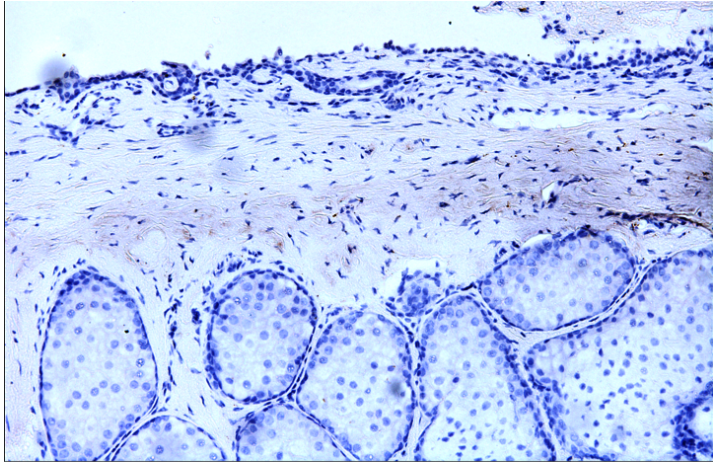
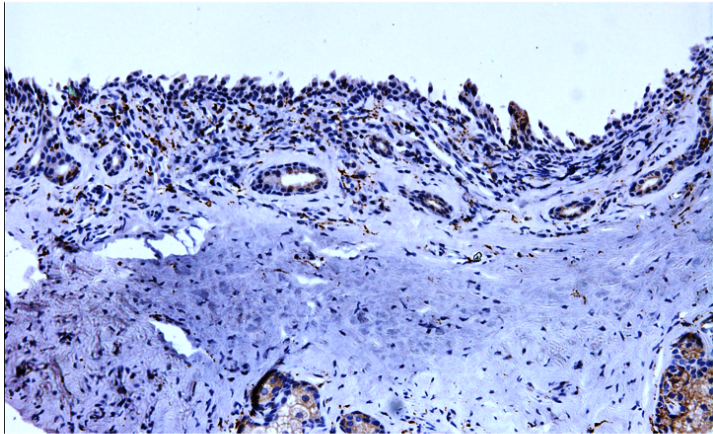


Figure 10: Example grading photos for the CD68+ cells in the sub-epithelium (stained brown). No section was given a grade 3. Original magnification $\times 200$.

Grade 0



Grade 1



Grade 2

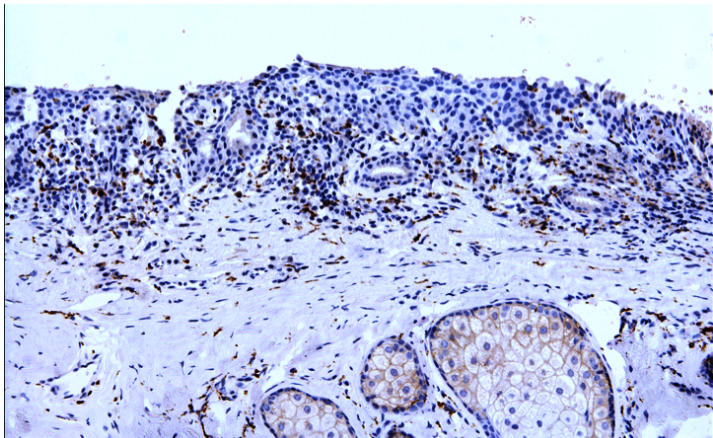
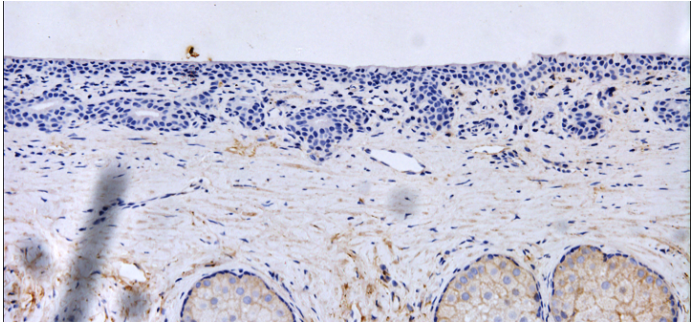
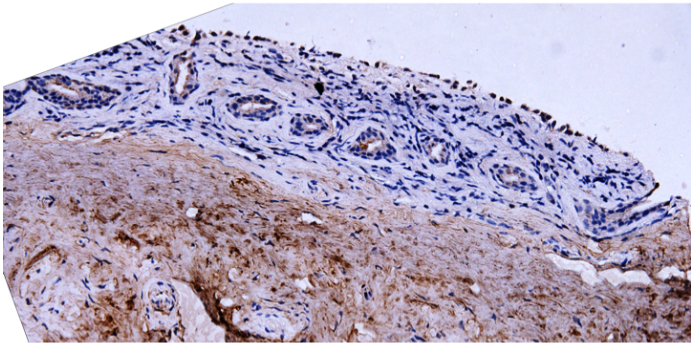


Figure 11: Example grading photos for the CD83+ cells in the sub-epithelium (stained brown). Original magnification $\times 200$.

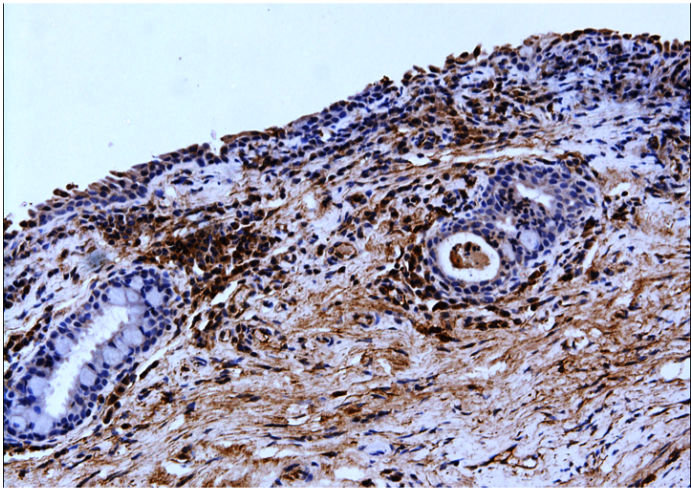
Grade 0



Grade 1



Grade 2



Grade 3

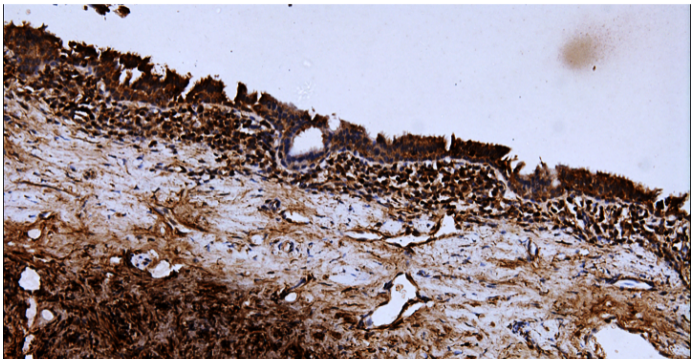
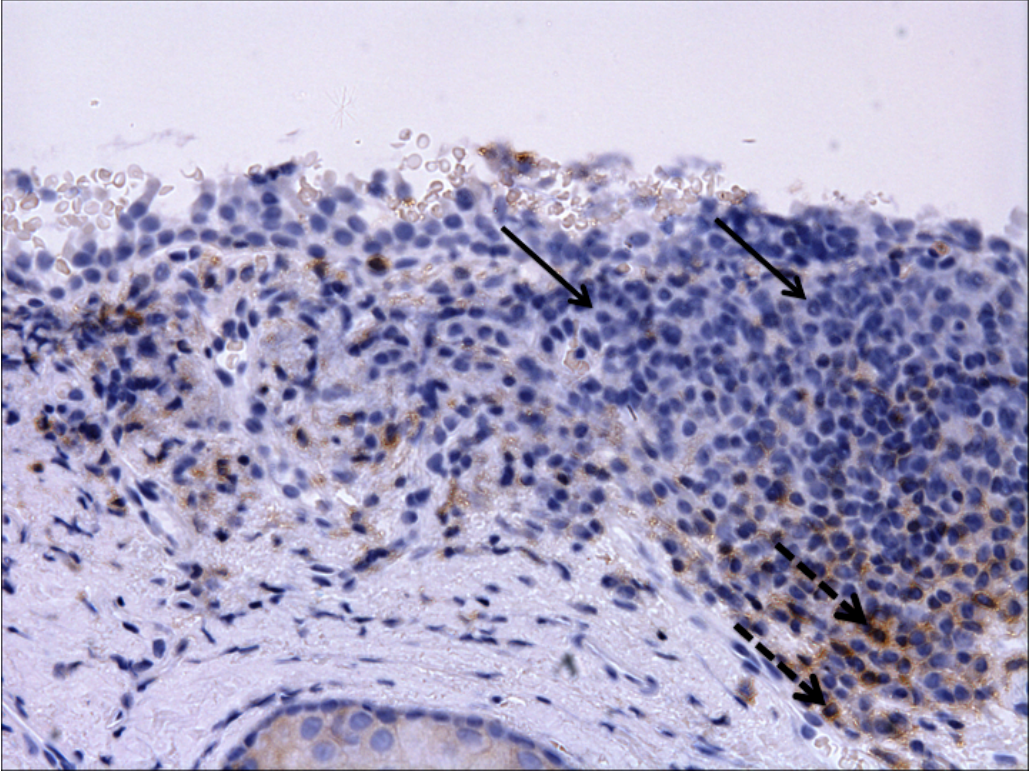
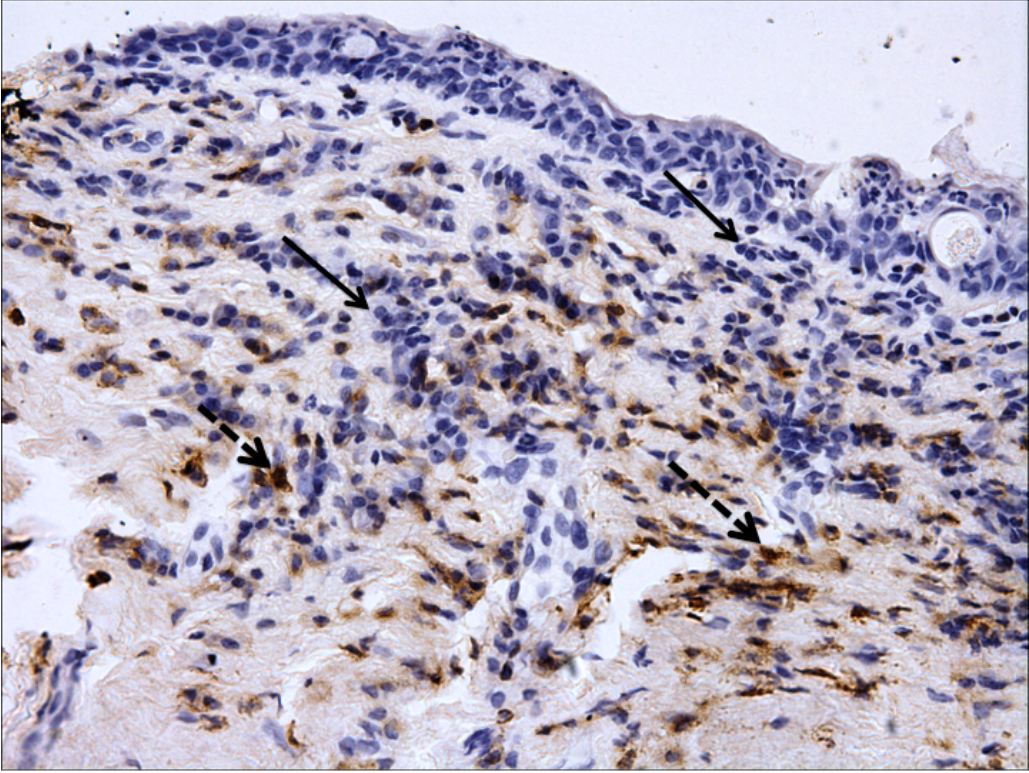


Figure 12: CD45 negative inflammatory/immune cells. (CD45 negative cells indicated by arrows; CD45+ cells staining brown indicated by broken arrows). Original magnification $\times 400$.



Chapter 14

Overall conclusions and future work



General discussion drawn from all of the contributing work including details of ongoing projects and potential future studies

Trachoma remains a major public health problem worldwide. Using data from 2002 the WHO estimated that 1.3 million people were blind from trachoma.¹ However, there was an even larger number blind from “corneal opacities”, much of which may be attributed to trachoma. Many more people suffer from serious visual impairment as a result of trachoma including those with constant ocular discomfort from trichiatic lashes abrading the cornea. There does appear to have been encouraging reductions in the number of children with active disease over the last few decades. However, there are still estimated to be 40 million affected at any one time and these children are at risk of future cicatricial complications. There has not been a corresponding reduction in the numbers estimated to have trichiasis. Trachoma is still very prevalent in poor, under-resourced areas such as Ethiopia and Sudan. The aim of this work was to further our understanding of the pathogenesis of trachomatous scarring with the objective of informing current trachoma control strategies and aiding in the development of future interventions to reduce blindness.

Innate immune responses

Both of the case-control studies employed in this work found evidence that innate immune responses are associated with trachomatous scarring. Gene expression data from the Trachomatous Scarring (TS) study found that cases had increased expression of the innate molecules *S100A7*, *DEFB4A* and *CXCL5* and the pro-inflammatory mediators *TNF α* and *IL1B*. The Trachomatous Trichiasis (TT) biopsy study indicated that scarred conjunctiva contains a greater infiltrate of Natural Killer (NK) cells than control tissue. NK cells respond to pathogens through pattern recognition receptors and are generally considered to be part of the innate immune response. These findings are consistent with recent transcriptome studies from The Gambia and Ethiopia, in children and adults, which found enrichment of innate pathways including NK cell related transcripts.^{2,3} Animal models of ocular and genital *C. trachomatis* infection and *in vitro* studies have also indicated that innate immune responses play an important role in tissue damage and the development of fibrotic complications.⁴⁻⁷ The role of NK cells in the development and progression of scarring requires further investigation. The function of these cells is still being studied but range from direct lysis of infected cells as an early response to the release of mediators that shape T and B cell responses. The possibility of an NK cell-based adaptive immunity which is independent of the recombination-activating gene (RAG) associated antigen receptors seen in T and B cells has challenged the way we think about immune memory. NK cells are a major source of IFN γ in response to *C. trachomatis* elementary bodies and it is likely that they are activated as part of the initial, innate response to infection. Our work suggests that they are also involved in mediating tissue damage. The LSHTM Trachoma Study Group is

planning further work including *in vitro* examination of NK cells responses to *C. trachomatis* elementary bodies in relation to trachomatous scarring phenotype.

There is good evidence that clearance of *C. trachomatis* infection relies on a Th1 response involving IFN γ . We were interested in examining the hypothesis that a predominantly Th2 response is associated with scarring, one that has gained some support in the literature. However, scarring was not associated with increased IL13 expression, but there was actually evidence of increased Th1 activity. This is consistent with a lack of Th2 polarisation in microarray studies.^{2, 3}

Understanding the immunopathology of trachoma is important in the rational development of a vaccine. A safe and effective vaccine would help prevent future children being infected and may help to reduce re-infection in those previously infected, thereby having beneficial effects on scarring progression. It could also have potential benefit in the control of genital tract infection, also a very major public health problem. Trachoma vaccine studies using inactivated whole elementary bodies gave protection little better than natural immunity and may have resulted in more severe disease. Understanding the immunobiology of the disease will help in the choice of antigen or antigen combination and the adjuvant used, and also in the detection of immunopathological responses.

Modification of the extra-cellular matrix (ECM)

Strong evidence was found for differential expression of various modifiers of the ECM in trachomatous scarring including matrix metalloproteinases (MMPs) and *SPARCL*. The expression of *SPARCL* showed the greatest fold change of all of the genes examined, being found 16 \times less in scarred cases with inflammation, and half as much in scarred cases without inflammation, compared to controls. These findings are consistent with previous gene expression and polymorphism studies.^{2, 8-11} A potential avenue of investigation is to alter the pro-fibrotic environment found in trachoma with the aim of reducing progression of the scarring process. Anti-fibrotic agents after glaucoma surgery have included the use of MMP inhibitors.¹² An agent such as doxycycline, which can inhibit MMP function and is also anti-chlamydial, might be a realistic agent for use in trachoma studies, such as the effect on recurrence after trichiasis surgery.

***C. trachomatis* and non-chlamydial bacterial infection**

C. trachomatis was rarely detected in these studies on scarring trachoma. Five (1.4%) of the cases in the TS study and none of the participants in the TT study were positive with Amplicor testing. A number of studies have confirmed that infection with *C. trachomatis* is

infrequently found in adults with trachomatous scarring. This is probably partly a result of the shortened duration of infection in adults compared to children, thereby making it more difficult to detect infection.^{13, 14} However, even taking this into account, it seems likely that other factors are also important in driving the scarring process. One of the hypotheses we tested was that non-chlamydial bacterial infection is found more frequently in scarring, and a significant association was indeed found. Furthermore, such infection was strongly associated with marked fold changes in expression of a number of genes, particularly innate, anti-bacterial mediators and ECM modifiers. Non-chlamydial bacterial infection has also been found more frequently in children with active disease, and this was also associated with differential expression of a number of genes.^{15, 16} It would appear that the conjunctiva of individuals previously exposed to ocular *C. trachomatis* infection is more vulnerable to harbouring both commensal and pathogenic organisms, and the latter, in particular, provoke an inflammatory response. This could well be an important factor leading to the development and/or progression of scarring complications. This could conceivably be mediated by NK cells, initially activated by *C. trachomatis* infection, being further stimulated by the presence of these additional bacteria into an uncontrolled, pathological response.

Future work on a cohort study of progressive scarring

While the studies in this current work have helped to establish factors associated with the presence of trachomatous scarring, it is of interest to analyse whether these factors are also associated with the progression of scarring. This would help to provide evidence of a causal relationship in the pathogenesis of scarring. To this end I have been leading/conducting the field work of a cohort study of 800 individuals with trachomatous scarring who have been examined every 6 months for 2 years (a total of 5 examination points). This cohort (which includes the cases from the TS Study) have been examined clinically and had high resolution digital photographs taken at each examination. Conjunctival swabs for gene expression, bacteriology and detection of *C. trachomatis* were taken at 0, 6, 12 and 18 months. *In vivo* confocal microscopy (IVCM) was performed at baseline and at the final examination which was completed mid-2011. We are in the process of performing the qPCR for this study and analysing the large amount of data generated. Being able to identify factors causing progression of scarring will help to focus the development of future interventions aimed at reducing blindness. Identification of biomarkers for progressive disease can also be used to evaluate the effect of mass antibiotic distribution, a core element of the WHO endorsed SAFE strategy.

Future work involving immunohistochemical staining of conjunctival biopsies

A limited amount of tissue is remaining for analysis from the conjunctival biopsies taken as part of the TT study. Important points which need addressing are confirmation of the identity of the CD8⁺ and CD45⁻ cell infiltrates seen in scarring. Double staining of a number of samples with CD8 and CD56 would provide further confirmation that the CD8⁺ cells are Natural Killer cells. Identification of the infiltrate of CD45 negative cells may require extensive further work. Follicular dendritic cells, for example, lack specific cellular markers and are difficult to work with.

The biopsies have already been stained for various cytokines and other mediators including IL1 β , IL13, IL17, S100A7, CXCL5, TGF β , MMP7 and MMP9. It is anticipated that the grading of these sections and the subsequent analysis will help to validate the gene expression results from swab samples, and also give information on their origin and tissue distribution.

Microscopic examination of trachomatous scarring

Scarred and control tissue was examined both with IVCM and with light microscopy on histological sections. Novel grading systems were developed for the assessment of scarring with both techniques which showed good correlation with clinical examination and with each other.

Histological and IVCM analyses found that scarring was associated with increased inflammatory cells. This inflammatory cell infiltrate appeared to be more strongly associated with scarring than with clinical inflammation.

The fold changes in gene expression seen with clinical scarring in the TS study tended to show corresponding fold changes with IVCM scarring. The fold changes were not so marked with IVCM, but this may have been because of differences in the types of analysis. Clinical scarring could be defined on a binary basis, while the IVCM scarring measurement was defined as a categorical variable, analysis of which will reduce the fold changes found. The use of IVCM has allowed some novel observations to be made about the pathophysiology of trachomatous scarring. Comparison of scans taken from different locations on the tarsal conjunctiva showed that the IVCM scarring grade tended to show little variation. If highly organised bands or sheets of organised connective tissue were seen in one scan, then the other scans usually showed a similar appearance. This indicates that the scarring process affects the whole of the conjunctival surface rather than focal areas, as might be concluded from clinical examination where bands of scar tissue are often seen. IVCM may also be able to detect sub-clinical scarring. Most of the cellular activity seen with IVCM was very close to

the conjunctival surface and this was confirmed on examination of the histological sections. This is consistent with the cellular paradigm of pathogenesis which proposes that the release of mediators by the epithelium is central in driving pathological responses. IVCM also identified dendritiform cells and found that these were very strongly associated with scarring. We did not find these structures to be associated with immunohistochemical markers of mature, conventional dendritic cells and further work is required to confirm what they are.

Further work on the identification of IVCM dendritiform cells

In order to identify what these cells are it would be helpful to cut histological sections in the same plane that the IVCM image is taken, i.e. *en face*. This will allow direct comparison of the images seen. If tissue can be identified which contains numerous dendritiform cells on IVCM, and removed for analysis (such as removal of a tumour with clear surgical margins), then sections could be cut *en face* and stained for a number of dendritic and fibroblast markers.

Other potential areas of future work: innate immune responses

To further investigate the contribution of the innate immune response to the pathogenesis of trachoma it would be worthwhile to examine polymorphisms in Killer-cell immunoglobulin-like receptors (regulatory cell surface proteins on NK cells) associated with scarring. This would provide further confirmation of the role of NK cells in the development of scarring. The identification of specific bacterial components provoking innate/scarring responses, either with the use of epithelial cell lines or animal models, could also be investigated.

Final conclusion

This work has potentially helped to change the way we think about the pathogenesis of trachoma by providing evidence that innate immune responses are involved, rather than a T-helper cell type 2 response, and that non-chlamydial bacterial infection may be an important driver for this. This work has also shown that clinical, molecular and immunohistological features of scarring trachoma are associated with particular IVCM appearances. This imaging technique could also be applied to the study of active disease and the identification of factors associated with the development/progression of scarring. Infection with *C. trachomatis* appears to play a relatively minor role in driving trachomatous scarring and this has very important implications for future trachoma control measures. Even if *C. trachomatis* infection is effectively eliminated there will remain a very large number of people at risk of future blindness from trachoma.

References

1. Resnikoff S, Pascolini D, Etya'ale D, et al. Global data on visual impairment in the year 2002. *Bull World Health Organ* 2004;82:844-851.
2. Burton MJ, Rajak SN, Bauer J, et al. Conjunctival transcriptome in scarring trachoma. *Infect Immun* 2011;79:499-511.
3. Natividad A, Freeman TC, Jeffries D, et al. Human conjunctival transcriptome analysis reveals the prominence of innate defense in *Chlamydia trachomatis* infection. *Infect Immun* 2010;78:4895-4911.
4. Lacy HM, Bowlin AK, Hennings L, Scurlock AM, Nagarajan UM, Rank RG. Essential role for neutrophils in pathogenesis and adaptive immunity in *Chlamydia caviae* ocular infections. *Infect Immun* 2011;79:1889-1897.
5. Frazer LC, O'Connell CM, Andrews CW, Jr., Zurenski MA, Darville T. Enhanced neutrophil longevity and recruitment contribute to the severity of oviduct pathology during *C. muridarum* infection. *Infect Immun* 2011.
6. Darville T, O'Neill JM, Andrews CW, Jr., Nagarajan UM, Stahl L, Ojcius DM. Toll-like receptor-2, but not Toll-like receptor-4, is essential for development of oviduct pathology in chlamydial genital tract infection. *J Immunol* 2003;171:6187-6197.
7. Rasmussen SJ, Eckmann L, Quayle AJ, et al. Secretion of proinflammatory cytokines by epithelial cells in response to *Chlamydia* infection suggests a central role for epithelial cells in chlamydial pathogenesis. *J Clin Invest* 1997;99:77-87.
8. Holland MJ, Jeffries D, Pattison M, et al. Pathway-focused arrays reveal increased matrix metalloproteinase-7 (matrilysin) transcription in trachomatous trichiasis. *Invest Ophthalmol Vis Sci* 2010;51:3893-3902.
9. Natividad A, Cooke G, Holland MJ, et al. A coding polymorphism in matrix metalloproteinase 9 reduces risk of scarring sequelae of ocular *Chlamydia trachomatis* infection. *BMC Med Genet* 2006;7:40.
10. El-Asrar AM, Geboes K, Al-Kharashi SA, et al. Expression of gelatinase B in trachomatous conjunctivitis. *Br J Ophthalmol* 2000;84:85-91.
11. Burton MJ, Bailey RL, Jeffries D, et al. Conjunctival expression of matrix metalloproteinase and proinflammatory cytokine genes after trichiasis surgery. *Invest Ophthalmol Vis Sci* 2010;51:3583-3590.
12. Wong TT, Mead AL, Khaw PT. Prolonged antiscarring effects of ilomastat and MMC after experimental glaucoma filtration surgery. *Invest Ophthalmol Vis Sci* 2005;46:2018-2022.
13. Bailey R, Duong T, Carpenter R, Whittle H, Mabey D. The duration of human ocular *Chlamydia trachomatis* infection is age dependent. *Epidemiol Infect* 1999;123:479-486.
14. Grassly NC, Ward ME, Ferris S, Mabey DC, Bailey RL. The natural history of trachoma infection and disease in a gambian cohort with frequent follow-up. *PLoS Negl Trop Dis* 2008;2:e341.
15. Burton MJ, Hu VH, Massae P, et al. What is causing active trachoma? The role of nonchlamydial bacterial pathogens in a low prevalence setting. *Invest Ophthalmol Vis Sci* 2011;52:6012-6017.
16. Burton MJ, Ramadhani A, Weiss HA, et al. Active trachoma is associated with increased conjunctival expression of IL17A and pro-fibrotic cytokines. *Infect Immun* 2011.

Appendices

Appendix 1: Enumeration/screening data collection forms	263
Appendix 2: Participant Information forms	
Appendix 2a: TS Study (English)	264
Appendix 2b: TS Study (Kiswahili)	266
Appendix 2c: TT Study (English)	268
Appendix 2d: TT Study (Kiswahili)	270
Appendix 3: Consent forms	
Appendix 3a: TS Study (English)	272
Appendix 3b: TS Study (Kiswahili)	273
Appendix 3c: TT Study (English)	274
Appendix 3d: TT Study (Kiswahili)	275
Appendix 4: Study data collection forms	
Appendix 4a: TS Study	276
Appendix 4b: TT Study	278
Appendix 5: Clinical examination protocol	280
Appendix 6: Background to methodologies	
Appendix 6a: Quantitative real-time reverse transcriptase polymerase chain reaction	289
Appendix 6b: Histology and immunohistochemistry	294
Appendix 7: Publication permissions	
Appendix 7a: Epidemiology and control of trachoma: systematic review	296
Appendix 7b: Trachoma: an update	298
Appendix 7c: In vivo confocal microscopy of trachoma in relation to normal tarsal conjunctiva	299
Appendix 7d: In vivo confocal microscopy in scarring trachoma	300
Appendix 7e: Bacterial infection and scarring trachoma	301
Appendix 7f: Innate immune responses and modified extra-cellular matrix regulation characterize bacterial infection and cellular/connective tissue changes in scarring trachoma	302

Appendix 1: Ennueration / screening data form

Pathophysiology of progressive trachomatous conjunctival scarring: Subject registration/screening form

Village Name	Village Number	Date
Subvillage Name	Subvillage Number	Name of person registering AP / PhM
Balozi Name	Balozi Number	Name of person screening VH / PaM
Household Name	Household Number	Name of person entering data

No.	1 st Name	2 nd Name	Yr of birth	M / F	Scarring?		Trichiasis?		Corneal opacity?		Prev Sx? Y / N	Suitable for study? 0 No 1 Yes & agrees 2 Yes but refuses 3 Absent 4 Refuses exam 5 Resident elsewhere
					RE Y / N	LE Y / N	RE Y / N	LE Y / N	RE Y / N	LE Y / N		
01												
02												
03												
04												
05												
06												
07												
08												
09												
10												

LSHTM / KCMC TRACHOMA PROJECT

Pathophysiology of Progressive Trachomatous Conjunctival Scarring

Information Sheet

Kilimanjaro Christian Medical Centre, Moshi, Tanzania

Kilimanjaro Regional Eye Care Programme, Moshi, Tanzania

International Centre for Eye Health, London School of Hygiene & Tropical Medicine, UK

What is this study about?

Trachoma is one of the main causes of blindness in Tanzania. It starts in childhood when children get redness and soreness under their eyelids, caused by infection with a bacteria called Chlamydia. As people get older they may develop eyelid scarring causing the eyelashes to turn inwards and rub on the eyeball. This is called trichiasis. This can cause the clear part of the eye to become white leading to blindness and the trichiasis is often painful. Currently, this disease process is only poorly understood and the treatments for it are only partially effective. In order to try to understand this better we would like to follow-up a group of people with eyelid scarring every six months for 2 years to investigate why some people have progressive scarring disease and some do not.

Whose help do we need?

We need the help of people who have scarring of the eyelids from trachoma.

What will we ask you to do?

We will ask you several questions about your eyes. A small sponge or tube may be used to collect tears from the inner corner of the eye. Then your eyes will be examined and photographed, to confirm that you have scarring from trachoma. We will examine a surface of the eye with a microscope. Three swab samples will be collected by gently rubbing the swab on the eyelid.

What benefits are there to taking part in the study?

1. It is only poorly understood how this disease causes blindness. You will be helping us to answer this question.
2. We will check the general health of your eyes and refer you to receive appropriate eye care if necessary.

Are there any risks caused by taking part in the study?

There is no known risk from the investigations we will do on your eyes. Collecting swabs samples has been done in many studies conducted in Tanzania and elsewhere.

What tests will we do on the swab sample?

The swab samples will be tested in various ways to try to help improve the understanding of trachoma. Samples will be tested in laboratories in Moshi and London. This will involve tests for bacterial and chlamydial infection. We will also study the human body's response to the infection to try to understand better how it fights the infection and how the scarring problems develop. It is hoped that information from these studies will help in the development of new ways to fight the disease.

What will happen to the records and photos we keep about your eye?

All the information we collect will be kept confidential. It will be kept securely and only the people organising the trial will have access to it.

Do I have to take part in this study?

You do not have to take part in this study.

How many people are taking part in this study?

We plan to recruit 1000 people with eyelid scarring to participate in this study.

Who is doing this study?

This project is collaboration between:

Kilimanjaro Christian Medical Centre, Moshi, Tanzania.

Kilimanjaro Regional Eye Care Programme, Moshi, Tanzania.

International Centre for Eye Health, London School of Hygiene & Tropical Medicine, UK

Institute of Ophthalmology, London, UK

Study Organisers:

Matthew Burton, LSHTM and KCMC

Victor Hu, LSHTM and KCMC.

If you have any questions please ask us:

Telephone: 027 275 3240 (Victor Hu or Patrick Massae)

Email: victor.hu@lshtm.ac.uk

Appendix 2b: Information sheet for the TS Study (Kiswahili)

MRADI WA TRACHOMA KCMC/LSHTM

Mabadiliko ya kifuniko cha jicho baada ya kovu

KARATASI YA MAELEZO

Kilimanjaro Christian Medical Centre, Moshi, Tanzania

Kilimanjaro Regional Eye Care Programme, Moshi, Tanzania

International Centre for Eye Health, London School of Hygiene & Tropical Medicine, UK

TRACHOMA(vikope) INAHUSU NINI?

Trachoma ni mojawapo ya kisababishi cha upofu Tanzania. Inaanza kipindi cha utotoni wakati watoto wanapopata maambukizi ya ugonjwa wa trachoma ndani ya kifuniko cha jicho ambao unasababishwa na vimelea viitwavyo Chlamydia. Wakati watu wanapozidi kukua, kovu katika kifuniko cha jicho linazidi kukua na kusababisha kope kuingia ndani na kugusa jicho. Kitendo hiki kinaitwa KIKOPE. Kitendo hiki kinaweza kusababisha kioo cha jicho kuwa na kidonda na baadaye kovu na kusababisha upofu na maumivu. Kwa sasa, ugonjwa unaweza kuendelea katika hali isiyoeleweka na matibabu yasiwe bora. Ili kuelewa vizuri kuhusu hili, tunatakiwa tuwafuatilie watu wenye kovu chini ya kifuniko cha jicho katika kila miezi sita, kwa muda wa miaka miwili ili kuchunguza kwa nini baadhi ya watu wana ugonjwa wa makovu yasiyoisha na wengine hawana.

Tunahitaji msaada kwa watu gani?

Tunahitaji msaada kwa watu ambao wana makovu chini ya kifuniko vya macho yao, yanayotokana na ugonjwa wa TRACHOMA (vikope).

Tutakuomba ufanye nini?

Tutakuuliza maswali mengi kuhusu macho yako. Pamba ndogo itatumika kukusanya machozi kutoka sehemu ya nje ya jicho. Baada ya hapo, macho yako yatafanyiwa uchunguzi na kupigwa picha ili kuhakikisha kuwa una kovu linalotokana na trachoma. Tutachunguza sehemu ya nje ya jicho lako kwa kutumia darubini.

NI FAIDA GANI AMBAZO ZITASAIDIA SOMO HILI?

1. Haieleweki vizuri ni jinsi gani ugonjwa huu unaweza kusababisha upofu. Utatusaidia kutupa majibu ya swali hili.
2. Tutaangalia afya ya macho yako kwa ujumla na ikiwezekana macho yako yapate uangalifu wa hali ya juu.

JE KUNA HATARI YOYOTE INAYOWEZA KUTOKEA KUTOKANA NA KUHUSIKA NA SOMO HILI?

Hakuna hatari yoyote utakayoyapata kutokana na uchunguzi wa macho yako. Uchukuzi wa sampuli umeshafanyika katika masomo mengi hapa Tanzania na sehemu nyinginezo.

MAJARIBIO GANI YANAWEZA KUFANYIKA KWA KUTUMIA SAMPULI ILIYOTOKA KWENYE MACHO YAKO?

Sampuli itafanyiwa majaribio kwa kutumia njia mbalimbali ili kukuza uelewa wa Trachoma(vikope). Sampuli zitajaribiwa maabara ya Moshi na Uingereza. Itahusisha majaribio ya vimelea na madhara yake. Tutasoma pia jinsi mwili unavyoweza kuhusika kutokana na madhara ili kujaribu kuelewa vizuri ni jinsi gani mwili unaweza kupambana na madhara na matatizo ya makovu kutokea. Inaaminika kuwa maelezo kutoka kwenye masomo haya yatasaidia kuendeleza njia mbadala za kupambana na ugonjwa.

Kitatokea nini kwenye kumbukumbu na picha tunazohifadhi kuhusu jicho lako?

Tutakusanya maelezo yote kama siri. Itawekwa kwa usalama na ni kwa watu wale tu ambao wanaoendesha jaribio wanaweza kuipata.

Je ni lazima kuhusika kwenye somo hili?

Hulazimishwi ila ni hiyari yako kushiriki kwenye somo hili.

Ni watu wangapi watashiriki kwenye somo hili?

Tumepanga kuwatembelea watu 1000 wenye kovu chini ya kifuniko cha jicho kushiriki kwenye somo hili.

Nani anafanya somo hili?

Mradi huu ni ushirikiano kati ya:

Kilimanjaro Christian Medical Centre(KCMC), Moshi, Tanzania
Kilimanjaro Regional Eye Care Programme, Moshi, Tanzania
International Centre for Eye Health, London School of Hygiene & Tropical Medicine, UK.
Institute of Ophthalmology, London, UK

Wanaendeshaji wa somo:

Matthew Burton, KCMC na LSHTM
Victor Hu, LSHTM na KCMC

Kwa maswali yoyote tuulize kupitia:

Barua pepe: victor.hu@lshtm.ac.uk
Simu: 0272753240 (Victor Hu au Patrick Massae)

Pathology of Trachomatous Conjunctival Scarring: A Case-Control Study

Kilimanjaro Christian Medical Centre, Moshi, Tanzania
Kilimanjaro Center for Community Ophthalmology, Moshi, Tanzania
Kilimanjaro Regional Eye Care Programme, Moshi, Tanzania
International Centre for Eye Health, London School of Hygiene & Tropical Medicine, UK

What is this study about?

Trachoma is one of the main causes of blindness in Tanzania. It starts in childhood when children get redness and soreness under their eyelids, caused by infection with a bacteria called Chlamydia. As people get older they may develop eyelid scarring causing the eyelashes to turn inwards and rub on the eyeball. This is called trichiasis, and you will be having surgery to correct this. Trichiasis can cause the clear part of the eye to become white leading to blindness is often painful. Currently, this disease process is only poorly understood and the treatments for it are only partially effective. In order to try to understand this better we would like to examine a group of people with eyelid scarring.

Whose help do we need?

We need the help of people who have eye lid scarring from trachoma and people without scarring.

What will we ask you to do?

We will ask you several questions about your eyes. A small sponge or tube will be used to collect tears from the inner corner of the eye. Then your eyes will be examined and photographed, to confirm the presence of trachoma scarring. We will examine the surface of the eye with a microscope. Anaesthetic drops will be put in the surface of the eye to make it numb. Three swab samples will be collected by gently rubbing the swab on the eyelid. We will take a very small (2mm by 2mm) piece of tissue from the inner surface of the upper lid, after turning the lid over. You will be offered a routine post-operative review about 1 to 2 weeks after the operation.

What benefits are there to taking part in the study?

1. Trachoma is a poorly understood disease. You will be helping us to learn new things which will hopefully help in the development of ways of preventing blindness..
2. Your eyes will receive a thorough examination for infection, inflammation or scarring.
3. If you have signs of an active infection we would provide appropriate treatment for this.

Are there any risks caused by taking part in the study?

There is no known risk from taking swab or tear samples, and has been done in many studies conducted in Tanzania and elsewhere. Several studies have collected small biopsy samples from the inner surface of the upper lid, without any problems. There is a very low risk of infection following surgery; this risk will be minimized by the use of antibiotic ointment, which is standard practice after eye surgery. If you experience any unusual problems or pain after the operation, before or after your scheduled post-operative review, you are advised to contact us for assistance. You will be provided with written contact information on your discharge.

What tests will we do on the swab sample?

The samples will be tested in various ways to try to help improve the understanding of trachoma. Samples will be tested in laboratories in Moshi and England. This will involve tests for bacterial and chlamydial infection and examining the tissue for inflammation or scarring. We will also study the human body's response to the infection to try to understand better how it fights the infection and how the scarring problems develop. The biopsy specimens will be examined at the Institute of Ophthalmology in London. We would like to archive the biopsy material indefinitely, so that in the future if new information about trachoma disease arises it will be possible to return the specimens to perform additional histopathological analysis. It is hoped that information from these studies will help in the development of new ways of preventing blindness from trachoma.

What will happen to the records and photos we keep about your eye?

All the information we collect will be kept confidential. It will be kept securely and only the people organising the trial will have access to it.

Do I have to take part in this study?

You do not have to take part in this study.

Who is doing this study?

This project is a collaboration between:

Kilimanjaro Christian Medical Centre, Moshi, Tanzania.

Kilimanjaro Center for Community Ophthalmology, Moshi, Tanzania

Kilimanjaro Regional Eye Care Programme, Moshi, Tanzania.

International Centre for Eye Health, London School of Hygiene & Tropical Medicine, UK

Institute of Ophthalmology, London, UK

Study Organisers:

William Makupa, Kilimanjaro Centre for Community Ophthalmology, KCMC, Moshi, Tanzania.

Wahida Shangali, Mawenzi Regional Hospital, Moshi, Tanzania

Matthew Burton, Kilimanjaro Centre for Community Ophthalmology, KCMC, Moshi, Tanzania.

Victor Hu, Kilimanjaro Centre for Community Ophthalmology, KCMC, Moshi, Tanzania.

If you have any questions please ask us:

Telephone: 027 275 3547 (Victor Hu or Matthew Burton)

Email: victor.hu@lshtm.ac.uk

**MRADI WA TRAKOMA KCMC/LSHTM
MABADILIKO YA KIFUNIKO CHA JICHO BAADA YA KOVU
KARATASI YA MAELEKEZO KWA WATU WENYE VIKOPE**

**Kilimanjaro Christian Medical Centre, Moshi, Tanzania
Kilimanjaro Regional Eye Care Programme, Moshi, Tanzania
International Centre for Eye Health, London School of Hygiene & Tropical Medicine, UK**

Utafiti huu unahusu nini?

Trachoma ni mojawapo ya kisababishi cha upofu Tanzania. Inaanza kipindi cha utotoni wakati watoto wanapopata maambukizi ya ugonjwa na kusababisha wekundu na uvimbe ndani ya kifuniko cha jicho ambao unasababishwa na wadudu wanaoitwa Chlamydia. Wakati watu wanapozidi kukua, kovu katika kifuniko cha jicho linazidi kukua na kusababisha kope kuingia ndani na kukwaruza jicho. Kitendo hiki kinaitwa KIKOPE na inawezekana kurekebisha kwa kufanyiwa upasuaji. Kitendo hiki kinaweza kusababisha sehemu nyeupe ya jicho kuwa na ukungu baadaye kovu na kusababisha upofu na maumivu ya mara kwa mara. Mpaka sasa hali ya ugonjwa huu haieleweki na kufanya matibabu yake yasiwe kamilifu. Ili kujaribu kuelewa vizuri kuhusu hili, tungependa kulinganisha idadi ya watu wenye makovu katika kifuniko cha jicho na idadi ileile ya watu ambao hawajaathirika.

Tunahitaji msaada kwa watu gani?

Tunahitaji msaada kwa watu ambao wana makovu chini ya vifuniko vya macho yao yatokanayo na vikope.

Tutakuomba ufanye nini?

Tutakuuliza maswali mbalimbali kuhusu macho yako. Tutatumia pamba ndogo au kichupa kidogo kukusanya machozi kutoka sehemu ya kona ya ndani ya jicho. Kisha, macho yako yatafanyiwa uchunguzi na kupigwa picha ili kuhakikisha kama una kovu linalotokana na trakoma. Tutachunguza sehemu ya jicho lako kwa kutumia darubini. Tutakuweka dawa kidogo ya kuondoa maumivu ndani ya jicho ambayo itakupa ganzi. Tutachukua kipande kidogo cha nyama sehemu ya kifuniko cha jicho. Utapewa taarifa ya mara kwa mara baada ya upasuaji husika kufanyika katika muda wa wiki moja hadi mbili.

Kuna faida zipi ukishiriki kwenye utafiti huu?

3. Trakoma ni ugonjwa ambao haujaeleweka. Unaweza kutusaidia sisi kufahamu njia mpya ambazo natumaini zitatusaidia kukuza njia za kuepuka au za kuondokana na upofu.
4. Macho yako yatafanyiwa uchunguzi wa kina ili kujua kama una maambukizi, uvimbe au upofu.
5. Kama una dalili za maambukizi, tungependa kukupa matibabu sahihi ya ugonjwa huu

Je kuna athari zozote zinaweza kutokea kutokana na utafiti huu?

Hakuna athari yoyote utakayoyapata kutokana na uchunguzi wa macho yako. Uchukuzi wa sampuli umeshafanyika katika tafiti nyingi hapa Tanzania na sehemu nyinginezo. Katika tafiti nyingi tulikusanya sampuli kidogo kutoka ndani, (chini ya kifuniko) cha jicho bila matatizo. Baada ya upasuaji, kuna uwezekano wa kupata madhara kidogo sana utakayoyapata, na madhara hayo yanaisha baada ya kupewa dawa ya macho, ambayo ni ya kuua vijidudu (antibiotic) ambapo ni kawaida baada ya upasuaji. Kama utaendelea kupata matatizo au maumivu baada ya upasuaji, utatakiwa kuwasiliana na sisi kwa uangalizi, pia utatakiwa kutupa namna ya mawasiliano na sisi wakati wa kupewa ruhusa.

Je, ni majaribio gani yatafanyika kwa kutumia sampuli tuliyoipata kwenye macho yako?

Sampuli zitafanyiwa majaribio mbalimbali ili kupata uelewa zaidi wa ugonjwa wa Vikope. Sampuli zitafanyiwa majaribio kwenye maabara ya Moshi (KCMC) na Uingereza. Hii itahusisha majaribio ya maambukizi ya vijidudu vya vijidudu vya bacteria wa Chlamydia. Pia kupima kijinyama kilichotolewa kwenye kovu lililopo chini ya kifuniko cha jicho. Tutajifunza jinsi mwili wa binadamu unavyojikinga na mashambulizi ya vijidudu na jinsi kovu linavyotokea. Kijinyama kitachunguzwa katika chuo cha macho, Uingereza (Institute of ophthalmology London). Tungependa kupokea sampuli hizi wakati wowote

na kuhifadhi ili hata baadaye ikihitajika irudishwe kwa uchunguzi zaidi. Tunategemea uchunguzi kama huu utatusaidia kupata njia mpya za kuzuia upofu utokanao na vikope.

Ni nini kitatokea kwenye kumbukumbu na picha tutakazotunza kuhusu macho yako?

Maelezo yote yanayokusanywa yatahifadhiwa kwa siri. Yatatunzwa kwa usalama na ni kwa wale tu ambao wanafanya utafiti huu ndio wanaweza kuzipata.

Je ni lazima kushiriki kwenye utafiti huu?

Hakuna ulazima wowote wakushiriki kwenye utafiti huu.

Je ni watu wangapi watachukuliwa kushiri kwenye utafiti huu?

Tumepanga kuwashirikisha watu mia mbili (200) ambao wana kovu kwenye kifuniko cha jicho ili kushiriki katika utafiti huu.

Je ni nani anafanya utafiti huu?

Mradi huu ni ushirikiano kati ya:-

Kilimanjaro Christian Medical Centre, Moshi Tanzania.

Kilimanjaro Center for Community Ophthalmology, Moshi Tanzania.

Kilimanjaro Regional Eye Care Programme, Moshi Tanzania.

International Centre Eye Health, London School of Hygiene & Tropical Medicine, UK

Institute of Ophthalmology, London, UK.

Waendeshaji wa utafiti:-

William Makupa, Kilimanjaro Centre for Community Ophthalmology, KCMC, Moshi, Tanzania.

Wahida Shangai, Mawenzi Regional Hospital, Moshi Tanzania.

Matthew Burton, Kilimanjaro Centre for Community Ophthalmology, KCMC, Moshi Tanzania.

Victor Hu, Kilimanjaro Centre for Community Ophthalmology, KCMC, Moshi Tanzania.

Kwa maswali zaidi tafadhali wasiliana nasi kwa:

Simu: 027 275 3547 (Victor Hu, and Matthew Burton)

Barua pepe: victor.hu@lshtm.ac.uk

Appendix 3a: Consent form for the TS Study (English)

**LSHTM / KCMC TRACHOMA PROJECT
Pathophysiology of Progressive Trichomatous Conjunctival Scarring
Consent Form**

**Kilimanjaro Christian Medical Centre, Moshi, Tanzania
Kilimanjaro Regional Eye Care Programme, Moshi, Tanzania
International Centre for Eye Health, London School of Hygiene & Tropical Medicine, UK**

Name:

Subject reference number:

--	--	--	--	--	--	--	--	--	--	--	--	--	--

I have read / had explained to me the information about the research study. I understand what will be involved in taking part in the study.

..... has answered all my questions about the study.

I agree to take part in this study.

Signed / Thumbprint..... Date.....

I have explained the purpose of the study to the above subject and I am satisfied that he/she willingly agrees to participate

Signed..... Date.....

Name:.....

In the event that the patient cannot read the above information, an additional witness is required:
I have witnessed the explanation and informed consent to this study of above named patient

Signed..... Date.....

Name:.....

Study Organisers:
Matthew Burton, Kilimanjaro Centre for Community Ophthalmology, KCMC, Moshi, Tanzania.
Victor Hu, Kilimanjaro Centre for Community Ophthalmology, KCMC, Moshi, Tanzania.

Appendix 3b: Consent form for the TS Study (Kiswahili)

FOMU YA RIDHAA

**Kilimanjaro Christian Medical Centre, Moshi, Tanzania
Kilimanjaro Regional Eye Care Programme, Moshi, Tanzania
International Centre for Eye Health, London School of Hygiene & Tropical Medicine, UK**

Jina:

Subject reference number:

--	--	--	--	--	--	--	--	--	--	--	--	--	--

Nimesoma/nimeelezwa maelezo kuhusu somo la utafiti.Nimeelewa nini kitahusika katika sehemu ya somo hili

..... amejibu maswali yote kuhusu somo hili.

Nimekubali kuwa sehemu ya somo hili

Imesainiwa na/ kidole gumba..... Tarehe.....

Nimeelezea lengo la somo hapo juu na nimeridhika me/ke yupo tayari na amekubali kushiriki

Imesainiwa na..... Tarehe.....

Jina:.....

Katika tukio ambalo mgonjwa hawezi kusoma maelezo hapo juu,shahidi wa ziada anatakiwa:

Nimetoa ushahidi na maelezo ya ridhaa ya somo hili kwa mgonjwa hapo juu.

Imesainiwa na Tarehe.....

Jina:.....

Washiriki wa somo:
Matthew Burton, Kilimanjaro Centre for Community Ophthalmology, KCMC, Moshi, Tanzania.
Victor Hu, Kilimanjaro Centre for Community Ophthalmology, KCMC, Moshi, Tanzania.

Appendix 3c: Consent form for the TT Study (English)

**Pathology of Trachomatous Conjunctival Scarring: A Case-Control Study
Consent form**

**Kilimanjaro Christian Medical Centre, Moshi, Tanzania
Kilimanjaro Center for Community Ophthalmology, Moshi, Tanzania
Kilimanjaro Regional Eye Care Programme, Moshi, Tanzania
International Centre for Eye Health, London School of Hygiene & Tropical Medicine, UK**

Name:

Study Reference Number:

--	--	--	--

I have read / had explained to me the information about the research study. I understand what will be involved in taking part in the study.

..... has answered all my questions about the study.

I agree to take part in this study.

Signed / Thumbprint..... Date.....

I have explained the purpose of the study to the above subject and I am satisfied that he/she willingly agrees to participate

Signed..... Date.....

Name:.....

In the event that the patient can not read the above information, an additional witness is required:

I have witnessed the explanation and informed consent to this study of above named patient

Signed..... Date.....

Name:.....

Study Organisers:

William Makupa, Kilimanjaro Christian Medical Center, KCMC, Moshi, Tanzania.
Wahida Shangali, Mawenzi Regional Hospital, Moshi, Tanzania
Matthew Burton, Kilimanjaro Centre for Community Ophthalmology, KCMC, Moshi, Tanzania.
Victor Hu, Kilimanjaro Centre for Community Ophthalmology, KCMC, Moshi, Tanzania.

Appendix 3d: Consent form for the TT Study (Kiswahili)

**FOMU YA RIDHAA
MABADILIKO YA KIFUNIKO CHA JICHO BAADA YA KOVU**

**Kilimanjaro Christian Medical Centre, Moshi, Tanzania
Kilimanjaro Center for Community Ophthalmology, Moshi, Tanzania
Kilimanjaro Regional Eye Care Programme, Moshi, Tanzania
International Centre for Eye Health, London School of Hygiene & Tropical Medicine, UK**

Kilimanjaro Christian Medical Centre(KCMC), Moshi, Tanzania.
Kilimanjaro Regional Eye Care Programme, Moshi, Tanzania.
International Centre for Eye Health, London School of Hygiene & Tropical Medicine, UK.

Jina:

Kumbukumbu namba:

--	--	--	--

Nimesoma/nimeelezwa maelezo kuhusu somo la utafiti. Nimeelewa nini kitahusika katika sehemu ya utafiti huu

..... amejibu maswali yote kuhusu utafiti huu.

Nimekubali kuwa sehemu ya utafiti huu

Imesainiwa na/ Dole gumba..... Tarehe.....

Nimeelezwa lengo la utafiti hapo juu na nimeridhika me/ke yupo tayari na amekubali kushiriki

Imesainiwa na..... Tarehe.....

Jina:

Katika tukio ambalo mgonjwa hawezi kusoma maelezo hapo juu, shahidi wa ziada anatakiwa:

Nimetoa ushahidi na maelezo ya ridhaa ya utafiti huu kwa mgonjwa hapo juu.

Imesainiwa na Tarehe.....

Jina:

Washiriki wa utafiti:-

William Makupa, Kilimanjaro Christian Medical Centre, KCMC, Moshi, Tanzania.
Wahida Shangali, Mawenzi Regional Hospital, Moshi, Tanzania
Matthew Burton, Kilimanjaro Centre for Community Ophthalmology, KCMC, Moshi, Tanzania.
Victor Hu, Kilimanjaro Centre for Community Ophthalmology, KCMC, Moshi, Tanzania.

Appendix 4a: Data form for the TS Study

Baseline subject examination form

1. Demographic data

Subject Number					
Study Number					
Date of the examination	Day / Month / Year				
First name					
Middle name					
Last name					
Village name					
Sub-village name					
Balozi name					
Household head name					
Telephone number (if possible)					
Whose telephone is this?					
Sex	1 = Male 2 = Female				
Date of birth	Date / Month / Year				
	Is this an estimate only? 0 = No 1 = Yes				
Ethnic group	1 = Maasai 2 = Chagga 3 = Meru 4 = Mang'ati 5 = Pare 6 = Other (specify)				
Education	Year of schooling attained				
Literacy	0 = Illiterate 1 = Able to read Kiswahili only 2 = Able to read English only 3 = Able to read other language only (specify) 4 = Able to read more than language 5 = Refused to answer				

2. General examination

Height in cm	0 = Not performed	
Weight in kg	0 = Not performed	

3. Ophthalmic Examination

Number of medial globe lashes		R	L
Number of lateral globe lashes		R	L
Number of corneal lashes		R	L
Trichiasis grade	T 0/1/2/3	R	L
Entropion grade	E 0/1/2/3/4	R	L
Trichiasis / entropion photo	0 = Not performed 1 = Performed	R	L
Bacteriology swab	0 = Not performed 1 = Performed		L
Bacteriology swab number			E1 <input type="checkbox"/> <input type="checkbox"/> <input type="checkbox"/> <input type="checkbox"/>
Follicle grade	F 0/1/2/3	R	L
Papillary grade	PH 0/1/2/3/4/5/6	R	L
Conjunctival scarring	S 1 _{a/b/c} /2/3	R	L
Lid margin conjunctivisation grade	CM 0/1/2/3	R	L
Tarsal plate photo	0 = Not performed 1 = Performed	R	L
Corneal scarring grade	CC 1/2 _{a/b/c/d} /3/4	R	L
Corneal photo	1 = Performed 2 = Not performed	R	L
Tarsal plate confocal microscopy	0 = Not performed 1 = Full protocol performed 2 = Performed, but not full	L	
RNA swab	0 = Not performed 1 = Performed		L
RNA swab number			F1 <input type="checkbox"/> <input type="checkbox"/> <input type="checkbox"/> <input type="checkbox"/>
DNA swab	0 = Not performed 1 = Performed		L
DNA swab number			G1 <input type="checkbox"/> <input type="checkbox"/> <input type="checkbox"/> <input type="checkbox"/>

I have recorded the demographic and general examination sections:

Signature

Date

I have recorded the ophthalmic examination findings:

Signature

Date

I have entered the data onto the database:

Signature

Date

Appendix 4b: Data form for the TT Study

TT Biopsy Study

1. Demographic data

Study Number				
Case or Control	0 = Control 1 = Case			
Date of the examination	Day / Month / Year			
First name				
Last name				
Village name				
Sub-village name				
Balozi name				
Telephone number				
Whose telephone is this?				
Sex	1 = Male 2 = Female			
Date of birth	Date / Month / Year			
	Is this an estimate only? 0 = No 1 = Yes			
Ethnic group	1 = Maasai 2 = Chagga 3 = Meru 4 = Mang'ati 5 = Pare 6 = Other (specify)			
Education	Year of schooling attained			

2. Study eye

Side	1 = Right 2 = Left		
Had previous surgery?	Y = Yes N = No	R	L

3. Ophthalmic Examination

Number of medial globe lashes		R	L
Number of lateral globe lashes		R	L
Number of corneal lashes		R	L
Trichiasis grade	0/1/2/3	R	L
Entropion grade	0/1/2/3/4	R	L
Corneal scarring grade	0/1/2/3/4/5/6/7	R	L
Corneal photo number	0 = Not performed	R	L
Trichiasis / entropion photo number	0 = Not performed	R	L
Follicle grade	0/1/2/3	R	L
Papillary grade	0/1/2/3/4/5/6	R	L
Conjunctival scarring	A, B, C, D, E	R	L
Lid margin conjunctivisation grade	0/1/2/3	R	L
Tarsal plate photo number	0 = Not performed	R	L
Confocal microscopy	0 = Not performed 1 = Full protocol 2 = Reduced protocol		
Bacteriology swab number		X	
RNA swab number		Y	
Biopsy number		Z	

I have recorded the data onto the form:

Signature

Date

I have entered the data onto the database:

Signature

Appendix 5: Clinical Examination Protocol

Abbreviations

TVH: Victor Hu

PaM: Patrick Massae

HM: Henry

AP: Alex Pallangyo

PhM: Phillip Mollel T

The clinical examination and photographs to be done on both eyes, the confocal microscopy and swabs only on the left eye for the TS Study and on the eye to be operated for the TT Study. VH to use a fresh pair of gloves between each subject.

STEP 1 Trichiasis assessment (VH)

- Assess eyelash position with the eye in the primary position (looking straight ahead).
- Count the number of lashes making contact with the globe:
 - o Medial to the cornea.
 - o Lateral to the cornea.
 - o Touching the cornea.
- Determine the grade of trichiasis (cf FPC System T/E₀₋₃)

T0	No trichiasis
T1	Lashes deviated towards the eye, but not touching the globe.
T2	Lashes touching the globe, but not rubbing on the cornea.
T3	Lashes constantly rubbing on the cornea.

STEP 2 Entropion assessment (VH)

- Assess eyelash position with the eye in the primary position.
- If necessary, gently raise the excess fold of upper lid skin, *without disturbing the lid position*.
- Determine the grade of entropion:

Degree of severity	Area of entropion	
	<50% of lid margin	>50% of lid margin
None	E0 (none)	
Without corneal-lash base contact	E1 (mild)	E2 (moderate)
With corneal-lash base contact	E3 (severe)	E4 (total)

None	'Normal' lid margin (see glossary) visible
Without corneal-lash base contact	Definite inwards rotation of the lid margin such that the lid margin is no longer visible when viewed in the primary position.
With corneal-lash base contact	Inward rotation of the lid margin, with some or all of the lash bases touching the globe

STEP 3. Photograph trichiasis / entropion / (HM)

- Photograph both eyes all the way through the protocol.
- Use the Nikon D200 camera with a VR lens, commander unit and 2 ring flash units.
- White balance to be set at the start and with any change in lighting conditions.
- Digital images will be visualized directly, and then saved, on a laptop.
- Trichiasis / entropion photo to be taken with the subject looking slightly upwards so that the lid margin can be visualised.

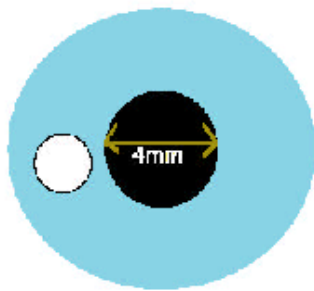
STEP 4. Corneal scarring grading (VH)¹

CC1	Opacity not entering central 4mm
CC2a	Opacity within central 4mm but not entering within the central 1mm of the cornea. The pupil margin is visible through the opacity.
CC2b	Opacity within central 4mm but not entering within the central 1mm of the cornea. The pupil margin is not visible through the opacity.
CC2c	Opacity within central 4mm and entering the central 1mm of the cornea. The pupil margin is visible through the opacity.
CC2d	Opacity within central 4mm and entering within the central 1mm of the cornea. The pupil margin is not visible through the opacity.
CC3	Opacity large enough and dense enough to make whole pupil margin invisible.
CC4	Phthisis

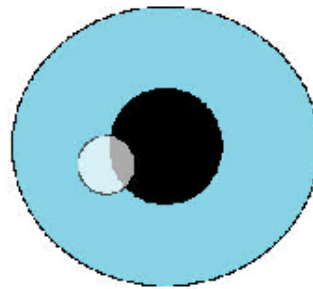
If there is more than one corneal scar then grade as for the worst/most central scar.

1. Rajak SN, Habtamu E, Weiss HA, et al. Epilation for Trachomatous Trichiasis and the Risk of Corneal Opacification. *Ophthalmology* 2011.

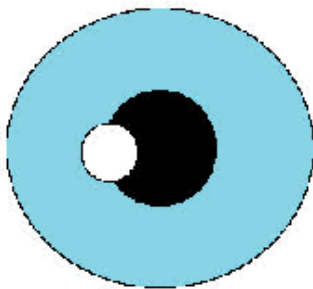
Trachomatous Corneal Scar Grading



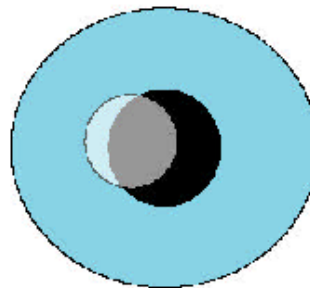
C1



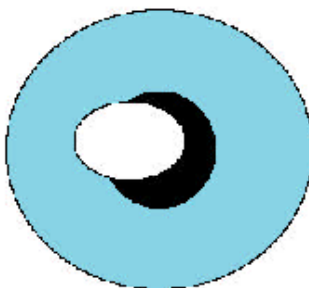
C2a



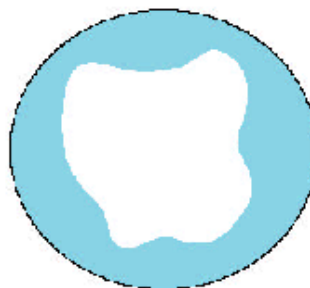
C2b



C2c



C2d



C3

STEP 5. Photography of the cornea (HM)

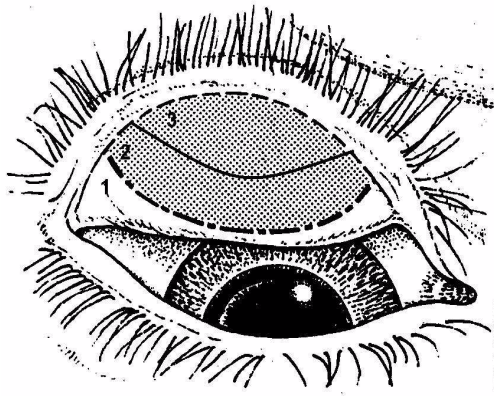
If corneal scarring is present then the cornea will be photographed in a similar manner to that of the conjunctiva.

STEP 6. Bacteriology swab (VH)

- One drop of proxymetacaine to be instilled into the lower fornix (VH).
- Use Amies Charcoal transport swabs.
- Sweep horizontally in the inferior fornix, particularly in areas of discharge, while rotating the swab along its long axis 3 times (VH). Avoid as much as possible swab contact with skin and lashes at the lid margin.
- Place swab into tube (opened and held by PaM) containing Amies media without touching any part of the swab that is in the tube.
- Seal the tube (PaM) and attach the sample number label (HM)
- Record the swab label number in the patient's study record form (AP).
- Record the patient number and the sample number on the lab form (HM).
- The tube to be kept at room temperature.

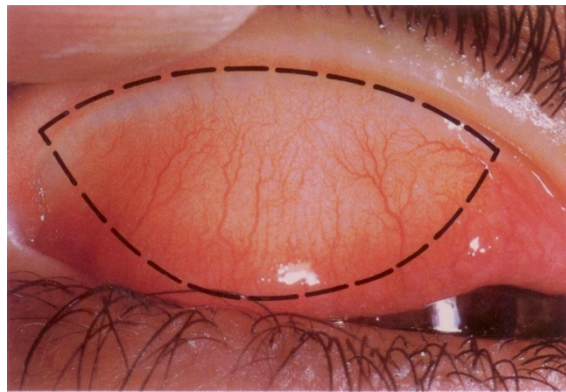
STEP 7. Tarsal plate grading (VH)

- The examiner to wear a fresh pair of non-sterile latex examination gloves (these will be changed between each examination to minimise the risk of cross contamination) and a pair of 2.5× binocular loupes and a bright hand-held torch).
- The upper lid to be everted and the conjunctival surface examined and graded. (VH)
- Zones 2 and 3 will be used for assessment in keeping with WHO guidelines.

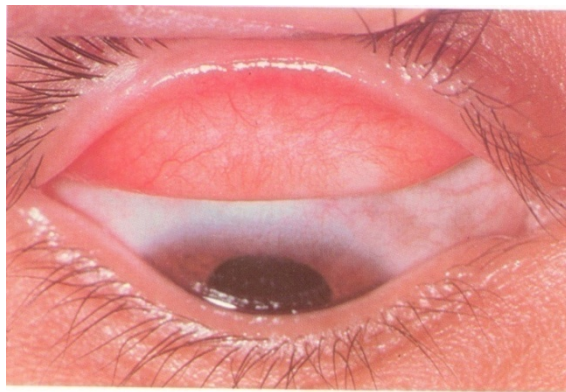


Examine upper lid for follicles

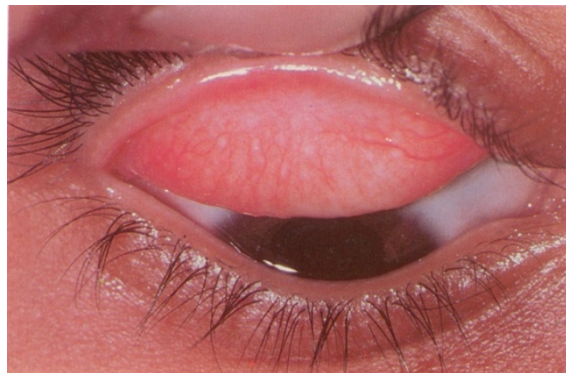
F 0 No follicles.



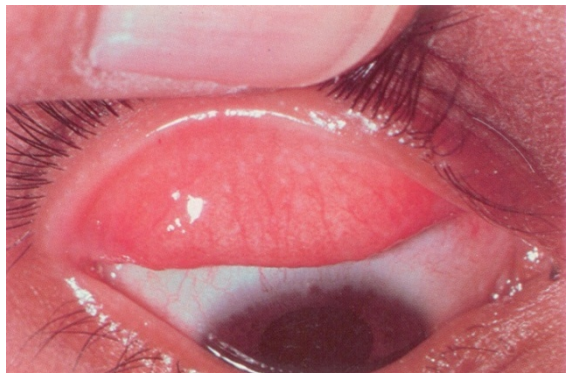
F 1 1-4 follicles.



F 2 5-10 follicles.



F 3 >10 follicles.



Examine upper lid for papillary hypertrophy

- Determine whether papillary reaction is over less than or greater than 50% of the tarsal area.

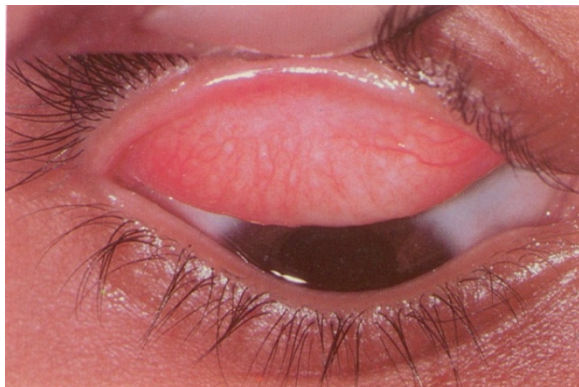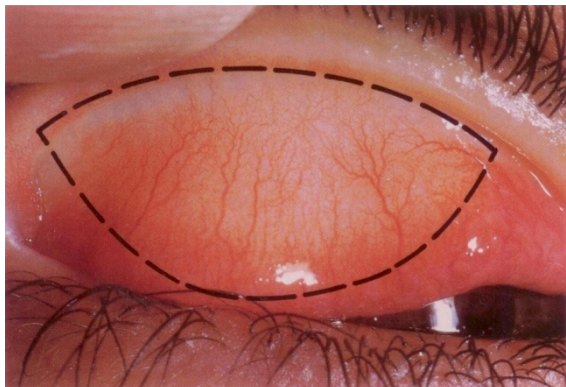
	<50% of tarsal area affected	>50% of tarsal area affected
None	PH 0	PH 0
Mild	PH 1	PH 2
Moderate	PH 3	PH 4
Severe	PH 5	PH 6

- Mild Individual vascular tufts (papillae) prominent, but deep sub-conjunctival vessels on the tarsus are not obscured.
- Moderate More prominent papillae and normal vessels appear hazy, even when seen by the naked eye.
- Severe Conjunctiva thickened and opaque, normal vessels on the tarsus are hidden.

WHO grading:

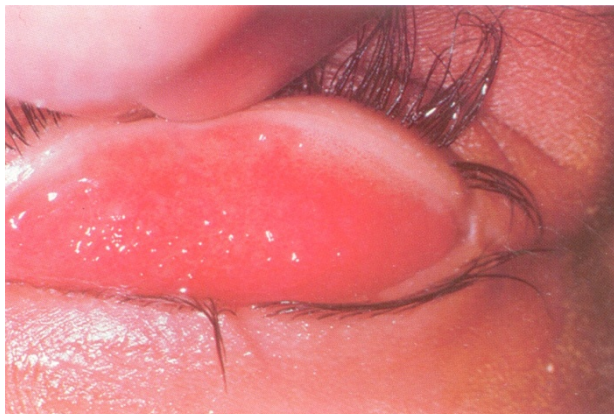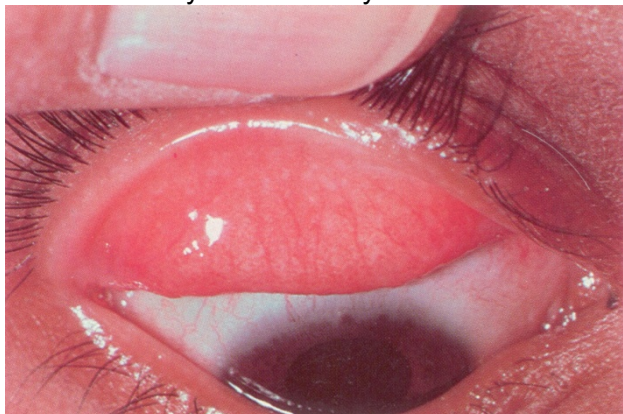
P 0 Absent: normal appearance

P1 Minimal: individual vascular tufts (papillae) prominent, but deep sub-conjunctival vessels on the tarsus are not obscured.



P2 Moderate: more prominent papillae and normal vessels appear hazy, even when seen by the naked eye

P3 Pronounced: conjunctiva thickened and opaque, normal vessels on the tarsus are hidden over more than half of the surface.

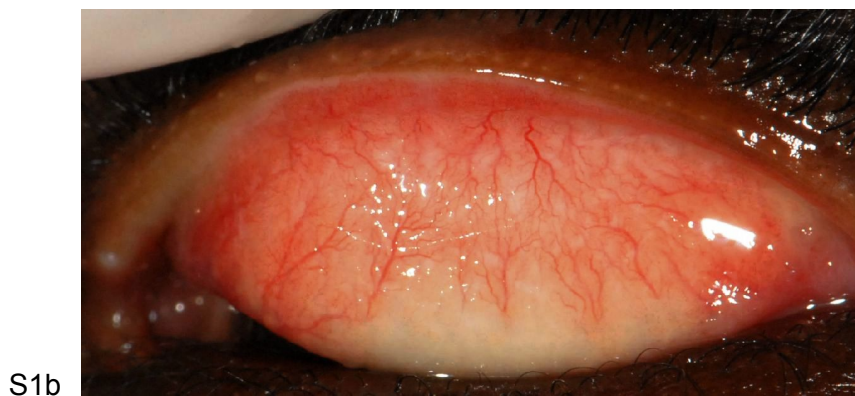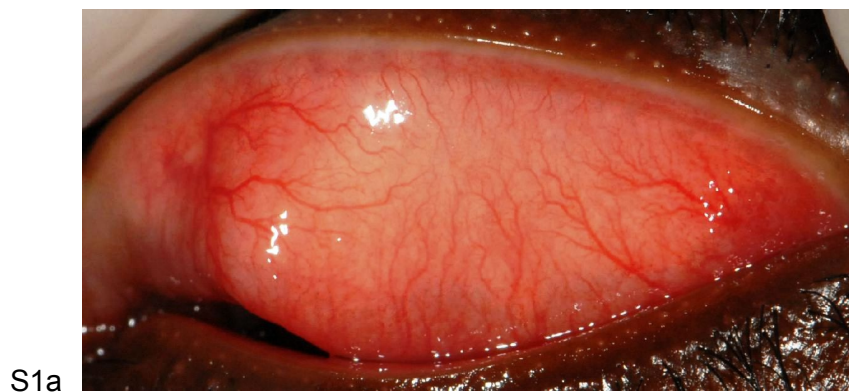


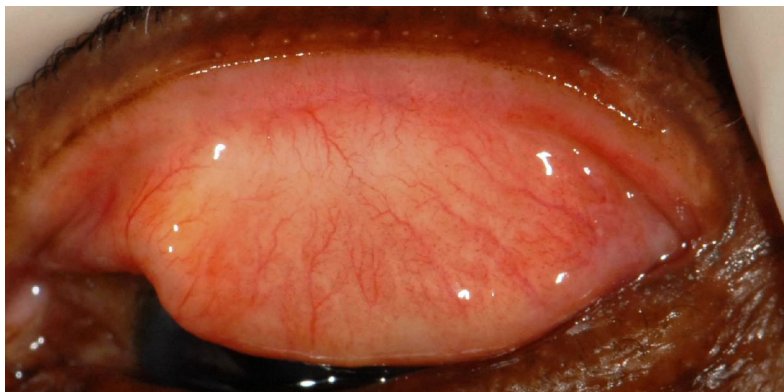-
- To convert to traditional papillary grading system use this table:

Degree of inflammation / 'redness'	<50% of tarsal area inflamed	>50% of tarsal area inflamed
None	P0	P0
Mild	P1	P1
Moderate	P2	P2
Severe	P2	P3

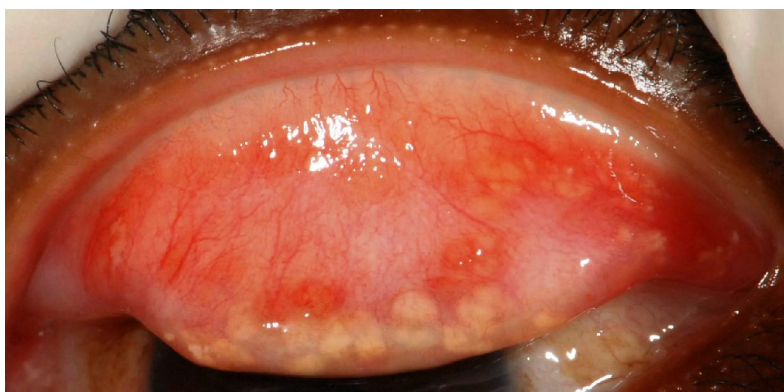Examine upper lid for Conjunctival scarring

Grade	Definition*
S1	Scarring occupying $< \frac{1}{3}$ of the upper lid
S1a	One or more pinpoint scars and/or a single line of scarring less than 2mm in length†
S1b	Multiple lines of scarring less than 2mm in length
S1c	One or more lines/patches of scarring each 2mm or more in length/maximal dimension
S2	Scarring occupying $\geq \frac{1}{3}$ but $< \frac{2}{3}$ of the upper lid
S3	Scarring occupying $\geq \frac{2}{3}$ of the upper lid

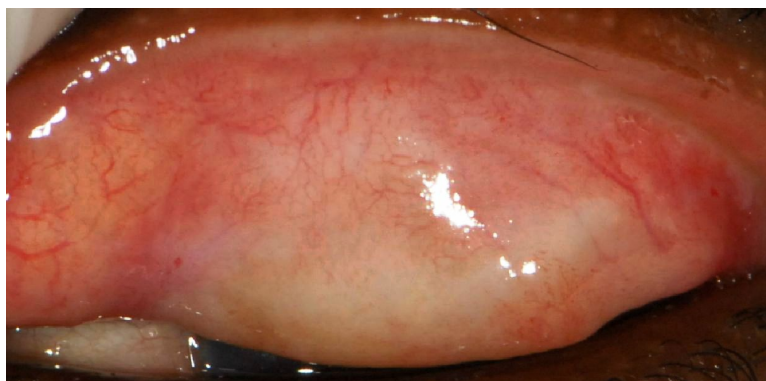



S1c



S2



S3

A portable slit-lamp to be used to rule out subtle scarring in potential control subjects.

STEP 8. Upper lid margin conjunctivalisation grading (VH)

- To be performed with the eyelid everted, so that the lid margin is visible.
- Grading:

- | | |
|------|--|
| CM 0 | No conjunctivalisation of the lid margin with the meibomian gland orifices in a normal position. |
| CM 1 | The muco-cutaneous junction is located anterior to its normal position, but the whole line is still posterior to the line of Meibomian gland orifices. |
| CM 2 | The muco-cutaneous junction is located anterior to the line of the Meibomian gland orifices for less than 50% of the lid. |
| CM 3 | The muco-cutaneous junction is located anterior to the line of the Meibomian gland orifices for greater than 50% of the lid. |

STEP 9. Photography of the tarsal conjunctiva (HM)

To be performed in a standard manner

STEP 10. Confocal microscopy of the tarsal conjunctiva (VH)

- Fresh sterile tomocap to be used for each examination.
- Viscotears to be inserted between tomocap and laser probe.
- A second drop of proxymetacaine to be instilled into the eye prior to the scan.
- Subject details to be entered onto the CLSM (confocal laser scanning microscopy) laptop, including ID number, first and last names, date of birth.
- HRT3 machine to be used with standard settings:
 - o auto brightness
 - o FV400 lens
 - o Focus on +12 dioptries
- Upper lid to be everted. PaM will help to keep the lid everted with the use of a sterile cotton bud holding the lashes.
- When the end of the second bright reflection of the tomocap seen, the digital micrometer gauge to be set to zero.
- The tomocap will be applanated onto the upper palpebral conjunctiva with digital images visualized directly on the laptop screen.
- 10 volume scans, each of 40 individual scans, to be taken. The scans should be spaced out over zones 2 and 3.

STEP 11. Conjunctival swab for Chlamydial RNA (VH)

- Swabs to be taken in a standard manner similar to the bacteriology swab.
- Evert upper lid.
- Sweep swab horizontally four times with a quarter turn of swab after each pass.
- Place swab into RNAlater tube.
- Seal the tube.
- Record the swab label number in the patient's record.
- Place tube in cool box.
- Label the next tube in preparation.

STEP 12. Conjunctival swab for Chlamydial DNA swab (VH)

- To be taken in standard manner, as above.
- Evert upper lid
- Sweep swab horizontally four times with a quarter turn of swab after each pass.
- Place swab into empty tube.
- Seal and label tube.
- Record the swab label number in the patient's record.
- Place tube in cool box
- Label the next tube in preparation.

RNA extraction

In our study conjunctival swabs were placed in RNALater® to stabilise the RNA and kept at -80°C. Total RNA was subsequently extracted using the RNeasy Mini Kit system (Qiagen, Crawley, UK) which is very effective in retrieving small amounts of RNA.

Reverse transcription

DNA polymerase can only act on DNA templates. Therefore, the RNA is reverse transcribed to cDNA using reverse transcriptase. Two-step PCR was performed in this study in which the reverse transcription was performed in a separate step to the PCR. The QuantiTect Multiplex NoROX Kit (Qiagen) was used in this study.

Amplification of cDNA using PCR

A combination of various components are added to the cDNA which include:

- Two primers that are complementary to the 3' ends of each of the sense and anti-sense strand of the cDNA target.
- Heat stable DNA polymerase (e.g. *Taq* polymerase).
- Dextroynucleoside triphosphates (dNTPs) which form the building blocks from which new DNA strands are synthesized.
- Buffer solution with cations provide an environment in which DNA amplification can occur.
- Fluorescent reporter probes which detect DNA containing the probe sequence.

The PCR was carried out in a reaction volume of 25µl in a thermal cycler (Rotor-Gene 6000 Corbett Research, Cambridge, UK). This normally consist of around 40-45 repeated temperature change cycles (the specific temperature and length of time depend on factors such as the enzyme used for DNA synthesis, melting temperature of the primers and dNTPs used) :

- Initialisation: heating to 95°C for 15 minutes for heat activation of the DNA polymerase.
- Denaturation: heating to 94°C for 30 seconds to cause melting of the cDNA template by disrupting hydrogen bonds between complementary bases resulting in single-stranded DNA molecules.
- Annealing and extension: the temperature is lowered to 60°C for 30 seconds allowing annealing of specific primers that are complimentary to a site on each strand. Polymerase binds to the primer-template complex and extends the DNA from the primers to form two new cDNA strands
- The denaturation and annealing/extension steps are repeated, doubling the number of cDNA strands with each cycle. After x cycles there are 2^x times as many strands as there was to start with. The reaction reaches a plateau when the reagents are used up.

Real Time PCR

This allows quantification of the amount of the specific cDNA target initially present, even in small samples, as the reaction progresses. Real time quantification can utilize either fluorescent dyes that bind non-specifically to double-stranded DNA, such as SYBR Green, or fluorescent probes that are sequence specific and consist of labeled oligonucleotides. Fluorescent reporter probes detect only the DNA containing the probe sequence and help to increase specificity and have to be used in multiplex assays. Dual-labeled fluorescent reporter probes are single-stranded oligonucleotides labeled with a reporter dye at the 5' end and a quencher molecule at the 3' end. The quencher molecule inhibits the natural fluorescence of the reporter dye. During the annealing stage of the PCR both probe and primers anneal the DNA target. The polymerase starts polymerization at the primer, once it reaches the probe it breaks the reporter-quencher proximity allowing emission of fluorescence which can be detected after excitation with a laser.

Quantification depends on analyzing the PCR reaction when the amount of cDNA, and therefore fluorescence, is increasing exponentially. Relative concentrations of DNA present during this phase are determined by plotting fluorescence against cycle number on a logarithmic scale (which will show a straight line during the exponential stage). A threshold for detection of fluorescence is selected, often between a third to half-way of the linear part. The cycle threshold, C_t , is the cycle at which the fluorescence from a sample crosses the threshold. During the exponential phase the amount of DNA doubles with each cycle (if the efficiency of the reaction is 100%). The numbers of copies of the cDNA target can be determined by comparison to a standard curve of serial dilutions of a known amount of DNA. The measured amount of target is usually divided by the amount of reference or housekeeping gene to normalize for variation in the amount and quality of RNA in different samples. The delta delta or comparative C_t method uses the difference in the C_t between the target of interest and housekeeping gene in cases or samples of interest, and compares this to the results from a control group. The amplification efficiencies of the target and housekeeping need to be approximately equal.

Multiplex PCR

Multiple primer sets within a single PCR reaction mixture are used to produce amplification products that are specific for different cDNA targets. Different reporter probes are also used, specific for each target, that have unique emission spectra. The amount of different cDNA targets can therefore be detected in the same reaction mixture, using a single sample, by detection of the different wavelengths of light emitted. This can help to maximize use of limited sample and is more time-efficient.

Figure 1: Amplification curves of samples from the TS study. A 100-well plate was used: 44 samples (coloured lines), 5 standards (brown lines), water as a negative control (blue lines), all in duplicate. Four different channels are used for detection of different wavelengths of light, allowing 4 different reporter probes to be used.

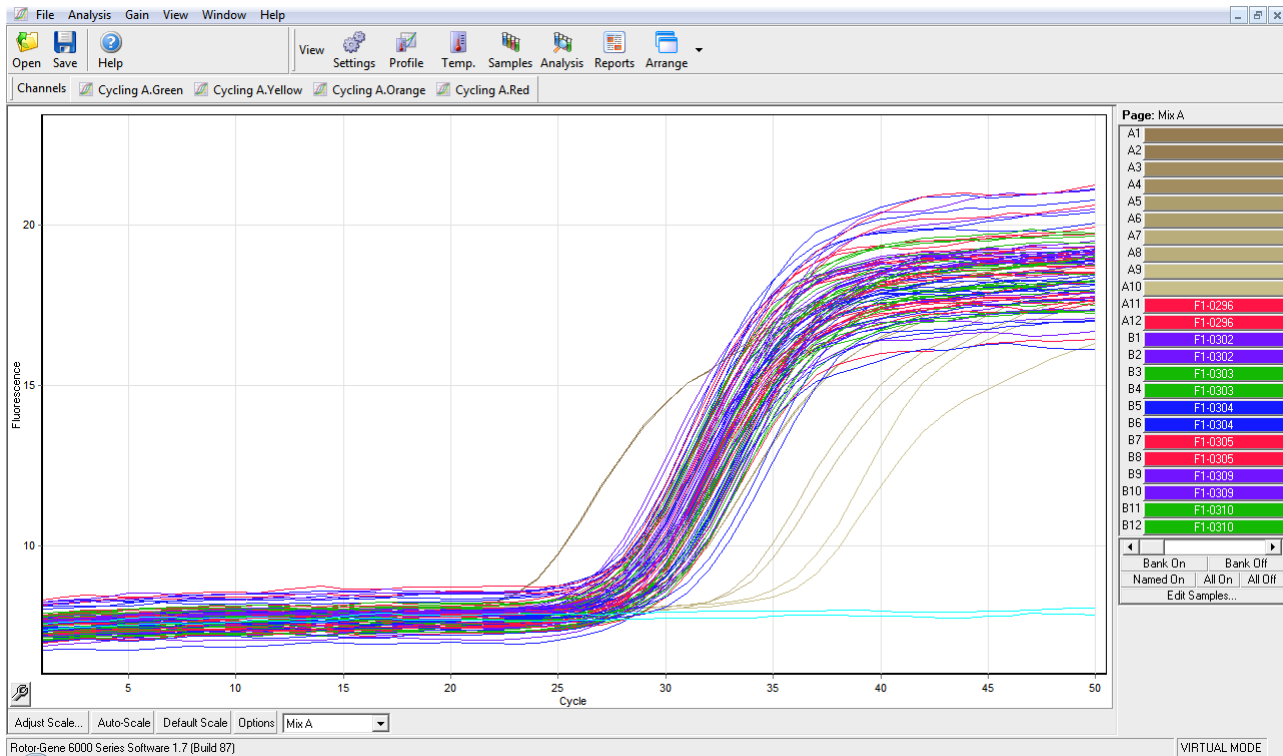


Figure 2: Amplification curves of the standards. Five standards of known concentration of the target gene were used in duplicate. Concentrations ranged from 10^2 copies (amplified last) to 10^6 copies (amplified first) of DNA. The higher the concentration the earlier the amplification occurs.

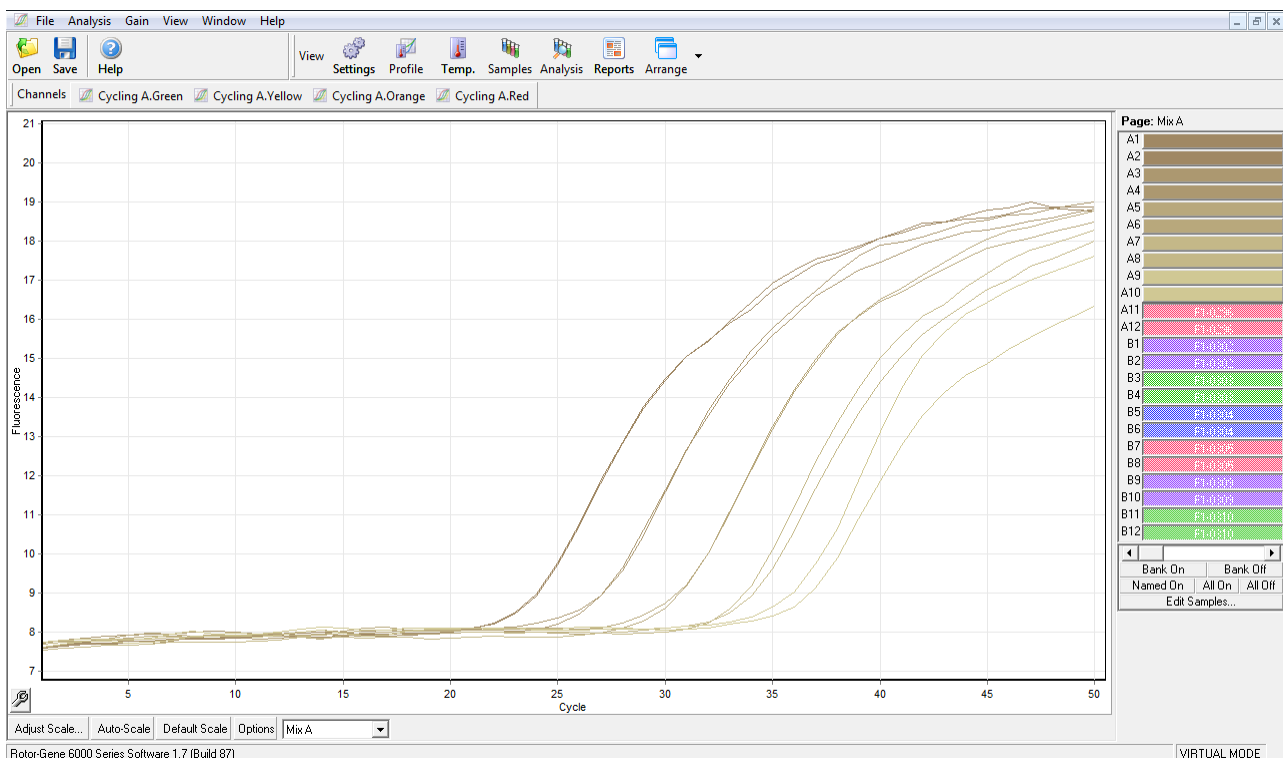


Figure 3: Amplification curves of the standards during the linear phase.

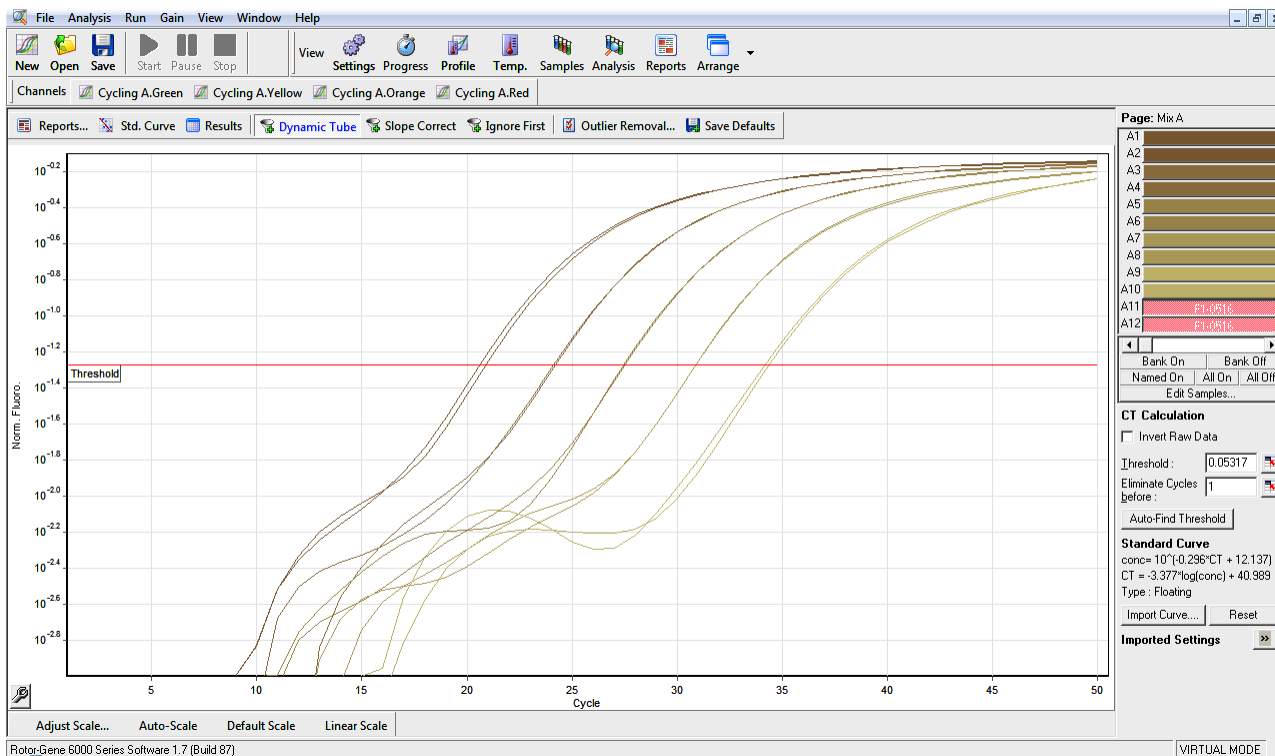


Figure 4: Efficiency of the standard curves (98%).

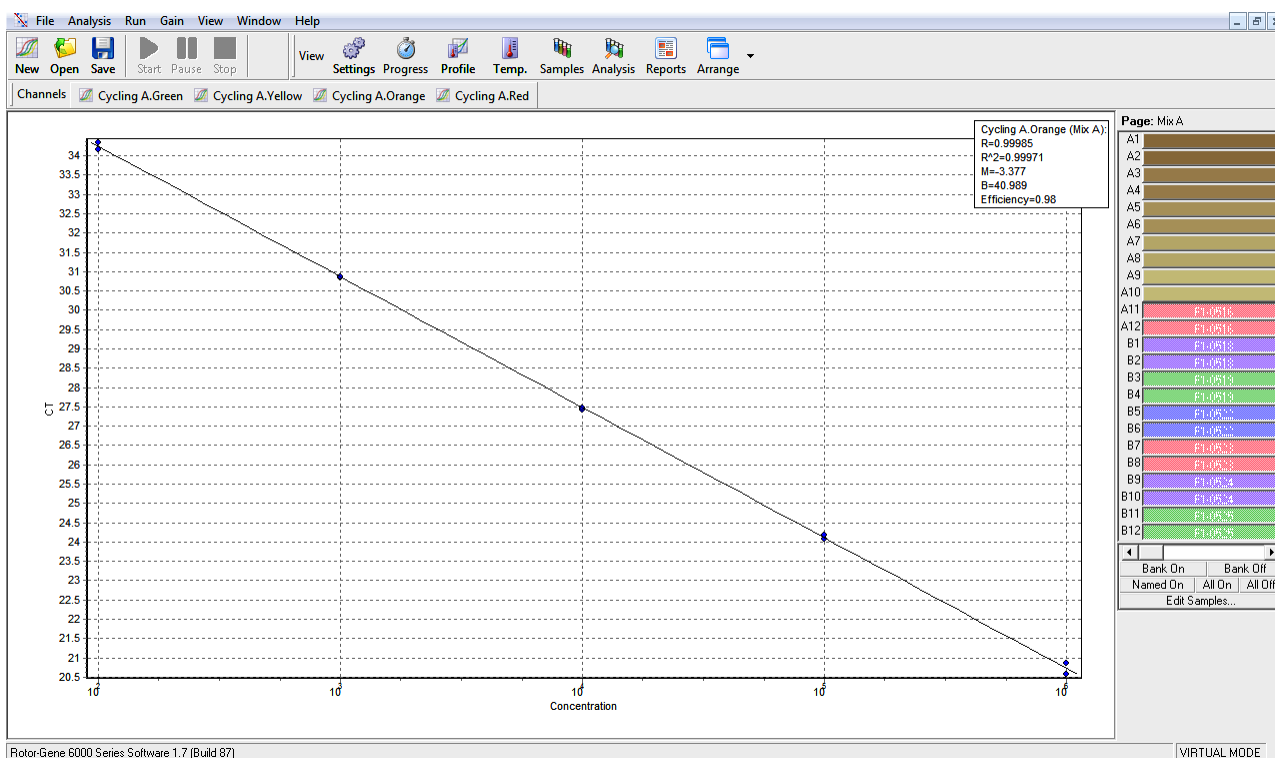


Figure 5: Amplification of all 100 wells during the linear phase.

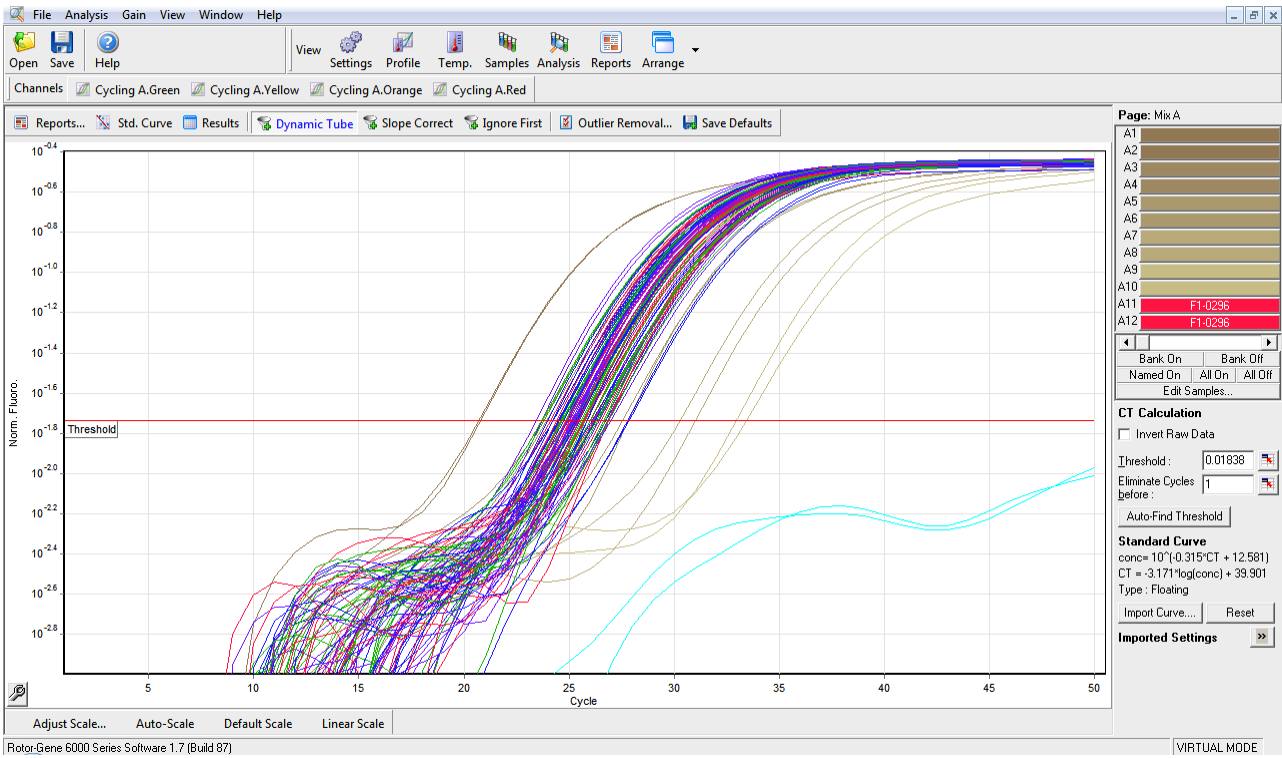
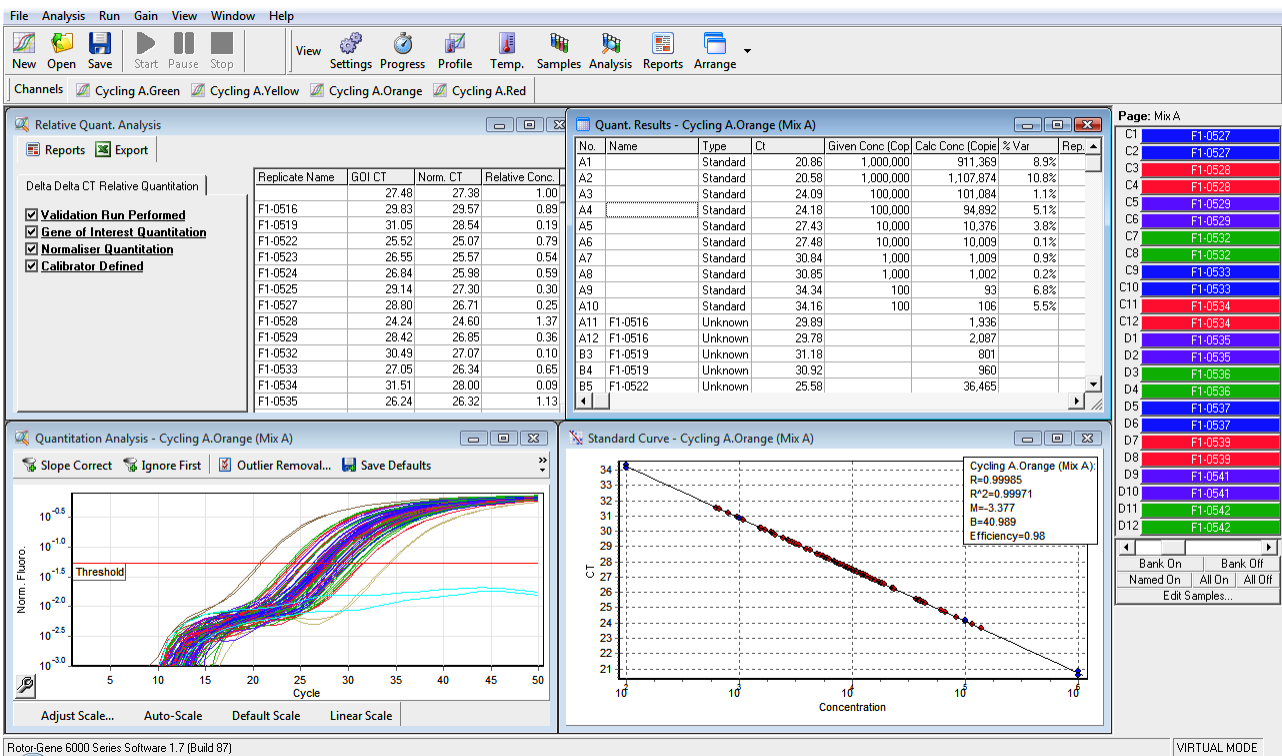


Figure 6: Delta delta Ct calculation.



Fixation

This is the process of preserving the tissue architecture from degradation so that the cellular and sub-cellular components can be examined. Buffered 10% formalin, which contains 4% formaldehyde, or a similar agent, is commonly used for light microscopy. These irreversibly cross-link proteins and may reduce the biological functionality of enzymes. Some antigens may not survive this fixation process and for these tissues frozen sections could be cut with the use of a cryostat.

Embedding

Paraffin is the most commonly used medium for embedding specimens. Infiltration of the tissue with paraffin allows thin sections to be cut. Before this can be done water needs to be removed from the tissue which is done by moving the sample through increasingly concentrated ethanol. This is followed by a hydrophobic clearing agent such as xylene to remove the alcohol. Molten paraffin wax then replaces the xylene. A microtome is used to cut thin sections.

Tinctorial stains

Special chemical agents are used to stain specific targets in the tissue. Hematoxylin and eosin is commonly used. Hematoxylin is a basic dye that stains nuclei blue and eosin is an acidic dye that stains cytoplasm pink.

Immunohistochemistry

This uses antibody binding to specific antigens. Antigen retrieval refers to the initial process of unmasking antigens and improving their detection by breaking the cross-links between proteins formed by formalin fixation. This can be done either by exposure to heat, such as with a pressure cooker, or with a proteolytic enzyme method, usually after deparaffinisation.

Reporter molecules are used in order to detect the antibody. Common techniques utilize enzymes for chromogenic detection or fluorophores for fluorescence detection. Horseradish peroxidase is a commonly used enzyme which uses diaminobenzadine as a substrate resulting in a brown stain. Antigen detection may involve the direct method where a single antibody is used which binds the antigen and is itself labeled with the reporter molecule. While quick and specific this generates little signal amplification and indirect methods are more commonly used. These involve an unlabeled primary antibody which binds the antigen. A labeled secondary antibody is then used which binds the primary antibody. Several secondary antibodies can bind to different antigenic sites on the primary antibody resulting in signal amplification. Further amplification can be achieved through the use of biotin which can be conjugated to the secondary antibody. The secondary antibody can be conjugated to several molecules of biotin. Streptavidin has a high affinity for biotin and can

also be conjugated to horse-radish peroxidase. Addition of diaminobenzadine results in the chromogenic reaction and identification of the antigen location in the tissue with microscopy.

After the immunohistochemical stain a counter-stain may be used to help show cellular compartments such as hematoxylin. Background staining may result from the antibody binding to non-specific or reactive sites, or the presence of endogenous biotin or reporter enzymes such as peroxidase. To prevent antibodies binding to non-specific or reactive sites a buffer may be used which blocks these reactive sites and enzymes.

Appendix 7a: Publisher permission for “Epidemiology and control of trachoma: systematic review”

JOHN WILEY AND SONS LICENSE TERMS AND CONDITIONS

Oct 21, 2011

This is a License Agreement between Victor Hu ("You") and John Wiley and Sons ("John Wiley and Sons") provided by Copyright Clearance Center ("CCC"). The license consists of your order details, the terms and conditions provided by John Wiley and Sons, and the payment terms and conditions.

All payments must be made in full to CCC. For payment instructions, please see information listed at the bottom of this form.

License Number

2773591343807

License date

Oct 21, 2011

Licensed content publisher

John Wiley and Sons

Licensed content publication

Tropical Medicine & International Health

Licensed content title

Epidemiology and control of trachoma: systematic review

Licensed content author

Victor H. Hu, Emma M. Harding-Esch, Matthew J. Burton, Robin L. Bailey, Julbert Kadimpeul, David C. W. Mabey

Licensed content date

Jun 1, 2010

Start page

673

End page

691

Type of use

Dissertation/Thesis

Requestor type

Author of this Wiley article

Format

Print and electronic

Portion

Full article

Will you be translating?

No

Appendix 7b: Publisher permission for “Trachoma: an update”

Greycoat Publishing <production@greycoatpublishing.co.uk>

Subject: Re: FAO Ashley Wallis: URGENT: Permission to republish Trachoma: an update
Date: 25 October 2011 13:00:04 GMT+01:00
To: Victor Hu <victor.hu@lshtm.ac.uk>

Dear Victor

My apologies for not responding to your earlier e-mails. We have had several titles going to press over the past week so it has been pretty busy to say the least.

We have no objection to you republishing your article ‘Trachoma: an update’ as part of your PhD thesis. All that we would ask is if you could credit the source: Ophthalmology International, Winter 2010, Volume 5, No. 4, pages 99–105.

Kind regards

Ashley Wallis

Greycoat Publishing Ltd
148 Buckingham Palace Road
London SW1W 9TR
UK

Tel: +44 (0)20 7730 7995
Fax: +44 (0)20 7730 3884

From: Victor Hu <victorhu@doctors.org.uk>

Subject: Permission to republish Trachoma: an update

Date: 21 October 2011 13:15:43 GMT+01:00

To: Greycoat Publishing <production@greycoatpublishing.co.uk>, Catherine Tighe <c.tighe@greycoatpublishing.co.uk>

Dear Ashely and Catherine,

I would like to ask for permission to use this article as part of my PhD thesis with the London School of Hygiene and Tropical Medicine (University of London).

Many thanks,

Victor

Appendix 7c: Publisher permission for “In vivo confocal microscopy of trachoma in relation to normal tarsal conjunctiva”

This is a License Agreement between Victor Hu ("You") and Elsevier ("Elsevier"). The license consists of your order details, the terms and conditions provided by Elsevier, and the [payment terms and conditions](#).

License number	Reference confirmation email for license number
License date	Oct 21, 2011
Licensed content publisher	Elsevier
Licensed content publication	Ophthalmology
Licensed content title	In Vivo Confocal Microscopy of Trachoma in Relation to Normal Tarsal Conjunctiva
Licensed content author	Victor H. Hu,Patrick Massae,Helen A. Weiss,Ian A. Cree,Paul Courtright,David C.W. Mabey,Robin L. Bailey,Matthew J. Burton
Licensed content date	April 2011
Licensed content volume number	118
Licensed content issue number	4
Number of pages	8
Type of Use	reuse in a thesis/dissertation
Portion	full article
Format	both print and electronic
Are you the author of this Elsevier article?	Yes
Will you be translating?	No
Order reference number	
Title of your thesis/dissertation	Studies on the pathogenesis of trachomatous scarring
Expected completion date	Nov 2011
Estimated size (number of pages)	250
Elsevier VAT number	GB 494 6272 12

Appendix 7d: In vivo confocal microscopy in scarring trachoma

Thank you very much for your order. This is a License Agreement between Victor Hu ("You") and Elsevier ("Elsevier"). The license consists of your order details, the terms and conditions provided by Elsevier, and the [payment terms and conditions](#).

License number	Reference confirmation email for license number
License date	Oct 21, 2011
Licensed content publisher	Elsevier
Licensed content publication	Ophthalmology
Licensed content title	In Vivo Confocal Microscopy in Scarring Trachoma
Licensed content author	Victor H. Hu,Helen A. Weiss,Patrick Massae,Paul Courtright,William Makupa,David C.W. Mabey,Robin L. Bailey,Matthew J. Burton
Licensed content date	13 September 2011
Number of pages	1
Type of Use	reuse in a thesis/dissertation
Portion	full article
Format	both print and electronic
Are you the author of this Elsevier article?	Yes
Will you be translating?	No
Order reference number	
Title of your thesis/dissertation	Studies on the pathogenesis of trachomatous scarring
Expected completion date	Nov 2011
Estimated size (number of pages)	250
Elsevier VAT number	GB 494 6272 12

Appendix 7e: Publisher permission for "Bacterial infection in scarring trachoma"

Customer: Victor Hu

Account Number: 3000392477

Investigative ophthalmology & visual science

Order detail ID: 57865800

ISSN: 1552-5783

Publication year: 2011

Publication Type: e-Journal

Publisher: ASSOCIATION FOR RESEARCH IN VISION AND
OPHTHALMOLOGY

Rightsholder: INVESTIGATIVE OPHTHALMOLOGY & VISUAL
SCIENCE

Author/Editor: Hu VH et al

Your reference: Victor Hu thesis

Permission Status: **Granted**

Permission type: Republish or display content

Type of use: Republish in a dissertation

Republication title: Studies on the pathogenies of
trachomatous scarring

Republicing organization: London School of Hygiene and
Tropical Medicine

Organization status: Non-profit 501(c)(3)

Republication date: 11/01/2011

Circulation/ Distribution: 5

Type of content: Full article/chapter

Description of requested content: Bacterial infection in
scarring tracoma

Page range(s): 2181-2186

Translating to: No Translation

Requested content's publication date: 11/01/2011

Appendix 7f: Publisher permission for “Innate immune responses and modified extra-cellular matrix regulation characterize bacterial infection and cellular/connective tissue changes in scarring trachoma

From: ASM Journals <Journals@asmusa.org>
Subject: RE: IAI05965-11R1 Request for permission
Date: 19 October 2011 19:43:21 GMT+01:00
To: Victor Hu <victor.hu@lshtm.ac.uk>

Good Afternoon,

ASM authors retain permission to reuse material from their accepted manuscripts/ published articles, and need only cite the original paper in a credit line.

From the IAI Instructions to Authors: http://iai.asm.org/misc/journal-ita_org.dtl#02

(iv) Referencing ASM Accepts (publish-ahead-of-print) manuscripts. Citations of ASM Accepts manuscripts should look like the following example.

Wang, G. G., M. P. Pasillas, and M. P. Kamps. 15 May 2006. Persistent transactivation by Meis1 replaces Hox function in myeloid leukemogenesis models: evidence for co-occupancy of Meis1-Pbx and Hox-Pbx complexes on promoters of leukemia-associated genes. Mol. Cell. Biol. doi:10.1128/MCB.00586-06.

Please let us know how we may be of further assistance.

Thank you.
ASM Journals
journals@asmusa.org

From: Victor Hu [mailto:victor.hu@lshtm.ac.uk]
Sent: Wednesday, October 19, 2011 10:39 AM
To: ASM Journals
Cc: Smith, Diane
Subject: Fwd: IAI05965-11R1 Request for permission

Dear ASM Journals,

The above submission has been accepted for publication in Infection & Immunity. I would like to ask for permission to use the manuscript as part of my PhD submission with the London School of Hygiene and Tropical Medicine. The PhD submission will be happening shortly, before the article is published by I&I.

Many thanks,

Victor Hu