

## Clinical Review

# Age related macular degeneration

BMJ 2010; 340 doi: <http://dx.doi.org/10.1136/bmj.c981> (Published 26 February 2010) Cite this as: BMJ 2010;340:c981

- [Article](#)
- [Related content](#)
- [Metrics](#)
- [Responses](#)
- [Peer review](#)
- [Feedback](#)

Usha Chakravarthy, professor of ophthalmology and vision sciences<sup>1</sup>, Jennifer Evans, PhD<sup>2</sup>, Philip J Rosenfeld, professor of ophthalmology<sup>3</sup>

[Author affiliations](#)

Correspondence to: U Chakravarthy [u.chakravarthy@qub.ac.uk](mailto:u.chakravarthy@qub.ac.uk)

## Summary points

The late stage manifestations of age related macular degeneration, neovascularisation and geographic atrophy, cause severe loss of central vision

Standard care for neovascular age related macular degeneration is treatment with monoclonal antibodies that inhibit vascular endothelial growth factor. A fifth of those treated do not respond to treatment and a further quarter may lose the initial gains in visual acuity over time.

No proven treatments exist for geographic atrophy. The preventive effects of supplementation with macular carotenoids (lutein/zeaxanthin) and omega-3 fatty acids are under investigation.

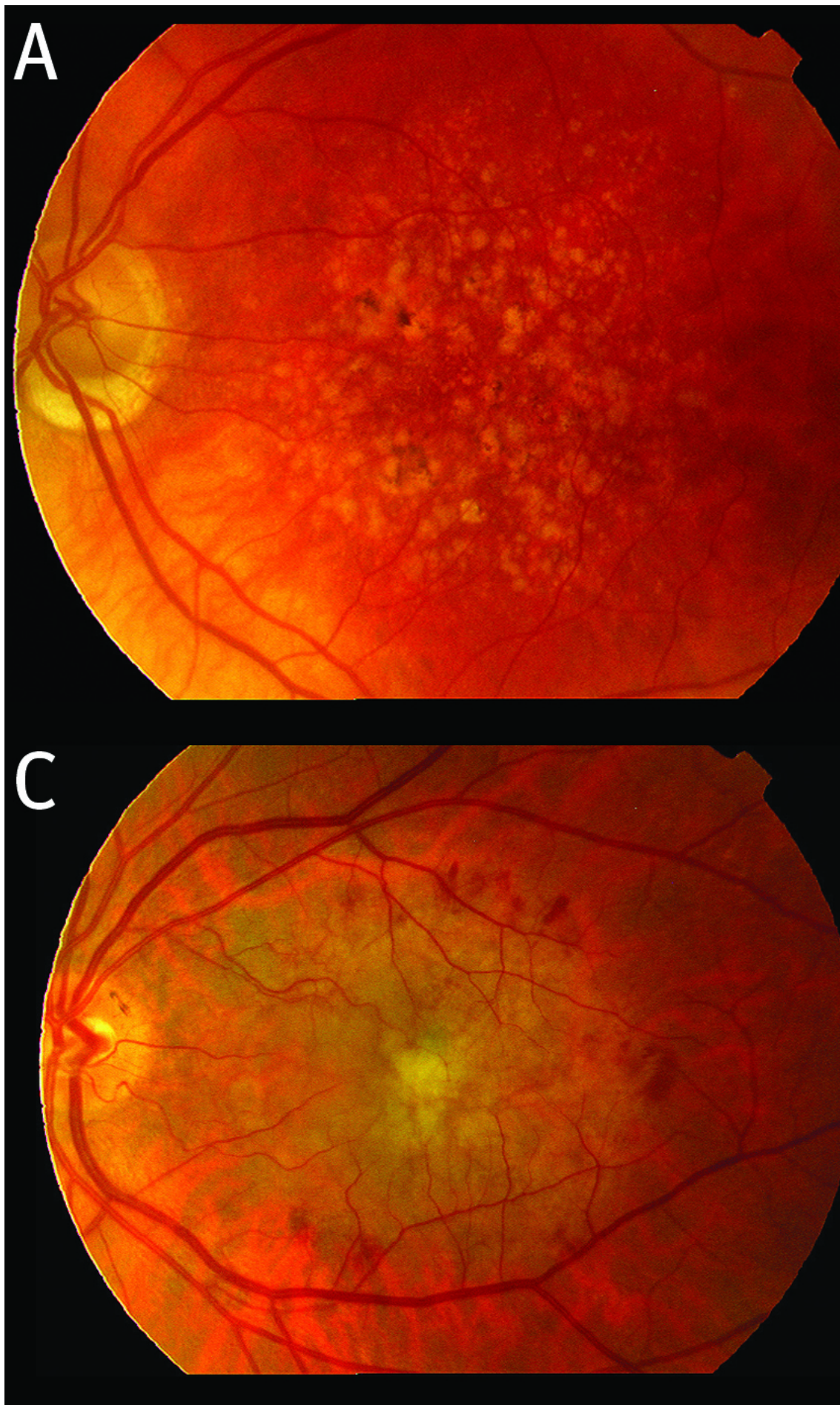
Age related macular degeneration, as the term implies, affects older adults and accounts for about half of all vision impairment or blind registrations in the developed world.<sup>1</sup> Its prevalence is increasing with the demographic shift towards an ageing society. Recent evidence from large scale population based epidemiological studies confirms that it is also a major cause of sight loss in the developing world, in countries such as India,<sup>2</sup> where life expectancy continues to rise. The two vision threatening manifestations of age related macular degeneration occur either as a consequence of neovascularisation, which causes an acute exudative pathology, or from cell loss due to geographic atrophy. Both neovascular age related macular degeneration and geographic atrophy result in reduced central vision with inability to undertake tasks that require visual discrimination, such as reading, driving, and recognising faces. The main aims of treatment are either to prevent the progression of early features to the late stage manifestations or to treat the symptoms of advanced disease if these do occur. Currently, intravitreal treatment with humanised monoclonal antibodies against vascular endothelial growth factor is used to ameliorate the acute manifestations of neovascular age related macular degeneration. This review examines the pathogenesis of age related macular degeneration and recent advances in its management.

## Sources and selection criteria

We searched Medline, EMBASE, the Cochrane Library, the NIH clinical trials database ([www.clinicaltrials.gov](http://www.clinicaltrials.gov)), and EUDRACT with the medical subject headings "age-related maculopathy", "age-related macular degeneration", "macular degeneration", "geographic atrophy", "neovascular AMD", "exudative AMD", and "controlled clinical trials". We used evidence from published abstracts from major international scientific meetings, the UK National Institute for Health and Clinical Excellence (NICE) technology appraisals, guidelines on the treatment of the condition from the UK Royal College of Ophthalmologists, and ophthalmic technology assessments of the American Academy of Ophthalmology. Priority was given to evidence obtained from well conducted systematic reviews and large well designed randomised controlled trials. Overall the quality of the evidence supporting the use of ranibizumab as the standard of care for neovascular age related macular degeneration with foveal involvement was high.

## What is macular degeneration?

The macula is the central area of the fundus of the eye that is easily seen on ophthalmoscopy and comprises a region bounded by the optic nerve and the superior and inferior retinal vascular arcades (fig 1A).<sup>↓</sup> A large range of inherited and acquired conditions fall into the category of macular degeneration. This review focuses only on the most common, age related macular degeneration. Early age related macular degeneration is said to be present when a spectrum of changes is observed in the ageing eye before the onset of overt vision loss. These changes include drusen, which are focal yellowish coloured deposits, and alterations in the pigmentation (hypopigmentation and hyperpigmentation) of the macula. The term late age related macular degeneration is applied when neovascularisation and/or geographic atrophy are observed. The term dry macular degeneration is frequently encountered in the lay literature and the scientific press, with potential for confusion, since it is used to signify the presence of drusen, pigmentary irregularities, or both, as well as geographic atrophy. Therefore the terms early and late macular degeneration are preferable.



**Fig 1 (A)** Fundus photograph of left eye with multiple discrete yellowish lesions (drusen) and focal areas of hyperpigmentation seen in the photograph. **(C)** accompanying fluorescein angiogram of the same eye. The colour image shows a diffuse pale yellowish lesion occupying the macula with haemorrhagic leakage, obscuring the margins of the abnormal vascular structures. The dark margins represent the normal vascular structures.

## What do we know about the pathogenesis of age related macular degeneration?

The molecular pathways leading to age related macular degeneration remain to be elucidated. The retina and its pigmented epithelium are unique among body tissues in their constant exposure to light energy and high oxygen concentrations, both of which are potent sources of free radicals—therefore, it has been suggested that the cumulative effects of oxidative stress over a lifetime may be the initiating stimulus for macular degeneration.<sup>3</sup> Concordant with this hypothesis are the findings of epidemiological studies, which show that cigarette smoking and a high lifetime exposure to sunlight are risk factors.<sup>4 5</sup> One recent cross sectional population based study in the European Union found that people with low levels of antioxidants in their serum combined with high cumulative lifetime sunlight exposure had a twofold increased risk of developing late macular degeneration.<sup>5</sup>

More recently, consistent associations between the clinical spectrum of age related macular degeneration and polymorphisms in genes encoding proteins involved in immune regulation have been observed and provide additional insights into how this condition may develop. The first gene to be implicated was the complement factor H gene, in which a single nucleotide substitution of thymine to cytosine at position 1277 in exon 9 results in a tyrosine to histidine change in the amino acid chain (Y402H polymorphism).<sup>6</sup> Polymorphic variation in the complement factor 3 and B2 genes also result in an increased susceptibility to this condition,<sup>7</sup> whereas deletions in the complement factor H related genes are protective.<sup>8</sup> Carriage of the at-risk alleles at multiple complement loci confer additive risks and, when combined with information on lifestyle factors such as smoking, can account for as much as 80% of the risk.<sup>9</sup> Since immune proteins are localised in drusen in the human eye,<sup>10</sup> and because transgenic mice with defective complement function are abnormally sensitive to oxidative stress,<sup>11</sup> it has been hypothesised that the polymorphisms create conditions that allow damage to Bruch's membrane and the retinal pigment epithelium, leading to development of disease.

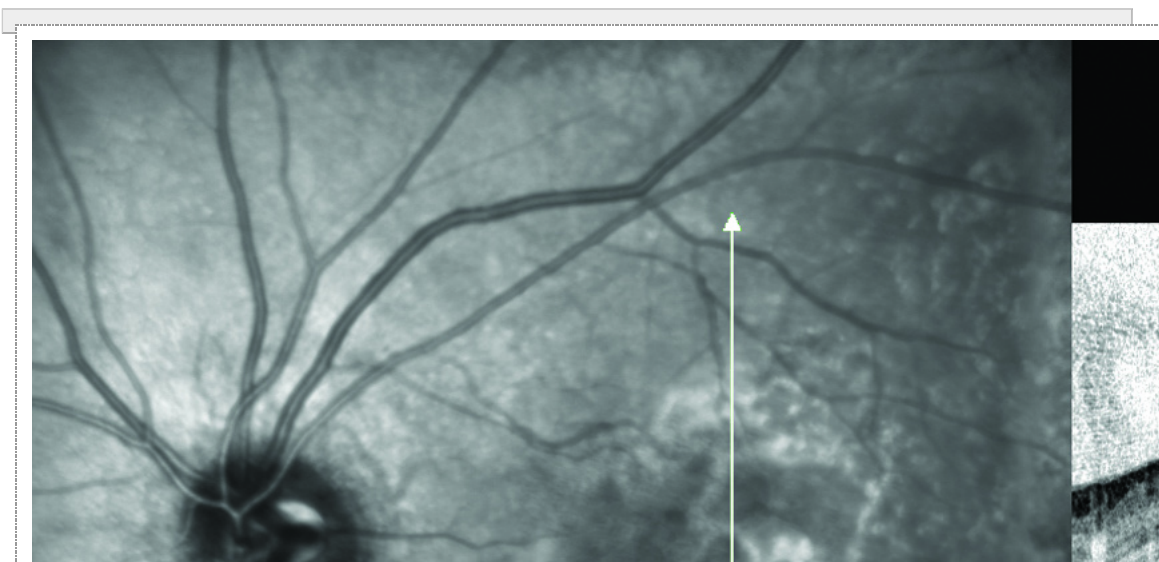
## What is the natural history of macular degeneration ?

Early macular degeneration can progress to late manifestations with sight loss in a proportion of people. The risk of progression is highly variable and depends on the severity and extent of the features of early macular degeneration. The age related eye diseases study has quantified this risk, and showed that people with small drusen in both eyes have a very low risk of progression—between 0.4% and 3.0% over five years.<sup>12</sup> However if large drusen and pigmentary abnormalities are present in both eyes this risk increases to around 47.3%.<sup>12</sup> Initially, geographic atrophy develops as focal areas of depigmentation. Eventually these coalesce or expand to involve the central macula causing progressive worsening of vision, and legal blindness can ensue after many years. Neovascular complications on the other hand have a more acute onset with sudden development of central blurring and distortion. Left untreated the area of neovascularisation expands rapidly and a large fibrous scar develops in the macula. A recent meta-analysis<sup>13</sup> of data from several controlled clinical trials showed that within three years of the onset of neovascularisation more than half of untreated eyes will have a level of vision of 20/200 (Snellen 6/60) or worse, which is within the WHO definition of severe visual impairment. When both eyes are affected with late stage age related macular degeneration sight can be markedly reduced and tasks that require visual discrimination, such as reading, driving, and recognising faces become difficult.

## How is the diagnosis made?

Since the presence of small areas of geographic atrophy is compatible with good vision, the diagnosis is often incidental during attendance at regular eye examinations. On the other hand, patients who develop neovascular disease will usually complain of central distortion and blurring in the affected eye. When late neovascular disease affects only one eye, however, the condition may be an incidental finding. The diagnosis is usually evident on clinical examination and fundus photography (fig 1A). If neovascularisation is present, fluorescein angiography, a method for examining the intraocular vascular beds, reveals the abnormal blood vessels which often leak profusely (fig 1D).

Optical coherence tomography is now used to image the retina and the retinal pigment epithelium non-invasively. It has provided a rapid method of assessing the macular tissues (fig 2A). The tomograms provide cross sectional views of the macula and abnormal tissue such as the choroidal neovascular membrane can be seen. The extent and severity of the exudative response, which causes separation of the tissue layers, may be visualised. When geographic atrophy is present, thinning of the macular tissues is seen but without separation of the layers. Thus tomography can be helpful in distinguishing neovascularisation and particularly in monitoring the therapeutic response.



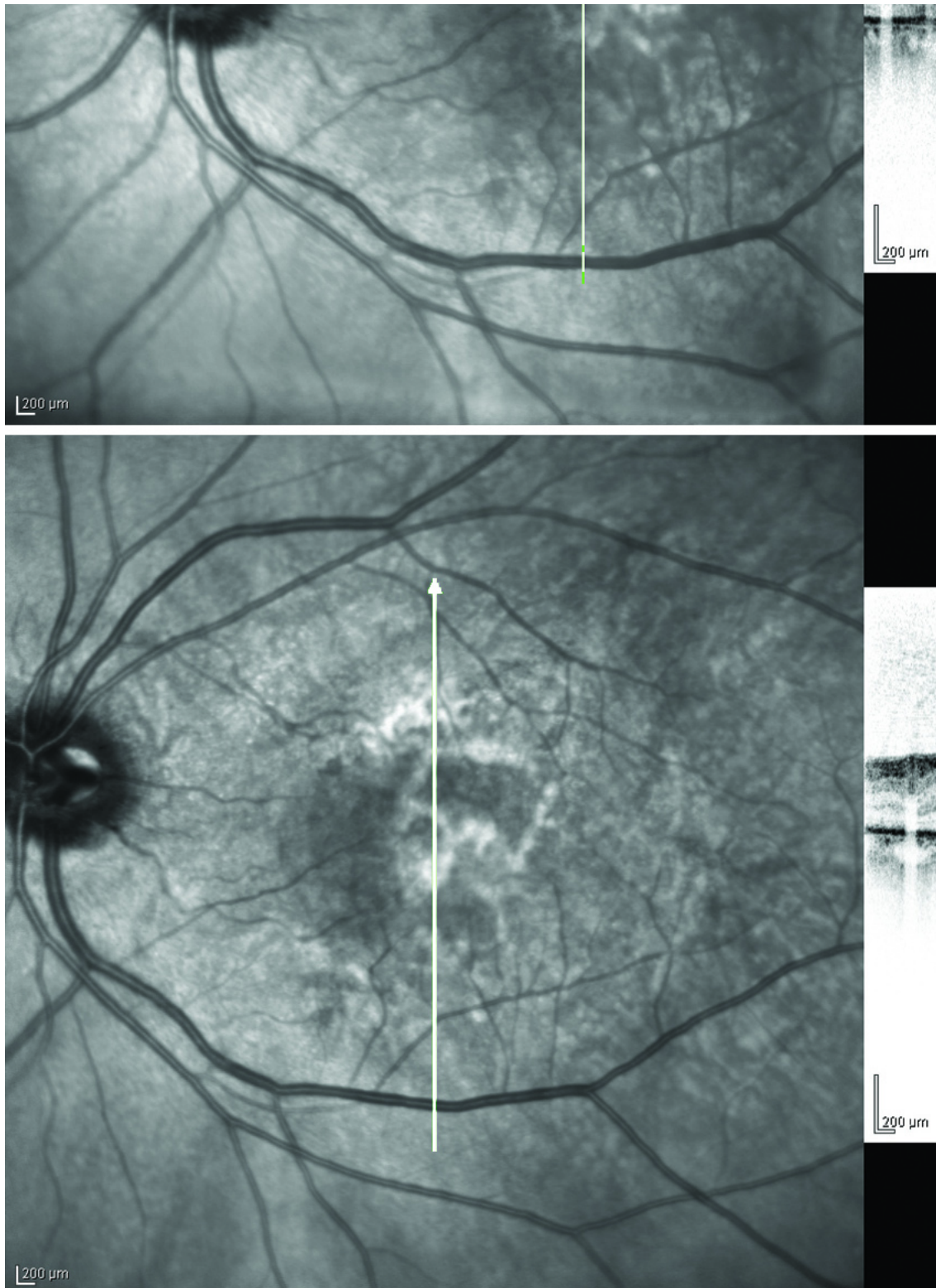


Fig 2 (A) High resolution spectral domain optical coherence tomogram of the same eye shown in fig 1C and 1D, showing fluid filled spaces in the cellular layers. (B) The eye one month after receiving the first intravitreal injection of ranibizumab, with marked improvement in the cellular layers.

- 
- 

[Download figure](#)  
[Open in new tab](#)  
[Download powerpoint](#)

## What are the principles of management?

The principles of management can be broadly divided into prevention in the early stages and treatment to ameliorate symptoms if late stage complications develop.

### Preventing progression

Research into the prevention of age related macular degeneration has focused on risk factors that exacerbate oxidative stress or interventions that ameliorate their effects, such as supplementation with antioxidant vitamins, particularly the macular carotenoids lutein and zeaxanthin. Stopping cigarette smoking is recommended since its adverse association with late age related macular degeneration is unequivocal.

The evidence as to whether diets rich in antioxidant micronutrients will prevent the development of age related macular degeneration is less consistent. The age related eye diseases clinical trial found that supplementation with high doses of beta-carotene, vitamins C and E, and zinc reduced the relative risk of progression from early to late disease by about 20%.<sup>14</sup> However, high doses of dietary supplements, particularly beta-carotene, may be harmful to smokers and may not be without risk.<sup>15</sup> The benefits and harms of taking supplements need to be assessed for the individual. Accumulating evidence from longitudinal observational studies supports the view that retinal function may be improved or better maintained after supplementation with carotenoids and anti-oxidants.<sup>16</sup>

### Treating symptoms

Once neovascular age related macular degeneration has manifested, monotherapy with an anti-vascular endothelial growth factor drug (administered into the vitreous) is the current standard of care. These drugs represent the era of biological medicines (“biologicals”) for the management of neovascular disease and their introduction has resulted in a shift away from laser based treatments. In previous decades, ablation of the area of neovascularisation with thermal laser or induction of vascular thrombosis by photodynamic therapy were used. These laser treatments were effective compared with natural history in restricted subgroups of patients.<sup>17 18</sup> Effectiveness was limited by the recurrence of neovascularisation and most treated patients experienced a moderate loss of vision (defined as a fall of three or more lines of vision on the ETDRS chart) over a two year period. Therefore, the finding that pegaptanib sodium, an aptamer that selectively inhibits vascular endothelial growth factor 165, was effective in reducing vision loss and could be applied across all subgroups of neovascular age related macular degeneration was greeted with enthusiasm.<sup>19</sup> The drug was almost immediately displaced by bevacizumab, a full length humanised monoclonal antibody against vascular endothelial growth factor.<sup>20</sup> Bevacizumab was approved initially for the treatment of metastatic colorectal cancer. Soon after, ranibizumab, an antibody fragment, was shown to be highly effective in several controlled clinical trials. The 12 month results from these trials<sup>21 22</sup> indicated that up to a third of those treated with ranibizumab will have improved visual acuity, few patients will have progressed to moderate vision loss, and on average visual acuity is improved by two lines. Retinal imaging with optical coherence tomography before and after intravitreal administration of anti-vascular endothelial growth factor treatment shows marked reduction of intraretinal and subretinal fluid, often with spectacular and rapid apposition of the retinal layers and restoration of the anatomical contours (figure 2*ii*). This morphological restitution is often accompanied by improvements in visual acuity of the order of three to four lines on the ETDRS chart. Bevacizumab was reported to be safe for administration into the vitreous gel of the eye, with reductions in the exudative manifestations and improvements in acuity similar to those seen with ranibizumab, and it has since become one the most used anti-vascular endothelial growth factor agents worldwide.<sup>23</sup> Although bevacizumab remains uncensored, its worldwide use remains fuelled by the fact that it is much cheaper than ranibizumab. The findings of large head to head clinical trials of bevacizumab versus ranibizumab in the United States (The CATT study, [NCT00593450](#)) and the UK (The IVAN trial, [ISRCTN92166560](#)), and of smaller trials in Norway, Germany, Austria, and France, are awaited with much interest.

### Drawbacks of treatment

Given that the natural history of neovascular age related macular degeneration is one of progressively falling visual acuity<sup>13</sup> and that none of the previously available treatments had ever achieved improvements of this scale (fig 3*ii*); anti-vascular endothelial growth factor therapy was hailed as the cure for neovascular age related macular degeneration. However there are major drawbacks to anti-vascular endothelial growth factor treatment. Initial concerns were that the eye might not tolerate the repeated perforation required for treatment administration, and that an unacceptable frequency of serious adverse events (such as intraocular infection) might occur—but these concerns have largely receded.<sup>24</sup> Concerns that remain include the need for monthly monitoring and re-treatment, which creates a huge burden on resources, and the theoretical possibility that long term inhibition of vascular endothelial growth factor could adversely affect the health of neural retina, the retinal pigmented epithelium, and choriocapillaris, since these tissues constitutively express vascular endothelial growth factor and rely on it for maintained health. More recently studies have found that around 20% of people with neovascular age related macular degeneration treated with anti-vascular endothelial growth factor therapy will lose vision over time.<sup>25</sup> A further proportion (about a fifth to a third) may lose the initial improvements in visual acuity. These losses may be the consequence of attempts to decrease the frequency of drug administration or may result from underlying disease progression even though the pathological effects of neovascularisation have been dealt with. These findings have dampened the initial enthusiasm for such treatment.

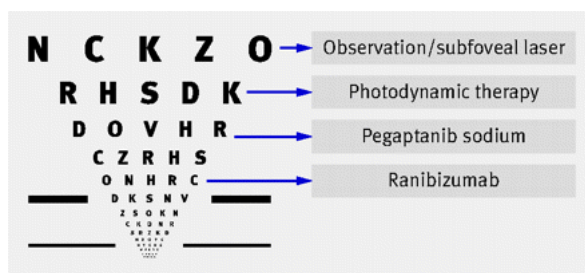


Fig 3 ETDRS chart. Arrows show mean levels of visual acuity achieved after two years of observation only or different treatments

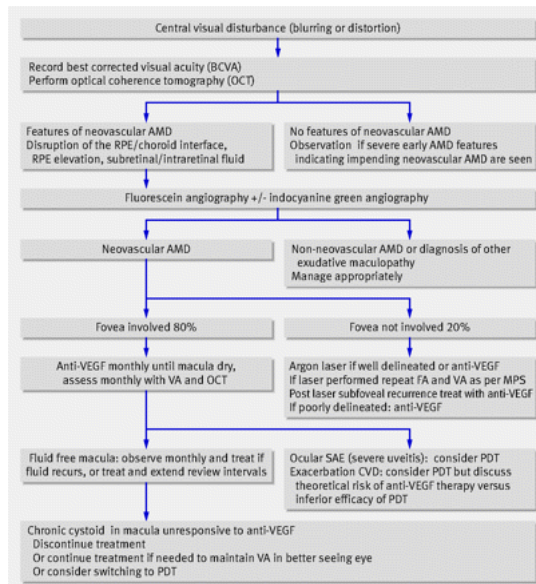
- 
- 
- 

[Download figure](#)  
[Open in new tab](#)  
[Download powerpoint](#)

## What do current guidelines recommend?

Subsequent to the technology appraisal and issue of guidance<sup>26</sup> by the National Institute for Health and Clinical Excellence, ranibizumab has been widely adopted as the treatment of choice for subfoveal neovascular age related macular degeneration in the UK. However, the high cost of ranibizumab, along with the positive clinical experience with bevacizumab, has resulted in the majority of patients in the United States and other countries being treated with the latter drug.

In the UK, updated guidelines<sup>27</sup> for the management and treatment of neovascular age related macular degeneration have been published by the Royal College of Ophthalmologists, but the clinical algorithm shown in figure 4*ii* reflects the worldwide pattern of use of anti-vascular endothelial growth factor therapy.



**Fig 4 Clinical algorithm based on principles commonly applied in management of neovascular age related macular degeneration.**  
**AMD=age related macular degeneration, RPE=retinal pigmented epithelium, VEGF=vascular endothelial growth factor, VA=visual acuity,**  
**MPS=macular photocoagulation study, PDT=photodynamic therapy.**

- [Download figure](#)
- [Open in new tab](#)
- [Download powerpoint](#)

## What can current treatment achieve?

The ultimate treatment goal when neovascular age related macular degeneration has already supervened is to achieve perfect central vision with normal or near normal foveal and macular anatomy. Complete cessation of exudation can result in good apposition of the tissue layers and reduction of metamorphopsia. Most patients, however, report difficulty with reading small print and other visually demanding tasks even when tissue contours have been restored. High resolution optical coherence tomography scans obtained after anti-vascular endothelial growth factor treatment show persistent abnormalities of the outer retina even though the tissues appear to be fluid free.<sup>28</sup> In other cases where atrophy and fibrosis have already occurred, considerable impairment of central visual function can remain despite the achievement of a fluid free macula.

Although thermal laser photocoagulation and photodynamic therapy are less effective than ranibizumab they remain useful under specific clinical settings. For example, thermal laser may be appropriate when the neovascular lesion is well defined and extrafoveal, or photodynamic, therapy may be used when ranibizumab is contraindicated or ineffective.

## What research is ongoing?

The fusion protein of binding domains from human vascular endothelial growth factor receptors 1 and 2 is a new treatment that showed highly promising findings in terms of improved retinal morphology and visual acuity in phase 1 dose seeking trials.<sup>29</sup> Its affinity for vascular endothelial growth factor is 200 times greater than that of ranibizumab, and because it remains in the vitreous for longer than ranibizumab it could achieve a similar efficacy with longer re-treatment intervals. Results of a head to head comparison of vascular endothelial growth factor TRAP and ranibizumab are expected towards the end of 2010.

Physical adjunctive treatments combined with ranibizumab are also being investigated—the theory is that adjunctive therapy would destroy new vessels while ranibizumab would minimise the exudative response and remove the stimulus for further new vessel growth. Although some pilot studies suggested marked reductions in the need for re-treatment with the combination of ranibizumab and physical adjunctive therapies, randomised controlled trials have not shown benefit in terms of a reduced need for re-treatment or improved visual outcome at 12 months when compared with ranibizumab monotherapy.<sup>30</sup> A further approach involves focused macular irradiation using strontium 90 brachytherapy combined with an anti-vascular endothelial growth factor drug. Preliminary findings from small randomised pilot studies with 12 months of follow-up suggest functional outcomes similar to those seen in the ranibizumab monotherapy trials but achieved without the need for continuing re-treatments with anti-vascular endothelial growth factor drugs.<sup>31</sup> A multicentre phase 3 randomised controlled clinical trial of epimacular brachytherapy combined with ranibizumab versus ranibizumab monotherapy (the CABERNET study) is in progress. Further strategies being tested include the combination of trophic growth factors that prevent death of photoreceptor or retinal pigment epithelial cells with inhibitors of vascular endothelial growth factor. Promising new agents include ciliary neurotrophic growth factor, which has been encapsulated for slow sustained intraocular release and delivery, and platelet derived growth factor.<sup>32</sup> Both are undergoing safety testing in phase 1 trials.

### Future research

Several distinct therapeutic approaches to prevention are being investigated. These include inhibition of oxidative stress and interference with the visual cycle, but the most exciting development is the use of immune modulation. This approach has arisen with the recognition that disordered complement regulation is a key step in the pathogenesis of both neovascularisation and geographic atrophy, and it has provided the impetus for the development of immunomodulators as a range of new therapeutic agents.<sup>33 34</sup> Since drusen almost always precede the development of geographic atrophy, immunomodulatory drugs can be administered to eyes with early macular degeneration without overt functional loss. Glatiramer acetate is one such drug and a small observational study has shown marked reductions in drusen size and area within 12 weeks of intraocular administration.<sup>35</sup> Other treatments include POT-4 (Potentia Pharmaceuticals, Louisville, Kentucky) and

eculizumab (Alexion Pharmaceuticals, Cheshire, Connecticut). These drugs and others are inhibitors of complement activation that prevent formation of the membrane attack complex or other inflammatory mediators, thus targeting the pathways that lead to early and late age related macular degeneration.

In summary, advances in the appreciation of the role of vascular endothelial growth factor in pathological ocular neovascularisation have been translated into new treatment agents and improved visual outcomes for neovascular age related macular degeneration. Further improvements in the understanding of immunological function and dysfunction in healthy ageing and degeneration of macular tissues are ushering in a new era of biological agents that may prevent progression from early to late age related macular degeneration. If the promise is realised there is huge potential for maintaining good eyesight and quality of life in older adults.

### **Tips for non-specialists**

Neovascularisation and geographic atrophy are late manifestations of age related macular degeneration

The sudden onset of central distortion and blurring are indicators of neovascularisation and patients should be urgently assessed by specialists with expertise in managing retinal disorders

Smoking is strongly and consistently associated with age related macular degeneration and susceptible individuals (such as those with a family history) and older adults (aged 65 and older) should be warned about the risk to eyesight

Patients' expectations are currently high owing to the publicity campaigns associated with introduction of anti-vascular endothelial growth factor drugs, but restoration of perfect central visual function is not yet a reality.

### **Questions for future research**

Do gene-environment and gene-nutrient interactions alter the risk of age related macular degeneration?

Do genetic factors determine morphological responsiveness to vascular endothelial growth factor inhibition?

Can visual outcomes in neovascular age related macular degeneration be improved through adjunctive treatment with neurotrophic agents?

What are the optimum screening strategies for identification of people at highest risk of developing late stage age related macular degeneration?

### **Additional educational resources**

#### **Resources for patients**

AMD Alliance International ([www.amdalliance.org](http://www.amdalliance.org))—promotes awareness of age related macular degeneration and provides support and information for those affected by the condition

Macular Disease Society ([www.maculardisease.org](http://www.maculardisease.org))— UK charity dedicated to helping people with macular degeneration.

#### **Resources for healthcare professionals**

Ophthalmic Technology Assessments (<http://one.aao.org/CE/PracticeGuidelines/Ophthalmic.aspx?sid=ab789157-5312-4bbe-86ed-8d164ffa9567>)—evaluations of new and existing procedures, drugs, and diagnostic and screening tests available through the American Academy of Ophthalmology

Royal College of Ophthalmologists—([www.rcophth.ac.uk/old-website-pages/publications](http://www.rcophth.ac.uk/old-website-pages/publications))—guidelines from the Royal College of Ophthalmologists

## **Notes**

Cite this as: *BMJ* 2010;340:c981

## **Footnotes**

- Contributors: UC drafted the manuscript and is the guarantor. PJR contributed to the manuscript and critically evaluated and revised the manuscript. JE contributed to the manuscript and critically evaluated and revised the manuscript
- Competing interests: All authors have completed the unified competing interest form at [www.icmje.org/coi\\_disclosure.pdf](http://www.icmje.org/coi_disclosure.pdf) (available on request from the corresponding author). (1) The authors declare that they have had no support for the submitted work. (2) In the past three years: PJR has received honoraria and travel support from Genentech, Othera, CoMentis, GlaxoSmithKline, Sanofi-Aventis, Oraya, Potentia, and Carl Zeiss Meditec, that might have an interest in the submitted work; PR has received research support from Genentech, Alcon, Othera, Quark, CoMentis, Potentia, Carl Zeiss Meditec, and Alexion; UC has received honoraria and travel support from Novartis, Allergan, Pfizer, Oraya, Neovista, and Bausch and Lomb; and UC has received research support from Alcon, Novartis, and Pfizer. (3) None of the spouses, partners, or children of the authors has any financial relationships with companies that might have an interest in the submitted work. (4) None of the authors have non financial interests that may be relevant to the submitted work.

## **References**

- ↵Owen CG, Fletcher AE, Donoghue M, Rudnicka AR. How big is the burden of visual loss caused by age-related macular degeneration in the United Kingdom? *Br J Ophthalmol*2003;**87**:312-7. [Abstract/FREE Full Text](#)
- ↵Woo KJ, Sanjay S, AuEong KG. The epidemiology of age-related macular degeneration in the Indian subcontinent. *Acta Ophthalmol*2009;**87**:262-9. [CrossRef](#) [Medline](#)

3. ↪Beatty S, Koh HH, Henson D, Boulton M. The role of oxidative stress in the pathogenesis of age-related macular degeneration. *Surv Ophthalmol*2000;**45**:115-34. [CrossRef](#) [Medline](#) [Web of Science](#)
4. ↪Smith W, Assink J, Kelien R, Mitchell P, Klaver CC, Klein BE, et al. Risk factors for age-related macular degeneration: pooled findings from three continents. *Ophthalmology*2001;**108**:697-704. [CrossRef](#) [Medline](#) [Web of Science](#)
5. ↪Fletcher AE, Bentham GC, Agnew M, Young IS, Augood C, Chakravarthy U, et al. Sunlight exposure, antioxidants, and age-related macular degeneration. *Arch Ophthalmol*2008;**126**:1396-403. [CrossRef](#) [Medline](#) [Web of Science](#)
6. ↪Klein RJ, Zeiss C, Chew EY, Tsai JY, Sackler RS, Haynes C, et al. Complement factor H polymorphism in age-related macular degeneration. *Science*2005;**308**:385-9. [Abstract/FREE Full Text](#)
7. ↪Yates JR, Sepp T, Matharu BK, Khan JC, Thurlby DA, Shahid H, et al. Genetic factors in AMD study group. Complement C3 variant and the risk of age-related macular degeneration. *N Engl J Med*2007;**357**:553-61. [CrossRef](#) [Medline](#) [Web of Science](#)
8. ↪Hughes AE, Orr N, Esfandiary H, Diaz-Torres M, Goodship T, Chakravarthy U. A common CFH haplotype with deletion of CFHR1 and CFHR3 is associated with a lower risk of age-related macular degeneration. *Nat Genet*2006;**38**:1173-7. [CrossRef](#) [Medline](#) [Web of Science](#)
9. ↪Hughes AE, Orr N, Patterson C, Esfandiary H, Hogg R, McConnell V, Silvestri G, et al. Neovascular age-related macular degeneration risk based on CFH, LC387715/HTRA1 and smoking. *PLoS Med*2007;**4**:e355. [CrossRef](#) [Medline](#)
10. ↪Anderson DS, Mulins RF, Hageman GS, Johnson LV. A role for local inflammation in the formation of drusen in the aging eye. *Am J Ophthalmol*2002;**134**:411-31. [CrossRef](#) [Medline](#) [Web of Science](#)
11. ↪Zhou J, Fonseca MI, Pisalyaput K, Tenner AJ. Complement C3 and C4 expression in C1q sufficient and deficient mice models of *Alzheimers Disease J Neurochem*2008;**106**:2080-92.
12. ↪Age-Related Eye Diseases Study Group. A simplified severity scale for age-related macular degeneration. AREDS report 18. *Arch Ophthalmol*2005;**123**:1570-74. [CrossRef](#) [Medline](#) [Web of Science](#)
13. ↪Wong TY, Chakravarthy U, Klein R, Mitchell P, Slateva G, Buggage R, et al. The natural history and prognosis of neovascular age-related macular degeneration; a systematic review of the literature and meta analysis. *Ophthalmology*2008;**115**:116-26. [CrossRef](#) [Medline](#) [Web of Science](#)
14. ↪Age-Related Eye Disease Study Research Group. A randomized, placebo-controlled, clinical trial of high-dose supplementation with vitamins C and E, beta carotene, and zinc for age-related macular degeneration and vision loss: AREDS report no 8. *Arch Ophthalmol*2001;**119**:1417-36. [CrossRef](#) [Medline](#) [Web of Science](#)
15. ↪Satia JA, Littman A, Slatore CG, Galanko JA, White E. Long term use of beta-carotene, retinol, lycopene and lutein supplements and lung cancer risk: results from the VITamins And Lifestyle (VITAL) study. *Am J Epidemiol*2009;**169**:815-28. [Abstract/FREE Full Text](#)
16. ↪Paris V, Tedeschi MG, Varano M, Saviano S, Piermarocchi S, CARMIS study group. Carotenoids and antioxidants in age-related Maculopathy Italian study: electroretinogram modifications after 1 year. *Ophthalmology*2008;**115**:324-33. [CrossRef](#) [Medline](#) [Web of Science](#)
17. ↪Virgili G, Bini A. Laser photocoagulation for neovascular age-related macular degeneration. *Cochrane Database Syst Rev*2007;(3):CD004763.
18. ↪Wormald R, Evans J, Smeeth L, Henshaw K. Photodynamic therapy for neovascular age-related macular degeneration. *Cochrane Database Syst Rev*2007;(3):CD002030.
19. ↪Gragoudas ES, Adamis AP, Cunningham ET Jr, Feinsod M, Guyer DR, for the VEGF Inhibition Study in Ocular Neovascularization Clinical Trial Group. Peptanib for neovascular age-related macular degeneration. *N Engl J Med*2004;**351**:2805-16. [CrossRef](#) [Medline](#) [Web of Science](#)
20. ↪Rich RM, Rosenfeld PJ, Puliafito CA, Dubovy SR, Davis JL, Flynn HW Jr, et al. Short-term safety and efficacy of intravitreal bevacizumab (Avastin) for neovascular age-related macular degeneration. *Retina*2006;**26**:495-511. [CrossRef](#) [Medline](#)
21. ↪Rosenfeld PJ, Brown DM, Heier JS, Boyer DS, for the MARINA Study Group. Ranibizumab for neovascular age related macular degeneration. *N Engl J Med*2006;**355**:1419-31.
22. ↪Brown DM, Kaiser PK, Michels M et al; ANCHOR Study Group. Ranibizumab versus verteporfin for neovascular age-related macular degeneration. *N Engl J Med*. 2006;**355**:1432-4412. [CrossRef](#) [Medline](#) [Web of Science](#)
23. ↪Fung AE, Rosenfeld PJ, Reichel E. The international intravitreal bevacizumab safety survey: using the internet to assess drug safety worldwide. *Br J Ophthalmol*2006;**90**:1344-9. [Abstract/FREE Full Text](#)
24. ↪Chakravarthy U, Lim JI. New treatments for acute neovascular macular degeneration. *BMJ*2007;**10**:269-70. [CrossRef](#)
25. ↪Eldem B. Visual acuity response profiles of patients with neovascular AMD treated with quarterly dosing of ranibizumab in the EXCITE study. Retina Congress Scientific Abstracts, 2009
26. ↪Royal College of Ophthalmologists. Age-related macular degeneration guidelines for management. February 2009. [www.rcophth.ac.uk/docs/publications/AMD\\_GUIDELINES\\_FINAL\\_VERSION\\_Feb\\_09.pdf](http://www.rcophth.ac.uk/docs/publications/AMD_GUIDELINES_FINAL_VERSION_Feb_09.pdf).
27. ↪National Institute for Health and Clinical Excellence. Pegaptanib and ranibizumab for the treatment of age-related macular degeneration. August 2008. <http://guidance.nice.org.uk/TA155>.
28. ↪Witkin AJ, Vuong LN, Srinivasan VJ, Gorczyńska I, Reichel E, Baurnal CR, et al. High-speed ultrahigh resolution optical coherence tomography before and after ranibizumab for age-related macular degeneration. *Ophthalmology*2009;**116**:956-63. [CrossRef](#) [Medline](#) [Web of Science](#)
29. ↪Nguyen QD, Shah SM, Browning DJ, Hudson J, Sonkin P, Hariprasad SM, et al. A phase 1 study of intravitreal vascular endothelial growth factor trap-eye in patients with neovascular age-related macular degeneration. *Ophthalmology*2009;**116**:2141-8. [CrossRef](#) [Medline](#) [Web of Science](#)
30. ↪Schmidt Erfurth U. Verteporfin Photodynamic therapy and ranibizumab combination for subfoveal CNV secondary to AMD. 12 month efficacy. Results of the Mont Blanc Study. Retina Congress Scientific Abstracts, 2009.
31. ↪Avila MP, Farah ME, Santos A, Karpran Z, Duprat JP, Woodward BW, et al. Twelve month safety and visual acuity results from a feasibility study of intraocular epi retinal radiation therapy for the treatment of subfoveal CNV secondary to AMD. *Retina*2009;**29**:157-69. [CrossRef](#) [Medline](#) [Web of Science](#)
32. ↪Emerich DF, Thanos CG. NT 501: an ophthalmic implant of polymer-encapsulated ciliary neurotrophic factor-producing cells. *Curr Opin Mol Ther*2008;**10**:506-15. [Medline](#) [Web of Science](#)
33. ↪Holers VM. The spectrum of complement alternative pathway-mediated diseases. *Immunol Rev*2008;**223**:300-16. [CrossRef](#)
34. ↪Schnatbaum K, Locardi E, Scham D, Richter U, Hawlisch H, Knolle J, et al. Peptidomimetic C5a receptor antagonists with hydrophobic substitutions at the C terminus: increased receptor specificity and in vivo activity. *Bioorg Med Chem Lett*2006;**16**:5088-92. [CrossRef](#) [Medline](#) [Web of Science](#)
35. ↪Landa G, Butovsky O, Shoshani J, Schwartz M, Pollac A. Weekly vaccination with Copaxone (glatiramer acetate) as a potential therapy for dry age-related macular degeneration. *Curr Eye Res*2008;**33**:1011-3. [CrossRef](#) [Medline](#) [Web of Science](#)



Tweet